



**HAL**  
open science

## Partial ulnar head replacement : Eclipse® prosthesis : a multicentric review of 27 patients

Virginie Mesquida

► **To cite this version:**

Virginie Mesquida. Partial ulnar head replacement : Eclipse® prosthesis : a multicentric review of 27 patients. Médecine humaine et pathologie. 2011. dumas-00658822

**HAL Id: dumas-00658822**

**<https://dumas.ccsd.cnrs.fr/dumas-00658822>**

Submitted on 11 Jan 2012

**HAL** is a multi-disciplinary open access archive for the deposit and dissemination of scientific research documents, whether they are published or not. The documents may come from teaching and research institutions in France or abroad, or from public or private research centers.

L'archive ouverte pluridisciplinaire **HAL**, est destinée au dépôt et à la diffusion de documents scientifiques de niveau recherche, publiés ou non, émanant des établissements d'enseignement et de recherche français ou étrangers, des laboratoires publics ou privés.

Année 2011

N°

**PARTIAL ULNAR HEAD REPLACEMENT :  
ECLYPSE® PROSTHESIS  
A MULTICENTRIC REVIEW OF 27 PATIENTS**

THÈSE  
PRÉSENTÉE POUR L'OBTENTION DU DOCTORAT EN MÉDECINE  
DIPLOME D'ETAT

**Virginie MESQUIDA**

Née le 20 avril 1982 à Chambéry (73)

Thèse soutenue publiquement à la faculté de médecine de Grenoble  
Le 13 Décembre 2011

DEVANT LE JURY COMPOSÉ DE :

Président : Monsieur le Professeur F. MOUTET

Membres : Monsieur le Professeur D. SARAGAGLIA  
Monsieur le Professeur P. MERLOZ  
Monsieur le Docteur G. DEBUS  
Mademoiselle le Docteur M. LORET

*La faculté de médecine de Grenoble n'entend donner aucune approbation ni improbation aux opinions émises dans les thèses ; ces opinions sont considérées comme propres à leurs auteurs.*

**Professeur des Universités - Praticien Hospitalier  
2011-2012**

Nom	Prénom	Intitulé de la discipline universitaire
ALBALADEJO	Pierre	Anesthésiologie-réanimation
ARVIEUX-BARTHELEMY	Catherine	Chirurgie générale
BACONNIER	Pierre	Biostatistiques, informatique médicale et technologies de communication
BAGUET	Jean-Philippe	Cardiologie
BALOSSO	Jacques	Radiothérapie
BARRET	Luc	Médecine légale et droit de la santé
BAUDAIN	Philippe	Radiologie et imagerie médicale
BEANI	Jean-Claude	Dermato-vénérologie
BENHAMOU	Pierre Yves	Endocrinologie, diabète et maladies métaboliques
BERGER	François	Biologie cellulaire
BLIN	Dominique	Chirurgie thoracique et cardio-vasculaire
BOLLA	Michel	Cancérologie; radiothérapie
BONAZ	Bruno	Gastroentérologie; hépatologie; addictologie
BOSSON	Jean-Luc	Biostatistiques, informatique médicale et technologies de communication
BOUGEROL	Thierry	Psychiatrie d'adultes
BRAMBILLA	Elisabeth	Anatomie et cytologie pathologiques
BRAMBILLA	Christian	Pneumologie
BRICAULT	Ivan	Radiologie et imagerie médicale
BRICHON	Pierre-Yves	Chirurgie thoracique et cardio-vasculaire
BRIX	Muriel	Chirurgie maxillo-faciale et stomatologie
CAHN	Jean-Yves	Hématologie
CARPENTIER	Françoise	Thérapeutique; médecine d'urgence
CARPENTIER	Patrick	Chirurgie vasculaire; médecine vasculaire
CESBRON	Jean-Yves	Immunologie
CHABARDES	Stephan	Neurochirurgie
CHABRE	Olivier	Endocrinologie, diabète et maladies métaboliques
CHAFFANJON	Philippe	Anatomie
CHAVANON	Olivier	Chirurgie thoracique et cardio-vasculaire
CHIQUET	Christophe	Ophtalmologie
CHIROSEL	Jean-Paul	Anatomie
CINQUIN	Philippe	Biostatistiques, informatique médicale et technologies de communication
COHEN	Olivier	Biostatistiques, informatique médicale et technologies de communication
COUTURIER	Pascal	Gériatrie et biologie du vieillissement
CRACOWSKI	Jean-Luc	Pharmacologie fondamentale; pharmacologie clinique

DE GAUDEMARIS	Régis	Médecine et santé au travail
DEBILLO	Thierry	Pédiatrie
DEMATTEIS	Maurice	Addictologie
DEMONGEOT	Jacques	Biostatistiques, informatique médicale et technologies de communication
DESCOTES	Jean-Luc	Urologie
ESTEVE	François	Biophysique et médecine nucléaire
FAGRET	Daniel	Biophysique et médecine nucléaire
FAUCHERON	Jean-Luc	Chirurgie générale
FERRETTI	Gilbert	Radiologie et imagerie médicale
FEUERSTEIN	Claude	Physiologie
FONTAINE	Eric	Nutrition
FRANCOIS	Patrice	Epidémiologie, économie de la santé et prévention
GARBAN	Frédéric	Hématologie; transfusion
GAUDIN	Philippe	Rhumatologie
GAVAZZI	Gaetan	Gériatrie et biologie du vieillissement
GAY	Emmanuel	Neurochirurgie
GRIFFET	Jacques	Chirurgie infantile
HALIMI	Serge	Nutrition
HOMMEL	Marc	Neurologie
JOUK	Pierre-Simon	Génétique
JUVIN	Robert	Rhumatologie
KAHANE	Philippe	Physiologie
KRACK	Paul	Neurologie
KRAINIK	Alexandre	Radiologie et imagerie médicale
LANTUEJOUL	Sylvie	Anatomie et cytologie pathologiques
LEBAS	Jean-François	Biophysique et médecine nucléaire
LEBEAU	Jacques	Chirurgie maxillo-faciale et stomatologie
LECCIA	Marie-Thérèse	Dermato-vénérologie
LEROUX	Dominique	Génétique
LEROY	Vincent	Gastroentérologie; hépatologie; addictologie
LETOUBLON	Christian	Chirurgie générale
LEVY	Patrick	Physiologie
LUNARDI	Joël	Biochimie et biologie moléculaire
MACHECOURT	Jacques	Cardiologie
MAGNE	Jean-Luc	Chirurgie vasculaire
MAITRE	Anne	Médecine et santé au travail
MAURIN	Max	Bactériologie-virologie
MERLOZ	Philippe	Chirurgie orthopédique et traumatologique

MORAND	Patrice	Bactériologie-virologie
MORO-SIBILOT	Denis	Pneumologie
MOUSSEAU	Mireille	Cancérologie
MOUTET	François	Chirurgie plastique, reconstructrice et esthétique; brûlogie
PALOMBI	Olivier	Anatomie
PASSAGIA	Jean-Guy	Anatomie
PAYEN DE LA GARANDERIE	Jean-François	Anesthésiologie-réanimation
PELLOUX	Hervé	Parasitologie et mycologie
PEPIN	Jean-Louis	Physiologie
PERENNOU	Dominique	Médecine physique et de réadaptation
PERNOD	Gilles	Médecine vasculaire
PIOLAT	Christian	Chirurgie infantile
PISON	Christophe	Pneumologie
PLANTAZ	Dominique	Pédiatrie
POLACK	Benoît	Hématologie
PONS	Jean-Claude	Gynécologie-obstétrique
RAMBEAUD	Jean-Jacques	Urologie
REYT	Emile	Oto-rhino-laryngologie
RIGHINI	Christian	Oto-rhino-laryngologie
ROMANET	Jean-Paul	Ophtalmologie
SARAGAGLIA	Dominique	Chirurgie orthopédique et traumatologique
SCHMERBER	Sébastien	Oto-rhino-laryngologie
SELE	Bernard	Biologie et médecine du développement et de la reproduction
SERGENT	Fabrice	Gynécologie-obstétrique
SESSA	Carmine	Chirurgie vasculaire
STAHL	Jean-Paul	Maladies infectueuses; maladies tropicales
STANKE	Françoise	Pharmacologie fondamentale
TIMSIT	Jean-François	Réanimation
TONETTI	Jérôme	Chirurgie orthopédique et traumatologique
TOUSSAINT	Bertrand	Biochimie et biologie moléculaire
VANZETTO	Gérald	Cardiologie
VUILLEZ	Jean-Philippe	Biophysique et médecine nucléaire
WEIL	Georges	Epidémiologie, économie de la santé et prévention
ZAOUI	Philippe	Néphrologie
ZARSKI	Jean-Pierre	Gastroentérologie; hépatologie; addictologie

**Maître de Conférence des Universités - Praticien Hospitalier  
2011-2012**

Nom	Prénom	Intitulé de la discipline universitaire
BONNETERRE	Vincent	Médecine et santé au travail
BOTTARI	Serge	Biologie cellulaire
BOUTONNAT	Jean	Cytologie et histologie
BRENIER-PINCHART	Marie-Pierre	Parasitologie et mycologie
BRIOT	Raphaël	Thérapeutique; médecine d'urgence
CALLANAN-WILSON	Mary	Hématologie; transfusion
CROIZE	Jacques	Bactériologie-virologie
DERANSART	Colin	Physiologie
DETANTE	Olivier	Neurologie
DUMESTRE-PERARD	Chantal	Immunologie
EYSSERIC	Hélène	Médecine légale et droit de la santé
FAURE	Julien	Biochimie et biologie moléculaire
GILLOIS	Pierre	Biostatistiques, informatique médicale et technologies de communication
GRAND	Sylvie	Radiologie et imagerie médicale
HENNEBICQ	Sylviane	Biologie et médecine du développement et de la reproduction
HOFFMANN	Pascale	Gynécologie-obstétrique
LABARERE	José	Epidémiologie, économie de la santé et prévention
LAPORTE	François	Biochimie et biologie moléculaire
LARDY	Bernard	Biochimie et biologie moléculaire
LARRAT	Sylvie	Bactériologie-virologie
LAUNOIS-ROLLINAT	Sandrine	Physiologie
MALLARET	Marie-Reine	Epidémiologie, économie de la santé et prévention
MAUBON	Danièle	Parasitologie et mycologie
MC LEER (FLORIN)	Anne	Cytologie et histologie
MOREAU-GAUDRY	Alexandre	Biostatistiques, informatique médicale et technologies de communication
MOUCHET	Patrick	Physiologie

PACLET	Marie-Hélène	Biochimie et biologie moléculaire
PASQUIER	Dominique	Anatomie et cytologie pathologiques
PAYSANT	François	Médecine légale et droit de la santé
PELLETIER	Laurent	Biologie cellulaire
RAY	Pierre	Génétique
RIALLE	Vincent	Biostatistiques, informatique médicale et technologies de communication
SATRE	Véronique	Génétique
STASIA	Marie-Josée	Biochimie et biologie moléculaire
TAMISIER	Renaud	Physiologie

## Remerciements,

### **A Monsieur le Professeur Moutet,**

*Vous me faites l'honneur de présider ce jury de thèse et de juger mon travail. Je vous remercie de m'avoir ouvert les portes de la chirurgie de la main et de votre soutien dans ce choix. Je vous suis reconnaissante de me faire profiter de votre enseignement tout au long de mon cursus.*

### **A Monsieur le Professeur Saragaglia,**

*Votre rigueur, votre expérience et vos connaissances en traumatologie ainsi qu'en orthopédie sont une chance inespérée pour vos élèves et je suis très honorée d'avoir pu en profiter. Veuillez trouver l'expression de mon plus profond respect pour votre enseignement, votre disponibilité et votre soutien.*

### **A Monsieur le Professeur Merloz,**

*Je vous remercie d'avoir accepté de faire partie de ce jury. Je vous suis redevable de la qualité de votre enseignement, de votre disponibilité et de votre gentillesse. Soyez assuré de ma profonde considération.*

### **A Monsieur le Docteur Debus,**

*Je te remercie d'avoir accepté de faire partie de ce jury. Tes qualités pédagogiques et humaines sont pour moi en exemple. Je suis très honorée de pouvoir encore profiter cette année de tes connaissances chirurgicales, de ta sérénité et de ton calme en toutes circonstances sans oublier ton humour !*

### **A Mademoiselle le Docteur Loret,**

*Marie, je te remercie infiniment pour ton aide et ta disponibilité sans lesquelles je n'aurai pu achever ce travail. Tes connaissances chirurgicales, ton professionnalisme, ta gentillesse et ta bonne humeur quotidienne font de toi un modèle pour moi. Je suis très honorée d'être ton interne et très fière d'être ton amie ! Merci pour cette amitié si précieuse.*



***A tous les chirurgiens qui ont participés à cette étude,***

*Monsieur le Docteur Marc Garcia-Elias, merci de m'avoir proposé ce travail en espérant qu'il sera à la hauteur de vos attentes...*

*Messieurs les Docteurs Philippe Bellemère et Jean-Pierre Péquignot, merci d'avoir accepté de participer à cette étude et merci pour votre disponibilité notamment ces derniers mois!*

*Monsieur le Docteur Nick Gillham, merci de m'avoir accueilli si chaleureusement dans votre équipe lors de ma venue à Banbury et pour votre proposition de travail !*

*Madame Kirsten Davies, un grand merci pour ta disponibilité durant ces deux dernières années et pour ton aide si précieuse lors de la revue des patients, mon anglais n'étant pas si bon finalement...*

*Madame le Docteur Isabelle David, merci pour votre enthousiasme et vos encouragements dans ce projet.*

*Monsieur le Docteur Martin Chochole, merci d'avoir répondu présent si rapidement malgré la distance.*

***A toute l'équipe de chirurgie de la main,***

*Alexandra,*

*Je te remercie de me transmettre tes connaissances, ta rigueur et tes grandes qualités humaines.*

*Je suis très honorée d'être une de tes élèves.*

*Docteur Corcella,*

*Je vous remercie de me faire bénéficier de votre expérience chirurgicale au quotidien.*

*A l'équipe infirmière de consultation,*

*Irène, Isabelle, Christine, Christiane.*

*Vos conseils et votre expérience sont toujours les bienvenus surtout lors de nos premiers pas en consultation ! Un grand merci pour votre bonne humeur et votre enthousiasme quotidien !*

*A l'équipe du bloc opératoire,*

*Christine, Hassina, Cécile, Magalie, Claude, Brigitte...*

*Merci pour votre soutien et votre patience lors de nos débuts de chirurgiens ! C'est un réel plaisir de travailler avec vous.*

*A l'équipe soignante du 7<sup>ème</sup> M,*

*Merci pour votre gentillesse et votre efficacité dans le service malgré nos petits « oublis » parfois !*

*Aux secrétaires,*

*Marie, Jöelle, Pamela, Fatiha, Déborah, Aurélie..*

*Merci pour votre disponibilité et votre rigueur quand parfois nous en manquons...*

### **A toute l'équipe d'orthopédie de l'hôpital Sud,**

#### Aux chirurgiens,

*Christophe, merci de m'avoir communiqué le goût de travail bien fait! Tes connaissances, ta rigueur et ton perfectionnisme font de toi un exemple pour moi. Je te remercie du soutien et de la confiance que tu me témoignes.*

*Numa, j'ai appris à comprendre ton langage fait de « grognements » mais je préfère quand tu parles! Je te remercie de m'avoir transmis ta « passion » pour la chirurgie du membre supérieur et pour ta confiance au bloc. Et un grand merci pour l'arthroscopie d'épaule !!*

*Matthieu, merci pour tes grandes qualités humaines et de m'avoir montré qu'on pouvait travailler avec rigueur dans la bonne humeur. Ta « sous-peau et au lit » et « allez zou ! » resteront gravés dans ma mémoire.*

*Marc, merci pour ta bonne humeur et ta sympathie. Ne m'envoie pas trop d'épicondylites ni d'épines de palmier en consultation!*

*Stéphane, Brice, Eric, merci de m'avoir soutenue lors de mes deux passages à Sud. Je n'en garde que de bons souvenirs !*

#### A l'équipe du bloc,

*Valérie, Maude, Manue, Stéphanie, Véronique(s), Isabelle(s), Céline, Gaëlle, Sandrine, Gigi, Anne, Arlette, Maria, Clarisse, France, Dina, « Kate », Daniel, Luc, Franck, Hafid, Serge, Jean-Paul, Mickael, Patrick(s), Chouky, James, Sylvain... et tous ceux que j'oublie.*

*Je vous remercie pour votre rigueur et professionnalisme lors des interventions mais également pour votre accueil, votre bonne humeur et sympathie envers moi. Et merci pour les délicieux desserts des week-ends de garde !*

#### Aux équipes soignantes des étages,

*Géraldine, Stéphanie, Besma, Julie, Joëlle, Perrine, Catherine, William...et tous les autres.*

*Merci pour votre compréhension lorsque l'on est « coincé » au bloc et pour pallier à nos oublis toujours avec le sourire !*

### **A toute l'équipe d'orthopédie de l'hôpital Nord,**

*Monsieur le Professeur Tonetti, merci pour votre enseignement.*

*Monsieur le Docteur Eid, votre savoir et votre sagesse font de vous un modèle.*

*Vito et Julie, vous avez été des assistants inoubliables ! Merci pour votre enseignement, votre amitié et les bons moments partagés ensemble.*

### **A toute l'équipe d'orthopédie du membre supérieur de Fort-de-France,**

*Messieurs Delattre, Duroux, Guitton, Lucian,*

*A toute l'équipe soignante du 2<sup>ème</sup> B et aux secrétaires, un grand merci pour votre accueil, votre joie de vivre et vos heures supplémentaires !! A bientôt, si Dieu l'veut !*

### **A toute l'équipe d'orthopédie d'Annecy,**

*Messieurs Chirpaz, Mèlère et Jager.*

*Merci de m'avoir transmis le goût de l'orthopédie et de la chirurgie de la main. Votre accueil, vos enseignements et votre bonne humeur font de ces 6 mois un stage inoubliable !*

### **A l'équipe de chirurgie générale de Grenoble,**

*Irène et messieurs Delannoy, Risse et Voirin,*

*Je vous remercie de la confiance et du soutien que vous m'avez accordé lors de mes premiers pas de chirurgien. Vous m'avez appris les bases de la chirurgie et le maniement du bistouri !*

### **A tous mes co-internes,**

*Charline, je t'apprécie beaucoup. Toujours de bonne humeur, c'est un plaisir de travailler avec toi. Tu prends soin des autres mais pense un peu à toi ! Merci pour ton amitié.*

*Lydie, Séverine, votre rigueur et vos qualités humaines feront de vous de très bons orthopédistes. Merci pour tous les bons moments partagés, les fou-rires et les conversations de filles...*

*Ruattiiii, tes blagues et autres imitations égayent nos journées. Ce troisième semestre ensemble promet d'être inoubliable !*

*P'tit Billy, merci pour ta gentillesse et ton amitié. Malgré ton expatriation à Chambéry, on compte sur toi pour le week-end ski !*

*Alexis, Gaël, vous avez été de super co-internes et vous serez de Grands chefs !*

*Roch, finalement on aura réussi à ne pas s'entretuer ces 6 derniers mois. Bon courage à Lyon et merci pour les entraînements de tennis !*

*Romain, merci pour ce semestre au 13<sup>ème</sup> ensemble. Tu seras un grand chirurgien !*

*Guillaume, merci pour ta gentillesse, ta disponibilité, d'avoir été mon « faisant fonction de chef » et de m'avoir aidé tant de fois en Martinique. Je suis dispo quand tu veux pour un extenseur à minuit au bloc !! C'est un plaisir de te retrouver au DU d'Oberlin !*

*Jérémie, Baptiste, Aurélien, merci pour toutes les soirées passées et à venir!!*

### **A ma famille,**

*Maman, Papa, merci pour votre soutien, même de loin, tout au long de mes études.*

*Stéphanie, merci d'être là pour m'écouter et me reconforter pendant des heures au téléphone !*

*A mes regrettés grands-parents...*

### **A mes amis,**


*Aurélie, merci pour ton amitié si précieuse, ce fut un honneur d'être ta témoin de mariage ! Merci pour ton soutien pendant toutes ces années et pour tous les bons moments partagés, en espérant qu'il y en aura pleins d'autres ! Je t'adore ma biche !*

*Benjamin, dit Chouchou, merci pour ta gentillesse, ta disponibilité et tes connaissances en stat' ! Sans toi, je n'aurais pu achever ce travail. Tu es quelqu'un d'exceptionnel !*

*Julien, dit l'affreux, tu es toi aussi quelqu'un d'exceptionnel même si tout le monde ne le voit pas ! Merci pour tes séances de jogging-debriefing, pour tes dédicaces Kuduro et ta bonne humeur quotidienne ! Merci pour ton amitié depuis tant d'années !*

*Marie, Elo, Clo et Domitille, on ne s'est pas trop vu ces derniers temps mais nos soirées filles sont toujours de bons moments pleins de « bla-bla » pendant des heures...j'adore ! Gros bisous à vous toutes !*

*Gregoire, merci de m'avoir proposé cette colocation, c'est un plaisir de rentrer à la maison ! Je suis très heureuse de te connaître et je viendrai te voir aux Etats-Unis !*



## *SERMENT D'HIPPOCRATE*

*En présence des Maîtres de cette Faculté, de mes chers condisciplines et devant l'effigie d'HIPPOCRATE,*

*Je promets et je jure d'être fidèle aux lois de l'honneur et de la probité dans l'exercice de la Médecine.*

*Je donnerais mes soins gratuitement à l'indigent et n'exigerais jamais un salaire au dessus de mon travail. Je ne participerai à aucun partage clandestin d'honoraires.*

*Admis dans l'intimité des maisons, mes yeux n'y verront pas ce qui s'y passe ; ma langue taira les secrets qui me seront confiés et mon état ne servira pas à corrompre les mœurs, ni à favoriser le crime.*

*Je ne permettrai pas que des considérations de religion, de nation, de race, de parti ou de classe sociale viennent s'interposer entre mon devoir et mon patient.*

*Je garderai le respect absolu de la vie humaine.*

*Même sous la menace, je n'admettrai pas de faire usage de mes connaissances médicales contre les lois de l'humanité.*

*Respectueux et reconnaissant envers mes Maîtres, je rendrai à leurs enfants l'instruction que j'ai reçue de leurs pères.*

*Que les hommes m'accordent leur estime si je suis fidèle à mes promesses. Que je sois couvert d'opprobre et méprisé de mes confrères si j'y manque.*

# Table of contents

<b>I- INTRODUCTION.....</b>	<b>14</b>
<b>II- DISTAL RADIOULNAR JOINT ANATOMY AND BIOMECHANIC.....</b>	<b>15</b>
- 1) DRUJ ANATOMY .....	15
<i>a- DRUJ articulation :</i> .....	15
<i>b- DRUJ ligaments :</i> .....	18
- 2) DRUJ BIOMECHANICS.....	20
<i>a- Kinematics :</i> .....	20
<i>b- Kinetics :</i> .....	23
<b>III- MATERIALS AND METHODS.....</b>	<b>25</b>
- 1) THE PROSTHESIS.....	25
- 2) INDICATIONS AND CONTRAINDICATIONS .....	26
- 3) SURGICAL TECHNIQUE .....	26
- 4) POSTOPERATIVE CARE.....	30
- 5) PATIENT POPULATION.....	31
- 6) ASSESSMENTS .....	31
<b>IV- RESULTS.....</b>	<b>33</b>
- 1) CLINICAL RESULTS.....	33
<i>a-Subjective results</i> .....	33
<i>b-Objective results</i> .....	34
<i>c- functional scores</i> .....	35
<i>d-Comparative analysis</i> .....	36
- 2) RADIOGRAPHIC RESULTS.....	38
- 3) COMPLICATIONS : ACUTE AND CHRONIC .....	42
<b>V- DISCUSSION .....</b>	<b>43</b>
- 1) ULNAR HEAD PROSTHESIS CONCEPT .....	43
- 2) DRUJ IMPLANT ARTHROPLASTIES .....	44
- 3) WHY A PARTIAL ULNAR HEAD REPLACEMENT ?.....	45

- 4) PARTIAL ULNAR HEAD PROSTHESIS .....	45
- 5) INDICATIONS OF ECLYPSE® PROSTHESIS.....	45
- 6) COMPARISONS WITH OTHERS SURGICAL PROCEDURES IN SAME INDICATIONS .....	46
- 7) COMPLICATIONS .....	50
- 8) STUDY’S LIMITATIONS .....	51
<b>VI- CONCLUSION.....</b>	<b>52</b>
<b>VII- BIBLIOGRAPHY .....</b>	<b>54</b>
<b>VIII- FIGURES’ TABLE .....</b>	<b>57</b>
<b>IX- ANNEX.....</b>	<b>61</b>
- 1) ANNEX 1.....	61
- 2) ANNEX 2.....	63
- 3) ANNEX 3.....	64

## I- INTRODUCTION

An intact distal radio ulnar joint (DRUJ) is critical to stability and load transmission during forearm and wrist motion<sup>1'2'3</sup>. Arthrosis of the DRUJ is a common problem that can cause pain, decreased forearm rotation, loss of grip strength and instability. These degenerative changes can be due to idiopathic osteoarthritis, chronic inflammatory diseases (chondrocalcinosis, rheumatoid arthritis), posttraumatic arthrosis or congenital disease (Madelung).

Current treatment options for DRUJ arthritis include complete resection of the ulna head (Darrach procedure)<sup>4'5'6</sup>, partial resection of the proximal joint surface (Bowers)<sup>7'8'9'10'11</sup> with or without soft-tissue interposition and fusion of the distal radius and ulna with creation of a proximal pseudarthrosis (Kapandji-Sauvé)<sup>12'13'14</sup>. However, these procedures fail to restore normal joint anatomy and lead to a lot of complications like decreased grip, decreased range of motion, persistent pain and instability<sup>1'15'16'14'11</sup>.

The most common complication is the « ulna impingement syndrome »<sup>17'18'19'20</sup> : a convergence instability of the stump of the resected ulna toward the metaphysis of the radius. Lees and Scheker (1997)<sup>21</sup> demonstrated that with these surgical techniques, when the action of lifting is performed with forearm in neutral position, the radius converges inevitably toward the ulna stump because of muscles forces. This contact between the two bones produces pain and is more symptomatic in young and active patients.

Furthermore, Stuart and al<sup>2</sup> reported that approximately 20% of the total constraint of the DRUJ is contributed by the articular surface between the radius and the ulna. To reproduce a DRUJ as anatomic as possible, an ulna head replacement seems a good option<sup>19</sup>.

Many implant arthroplasties have been created including Swanson silicone ulna head, the Herbert ceramic head<sup>22'23'</sup>, the uHead endoprosthesis<sup>24'25</sup>, the Aptis DRUJ<sup>26'27</sup>. These prosthesis require a complete excision of the ulna head with extensive surgical dissection which includes releasing all soft tissue attachments of the distal ulna.

Some studies demonstrate that the palmar and dorsal distal ulnar ligaments, ulnocarpal ligaments, extensor carpi ulnaris tendon sheath and the triangular fibrocartilage complex are DRUJ stabilizers<sup>2'28'29'30</sup>.

Eclipse® implant is a partial ulnar head replacement that substitute only the damaged articular surface of distal ulna without disrupting the efficiency of DRUJ stabilizer ligaments.

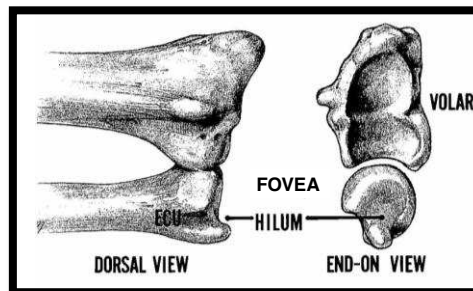
The purpose of this study is to evaluate functional outcome of Eclipse® implantation in 27 patients.

## II- DISTAL RADIOULNAR JOINT ANATOMY AND BIOMECHANIC

### - 1) DRUJ anatomy

#### a- DRUJ articulation :

The distal radioulnar joint is a trochoid articulation between the head of the ulna and the sigmoid notch of the distal radius.

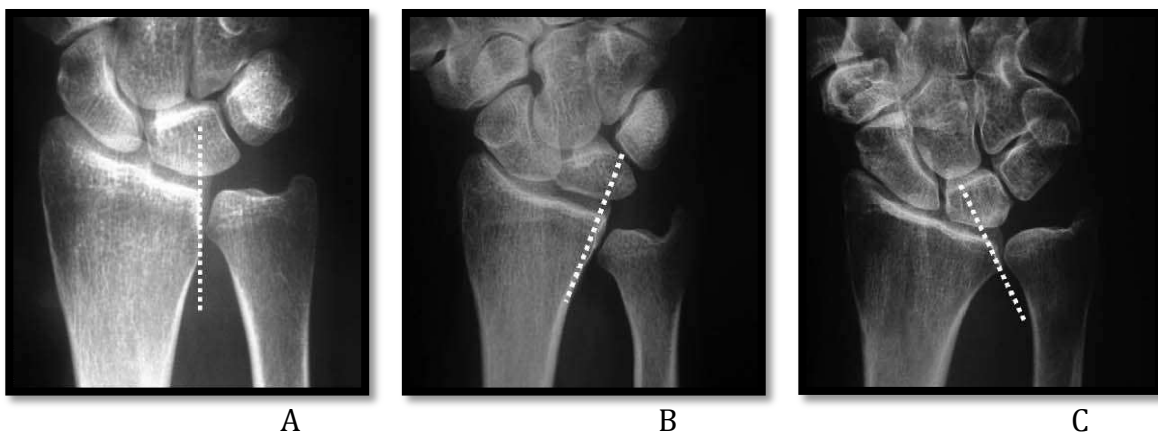


**Figure 1.** DRUJ anatomy with the sigmoid notch of the radius, the articular surface of the ulnar head with the fovea or fossa.

From Diane Coker, 2010

Three main types of DRUJ<sup>31</sup> can be observed in the coronal plane :

- Type I : The apposing joint surfaces were parallel to the long axis of the radius and ulna.
- Type II : The apposing joint surfaces were oblique.
- Type III : The apposing joint surface were set in a « reverse oblique » manner.



**Figure 2.** Three types of distal radioulnar joint in coronal plane :

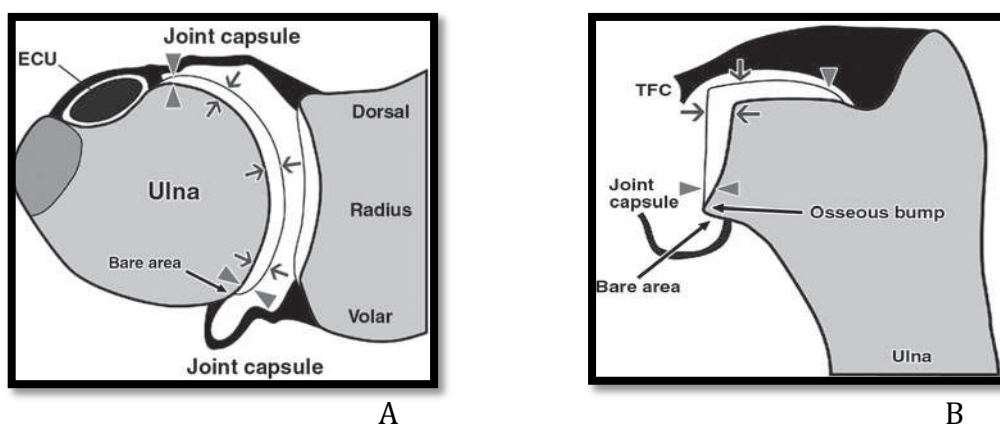
- A, Type I
- B, Type II
- C, Type III

From N.Hollevoet, 2006



Hollevoet and al. <sup>32</sup> observed in 248 wrists without previous trauma or rheumatoid disease that the morphology of the ulnar head was statistically the most significant factor in the development of degenerative changes of the DRUJ. Degenerative changes were more frequent with an oblique sigmoid notch facing proximally (Type II).

The ulna head has a concave articular surface covered with hyaline cartilage with a central height of 8 mm, which diminishes in height dorsally and volarly. It occupies a sector of approximately 150° of the circumference of the ulnar head <sup>33</sup>. The articular surface of the ulna head facing to the triangular fibrocartilage (TFC) is defined as the « pole »<sup>34</sup>. The fovea is the recess lying between the hyaline cartilage of the ulna pole and the ulna styloid. This fossa serves as a point of insertion of the major stabilizing ligamentous components of the TFC<sup>28</sup>.



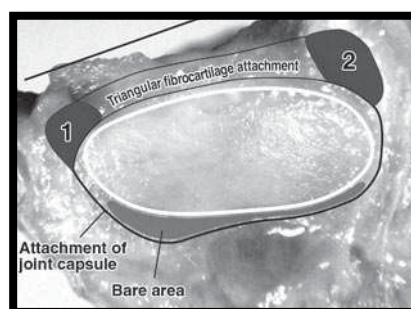
**Figure 3.** Distal radioulnar joint : cartilage thickness in ulnar head and sigmoid notch of the radius and insertion of joint capsule and triangular fibrocartilage (TFC)

**A,** Diagram in axial plane. ECU=extensor carpi ulnaris tendon

**B,** Diagram in coronal plane.

From Florian M. Buck, 2010

The sigmoid notch in the distal aspect of the radius has an oval area of cartilage surrounded by attachment of joint capsule, footprint of volar and dorsal radioulnar ligaments and attachment of TFC<sup>33</sup>.

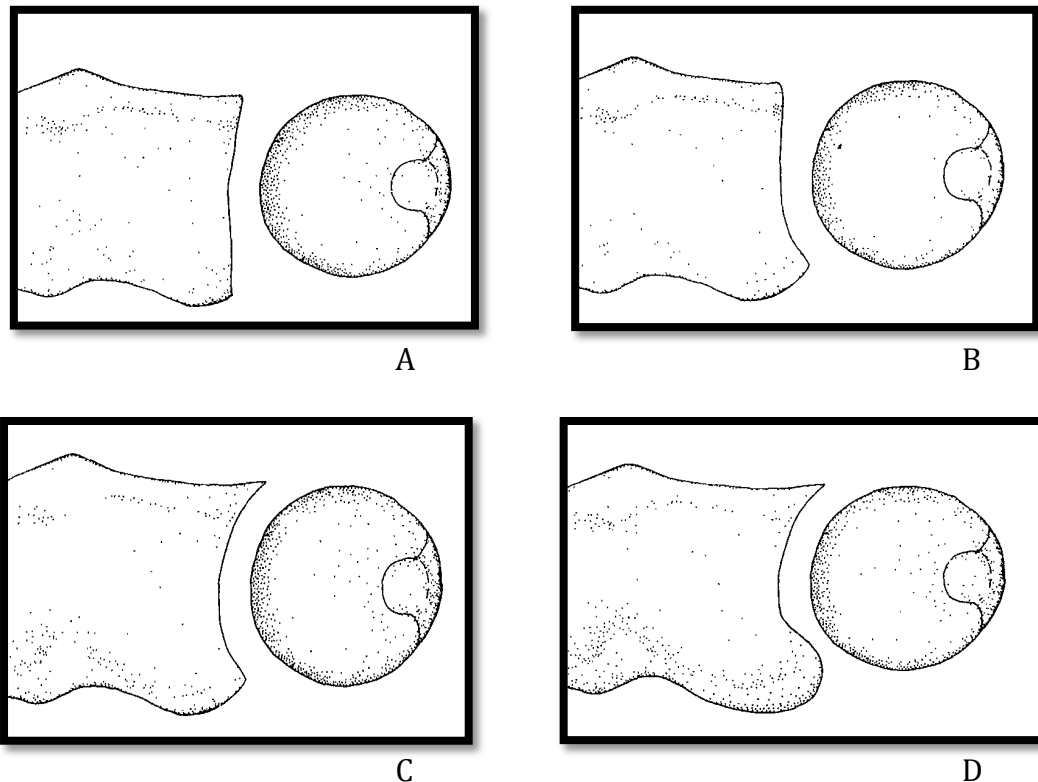


**Figure 4.** Cartilage surface (white line) of sigmoid notch of the radius after removal of ulna head during dissection. Cartilage is surrounded by attachment of joint capsule, volar radioulnar ligament (1), dorsal radioulnar ligament (2) and triangular fibrocartilage.

From Florian M. Buck, 2010

In a cadaveric study, Tolat and al.<sup>31</sup> observed four types of sigmoid notch in the transverse plane view :

- Type A : « Flat face » notch
- Type B : « Ski slope » notch
- Type C : « C » type notch
- Type D : « S » type notch



**Figure 5.** *The different types of sigmoid notch in the transverse plane :*

- A,** *« Flat face » notch*
- B,** *« Ski slope » notch*
- C,** *« C » type notch*
- D,** *« S » type notch*

From A.R. Tolat, 1996

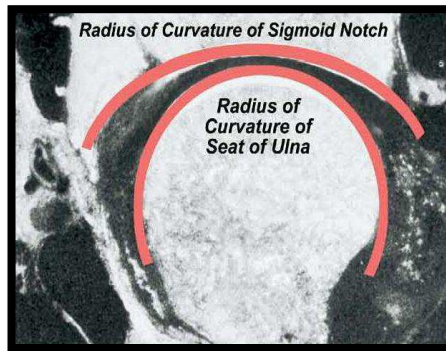
The « Flat face » notch could be considered the least congruous and potentially more unstable notch. In 50 cadaver wrist specimens studied, the type A was seen most commonly (42%)<sup>31</sup>.

The palmar osteocartilaginous lip was noted to be a stable buttress to palmar dislocation of the DRUJ.

The concave curvature of the sigmoid notch is greater than that of the ulna seat<sup>34</sup>.

Tolat and al.<sup>31</sup> observed in cadaveric study that the mean radius of the seat of the sigmoid notch was 19mm and that of the ulnar seat was 10mm, with a significant difference between their radii of curvature.

Therefore, in the transverse plane, the sigmoid notch and the ulna are not congruous.



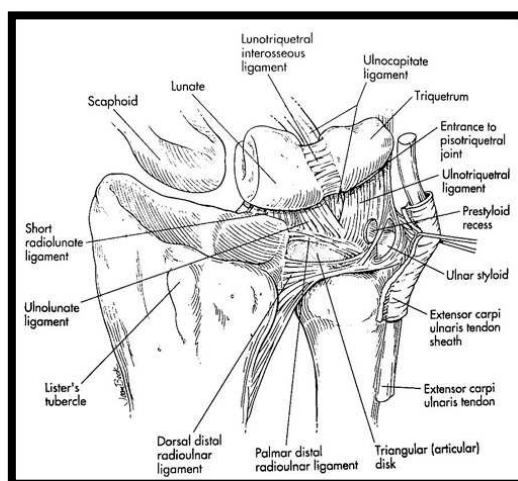
**Figure 6.** Transverse section through the distal radioulnar joint. The radius of curvature of the sigmoid notch is greater than the radius of curvature of the seat of the ulna.

From William B. Kleinman, 2007

### b- DRUJ ligaments :

The ligamentous anatomy about the distal radioulnar joint is quite complex. Palmer and Werner introduced the term of **Triangular Fibrocartilage Complex (TFCC)** to define the ligamentous and cartilaginous structures that suspend the distal radius and ulnar carpus from the distal ulna<sup>35</sup>.

The TFCC includes the dorsal and volar radioulnar ligaments, the ulnar collateral ligament, the meniscus homologue, the articular disc and extensor carpi ulnaris sheath<sup>34/35</sup>. The TFCC arises from the medial border of the distal radius and insert on the ulna at two separate sites : the fovea at the base of the ulna styloid and the ulna styloid itself. Volarly, the TFCC includes the ulnotriquetral ligament and the ulnolunate ligament that attach it strongly to the carpus<sup>28</sup>.

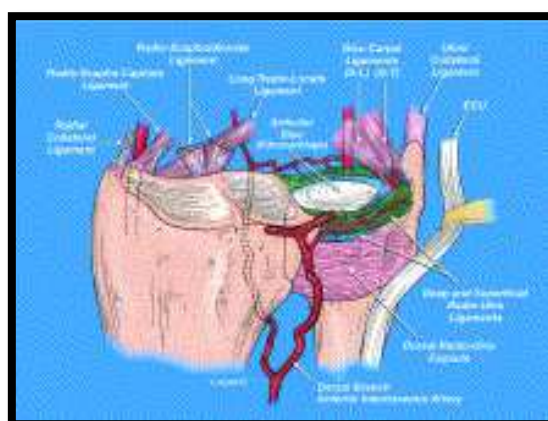


**Figure 7.** The Triangular Fibrocartilage Complex with the volar and dorsal radioulnar ligaments, the articular disc, the extensor carpi ulnaris tendon sheath, the ulnotriquetral ligament and ulnolunate ligament.

From Hung Wai Lam, 2011

The **Triangular Fibrocartilage (TFC)** can be divided into three portions : dorsal, volar and central. The dorsal and volar portions are ligamentous corresponding to the dorsal and volar radioulnar ligaments and the central portion is fibrocartilaginous (articular disc)<sup>28'29</sup>.

The dorsal and volar radioulnar ligaments consist of *superficial* components inserting directly onto the ulna styloid and *deep* components inserting more lateral into the fovea of the ulna. The blood supply to the periphery of the TFC is through dorsal and palmar branches of the posterior interosseous artery nourishing the dorsal 20% and the palmar 20% of the TFC. The articular disc is nourished by synovial fluid<sup>28'34</sup>.



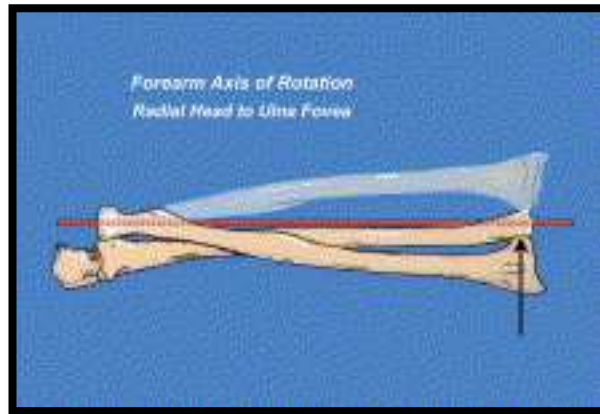
**Figure 8.** The triangular fibrocartilage consists of superficial (green) and deep (blue) radioulnar fibers and the central articular disc (white).

From William B. Kleinman, 2007

## - 2) DRUJ biomechanics

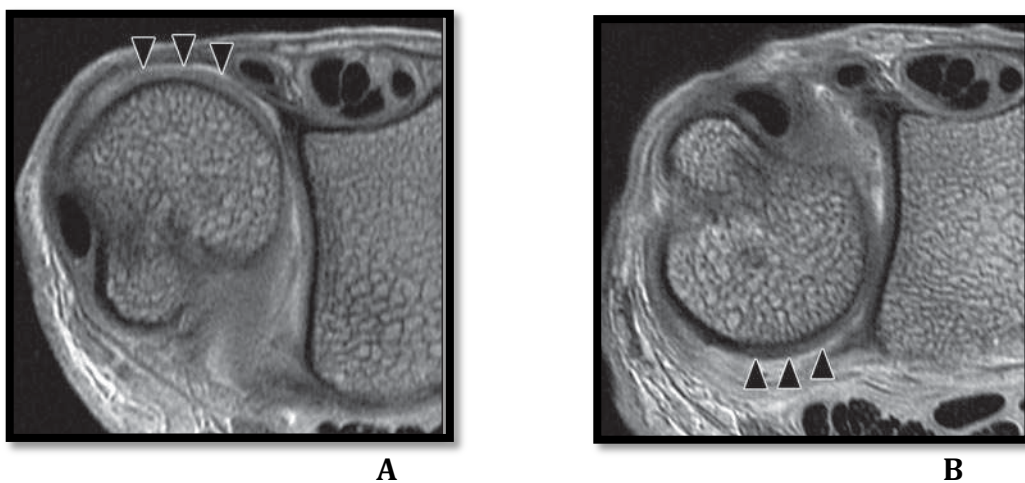
### a- Kinematics :

Forearm pronosupination involves rotation of the radiocarpal unit around a rotationally fixed and stable ulna<sup>35'36</sup>. The longitudinal axis of rotation of the forearm passes through the head of the radius proximally and through the fovea of the ulna distally.



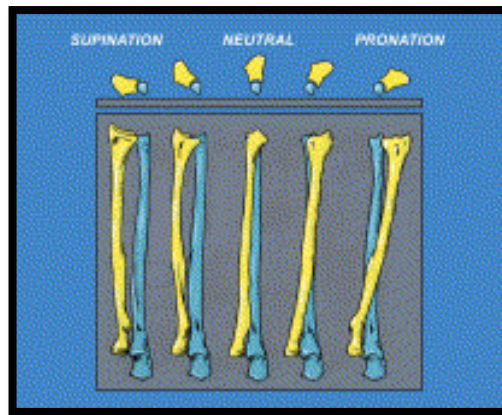
**Figure 9.** *The longitudinal axis of rotation of the forearm.*  
From William B. Kleinman, 2007

But the ulna head is not totally fixed during forearm rotation. Because of the incongruity of articular surface between ulna head and sigmoid notch, the head of the ulna moves slightly dorsally in pronation and toward the palm in supination<sup>34'35</sup>.



**Figure 10.** *Axial IRM images from DRUJ.*  
**A**, in maximal pronation, the ulna head moves dorsally  
**B**, in maximal supination, the ulna head moves toward palmar side  
From Florian M. Buck, 2010

Moreover, the ulna head moves distally in relation to the distal radius in pronation and proximally in supination<sup>34'35</sup>. So the ulnar head glides in the sigmoid notch of the radius from a dorsal distal position in full pronation to a volar proximal position in full supination.



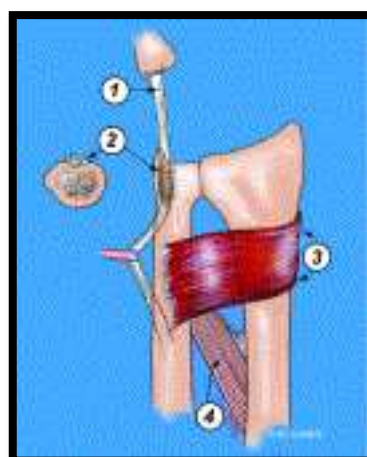
**Figure 11.** As the radius rotates from full supination to full pronation around the ulna, the radioulnar variance changes during motion.

From William B. Kleinman, 2007

For that, the DRUJ appears as a geometrically unconstrained articulation subject to dorsal and palmar instability.

Stability of the DRUJ is so obtained with extrinsic extracapsular and intrinsic intracapsular structures.

Extrinsic stability is provided by tensioning of the extensor carpi ulnaris tendon, the sixth dorsal compartment subsheath, the pronator quadratus and the interosseous membrane<sup>2'30'37</sup>.

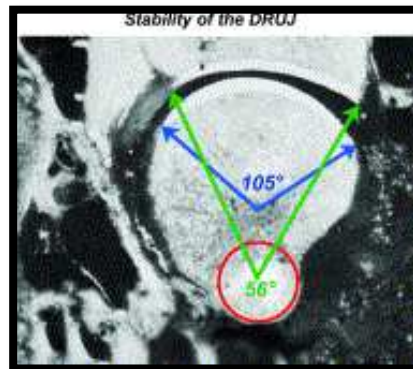


**Figure 12.** Extrinsic stabilizers of the DRUJ include the tendon of the extensor carpi ulnaris (1), the sixth dorsal compartment subsheath (2), the pronator quadratus (3) and the interosseous membrane of the forearm (4).

From William B. Kleinman, 2007

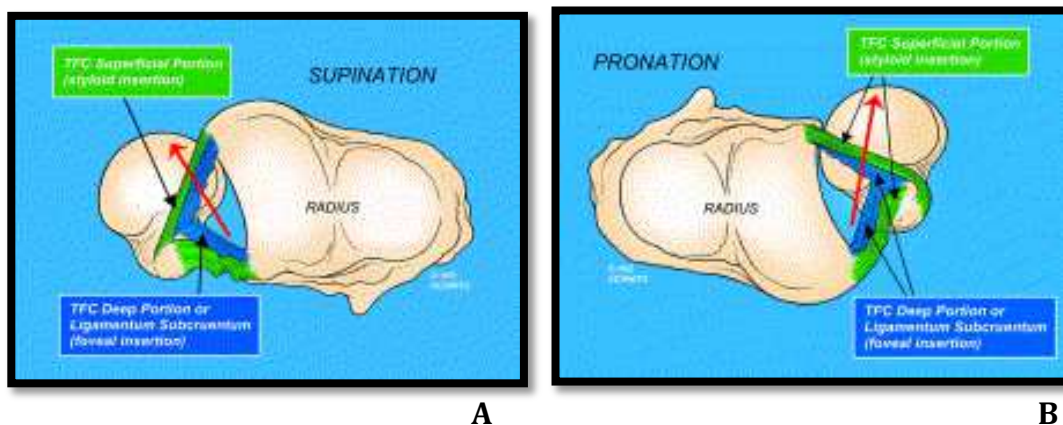
Intrinsic stability is more biomechanically effective than the extrinsic DRUJ stabilizers and is provided by the TFC<sup>35'38'39</sup>.

The dorsal and palmar fibers of the TFC lead to control radioulnar rotation and translation. Because of their obtuse angle-of-attack, the deep dorsal and palmar fibers inserted onto the fovea are more effective in guiding the radius around the ulna during pronosupination than superficial fibers.



**Figure 13.** The angle of attack of the superficial (green) and deep (blue) fibers of the TFC from the medial radius to the fovea is different.

From William B. Kleinman, 2007



**Figure 14.** Role of the superficial (green) and deep (blue) fibers of the TFC in DRUJ stability during motion.

**A,** in supination

**B,** in pronation

From William B. Kleinman, 2007

Tolat and al.<sup>31</sup> suggested that a greater stabilizing role of the radioulnar ligaments might exist when a type A of the sigmoid notch was seen.

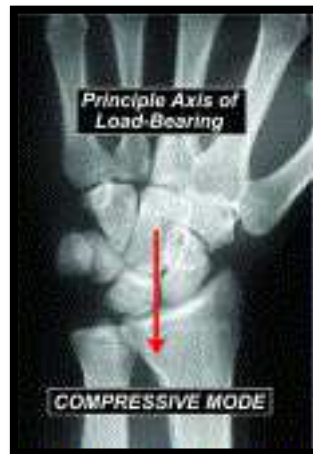Haugstvedt and al.<sup>38</sup> found in a cadaveric study that disruption of the foveal TFCC insertion into the distal ulna can produce instability of the DRUJ.

Kihara and al.<sup>29</sup> found that after sectioning the interosseous membrane, the dorsal radioulnar ligament is more important than palmar in stabilizing the DRUJ in pronation and inversely in supination.

The deep fibers of the TFC seem to be the principal stabilizers of the DRUJ<sup>34'38</sup>.

*b- Kinetics :*

In neutral position, 80% of hand load is transferred to the radius and only 20% is transferred through the central articular disc of the TFC<sup>34'35</sup>.

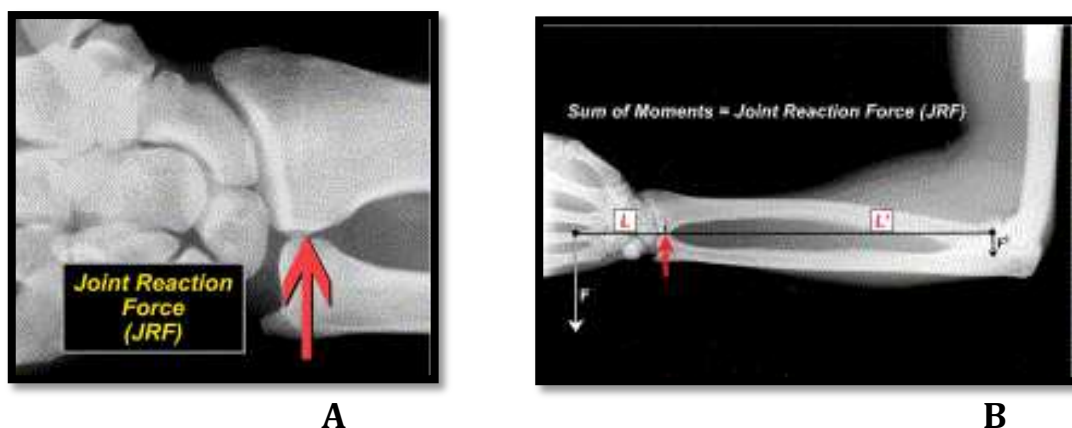


**Figure 15.** In neutral position, the principal axis of load bearing passes through the scapholunate ligament and onto the interfossa ridge of the distal radius.

From William B. Kleinman, 2007

In most upper limb activities in the bipedal human, the radiocarpal unit is rested on top of the ulna seat, with gravity pulling the hand toward the ground. In this position, a significant joint reaction force can develop between the sigmoid notch of the radius and the fixed ulna seat.

In this position, the principal axis of load bearing at the DRUJ is between the center of the sigmoid notch and the center of the seat of the ulna<sup>34</sup>.



**Figure 16.**

**A,** The seat of the ulna is the fulcrum for all distal radioulnar joint mechanics.

**B,** The sum of the moments on the distal and proximal sides of the fulcrum equal the joint reaction force (JRF) at the distal radioulnar joint.

From William B. Kleinman, 2007



The joint reaction force is proportional to the load in the hand, the force of all muscles acting to pull the radius and ulna together and the force of gravity acting on the hand-forearm unit.

The structural presence and health of the articular surface of the ulna seat is critical in providing a painless mechanical fulcrum for all load-bearing activity.

Palmer and al.<sup>35</sup> found that removal of the TFCC decreases the load borne by the distal ulna by approximately 12% and removal of the distal ulna totally unloads the distal ulna.

Shaaban and al.<sup>3</sup> found that the force transmission across the DRUJ is higher in supination than pronation and disruption of a single distal radioulnar ligaments increases force transmission across the DRUJ.

Changes in the forearm wrist unit as excision of the TFCC or excision of the distal ulna could be expected to unphysiologically increase radial loading.

### III- MATERIALS AND METHODS

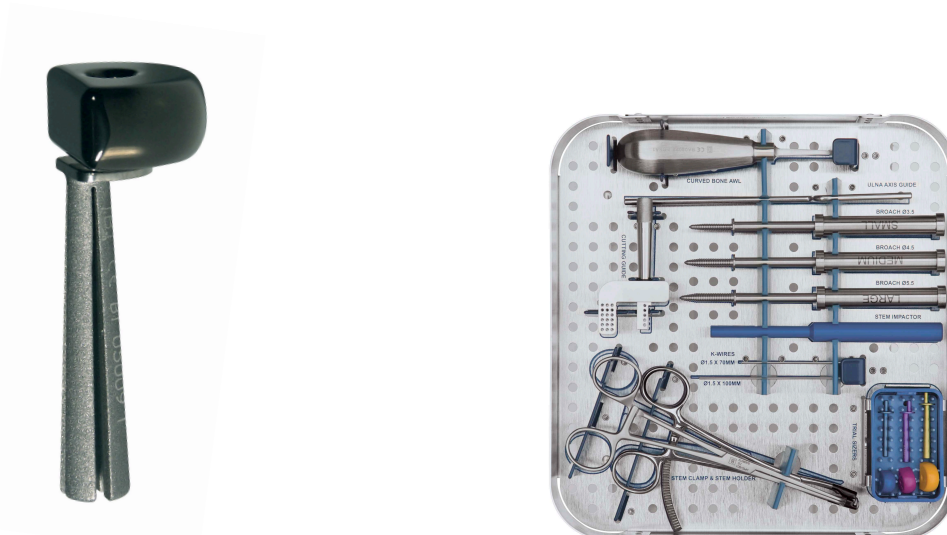#### - 1) The prosthesis

The ulnar head prosthesis used in this study is the Eclipse® implant (Bioprofile, Grenoble, France) that substitute only the articular part of the ulna head.

This partial ulnar head implant consists of a semicylindrical pyrocarbon spacer shaped to imitate the joint surface of distal ulna, with a cylindrical hole in the center. To avoid subluxation of spacer during extreme prono-supination, a titanium stem with four legs is set in the ulna and a distal peg fit into the hole of the spacer. However, the spacer is free to slightly rotate and translate relative to the stem to allow adaptation during motion.

It exists three size of stem : Small (diameter 6 mm ; length 27 mm), Medium (diameter 7,5 mm ; length 30 mm) et Large (diameter 9 mm ; length 33 mm). The height of the head is 8 mm and three size of thickness exists : Small (thick 10 mm), Medium (thick 11,7 mm) and Large (thick 13,2 mm) relative to the diameter of distal ulna portion extracted.

Pyrocarbon has a extremely low friction coefficient able to resist important friction forces during mobility without wear. The elastic modulus of pyrocarbon is similar to the bone one allowing excellent transmission of pressures between bone and implant. Because of the using of this prosthesis in case of destroyed articular surface in DRUJ injuries, this material seems adapted.



**Figure 17.** The Eclipse® prosthesis (Bioprofile, Grenoble, France) and its ancillary.  
From Bioprofile, Grenoble, France

## - 2) Indications and contraindications

Eclipse® indications could be idiopathic osteoarthritis of the DRUJ, posttraumatic osteoarthritis of the DRUJ (distal ulna fracture or malunited Colles' fracture) and ulnar head degeneration secondary to chronic inflammatory diseases (chondrocalcinosis, rheumatoid arthritis)<sup>40'41</sup>. The indications will be analysed and specified in the discussion.

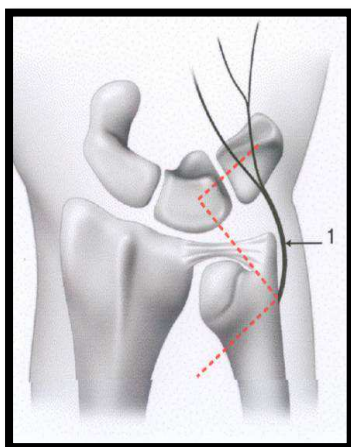
General contraindications for implantation of prosthesis are infection, current or past history of inadequate soft tissues, regional neurologic pain dysfunction and severe axial forearm instability<sup>25'42</sup>.

Partial ulnar head implant is not recommended in patient with a previous Darrach procedure, if there is an important DRUJ instability with severe TFCC insufficiency or if there is a malalignment of the radius requiring corrective osteotomy before implantation<sup>40'41</sup>.

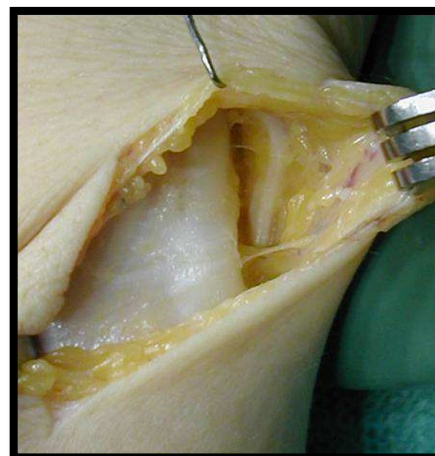
## - 3) Surgical technique

The patient is placed supine on the surgical table. A general or regional anesthesia is used. The elbow need to be exposed to palpate it later. The arm is elevated, exsanguinated and upper-arm tourniquet is inflated.

A dorsoulnar skin incision, curved or Z-shaped, is made centered over the head of the distal ulna. Dorsal cutaneous branches of ulnar nerve are identified and protected.



**A**



**B**

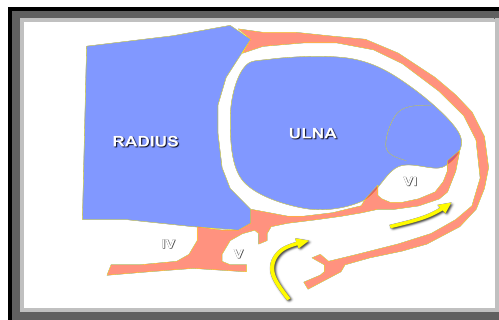
**Figure 18.** Dorsoulnar skin incision centered over the head of the distal ulna with the dorsal branches of the ulnar nerve not far.

**A,** schema representing a Z-shaped incision. 1= dorsal branches of ulnar nerve

**B,** cadaveric dissection bringing to light dorsal branch of ulnar nerve.

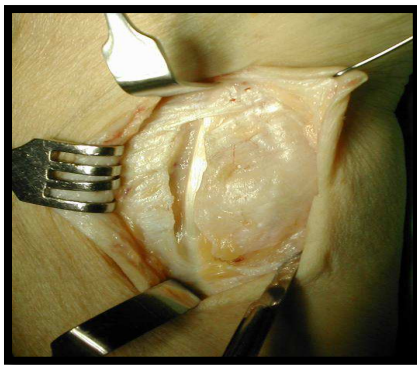
From Marc Garcia-Elias, 2010

The extensor retinaculum is incised between the fifth and the sixth extensor compartment and an ulnar base retinacular flap is elevated taking care not to enter the DRUJ joint and not to open the ECU sheath.

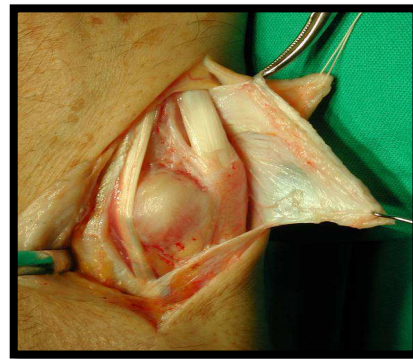


**Figure 19.** Schematic representation of how to enter the subretinacular space between the extensor retinaculum, the DRUJ capsule and the sixth compartment (sheath of the Extensor Carpi Ulnaris, ECU)

From Marc Garcia-Elias, 2007



**A**



**B**

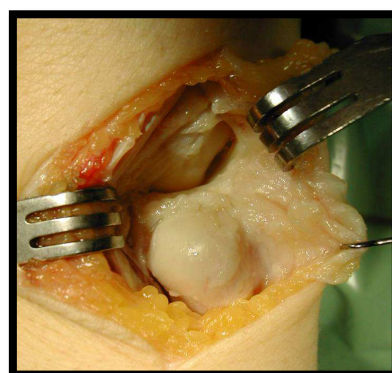
**Figure 20.** Cadaveric dissection.

**A,** Incision of the retinacular ligament.

**B,** Once the retinacular flap is elevated, the ECU tendon and sheath can be observed and checked for its integrity.

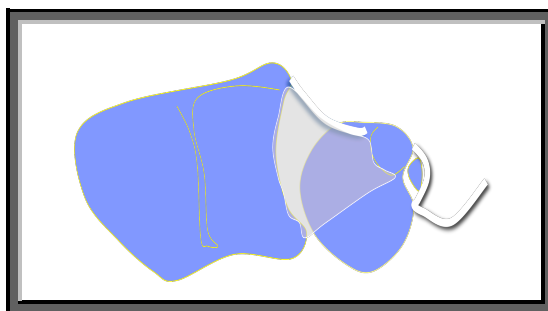
From Marc Garcia-Elias, 2007

An ulnar-based capsular flap is detached off the ulnar edge of the radius preserving the TFCC. The head can be exposed without TFCC detachment in full pronation with dorsal translation force added.



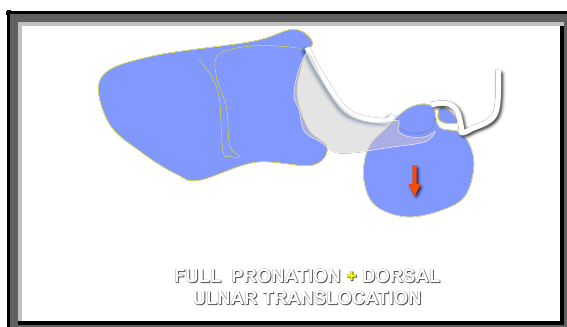
**Figure 21.** Example of the capsular flap being elevated towards the ulna, thus uncovering the dorsal edge of the TFCC.

From Marc Garcia-Elias, 2007



**Figure 22.** Schematic representation of the exposure of the ulnar head : Capsule elevated towards the ulnar side.

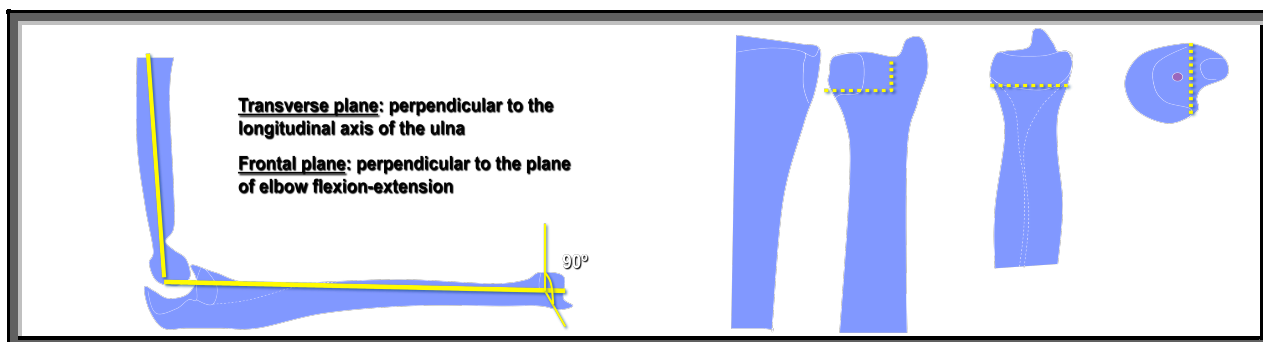
From Garcia-Elias, 2007



**Figure 23.** The forearm is full pronated and by adding some dorsal translation force, the head can be almost subluxed without TFCC detachment.

From Marc Garcia-Elias, 2007

The bone resection needs two osteomies. The proximal osteotomy is perpendicular to the longitudinal axis of the ulna and the length is fitting to proximal end of sigmoid notch of the radius. The second is longitudinal near the fovea adjacent to the styloid process, perpendicular to the plane of flexion-extension of the elbow. An osteotomy guide is used to help the bone resection in neutral position and it's temporarily fixed to the radius with Kirschner wires.



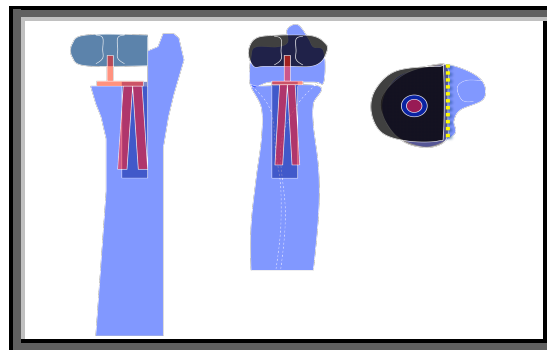
**Figure 24.** Two cuts are necessary:

- a transverse osteotomy of about half the diameter of the ulnar head strictly perpendicular to the longitudinal axis of the ulna.
- a longitudinal osteotomy along the frontal plane, at the level of the fovea by the styloid process perpendicular to the plane of flexion-extension of the elbow.

From Marc Garcia-Elias, 2007

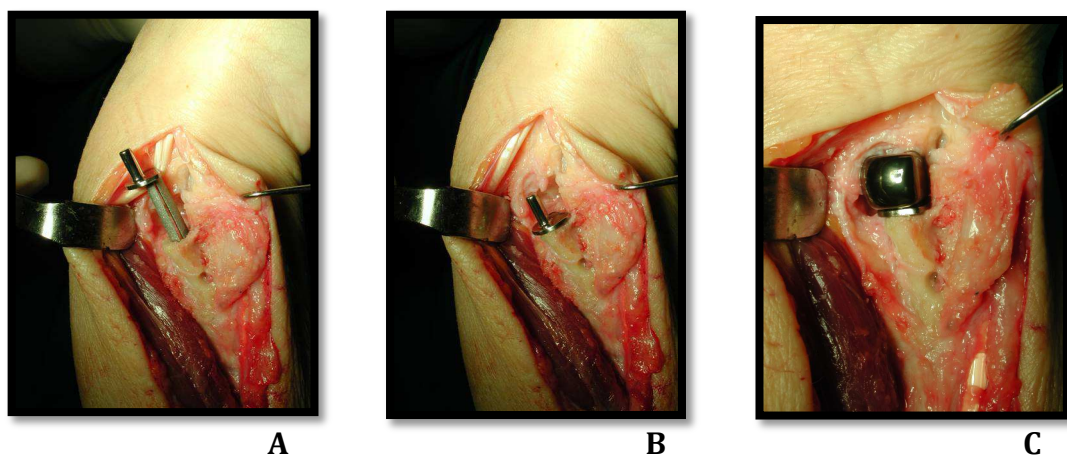
For preparation of stem insertion with press fit, the intramedullary canal of the ulna is reamed with increased-diameter reamers. The entrance point of this instrument is to be set as the basistyloid fovea. When the reamer is tight, the same size stem trial is placed down shaft and trial head is inserted based on the stem. The smaller size of head has to be chosen first. Stability and full mobility have to be checked. Care is taken not to have head more distal than distal radial articular surface. The TFCC should not be under pressure and bone cut has to be adjusted if needed.

To insert the definitive ulna stem, the 4 legs need to be compressed toward the center of the stem with a special clamp. Once fully inserted, the proximal tips of the 4 legs will adopt an expanded position to maximize stability. The stem is introduced with a special orientation clamp to ensure adequate rotation in the hole. The stem has a semicircular plate on which there is a peg for definitive ulnar head insertion. The ulnar head should be able to move easily around the central peg. Stability of the forearm and DRUJ throughout the entire range of motion is checked before closure.



**Figure 25.** Once fully inserted, the proximal tips of the four legs will adopt an expanded position and the adapted size head is inserted on.

From Garcia-Elias, 2007



**Figure 26.**  
A and B, Stem implantation.  
C, Head insertion.

From Marc garcia-Elias, 2007

The capsule is closed suturing it with tissue on the radius with a good grip to get stability and if it's not the case, a soft tissue anchor can be used. The capsule closure has to be done without tension not to limit fully rotation. The extensor retinaculum, subcutaneous tissues and skin are closed over a suction drain.

#### - 4) Postoperative care

After surgery, different wrist immobilisation and rehabilitation procedures were begun depending on assessment of DRUJ stability at the time of surgery and surgeon's preference.

Post-operative recommendations are to keep a splint for 6 weeks to protect the soft tissue repair associated with physiotherapy.

During the first 3-4 weeks, the wrist should not move. Finger exercises and arm elevation were advised.

After 4 weeks, active and active-assisted wrist exercises can be started along with gripping exercises. The presence of pain is a guide to stop the motion during exercises. A protective splint should be worn during rest.

After 6 weeks, use of splint is not necessary. The patient can use his wrist for light daily activities. Wrist movements are improved and strengthening started. Maximal passive pronosupination is allowed.

Contact sport should be avoided for 6 months.

#### - 5) Patient population

This is a retrospective and multicentric study of 27 wrists in 27 patients treated between 2005 and 2010 for painful DRUJ disorders by a partial ulnar head replacement using Eclipse implant (Bioprofile, Grenoble). The average follow-up period has been 30,6 months (range, 12-69 mo). There were 20 women and 7 men with a average age of 61,2 years (range, 27-92 y). Seventeen implants were inserted into the right wrist (63%) and 10 into the left wrist (37%). The dominant extremity was involved in 16 cases (59,2%).

Indications for partial ulnar head replacement were DRUJ arthrosis (20 wrists), inflammatory arthritis (6 wrists) and congenital disease (1 wrist). Among the 20 cases of arthrosis, 13 cases were idiopathic arthrosis and 7 cases were related with trauma. In 6 cases of trauma, a distal radius or ulna fracture was associated. There was 3 patients with rheumatoid arthritis and 3 patients with chondrocalcinosis. Three of these patients had a rupture of the fourth and fifth extensors associated.

Ten patients (37%) had previous surgery on the operated arm including 4 osteosynthesis of distal radius, 1 synovectomy associated with a radioulnar ligamentoplasty, 1 trapezectomy with Pyrocarbon Interposition Implant (PI2, Bioprofile, Grenoble), 1 radial head prosthesis, 1 total elbow prosthesis, 1 wrist arthroscopy and 1 distal radius osteotomy correction.

Eleven patients (40,7%) had an other surgical act during the same operated time including 3 sutures of the fourth and fifth extensors, 2 dorsalisation of the Extensor Carpi Ulnaris sheath which one associated with a synovectomy, 1 carpal tunnel syndrome decompression, 1 lengthening radius osteotomy, 2 trapezectomies with Pyrocarbon Interposition Implant, 1 radial head resection and 1 Scaphoid Trapezium Pyrocarbon Implant (STPi, Bioprofile, Grenoble).

Post-operative wrist immobilisation was chosen by the surgeon depending on DRUJ stability and his preference. A removable wrist splint was applied in 13 patients for 2 to 6 weeks. A removal long-arm splint was applied in neutral position for 3 weeks in 5 patients and in supination for 3 to 4 weeks in 2 patients. A removal static then dynamic above-elbow splint was applied for 3 weeks in 2 patients and 6 weeks in one patient. A long-arm cast in neutral position was applied for 2 to 3 weeks in 3 patients.

Because of the great distance between their place of residence and our hospital, 9 of the 27 patients were reviewed by their surgeon and 1 was interviewed by phone and the measurements were extracted from the last follow-up visit.


## - 6) Assessments

In all patients, pre and post-operative pain was evaluated with a verbal analog pain scale ranging from 0 to 10, 0 being no pain and 10 the worst pain ever imagined by the patient. The Disabilities of the Arm, Shoulder and Hand (DASH) score (annex 1) was used to measure function in individual patients. More the score is low, better are patient abilities to use their arm. Patient satisfaction and return to activities following prosthesis implantation was asked.

Range of motion were recorded on operated and opposite wrists using a goniometer and consisted of extension, flexion, radial deviation, ulnar deviation, pronation and supination. Grip strength was measured in neutral position, pronation and supination using the Jamar Hydraulic Hand Dynamometer. The shoulder was held in adduction and the elbow was held at 90° of flexion. The score of three successive measurements were averaged and recorded as a percentage of the opposite limb.



Weight-bearing ability was evaluated in neutral position, pronation and supination with a specific measuring device (« the Pronosupinator ») lifting different weights of 0.5, 1, 2, 3, 4 and 4.5 kgs. Because of existence of this specific instrument not in every surgical center, this evaluation was made in only 12 patients.



**Figure 27.** Weigh-bearing evaluation with the « pronosupinator »  
A, in pronation.  
B, in supination.

The Mayo wrist score<sup>24</sup> (MWS) (annex 2) applied to conditions affecting the DRUJ was applied to patients after surgery for pain, functional status (return to work), range of forearm motion and grip strength. A score of 90 to 100 was excellent; 80 to 89, good; 65 to 79, fair; and less than 65, poor.

After surgery, the latest radiographs (posteroanterior x-ray and lateral x-ray from neutral alignment) were examined and recorded for signs of loosening of prosthetic stem, proximal osteolysis and bony reactions within the sigmoid fossa.

All patients were screened for common complications following insertion of joint implant.

## - 7) Statistical analysis

Statistical analysis was performed with the SPSS software model 17.0.

For descriptive analysis, quantitative variables were expressed in mean and median with range and qualitative variables in absolute number and percentage.

To assess the significant differences between preoperative and postoperative outcome in pain, a paired *t*-test was performed and *p*-value less than 0.05 was considered significant.

To study association between different variables, several statistical models were used as General Linear Model, Logistic Regression Values, Explore and Univariate Analysis of Variance.

Associations were considered statistically significant for a *p*-value less than 0.05.

## IV- RESULTS

### - 1) Clinical results

#### a-Subjective results

Subjectively, these 27 patients scored **preoperative** pain at a mean of **6,0** (range 3-10) and **postoperative** pain at a mean of **1,7** (range 0-8). The improvement in pain was statistically significant.

Table 1. Comparison of preoperative and postoperative pain score.

Pain	n	Mean (SD)		Median (min, max)		p
		Before Surgery	After Surgery	Before Surgery	After Surgery	
	27	6,0 (1,8)	1,7 (2,3)	6 (3,10)	1 (0,8)	< 0.001

**Twenty four (88,8%)** patients reported having improved pain compared with the preoperative status. **Nineteen (70,3%)** patients had pain relief at rest, **7** had mild pain with activities, but was improved from the preoperative pain level and **3** patients had persistent pain.

**Nineteen (70,4%)** patients were **very satisfied**, **5 (18,5%)** patients were **satisfied**, **1 (3,7%)** patient were **indifferent** and **2 (7,4%)** patients were **dissatisfied**.

**Twenty two (81,5%)** patients didn't required **analgesia anymore**.

**Twenty one (77,8%)** patients returned to their work, hobbies or daily life activities without difficulties.

#### b-Objective results

- Range of motion :

Mean **pronation** in the operated wrist was **83,3°** (range 65-90°) and represented a mean of **99,8%** (range 89-114%) of the opposite side.


Mean **supination** in the operated wrist was **64,0°** (range 0-90°) and represented a mean of **83,6%** (range 0-114%) of the opposite side.

Mean **extension** in the operated wrist was **58,1°** (range 25-85) and represented a mean of **96%** (range 57-155%) of the opposite side.

Mean **flexion** in the operated wrist was **56,4°** (range 20-80°) and represented a mean of **88,3%** (range 29-111%) of the opposite side.

Mean **radial deviation** in the operated wrist was **19,5°** (range 0-35) and represented a mean of **88,8%** (range 0-150%) of the opposite side.

Mean **ulnar deviation** in the operated wrist was **27,8°** (range 5-45) and represented a mean of **80,8%** (range 25-125%) of the opposite side.



**Figure 28.** A 51-year-old woman with Eclypse® implantation on her right hand.

**A**, supination of the both hand.

**B**, pronation of the both hand.

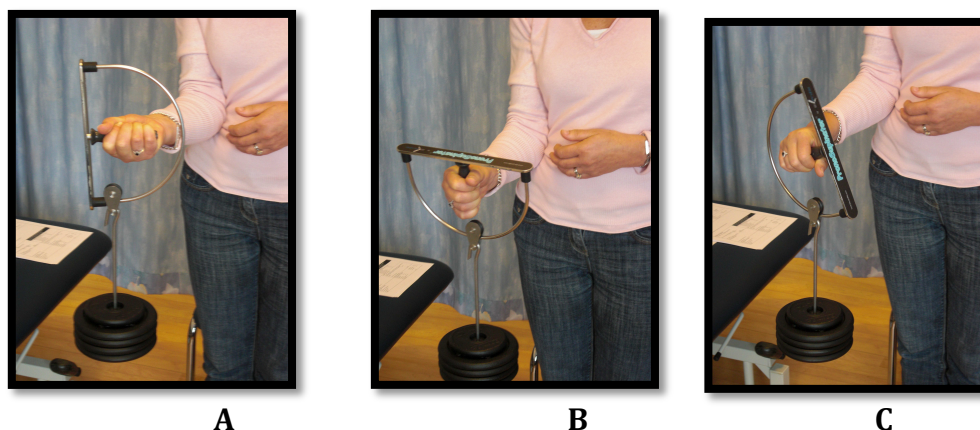
- *Strength* :

**Grip strength** for the operated wrist in **neutral position** was a mean of **14,8 kg** (range 1-46 kg) and represented a mean of **102,3%** (range 25-600%) of the opposite side.

Grip strength for the operated wrist in **supination** was a mean of **14,1 kg** (range 1-42 kg) and represented a mean of **91%** (range 12-200%) of the opposite side.

Grip strength for the operated wrist in **pronation** was a mean of **14,5 kg** (range 1-40 kg) and represented a mean of **104%** (range 6-400%) of the opposite side.

For the twelve patients in which « the pronosupinator » was used, a mean of **3,7 kg** (range 1-5 kg) was born in pronation and supination on the operated wrist.



**Figure 29.** A 51-year-old women using the « pronosupinator » to evaluate her weight-bear capacity of her operated hand.

**A**, in supination.

**B**, in neutral position.

**C**, in pronation.

### c- functional scores

#### - DASH score :

Following implantation of partial radioulnar joint prosthesis, the mean post-operative **DASH score** was **26,3** (range 0-86). The **Median** DASH score was **16**.

#### - Mayo Wrist Score :

**Mean Mayo Wrist Score** post-operative was **76,8** (range 5-95).

Based on this Mayo Wrist Score, there were **11 (44%) excellent**, **5 (20%) good**, **6 (24%) fair** and **3 (12%) poor** results.

In two patients, the Mayo Wrist Score couldn't be calculated because of lack of clinical data.

#### - Stability :

At final follow-up, any case of DRUJ instability was found on the operated wrist after Eclipse® implantation.

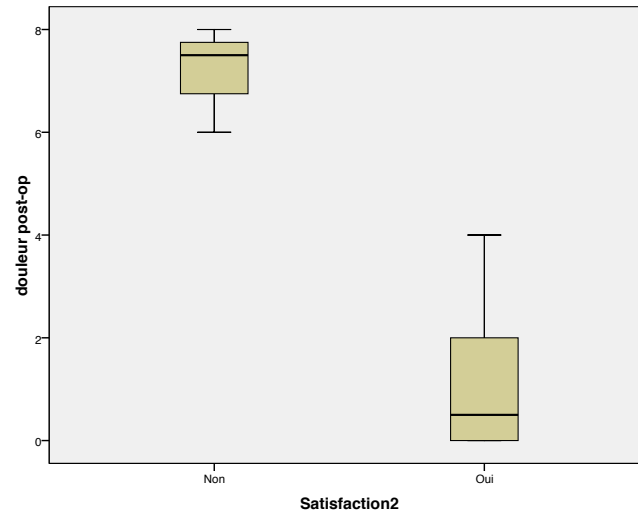
Table 2. Post-operative outcome measures.

Outcome		n	Mean	Median (min, max)
Pronation	Operated side	27	83,3	90 (65,90)
	Comparison with the opposite side, %	21	99,8	100 (89,114)
Supination	Operated side	27	64,0	80 (0,90)
	Comparison with the opposite side, %	21	83,6	94 (0,114)
Flexion	Operated side	27	56,4	60 (20,80)
	Comparison with the opposite side, %	21	88,3	93 (29,111)
Extension	Operated side	27	58,1	60 (25,85)
	Comparison with the opposite side, %	21	96	94 (57,155)
Grip Strength	Operated side	25	14,8	9 (1,46)
	Comparison with the opposite side, %	25	102,3	90 (6-600)
Mayo Wrist Score		25	76,8	85 (5-95)
DASH		25	26,3	16 (0,86)

### d-Comparative analysis

- Patient satisfaction :

The patient satisfaction is correlated with the post-operative pain with a statistical significant result ( $p < 0.001$ ).



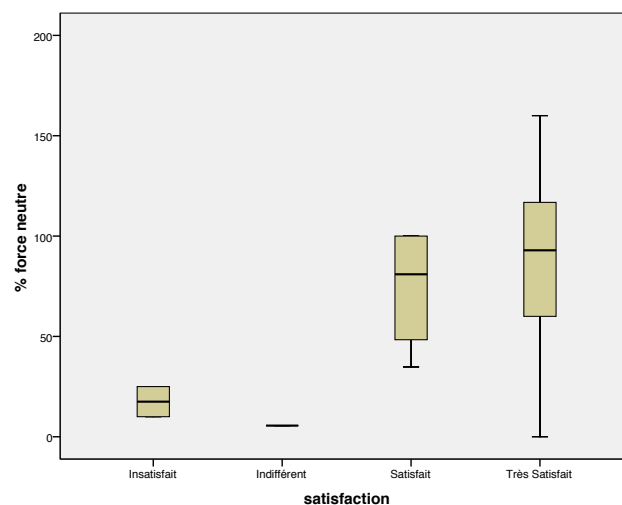
**Figure 30 :** Correlation between postoperative pain and patient satisfaction :

- in ordinate : Pain scale from 0 to 10

- in axis : satisfaction : yes= very satisfied and satisfied

no= indifferent and dissatisfied

The patient satisfaction wasn't correlated with forearm motion and grip strength ( $P > 0.05$ ). However, the patient satisfaction tended to increase with increased grip strength (percentage of operated wrist strength compared to the opposite side) but it was not statistically significant.



**Figure 31 :** Correlation between patient satisfaction and grip strength of operated wrist :

- in ordinate : patient satisfaction

- in axis : % of grip strength of the operated wrist compared to the opposite side

- Etiology :

*Table 3. Postoperative outcome measures according to etiology.*

		Mean of						
	n	pain	Pronation (degrees and % opposite side)	Supination (degrees and % opposite side)	Flexion (degrees and % opposite side)	Extension (degrees and % opposite side)	Strength (kg and % opposite side)	MWS
<b>Inflammatory Diseases</b>	6	0,16	79 (98%)	74 (94%)	63 (103%)	56 (98%)	4,9 (100%)	88
<b>Post- trauma</b>	7	1,2	82,8 (97,2%)	71,4 (83,2%)	67,8 (88,7%)	62,1 (87,6%)	23,1 (89%)	82,1
<b>Idiopathic Arthrosis</b>	13	2,7	85 (100,7%)	60,3 (88,2%)	47,6 (84,6%)	55,5 (102,7%)	13,7 (109,1%)	72

Because of a poor cohort, no comparison between clinical results of different etiologies could be calculated.

- Previous surgery :

There was no significant difference between patients with and without previous surgery for post-operative forearm motion and grip strength.

- Associated surgery :

There was no significant difference between patients with and without associated surgery during Eclipse implantation for post-operative forearm motion and grip strength.

- Length of post-operative immobilisation :

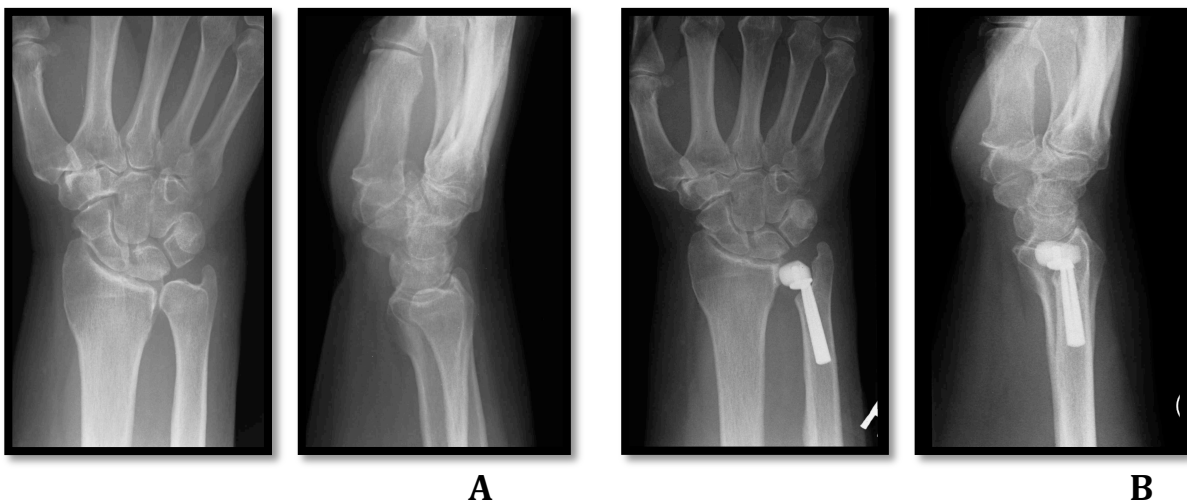
There was no correlation between the length of post-operative wrist immobilisation and the forearm motion at final follow-up.

## - 2) Radiographic results

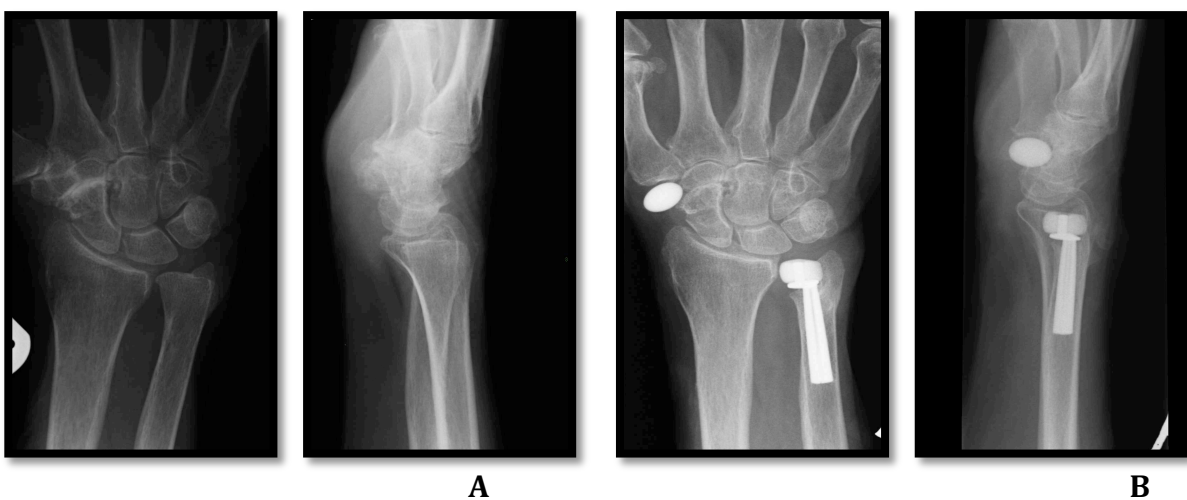Because of the different types of DRUJ described above for each patient, the deformation of the ulna head following fracture or inflammatory disease and the entry point of the stem slightly radial to the fovea to leave intact the TFCC insertion, the stem could appear with a slight distal radial inclination on posteroanterior X-ray.

This distal **radial inclination of the stem** in the ulna diaphysis was present **in 8 cases (33%)**. In this 8 cases, 6 patients were very satisfied with a mean Mayo Wrist Score at 87. However, two patients had poor clinical results with a MWS at 30 and 5.

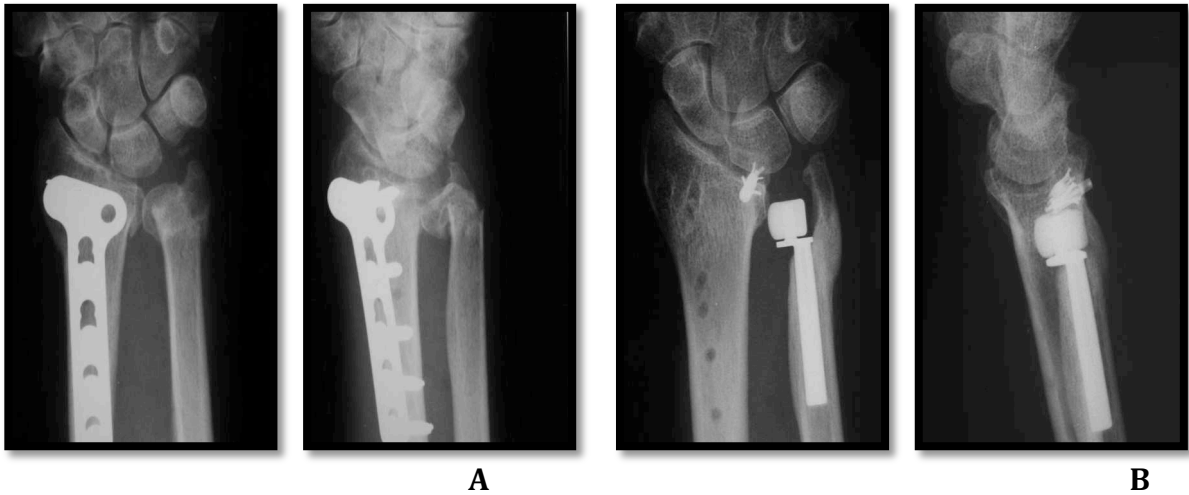
No comparative analysis could be done to research a correlation between this stem inclination and pain, forearm motion and grip strength because of a poor cohort of this study.



**Figure 32.** A 64-year-old man with a painful idiopathic arthrosis of the DRUJ.  
A, preoperative X-rays.  
B, after Eclyspe<sup>®</sup> implantation with a 22 months follow-up.



**Figure 33.** A 80-year-old woman with painful DRUJ arthrosis and scaphotrapezometacarpal arthrosis.  
A, preoperative X-rays.  
B, after Eclyspe<sup>®</sup> implantation, trapezectomy and a pyrocarbon interposition implant (Pi2).



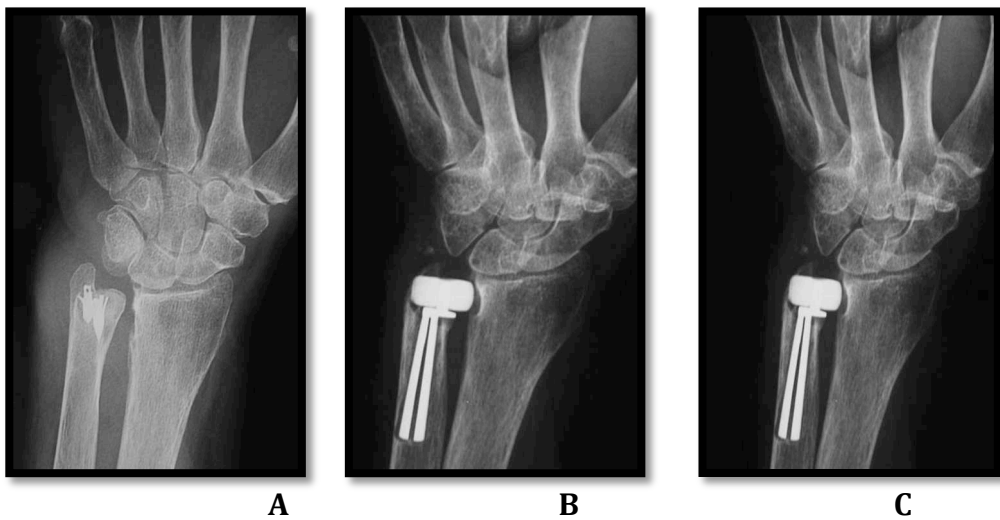
**Figure 34.** A 58-year-old woman with distal radius and ulna fractures.

**A**, distal radius osteosynthesis in emergency, after 6 months the pronosupination was 0°.

**B**, X-rays after 9 months following Eclyspe® implantation. At final follow-up, she had 75° of pronation and 80° of supination.

On post-operative X-rays, signs of **remodeling of the sigmoid fossa** were present in **9 (37%) patients**. There was no significant difference between patients with and without remodeling of the sigmoid notch for post-operative pain at the final follow-up.

Correlation between this remodeling of the sigmoid fossa and the forearm motion couldn't be analysed.



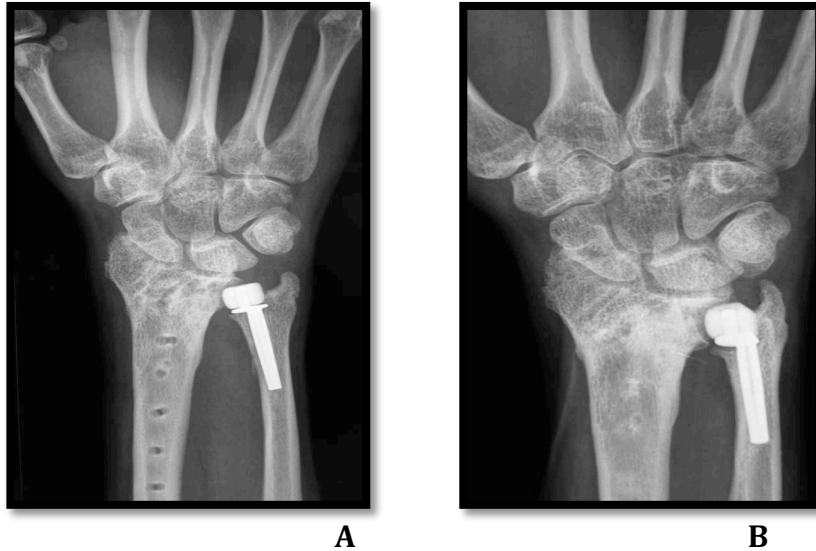**Figure 35.** A 67-year-old man with painful DRUJ because of rheumatoid arthritis with synovectomy and ECU dorsalisatio as previous surgery.

**A**, preoperative X-rays

**B**, signs of remodeling of the sigmoid notch at 3 months follow-up.

**C**, No evolution of the remodeling of the sigmoid notch at 6 months follow-up.

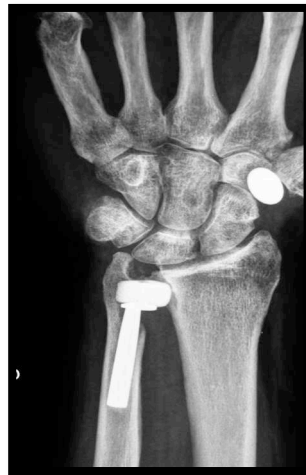



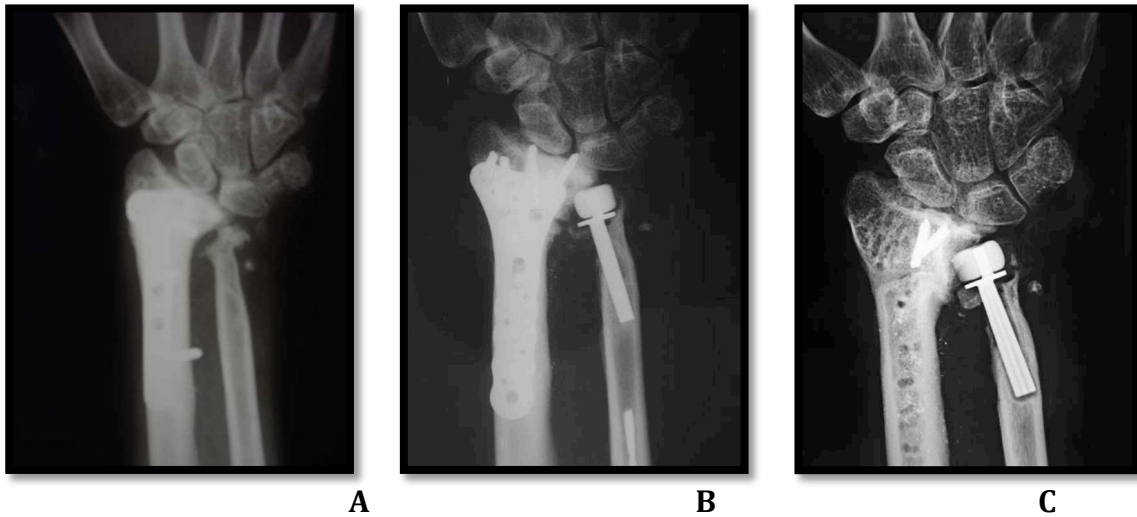
**Figure 36.** A 27-year-old man with a distal radius fracture in 2007 and any supination after osteosynthesis. A distal radius osteotomy correction was made in 2009 but the DRUJ was still painful. A Eclipse® prosthesis was implanted 1 year after. Signs of remodeling of the sigmoid notch were visible

**A**, on 1 month X-ray follow-up  
**B**, on 22 months X-ray follow-up

**Ten (41%)** of 25 wrists had a **slight bone resorption** beneath the collar of the stem. No comparative analysis could be calculated between this bone resorption and pain and forearm motion of the patient.



**Figure 37.** A 61-year-old man with Eclipse® implantation for painful DRUJ idiopathic arthrosis. After 20 months follow-up, a slight bone resorption was visible beneath the collar of the stem.



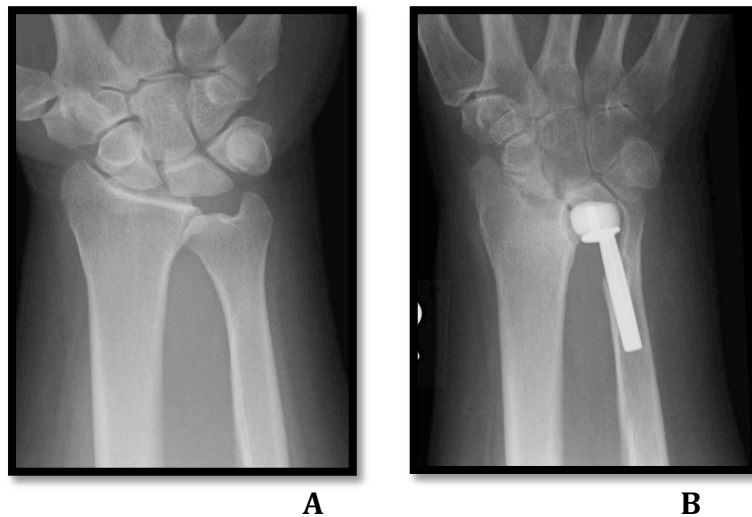
**Figure 38.** A 37-year-old man with distal radius and ulna fractures. One year after the first osteosynthesis, an additional radial osteotomy was made associated with Eclipse® implantation. He returned to previous work 6 months after second surgery.

**A,** one year after the first osteosynthesis.

**B,** one month after radius osteotomy and Eclipse® implantation.

**C,** slight bone resorption was visible beneath the collar of the stem after 24 months follow-up.

A prosthetic distal migration of the stem was evidence in one patient with TFCC and carpal compression. No revision was made at the final follow-up.



**Figure 39.** A 52-year-old woman with painful DRUJ arthrosis.

**A,** X-ray before surgery

**B,** After 12 months follow-up, she had important DRUJ pain with limited range of motion.

For three patients, post-operative X-rays couldn't be recovered.

### - 3) Complications : acute and chronic

Tree patients had complications, 1 early and 2 late.

One patient had a superficial wound infection that resolved with antibiotic treatment and regular dressing.

One patient had a revision 22 months after the first Eclipse® distal ulna implantation. The patient had an important limitation of motion and painfull operated wrist. During revision, a persistent volar bone portion on distal ulna was found preventing rotation and correct prosthesis position. After Eclipse® removed, volar bone on distal ulna was removed and the entry point of the stem was adjusted. There were no signs of infection and the previous prosthesis was reinserted. Full forearm rotation was obtained during second surgery.

At final follow-up X-ray, one patient had a distal migration of the Eclipse® prosthesis with carpal compression. The patient was very painfull and limited in motion. No revision was made at the final follow-up.

## V- DISCUSSION

### - 1) Ulnar head prosthesis concept

The rationale for development of an ulnar head replacement is based upon the fixed point concept defined by Hagert<sup>36'43</sup> in which the ulnar head is the fixed point. The ulnar head is immobile and the load-bearing part of the wrist<sup>44</sup>. The distal radioulnar joint is known to carry nearly 20% of the axial load of the forearm<sup>2'35</sup>.

Traditional treatment of distal radioulnar arthritis has used nonanatomic procedures as ulna head resection (Darrach procedure)<sup>4'5'6</sup>, hemiresection interposition arthroplasty (Bowers)<sup>7'8'9'10'11</sup> and fusion of the distal radius and ulna with creation of a proximal pseudarthrosis (Kapandji-Sauvé)<sup>12'13'14</sup>. However, these procedures lead to a lot of complications like decreased grip, decreased range of motion and instability<sup>1'11'14'15'16</sup>. The most common complication is the « ulna impingement syndrome »<sup>17'18'19'20</sup> or « convergent instability » demonstrated by Lees and Scheker<sup>21</sup>. Although decrease of pain at the DRUJ may be obtained simply resecting the distal ulna, the problem is disruption of the stability of the entire forearm.

If the radioulnar joint has been injured, only a procedure restoring the DRUJ anatomy as an ulnar head replacement can offer a stable, pain-free and mobile joint. Cadaveric laboratory studies have shown that replacement of the distal ulna head with a implant can effectively prevent radioulnar convergence, maintain the kinematic relationship between the radius and ulna during the forearm rotation and can lead to load transmission in the wrist and forearm<sup>19'45</sup>.

### - 2) DRUJ implant arthroplasties

A lot of different distal radioulnar joint prosthesis were created.

Some of them tend to replace both radius articular surface and ulna head<sup>26'27'46</sup>. One of these prosthesis, the APTIS DRUJ prosthesis (Aptis Medical, Louisville, KY, USA) is quite complex with several components and need a relative invasive surgical technique for implantation<sup>26'27</sup>.

Based on the concept of the first ulnar head in silicone described by Swanson<sup>47'48</sup>, a lot of ulnar head prosthesis were created : the Herbert Ulnar Head prosthesis (Hand Innovations, Miami, FL)<sup>47'48</sup> which is a metallic endoprosthesis and ceramic ulnar head, Avanta U-head prosthesis (Small Bone Innovations, LLC, New York, NY)<sup>24'25'48</sup> which is a cobalt-chrome alloy ulnar head prosthesis, the E-centrix (Wright Medical Technology, Arlington, Tenn)<sup>49</sup> and the First Choice DRUJ system : modular ulnar head (Ascencion Orthopedics, Austin, TX)<sup>50</sup>. Some authors discuss the indications and contraindications for ulnar head replacement and detail the surgical technique and rehabilitation<sup>25'47'49'50</sup>.

Few preliminary clinical reports using different ulnar head prostheses for painful disorders of the DRUJ have been encouraging.

In 2007, Willis et al.<sup>24</sup> used in 19 wrists the Avanta U-head prosthesis (Small Bone Innovations, LLC, New York, NY) to treat painful disorders of the DRUJ. Although the principal indication for total head replacement is a failed resection of the distal ulna, the authors extended ulnar head prosthesis indications to a primary procedure in patients with arthritic changes at the DRUJ. After 2 years of follow-up, patients demonstrated decreased pain, improved grip strength and functional satisfaction scores. Forearm rotation was unchanged.

In 2009, Van Schoonhoven et al.<sup>51</sup> reported on 16 patients treated with the Herbert Ulnar Head prosthesis (Hand Innovations, Miami, FL) combined with a soft tissue repair as a salvage procedure after distal ulna resection. After more than 10 years follow-up, all patients demonstrated a clinically stable DRUJ and improvement in pain scores, satisfaction scores, forearm motion and grip strength.

In 2009, Shipley et al.<sup>48</sup> reported on 20 patients (22 wrists) with painful arthrosis or instability of the DRUJ treated with either Herbert-Martin (Martin Medizin-Technik, Tuttlingen, Germany) or Avanta (Small Bone Innovations, New York, NY) head prosthesis. With an average of 4 years follow-up, they reported significant improvement in pain scores and satisfaction scores.

Total ulnar head prosthesis is initially proposed for treatment in cases of ulnar instability after resection of the distal ulna<sup>51</sup>. Then, indications are extended to primary treatment such as rheumatoid arthritis, osteoarthritis of the DRUJ (posttraumatic, primary), congenital deformity and tumor<sup>24'41'46'47'48'49'50</sup>.

### - 3) Why a partial ulnar head replacement ?

One of the disadvantages of a complete head replacement is the relatively extensive surgical dissection detaching all soft tissue attachments to the distal ulna. Some cadaveric studies have shown the important role of ligaments in DRUJ stability such as palmar and dorsal distal ulnar ligaments, ulnocarpal ligaments, Extensor Carpi Ulnaris tendon sheath and the triangular fibrocartilage complex<sup>2'28'29'30</sup>.

Haugstvedt and al.<sup>38</sup> found in a cadaveric study that disruption of the foveal TFCC insertion into the distal ulna can produce instability of the DRUJ.

Kihara and al.<sup>29</sup> found that after sectioning the interosseous membrane the dorsal radioulnar ligament is more important than palmar in stabilizing the DRUJ in pronation and inversely in supination.

Moreover, Willis et al.<sup>24</sup> and Van Schoonhoven et al.<sup>51</sup> insisted on the great role of soft tissue repair to the head of the prosthesis which added DRUJ stability.

Conaway et al.<sup>41</sup> demonstrated that a partial ulnar head implant can closely recreate the ulnar head anatomy.

A partial ulnar head replacement requires a minimal bone resection preserving the attachments of the stabilizing ligaments and maintaining anatomy and stability<sup>41'50</sup>.

#### - 4) Partial ulnar head prosthesis

More recently, Kopylov et al.<sup>50</sup> recommended a partial resurfacing implant for DRUJ in primary procedures. The partial ulnar head replacement proposed (First Choice DRUJ System, Ascension Orthopedics, Austin, TX) is a chrome-cobalt alloy prosthesis composed by a stem and a partial head in one component. Only ten patients were reported to be operated with implantation of this prosthesis with 6 months of follow-up. The indications were 7 osteoarthritis and 3 posttraumatic arthritis.

This 10 case-reports are presented to have decreased pain and improvement of pronation and supination but any clinical study of this prosthesis exists.

Eclipse® prosthesis is the other one partial ulnar head implant. The semicylindrical pyrocarbon spacer shaped to imitate the joint surface of distal ulna is free to rotate and translate relative to the stem during motion. There is no pressure exerted on the stem that could lead to a diaphysis ulna fracture. Pyrocarbon is a well tolerated material and any case of allergy is reported. The Eclipse® implantation is reproducible as more than five different surgeons have implanted it in this study.

#### - 5) Indications of Eclipse® prosthesis

Eclipse® prosthesis may have good primary indications in painful DRUJ related to rheumatoid arthritis, chondrocalcinosis, posttraumatic or idiopathic arthritis<sup>40</sup> and congenital disease.

In inflammatory diseases, patients seemed to have a postoperative lower pain score and a better Mayo Wrist Score. The both wrists were affected by the disease that's why after Eclipse® implantation the operated wrist began the better one.

In this study, clinical results seemed to be good for each indication with maintaining of forearm motion and grip strength, limited pain and a good Mayo Wrist Score. But the cohort is poor and any clinical results comparison could be done between different indications.

Because of Eclipse® prosthesis is only a partial ulnar head prosthesis, it cannot be used in cases of a salvage procedure after distal ulna resection<sup>40/50</sup>. But in case of partial head implant failure, a conversion to a total head replacement or a partial head resection is an available option.

- 6) Comparisons with others surgical procedures in same indications

- Darrach : clinical results

Even though the ulnar head resection is known to lead to serious complications quoted above, the Darrach procedure is still used in DRUJ injuries because of its simplicity of execution and its low cost.

In 1993, Field et al.<sup>53</sup> reported 36 patients with an average of 52 years who had undergone Darrach procedure following a radius or ulna fracture. After a mean follow-up of 6 years, persistent **pain** was present in **31 cases** and 22 patients complained of pain on pronation and supination. **Twenty-seven** patients complained a **weak grip** and **wrist stiffness** and a **clicking sensation** were present in **16 cases**. The **total movement** was **reduced by 16%** in the operated wrist and 29 (**80%**) patients had a significantly **reduced grip strength**. Wrist **deformity** was present in **15 patients**. Only 16 patients were satisfied and 15 patients had one or more features of algodystrophy.

In 2004, George et al.<sup>5</sup> reported 21 patients less than 50 years of age who had undergone the Darrach procedure for symptomatic DRUJ following fractures of the distal radius. Only 13 patients were available for clinical evaluation. After an average follow-up period of 4 years, the mean **flexion** was **52°**, the mean **extension** was **58°**, the mean **pronation** was **80°** and the mean **supination** was **77°**. The mean **grip strength** was **82% of unaffected side**. The mean **Modified Mayo Wrist Score** was **72** and the mean **DASH score** was **23**. Three patients had **pain at the ulnar stump** and one patient had an **ulnar carpal translation**.

In 2009, De Witte et al.<sup>52</sup> reported 26 patients with a mean age of 53 years who had the Darrach procedure for symptomatic DRUJ following trauma. At an average follow-up of 21 months, they found a improvement in total arc forearm rotation from a average of 49° to an average of **136°**. However, 7 patients had **occasional or continous pain** after surgery.

In 2009, Mansat et al.<sup>4</sup> reported 20 patients with an average age of 45 years had undergone the Darrach procedure for symptomatic DRUJ following a distal radius fracture. After an average follow-up of 11 years, mean pain score decreased from **2,2 to 0,5**. Range of motion improved in **supination from 37° to 80°**, in **pronation from 66° to 84°**, in **flexion from 41° to 57°** and in **extension from 40° to 63°**. The mean **grip strength** was **80,8%** of the opposite side. The satisfaction rate was 95%. However, in this study the surgical technique was modified. A minimal ulna head resection was done associated with dorsalisation of the extensor carpi ulnaris.

### - Hemiresection interposition arthroplasty : clinical results

The concept of the Eclipse® prosthesis is to replace only the distal ulnar articular surface opposite the sigmoid notch without excision of DRUJ ligaments to treat painful DRUJ injuries.

The hemiresection interposition arthroplasty (HRIA) has the same concept to do a partial resection of the distal ulna joint surface with interposition of soft tissue.

In 1995, Bain et al.<sup>54</sup> reported 49 patients treated with an HRIA for rheumatoid arthritis or post traumatic DRUJ arthrosis with a follow-up of 36 months. They found an improvement of pain with a postoperative average **pain of 5,4**, an average postoperative **pronation of 72°** and **supination of 72°**. But **9** patients had an **ulnar-carpal impaction**, **16** patients had **discomfort** at the extremes of rotation and **19** had **discomfort with compression** of the DRUJ.

In 1999, Schober and al.<sup>7</sup> reported 24 patients treated with an HRIA for post-traumatic DRUJ arthrosis. They found a mean **pronation of 80°**, mean **supination of 62°** and a mean **grip strength of 57%** compare to the opposite side. But **10** patients developed a postoperative **instability** of the distal ulna.

In 2003, Van Schoonhoven et al.<sup>9</sup> reported 36 patients treated with an HRIA for DRUJ arthrosis with a follow-up of 36 months. The average postoperative **pain was 3,9**. The average **pronation was 76°**, average **supination was 69°** and the average **grip strength was 64%** of the opposite side. The mean **DASH score** was **35**. But **21** patients had **radioulnar impingement** with pain in 14 patients that required a **revision surgery** in **5 cases** (ulnar head prosthesis). **Three** patients had a **ulnar-carpal impaction** requiring a revision surgery (ulnar head resection).

The HRIA improves the range of forearm rotation and grip strength. But complications are common as instability of the distal ulna with radioulnar impingement or ulnar-carpal impaction lead to pain<sup>13'15</sup>. Continuous repetitive compression of the soft tissue interposition after HRIA would explain progressive wear and mechanical failure of the scare tissue leading to radioulnar impingement<sup>15'16</sup>.

### - Total ulnar head prosthesis : clinical results

In 2006, Mueller et al.<sup>55</sup> reported 14 patients with an ulnar head implantation following DRUJ failed procedures in 5 cases and in primary indications in 9 cases with a follow-up of 14 months. The average **grip strength was 75%** of the opposite side, pronation-supination was **141° (78%** of the opposite side) and the average **DASH score** was **15**.



In 2007, Willis et al.<sup>24</sup> reported 19 ulnar head prosthesis implantations for instability after resection of ulna head (6 cases), DRUJ arthrosis (11 cases) and inflammatory arthritis (2 cases). After a average follow-up of 32 months, the mean pain was **1,8**. Forearm motion was improved with a mean **pronation at 71°**, a mean **supination at 60°** and a mean **rotation arc at 131°**. The mean **grip strength** was **73%** of the opposite side and the mean **Mayo Wrist Score** was **77**.

In 2009, Shipley et al.<sup>48</sup> reported 22 ulnar head prosthesis implantations following failed procedures (12 cases) and as a primary procedure (10 cases) for DRUJ dysfunction. After a mean follow-up of 54 months, the average postoperative **pain score** was **1,3** and the average modified **Mayo Wrist Score** was **72,7**. In their modified Mayo Wrist Score, they decreased the score for « excellent » result at 80-100 points and the score for « good » result at 65-79 points. Two patients had a **symptomatic dorsal instability** requiring revision.

#### - Partial ulnar head prosthesis

In 2007, Kopylov et al.<sup>50</sup> presented a partial resurfacing implant (First Choice DRUJ, Ascension Orthopedics, Austin, TX) to be used in primary procedure in DRUJ injuries.

Any clinical study was published on this prosthesis.

#### - Eclipse® prosthesis :

Compare with clinical results after the Darrach procedure, wrist range of motion after Eclipse® implantation was similar. However, mean grip strength, DASH score and Mayo Wrist Score seemed to be better.

Compare with clinical results after the HRIA procedure, postoperative wrist and forearm motion were relatively similar. However, mean grip strength, pain improvement and mean DASH score seemed to be better.

Compare with clinical results after the total ulnar head prosthesis implantation, postoperative wrist and forearm motion as well as pain improvement, mean DASH score and Mayo Wrist Score were similar. But grip strength seemed to be better.

Eclipse® prosthesis maintained DRUJ stability because any cases of DRUJ instability were found on operated wrist at final follow-up.

The follow-up clinical results seemed not to be influenced by previous surgery and associated surgery with Eclipse® implantation on the same wrist.

Patient satisfaction was correlated with improvement of pain but not necessary with forearm motion or grip strength. In this study, **88%** of patients were satisfied and very satisfied.

Table 4. Clinical results of different procedures for DRUJ disorders

Authors	Procedures	Follow-up, mo	Number of cases	Postoperative Pain	Mobility In degrees	Grip strength % of opposite side	Functional scores	Complications
<b>Field 1993</b>	Darrach	72	36	86% cases with persistent pain	↓ 16% of ROM	↓ in 80% of cases		15 : wrist deformity 27 : wrist stiffness 16 : clicking sensation
<b>George 2004</b>	Darrach	48	13		F/E : 52/58 P/S : 80/77	82%	MWS : 72 DASH : 23	3 : pain ulnar stump 1 : ulnar carpal translation
<b>De Witte 2009</b>	Darrach	21	26	7 patients with pain	F/E : 136			
<b>Mansat 2009</b>	Darrach	132	20	0,5	F/E : 57/63 P/S : 84/80	80%		None
<b>Bain 1995</b>	HRIA	36	49	5,4	P/S : 72/72			9 : ulnar carpal impaction 16 : discomfort with rotation 19 : discomfort with compression
<b>Schober 1999</b>	HRIA		24		P/S : 80/62	57%		10 : instability
<b>Van Schoonhoven 2003</b>	HRIA	36	36	3,9	P/S : 76/69	64%	DASH : 35	21 : radioulnar impingement 3 : ulnar carpal impaction 5 : revision
<b>Mueller 2006</b>	TUHP	14	14		P/S : 141	75%	DASH : 15	
<b>Willis 2007</b>	TUHP	32	19	1,8	F/E : 131 P/S : 71/60	73%	MWS : 77	
<b>Shipley 2009</b>	TUHP	54	22	1,3			MWS : 72	2 : dorsal instability
<b>Eclipse study, 2011</b>	Eclipse® prosthesis	30	27	1,7	F/E : 56/58 P/S : 83/64	102%	DASH : 26 MWS : 76	1 : revision 1 : migration

ROM : range of motion ; HRIA : hemiresection interposition arthroplasty ; TUHP : total ulnar head prosthesis ; F/E : flexion/extension ; P/S : pronation/supination ;

## - 7) Complications

### - Poor clinical results

Three patients had disabling post-operative pain after Eclipse® prosthesis implantation.

One patient had a cervical arthrosis with neurologic pain spreading in all of the upper extremity. Moreover, postoperative X-rays showed a distal migration of the prosthesis with carpal compression. It could explain the important pain and poor functional outcome.

One patient had severe radiocarpal and mediocarpal arthrosis on the operated wrist.

One patient was operated following a high energy trauma with a total elbow prosthesis implantation few years before. He kept pain and difficulties to use his upper extremity.

### - Radiological complications

In this study, one patient had a distal migration of Eclipse® prosthesis with clinical disabling consequences described above.

Some radiological bone changes were found at the final follow-up as signs of remodeling of the sigmoid notch in 9 patients and slight bone resorption around the collar of the stem in 10 patients.

These complications were already found by other authors.

Willis et al.<sup>24</sup> reported signs of remodeling of the sigmoid fossa around the metallic head on each patient X-ray but only one patient had progressive degeneration of the sigmoid notch requiring revision. Five patients had slight bone resorption beneath the collar of the prosthesis.

Van Schoonhoven et al.<sup>51</sup> using a ceramic ulnar head found one patient with progressive erosion and cyst formation at the sigmoid notch.

The sigmoid notch seemed to adapt and to remodel to the contour and forces imparted by the ulnar head. These radiological changes were not correlated with postoperative pain in this study.

The slight bone resorption beneath the collar of the stem, specially on the radial side, might be explained by the radial inclination of the stem leading to a higher pressure on this side. But no correlation could be analysed on it in this study because of lack of power.

## - 8) Study's limitations

There are limitations to this study.

The DASH score could be influenced by others disorders affected the operated upper extremity. Although is not a validated score, the Mayo Wrist Score lead to estimate more specifically wrist function.

The verbal analog pain score is based on the patient's subjective report as well as Mayo Wrist Score.

Additionally, clinical data of patients were obtained at follow-up but were not determined at the point before the partial ulnar head implant arthroplasty. It would be worthwhile to have clinical evaluation of patients for both before and after surgery.

Some follow-up data were collected by the patient's surgeon who were involved with the surgery, possibly a source of bias.

Because of the small patient cohort, the study lacks the power to find differences in outcome measurements.

## **VI- CONCLUSION**

This is the first clinical study on a partial ulnar head prosthesis.

Eclipse® prosthesis implantation is suggested in primary indications of DRUJ degenerative changes as chronic inflammatory diseases, post-traumatic arthrosis, idiopathic osteoarthritis and congenital disease.

Our preliminary results showed that Eclipse® prosthesis implantation can reliably decrease pain along with restoring stability of DRUJ, forearm motion and grip strength.

This is a reliable and reproducible procedure for painful DRUJ without important comorbidity and leaving possible others surgical procedures in case of failure.

Nevertheless, longer follow-up periods and more extended cohort of patients are required to determine the long-term value of Eclipse® implant.

Titre :

***Partial ulnar head replacement : Eclypse<sup>®</sup> prosthesis.  
A multicentric review of 27 patients***

Conclusion :

Treatment options of distal radioulnar joint (DRUJ) disorders consist of ulnar resection, hemiresection arthroplasties or the Kapandji-Sauvé procedure. However these nonanatomic procedures lead to a lot of complications like decreased grip, persistent pain and instability of the DRUJ as the « ulna impingement syndrome ». The ulna head is the load-bearing keystone of the DRUJ and the DRUJ stability is maintained by ligaments, the triangular fibrocartilage complex in particular. This multicentric study reports experience of several surgeons treating DRUJ disorders using a pyrocarbon partial ulnar head prosthesis Eclypse<sup>®</sup>.

Twenty-seven wrists in 27 patients (20 females, 7 males) were treated for painful DRUJ disorders secondary to posttraumatic arthrosis (7 patients), idiopathic arthrosis (13 patients), inflammatory diseases (6 patients) and congenital disease (1 patient) with an Eclypse<sup>®</sup> prosthesis (Bioprofile, Grenoble, France). The mean follow-up is 30 months. Post-operative assessments included patient-reported pain score, satisfaction, forearm range of motion, grip strength, clinical and radiographic examinations. The DASH score and the Mayo Wrist Score (MWS) was calculated at the last follow-up.

The mean pain score statistically significant decreased from 6 preoperative to 1,7 postoperative and 24 patients were very satisfied and satisfied. Postoperatively, the mean pronation was 83,3°, supination 64°, extension 58,1° and flexion 56,4°. Average grip strength was 14kg or 102% of the opposite side. The mean DASH score was 26,3 and the mean MWS was 76,8 with 16 excellent and good results. All wrists were clinically stable. One revision occurred at 22 months and one patient had a distal migration of the prosthesis.

Eclypse<sup>®</sup> prosthesis seemed to be a good option for treatment of DRUJ disorders with a low rate of complication. Eclypse<sup>®</sup> prosthesis implantation lead to decreased pain along with restoration of forearm motion and grip strength keeping DRUJ stability. These preliminary clinical results were better than nonanatomic others procedures. This procedure is reliable, reproducible and leaves possible others surgical procedures in case of failure. Larger clinical study will needed to determine the long-term success of Eclypse<sup>®</sup> prosthesis.

Vu et permis d'imprimer  
Grenoble, le 17/11/2011

Le Doyen de la faculté de Médecine de Grenoble,  
Pr J.P. ROMANET

Le Président de thèse,  
Pr F. MOUTET



## VII- Bibliography

1. Garcia-Elias M. FAILED ULNAR HEAD RESECTION: PREVENTION AND TREATMENT. *The Journal of Hand Surgery: Journal of the British Society for Surgery of the Hand*. 2002;27(5):470-480.
2. Stuart PR, Berger RA, Linscheid RL, An K-N. The dorsopalmar stability of the distal radioulnar joint☆. *The Journal of Hand Surgery*. 2000;25(4):689-699.
3. Shaaban H, Giakas G, Bolton M, et al. the distal radioulnar joint as a load-bearing mechanism—a biomechanical study1 ☆. *The Journal of Hand Surgery*. 2004;29:85-95.
4. Mansat P, Ayel J-E, Bonneville N, et al. Long-term outcome of distal ulna resection-stabilisation procedures in post-traumatic radio-ulnar joint disorders. *Orthopaedics & Traumatology: Surgery & Research*. 2010;96(3):216-221.
5. George M, Kiefhaber T, Stern P. The Sauve-Kapandji Procedure and the Darrach Procedure for Distal Radio-Ulnar Joint Dysfunction After Colles' Fracture. *The Journal of Hand Surgery: Journal of the British Society for Surgery of the Hand*. 2004;29(6):608-613.
6. Nanchahal J, Sykes P, Williams R. Excision of the distal ulna in rheumatoid arthritisIs the price too high? *The Journal of Hand Surgery: Journal of the British Society for Surgery of the Hand*. 1996;21(2):189-196.
7. Schober F, van Schoonhoven J, Prommersberger KJ, Lanz U. [Bowers hemi-resection-interposition arthroplasty for treatment of post-traumatic arthrosis of the distal radio-ulnar joint after distal radius fractures]. *Handchir Mikrochir Plast Chir*. 1999;31(6):378-382.
8. Minami A, Suzuki K, Suenaga N, Ishikawa J. Hemiresection-interposition arthroplasty for osteoarthritis of the distal radioulnar joint. *Int Orthop*. 1995;19(1):35-39.
9. van Schoonhoven J, Kall S, Schober F, Prommersberger K-J, Lanz U. [The hemiresection-interposition arthroplasty as a salvage procedure for the arthrotically destroyed distal radioulnar joint]. *Handchir Mikrochir Plast Chir*. 2003;35(3):175-180.
10. Pillukat T, van Schoonhoven J. [The hemiresection-interposition arthroplasty of the distal radioulnar joint]. *Oper Orthop Traumatol*. 2009;21(4-5):484-497.
11. Watson H. MODIFIED ARTHROPLASTY OF THE DISTAL RADIO-ULNAR JOINT. *The Journal of Hand Surgery: Journal of the British Society for Surgery of the Hand*. 2002;27(4):322-325.
12. Minami A, Suzuki K, Suenaga N, Ishikawa J. The Sauvé-Kapandji procedure for osteoarthritis of the distal radioulnar joint. *The Journal of Hand Surgery*. 1995;20(4):602-608.
13. Van Schoonhoven J, Lanz U. [Salvage operations and their differential indication for the distal radioulnar joint]. *Orthopade*. 2004;33(6):704-714.
14. Minami A, Iwasaki N, Ishikawa J-I, et al. Treatments of osteoarthritis of the distal radioulnar joint: long-term results of three procedures. *Hand Surg*. 2005;10(2-3):243-248.
15. Gaebler C. Ulnar procedures for post-traumatic disorders of the distal radioulnar joint. *Injury*. 2003;34(1):47-59.
16. Gonzalezdelpino J, Fernandez D. Salvage procedure for failed Bowers' hemiresection interposition technique in the distal radioulnar joint. *The Journal of Hand Surgery: Journal of the British Society for Surgery of the Hand*. 1998;23(6):749-753.
17. Sauerbier M. THE DYNAMIC RADIOULNAR CONVERGENCE OF THE DARRACH PROCEDURE AND THE ULNAR HEAD HEMIRESECTION INTERPOSITION ARTHROPLASTY: A BIOMECHANICAL STUDY. *The Journal of Hand Surgery: Journal of the British Society for Surgery of the Hand*. 2002;27(4):307-316.

18. Sauerbier M, Fujita M, Hahn ME, et al. [Radioulnar impingement after distal ulnar resection and ulnar head hemiresection interposition arthroplasty (Bowers procedure). An experimental biomechanical study]. *Handchir Mikrochir Plast Chir.* 2003;35(3):138-146.
19. Gordon K. Kinematics of ulnar head arthroplasty. *The Journal of Hand Surgery: Journal of the British Society for Surgery of the Hand.* 2003;28(6):551-558.
20. McKee MD, Richards RR. Dynamic radio-ulnar convergence after the Darrach procedure. *J Bone Joint Surg Br.* 1996;78(3):413-418.
21. Lees V, Scheker L. The radiological demonstration of dynamic ulnar impingement. *The Journal of Hand Surgery: Journal of the British Society for Surgery of the Hand.* 1997;22(4):448-450.
22. Talwalkar S, Roy N, Trail I, et al. 17.1 THE ROLE OF THE HERBERT ULNAR HEAD PROSTHESIS IN THE MANAGMENT OF DRUJ INSTABILITY. *The Journal of Hand Surgery: Journal of the British Society for Surgery of the Hand.* 2006;31:81-81.
23. Masaoka S, Longsworth S, Werner F, Short W, Green J. Biomechanical analysis of two ulnar head prostheses. *The Journal of Hand Surgery.* 2002;27(5):845-853.
24. Willis A, Berger R, Cooneyiii W. Arthroplasty of the Distal Radioulnar Joint Using a New Ulnar Head Endoprosthesis: Preliminary Report. *The Journal of Hand Surgery.* 2007;32(2):177-189.
25. Cooneyiii W, Berger R. Distal Radioulnar Joint Implant Arthroplasty. *Journal of the American Society for Surgery of the Hand.* 2005;5(4):217-231.
26. Scheker LR. Implant Arthroplasty for the Distal Radioulnar Joint. *The Journal of Hand Surgery.* 2008;33(9):1639-1644.
27. Laurentin-Perez LA, Goodwin AN, Babb BA, Scheker LR. A STUDY OF FUNCTIONAL OUTCOMES FOLLOWING IMPLANTATION OF A TOTAL DISTAL RADIOULNAR JOINT PROSTHESIS. *Journal of Hand Surgery (European Volume).* 2008;33(1):18-28.
28. Nakamura T, Yabe Y, Horiuchi Y. Functional anatomy of the triangular fibrocartilage complex. *The Journal of Hand Surgery: Journal of the British Society for Surgery of the Hand.* 1996;21(5):581-586.
29. Kihara H, Short W, Werner F, Fortino M, Palmer A. The stabilizing mechanism of the distal radioulnar joint during pronation and supination. *The Journal of Hand Surgery.* 1995;20(6):930-936.
30. Gofton W. Soft-tissue stabilizers of the distal radioulnar joint: an in vitro kinematic study1. *The Journal of Hand Surgery.* 2004;29(3):423-431.
31. Tolat A, Stanley J, Trail I. A cadaveric study of the anatomy and stability of the distal radioulnar joint in the coronal and transverse planes. *The Journal of Hand Surgery: Journal of the British Society for Surgery of the Hand.* 1996;21:587-594.
32. Hollevoet N, Verdonk R, Vanmaele G. The influence of articular morphology on non-traumatic degenerative changes of the distal radioulnar joint. A radiographic study. *The Journal of Hand Surgery: Journal of the British Society for Surgery of the Hand.* 2006;31:221-225.
33. Buck FM, Nico MAC, Gheno R, et al. Morphology of the distal radioulnar joint: cadaveric study with MRI and MR arthrography with the forearm in neutral position, pronation, and supination. *AJR Am J Roentgenol.* 2010;194(2):W202-207.
34. Kleinman WB. Stability of the Distal Radioulna Joint: Biomechanics, Pathophysiology, Physical Diagnosis, and Restoration of Function What We Have Learned in 25 Years. *The Journal of Hand Surgery.* 2007;32:1086-1106.
35. Palmer AK, Werner FW. Biomechanics of the distal radioulnar joint. *Clin. Orthop. Relat. Res.* 1984;(187):26-35.



36. Hagert CG. The distal radioulnar joint in relation to the whole forearm. *Clin. Orthop. Relat. Res.* 1992;(275):56-64.
37. DiTano O, Trumble TE, Tencer AF. Biomechanical function of the distal radioulnar and ulnocarpal wrist ligaments1. *The Journal of Hand Surgery.* 2003;28:622-627.
38. Haugstvedt J-R, Berger RA, Nakamura T, et al. Relative Contributions of the Ulnar Attachments of the Triangular Fibrocartilage Complex to the Dynamic Stability of the Distal Radioulnar Joint. *The Journal of Hand Surgery.* 2006;31:445-451.
39. Gofton W. Soft-tissue stabilizers of the distal radioulnar joint: an in vitro kinematic study1. *The Journal of Hand Surgery.* 2004;29(3):423-431.
40. Marc Garcia-Elias. Partial Ulnar Head (Eclipse) Replacement. Dans: *Principles and Practice of Wrist Surgery.* Elsevier; 2011:352-358.
41. Conaway DA, Kuhl TL, Adams BD. Comparison of the Native Ulnar Head and a Partial Ulnar Head Resurfacing Implant. *The Journal of Hand Surgery.* 2009;34(6):1056-1062.
42. Vanschoonhoven J. The ulnar head prosthesisIndications and limitations. *International Congress Series.* 2006;1295:69-72.
43. Hagert CG. Distal radius fracture and the distal radioulnar joint--anatomical considerations. *Handchir Mikrochir Plast Chir.* 1994;26(1):22-26.
44. Kleinman W, Graham T. The distal radioulnar joint capsule: Clinical anatomy and role in posttraumatic limitation of forearm rotation. *The Journal of Hand Surgery.* 1998;23:588-599.
45. Sauerbier M, Hahn M, Fujita M, et al. Analysis of dynamic distal radioulnar convergence after ulnar head resection and endoprosthesis implantation☆. *The Journal of Hand Surgery.* 2002;27(3):425-434.
46. Schuurman AH, Teunis T. A New Total Distal Radioulnar Joint Prosthesis: Functional Outcome. *The Journal of Hand Surgery.* 2010;35(10):1614-1619.
47. Herbert TJ, van Schoonhoven J. Ulnar Head Replacement. *Techniques in Hand and Upper Extremity Surgery.* 2007;11:98-108.
48. Yen Shipley N, Dion GR, Bowers WH. Ulnar head implant arthroplasty: an intermediate term review of 1 surgeon's experience. *Tech Hand Up Extrem Surg.* 2009;13(3):160-164.
49. Sauder DJ, King GJ. Hemiarthroplasty of the Distal Ulna With an Eccentric Prosthesis. *Techniques in Hand and Upper Extremity Surgery.* 2007;11:115-120.
50. Kopylov P, Tägil M. Distal radioulnar joint replacement. *Tech Hand Up Extrem Surg.* 2007;11(1):109-114.
51. van Schoonhoven JC, Fernandez DL, Herbert TJ. Salvage of Failed Resection Arthroplasties of the Distal Radioulnar Joint using an Ulnar Head Prosthesis – Long Term ResultsLevel 4 Evidence. *The Journal of Hand Surgery.* 2009;34(7):16-17.
52. De Witte PB, Wijffels M, Jupiter JB, Ring D. The Darrach procedure for post-traumatic reconstruction. *Acta Orthop Belg.* 2009;75(3):316-322.
53. Field J, Majkowski RJ, Leslie IJ. Poor results of Darrach's procedure after wrist injuries. *J Bone Joint Surg Br.* 1993;75(1):53-57.
54. Bain G, Pugh D, Macdermid J, Roth J. Matched hemiresection interposition arthroplasty of the distal radioulnar joint. *The Journal of Hand Surgery.* 1995;20(6):944-950.
55. Mueller M, Gohla T, Germann G, Sauerbier M. 17.2 PRELIMINARY RESULTS AFTER RECONSTRUCTION OF THE DESTROYED DRUJ WITH AN ULNAR HEAD PROSTHESIS. *The Journal of Hand Surgery: Journal of the British Society for Surgery of the Hand.* 2006;31:81-81.

## VIII- Figures' table

**Figure 1.** DRUJ anatomy with the sigmoid notch of the radius, the articular surface of the ulnar head with the fovea or fossa.

From Diane Coker, 2010

**Figure 2.** Three types of distal radioulnar joint in coronal plane :

A, Type I

B, Type II

C, Type II

From N.Hollevoet, 2006

**Figure 3.** Distal radioulnar joint : cartilage thickness in ulnar head and sigmoid notch of the radius and insertion of joint capsule and triangular fibrocartilage (TFC)

A, Diagram in axial plane. ECU=extensor carpi ulnaris tendon

B, Diagram in coronal plane.

From Florian M. Buck, 2010

**Figure 4.** Cartilage surface (white line) of sigmoid notch of the radius after removal of ulna head during dissection. Cartilage is surrounded by attachment of joint capsule, volar radioulnar ligament (1), dorsal radioulnar ligament (2) and triangular fibrocartilage.

From Florian M. Buck, 2010

**Figure 5.** The different types of sigmoid notch in the transverse plane :

A, « Flat face » notch

B, « Ski slope » notch

C, « C » type notch

D, « S » type notch

From A.R. Tolat, 1996

**Figure 6.** Transverse section through the distal radioulnar joint. The radius of curvature of the sigmoid notch is greater than the radius of curvature of the seat of the ulna.

From William B. Kleinman, 2007

**Figure 7.** The Triangular Fibrocartilage Complex with the volar and dorsal radioulnar ligaments, the articular disc, the extensor carpi ulnaris tendon sheath, the ulnotriquetral ligament and ulnolunate ligament.

From Hung Wai Lam, 2011

**Figure 8.** The triangular fibrocartilage consists of superficial (green) and deep (blue) radioulnar fibers and the central articular disc (white).

From William B. Kleinman, 2007

**Figure 9.** The longitudinal axis of rotation of the forearm.

From William B. Kleinman, 2007

**Figure 10.** Axial IRM images from DRUJ.

A, in maximal pronation, the ulna head moves dorsally

B, in maximal supination, the ulna head moves toward palmar side

From Florian M. Buck, 2010

**Figure 11.** As the radius rotates from full supination to full pronation around the ulna, the radioulnar variance changes during motion.

From William B. Kleinman, 2007

**Figure 12.** *Extrinsic stabilizers of the DRUJ include the tendon of the extensor carpi ulnaris (1), the sixth dorsal compartment subsheath (2), the pronator quadratus (3) and the interosseous membrane of the forearm.*

From William B. Kleinman, 20

**Figure 13.** *The angle of attack of the superficial (green) and deep (blue) fibers of the TFC from the medial radius to the fovea is different.*

From William B. Kleinman, 2007

**Figure 14.** *Role of the superficial (green) and deep (blue) fibers of the TFC in DRUJ stability during motion.*

**A,** *in supination*

**B,** *in pronation*

From William B. Kleinman, 2007

**Figure 15.** *In neutral position, the principal axis of load bearing passes through the scapholunate ligament and onto the interfossa ridge of the distal radius.*

From William B. Kleinman, 2007

**Figure 16.**

**A,** *The seat of the ulna is the fulcrum for all distal radioulnar joint mechanics.*

**B,** *The sum of the moments on the distal and proximal sides of the fulcrum equal the joint reaction force (JRF) at the distal radioulnar joint.*

From William B. Kleinman, 2007

**Figure 17.** *The Eclipse prosthesis (Bioprofile, Grenoble, France) and its ancillary.*

From Bioprofile, Grenoble, France

**Figure 18.** *Dorsoulnar skin incision centered over the head of the distal ulna with the dorsal branches of the ulnar nerve not far.*

**A,** *schema representing a Z-shaped incision. 1= dorsal branches of ulnar nerve*

**B,** *cadaveric dissection bringing to light dorsal branch of ulnar nerve.*

From Marc Garcia-Elias, 2010

**Figure 19.** *Schematic representation of how to enter the subretinacular space between the extensor retinaculum, the DRUJ capsule and the sixth compartment (sheath of the Extensor Carpi Ulnaris, ECU)*

From Marc Garcia-Elias, 2007

**Figure 20.** *Cadaveric dissection.*

**A,** *Incision of the retinacular ligament.*

**B,** *Once the retinacular flap is elevated, the ECU tendon and sheath can be observed and checked for its integrity.*

From Marc Garcia-Elias, 2007

**Figure 21.** *Example of the capsular flap being elevated towards the ulna, thus uncovering the dorsal edge of the TFCC.*

From Marc Garcia-Elias, 2007

**Figure 22.** *Schematic representation of the exposure of the ulnar head : Capsule elevated towards the ulnar side.*

From Garcia-Elias, 2007

**Figure 23.** *The forearm is full pronated and by adding some dorsal translation force, the head can be almost subluxed without TFCC detachment.*

From Marc Garcia-Elias, 2007

**Figure 24.** *Two cuts are necessary:*

- *a transverse osteotomy of about half the diameter of the ulnar head strictly perpendicular to the longitudinal axis of the ulna.*
- *a longitudinal osteotomy along the frontal plane, at the level of the fovea by the styloid process perpendicular to the plane of flexion-extension of the elbow.*

From Marc garcia-Elias, 2007

**Figure 25.** *Once fully inserted, the proximal tips of the four legs will adopt an expanded position and the adapted size head is inserted on.*

From Garcia-Elias, 2007

**Figure 26.**

**A and B,** *Stem implantation.*

**C,** *Head insertion.*

From Marc garcia-Elias, 2007

**Figure 27.** *Weigh-bearing evaluation with the « pronosupiator »*

**A,** *in pronation.*

**B,** *in supination.*

**Figure 28.** *A 51-year-old woman with Eclipse implantation on her right hand.*

**A,** *supination of the both hand.*

**B,** *pronation of the both hand.*

**Figure 29.** *A 51-year-old women using the « pronosupinator » to evaluate her weight-bear capacity of her operated hand.*

**A,** *in supination.*

**B,** *in neutral position.*

**C,** *in pronation.*

**Figure 30 :** *Correlation between postoperative pain and patient satisfaction :*

- *in ordinate : Pain scale from 0 to 10*

- *in axis : satisfaction : yes= very satisfied and satisfied  
no= indifferent and dissatisfied*

**Figure 31 :** *Correlation between patient satisfaction and grip strength of operated wrist :*

- *in ordinate : patient satisfaction*

- *in axis : % of grip strength of the operated wrist compared to the opposite side*

**Figure 32.** *A 64-year-old man with a painfull idiopathic arthrosis of the DRUJ.*

**A,** *preoperative X-rays.*

**B,** *after Eclyspe implantation with a 22 months follow-up.*

**Figure 33.** *A 80-year-old woman with painfull DRUJ arthrosis and scaphotrapezometacarpal arthrosis.*

**A,** *preoperative X-rays.*

**B,** *after Eclyspe implantation, trapezectomy and a pyrocarbon interposition implant (Pi2).*

**Figure 34.** *A 58-year-old woman with distal radius and ulna fractures.*

**A,** *distal radius osteosynthesis in emergency, after 6 months the pronosupination was 0°.*

**B,** *X-rays after 9 months following Eclyspe implantation. At final follow-up, she had 75° of pronation and 80° of supination.*

**Figure 35.** A 67-year-old man with painful DRUJ because of rheumatoid arthritis with synovectomy and ECU dorsalisation as previous surgery.

**A,** preoperative X-rays

**B,** signs of remodeling of the sigmoid notch at 3 months follow-up.

**C,** No evolution of the remodeling of the sigmoid notch at 6 months follow-up.

**Figure 36.** A 27-year-old man with a distal radius fracture in 2007 and any supination after osteosynthesis. A distal radius osteotomy correction was made in 2009 but the DRUJ was still painful. A Eclipse prosthesis was implanted 1 year after. Signs of remodeling of the sigmoid notch were visible

**A,** on 1 month X-ray follow-up

**B,** on 22 months X-ray follow-up

**Figure 37.** A 61-year-old man with Eclipse implantation for painful DRUJ idiopathic arthrosis. After 20 months follow-up, a slight bone resorption was visible beneath the collar of the stem.

**Figure 38.** A 37-year-old man with distal radius and ulna fractures. One year after the first osteosynthesis, an additional radial osteotomy was made associated with Eclipse implantation. He returned to previous work 6 months after second surgery.

**A,** one year after the first osteosynthesis.

**B,** one month after radius osteotomy and Eclipse implantation.

**C,** slight bone resorption was visible beneath the collar of the stem after 24 months follow-up.

**Figure 39.** A 52-year-old woman with painful DRUJ arthrosis.

**A,** X-ray before surgery

**B,** After 12 months follow-up, she had important DRUJ pain with limited range of motion.

## IX- Annex

### - 1) Annex 1

#### DISABILITIES OF THE ARM, SHOULDER AND HAND

Please rate your ability to do the following activities in the last week by circling the number below the appropriate response.

	NO DIFFICULTY	MILD DIFFICULTY	MODERATE DIFFICULTY	SEVERE DIFFICULTY	UNABLE
1. Open a tight or new jar.	1	2	3	4	5
2. Write.	1	2	3	4	5
3. Turn a key.	1	2	3	4	5
4. Prepare a meal.	1	2	3	4	5
5. Push open a heavy door.	1	2	3	4	5
6. Place an object on a shelf above your head.	1	2	3	4	5
7. Do heavy household chores (e.g., wash walls, wash floors).	1	2	3	4	5
8. Garden or do yard work.	1	2	3	4	5
9. Make a bed.	1	2	3	4	5
10. Carry a shopping bag or briefcase.	1	2	3	4	5
11. Carry a heavy object (over 10 lbs).	1	2	3	4	5
12. Change a lightbulb overhead.	1	2	3	4	5
13. Wash or blow dry your hair.	1	2	3	4	5
14. Wash your back.	1	2	3	4	5
15. Put on a pullover sweater.	1	2	3	4	5
16. Use a knife to cut food.	1	2	3	4	5
17. Recreational activities which require little effort (e.g., cardplaying, knitting, etc.).	1	2	3	4	5
18. Recreational activities in which you take some force or impact through your arm, shoulder or hand (e.g., golf, hammering, tennis, etc.).	1	2	3	4	5
19. Recreational activities in which you move your arm freely (e.g., playing frisbee, badminton, etc.).	1	2	3	4	5
20. Manage transportation needs (getting from one place to another).	1	2	3	4	5
21. Sexual activities.	1	2	3	4	5

## DISABILITIES OF THE ARM, SHOULDER AND HAND

	NOT AT ALL	SLIGHTLY	MODERATELY	QUITE A BIT	EXTREMELY
22. During the past week, to <i>what extent</i> has your arm, shoulder or hand problem interfered with your normal social activities with family, friends, neighbours or groups? ( <i>circle number</i> )	1	2	3	4	5

	NOT LIMITED AT ALL	SLIGHTLY LIMITED	MODERATELY LIMITED	VERY LIMITED	UNABLE
23. During the past week, were you limited in your work or other regular daily activities as a result of your arm, shoulder or hand problem? ( <i>circle number</i> )	1	2	3	4	5

Please rate the severity of the following symptoms in the last week. (*circle number*)

	NONE	MILD	MODERATE	SEVERE	EXTREME
24. Arm, shoulder or hand pain.	1	2	3	4	5
25. Arm, shoulder or hand pain when you performed any specific activity.	1	2	3	4	5
26. Tingling (pins and needles) in your arm, shoulder or hand.	1	2	3	4	5
27. Weakness in your arm, shoulder or hand.	1	2	3	4	5
28. Stiffness in your arm, shoulder or hand.	1	2	3	4	5

	NO DIFFICULTY	MILD DIFFICULTY	MODERATE DIFFICULTY	SEVERE DIFFICULTY	SO MUCH DIFFICULTY THAT I CAN'T SLEEP
29. During the past week, how much difficulty have you had sleeping because of the pain in your arm, shoulder or hand? ( <i>circle number</i> )	1	2	3	4	5

	STRONGLY DISAGREE	DISAGREE	NEITHER AGREE NOR DISAGREE	AGREE	STRONGLY AGREE
30. I feel less capable, less confident or less useful because of my arm, shoulder or hand problem. ( <i>circle number</i> )	1	2	3	4	5

**DASH DISABILITY/SYMPTOM SCORE** =  $\frac{[(\text{sum of } n \text{ responses}) - 1] \times 25}{n}$ , where n is equal to the number of completed responses.

A DASH score may not be calculated if there are greater than 3 missing items.

- 2) Annex 2

## Mayo Wrist Score

Category	Score, Points	Findings
Pain (25 points)	25	None
	20	Mild, occasional
	15	Moderate, tolerable
	0	Severe or intolerable
Functional status (25 points)	25	Returned to regular employment
	20	Restricted employment
	15	Able to work but unemployed
	0	Unable to work because of pain
Range of motion (25 points)	25	Percentage of normal 100
	15	75–99
	10	50–74
	5	25–49
	0	0–24
		Flexion–extension arc, ° (injured hand only)
	25	≥120
	15	91–119
	10	61–90
	5	31–60
0	≤30	
Grip strength (25 points)	25	% of normal 100
	15	75–99
	10	50–74
	5	25–49
	0	0–24
Final Result	Excellent	90–100
	Good	80–89
	Fair	65–79
	Poor	<65

From Andrew Willis, 2007



**Table 5. Characteristics of study population, satisfaction, DASH score and complications**

N° Patient	Gender	Age at Surgery, y	Operated Hand : Dominant or not	Diagnostic	Length of Follow-Up Period, mo	Associated Surgery	Patient Satisfaction	DASH	Complications
1	F	67	No	Rheumatoid arthritis	64	ECU Dorsalisation + synovectomy	Very satisfied	12	None
2	F	63	Yes	Rheumatoid arthritis + 4th and 5th extensors rupture	20	Suture of 4th and 5th extensors	Satisfied	NR	None
3	F	75	No	Arthrosis	22	NR	Very satisfied	3,3	NR
4	F	58	Yes	Trauma (fracture)	15	NR	Very satisfied	NR	NR
5	M	36	No	Trauma (fracture)	16	Lengthening radius osteotomy	Very satisfied	5	None
6	F	85	Yes	Chondrocalcinosis + 4th and 5th extensors rupture	69	Suture of 4th and 5th extensors	Very satisfied	7,5	None
7	F	72	Yes	Arthrosis	46	None	Disatisfied	71	None
8	F	52	Yes	Arthrosis	12	None	Indifferent	75	None
9	M	70	Yes	Arthrosis	32	None	Very satisfied	9,1	Prosthesis migration
10	F	58	Yes	Arthrosis	34	None	Very satisfied	73	None
11	F	79	No	Rheumatoid arthritis	29	None	Satisfied	50	Revision : additional bone resection
12	M	54	Yes	Trauma	29	None	Very satisfied	0	None
13	F	51	Yes	Trauma (fracture)	34	None	Very satisfied	22,5	None
14	F	64	No	Trauma (fracture)	48	None	Very satisfied	0	None
15	F	53	No	Arthrosis	28	None	Very satisfied	86	Wound infection
16	F	78	Yes	Arthrosis	24	STPi pyrocarbon	Very satisfied	19,2	None
17	F	80	Yes	Arthrosis	16	Trapezectomy + Pi2	Very satisfied	38,4	None
18	M	64	Yes	Arthrosis	22	None	Disatisfied	64,4	None
19	F	30	No	Congenital disease	43	Resection radial head	Very satisfied	25,8	None
20	F	63	Yes	Arthrosis	23	None	Satisfied	15,75	None
21	M	61	No	Arthrosis	20	None	Very satisfied	2,27	None
22	M	27	Yes	Trauma (fracture)	22	None	Very satisfied	43	None
23	M	54	Yes	Arthrosis	20	Carpal tunnel syndrome	Very satisfied	0	None
24	F	36	No	Arthrosis	12	None	Satisfied	NR	None
25	F	73	No	Chondrocalcinosis	34	Trapezectomy + Pi2	Very satisfied	7	None
26	F	58	No	Trauma (fracture)	12	None	Satisfied	5,4	None
27	F	92	No	Chondrocalcinosis + 4th and 5th extensors rupture	12	Suture of 4th and 5th extensors	Very satisfied	26	None

