



HAL
open science

Involvement of high frequency oscillations ranging from 60 to 100Hz at seizure onset demonstrated with epileptogenicity maps: new insights into seizure onset zone definition

Anne-Sophie Job

► To cite this version:

Anne-Sophie Job. Involvement of high frequency oscillations ranging from 60 to 100Hz at seizure onset demonstrated with epileptogenicity maps: new insights into seizure onset zone definition. Human health and pathology. 2012. dumas-00732973

HAL Id: dumas-00732973

<https://dumas.ccsd.cnrs.fr/dumas-00732973>

Submitted on 17 Sep 2012

HAL is a multi-disciplinary open access archive for the deposit and dissemination of scientific research documents, whether they are published or not. The documents may come from teaching and research institutions in France or abroad, or from public or private research centers.

L'archive ouverte pluridisciplinaire **HAL**, est destinée au dépôt et à la diffusion de documents scientifiques de niveau recherche, publiés ou non, émanant des établissements d'enseignement et de recherche français ou étrangers, des laboratoires publics ou privés.

AVERTISSEMENT

Ce document est le fruit d'un long travail approuvé par le jury de soutenance et mis à disposition de l'ensemble de la communauté universitaire élargie.

Il n'a pas été réévalué depuis la date de soutenance.

Il est soumis à la propriété intellectuelle de l'auteur. Ceci implique une obligation de citation et de référencement lors de l'utilisation de ce document.

D'autre part, toute contrefaçon, plagiat, reproduction illicite encourt une poursuite pénale.

Contact au SICD1 de Grenoble : thesebum@ujf-grenoble.fr

LIENS

Code de la Propriété Intellectuelle. articles L 122. 4

Code de la Propriété Intellectuelle. articles L 335.2- L 335.10

http://www.cfcopies.com/V2/leg/leg_droi.php

<http://www.culture.gouv.fr/culture/infos-pratiques/droits/protection.htm>

INVOLVEMENT OF HIGH FREQUENCY
OSCILLATIONS RANGING FROM 60 TO 100HZ
AT SEIZURE ONSET DEMONSTRATED WITH
EPILEPTOGENICITY MAPS

NEW INSIGHTS INTO SEIZURE ONSET ZONE DEFINITION

Anne-Sophie Job, née le 19/09/1984

Thèse soutenue publiquement le 15 mai 2012 à la Faculté de médecine de Grenoble,
devant un jury composé de
Philippe Kahane, Président du jury
Fabrice Bartolomei
Stéphan Chabardes
Olivier David, Directeur de thèse
Lorella Minotti, Co-directeur de thèse

ABSTRACT

High gamma oscillations (HFO, >60 Hz) at seizure onset are strongly associated to epileptogenesis, and their localising value for the seizure onset zone (SOZ) has been underlined using quantitative measures such as the epileptogenicity index. In particular, we recently reported a new method that produces images of epileptogenicity based on the detection of significant increase of HFO at seizure onset in stereotactic coordinates derived from patient's MRI (magnetic resonance imaging).

Here, we applied the same analysis to 21 consecutive patients who underwent stereo-electroencephalography (SEEG) recordings between 2009 and 2011, and in whom at least one spontaneous seizure was recorded. Power of HFO ranging from 60 to 100Hz band ($^{ictal}HFO_{60-100}$) was quantified at onset for each seizure, and statistical parametric maps were used to represent the cortex areas displaying significant $^{ictal}HFO_{60-100}$ when compared to an interictal baseline. Analysis was performed at the patient level per seizure, with a group analysis for all seizures from every patient.

All patients presented a significant epileptogenicity map at seizure onset, whatever seizure onset location or histological lesion they had. $^{ictal}HFO_{60-100}$ map was highly reproducible over seizures per patient, and most significant $^{ictal}HFO_{60-100}$ had the same localisation as epileptogenic lesions. For 11 patients who underwent a 3DT1 MRI in the post-operative period, the removal of cortex areas displaying significant $^{ictal}HFO_{60-100}$ was associated to a better outcome.

Epileptogenicity map (EM) is useful to evaluate the SOZ in the pre-surgical period. This new tool associated to SEEG might help to improve the surgical outcome of medically-intractable epilepsies.

Keywords: medically intractable epilepsy; stereo-electroencephalography; epileptogenicity; high frequency oscillations; seizure onset zone.

RESUME

Les oscillations hautes fréquences, ou HFO (high frequency oscillations, >60Hz) sont l'objet de multiples recherches récentes tant dans le domaine de l'épilepsie que dans celui de la cognition. Ces oscillations, étudiées en stéréo-électroencéphalographie (SEEG) chez les patients présentant une épilepsie partielle pharmaco-résistante, semblent être le témoin de l'épileptogénèse. Elles reflètent par ailleurs assez fidèlement, par leur topographie, la *seizure onset zone* (SOZ), zone corticale activée lors du début de la crise épileptique. Ces propriétés ont initialement été utilisées pour définir un index d'épileptogénicité, basé sur l'activation des hautes fréquences au début de la crise. Plus récemment, notre équipe a fait état d'une nouvelle méthode de cartographie de la SOZ basée sur l'augmentation de puissance des HFO₆₀₋₁₀₀ (HFO dont la fréquence est comprise entre 60 et 100 Hz). Cette méthode, principalement appliquée aux patients souffrant d'une épilepsie temporale méssiale, permet d'établir une cartographie des réseaux neuronaux impliqués dans l'initiation de la crise comme dans sa propagation.

Tous les patients implantés en SEEG entre 2009 et 2011 au CHU de Grenoble ont été inclus dans notre étude, dès lors qu'ils avaient présenté au moins une crise épileptique spontanée. 21 patients ont ainsi été étudiés, de SOZ majoritairement néocorticale. La puissance ictale des HFO₆₀₋₁₀₀ a été quantifiée pour chaque crise, puis les cartographies statistiques du logiciel SPM (Statistical Parametric Maps) ont été utilisées pour représenter les régions corticales présentant une activation significative des HFO₆₀₋₁₀₀ au début de la crise, comparativement aux HFO₆₀₋₁₀₀ intercritiques. Les analyses réalisées ont été conduites pour chaque patient et chaque crise, comme pour l'ensemble des crises de chaque patient.

Pour tous les patients étudiés, une activation critique significative des HFO₆₀₋₁₀₀ a été démontrée, quelle que soit la topographie de la SOZ, indépendamment de la présence d'une lésion épileptogène. La topographie des HFO₆₀₋₁₀₀ activées au début des crises semble corrélée à celle de la SOZ. Les cartographies d'épileptogénicité obtenues s'avèrent très reproductibles pour toutes les crises enregistrées, pour un patient donné. Enfin, pour 11 des patients opérés, le pronostic chirurgical s'avérait d'autant plus favorable que la résection réalisée contenait les régions cérébrales présentant une activation significative des HFO₆₀₋₁₀₀ ictales. Ces cartographies d'épileptogénicité pourraient constituer un nouvel outil du bilan pré-chirurgical des épilepsies pharmaco-résistantes, visant à préciser les limites de la zone épileptogène à réséquer, en fonction du degré d'épileptogénicité des zones corticales étudiées.

Mots-clés : Epilepsie; Stéréo-électroencéphalographie ; Oscillations hautes fréquences ; Zone épileptogène; Epileptogenicité

RESUME SUBSTANTIEL

La digitalisation des systèmes d'enregistrement électro-encéphalographique (EEG), et l'augmentation des fréquences d'échantillonnage utilisées ont abouti, depuis 10 ans, à de nombreuses avancées concernant le rôle des oscillations hautes fréquences, ou HFO (high frequency oscillations) au cours de l'épileptogénèse. Ces oscillations ont d'abord été extraites d'enregistrements EEG intracrâniens, qui présentent l'avantage de fournir des enregistrements non artefactés de l'activité corticale. La présence de ces oscillations a initialement été rapportée au début des crises, associée à l'activité rapide de bas voltage ictale visualisée en EEG (Fisher 1992). Les HFO, de fréquence gamma et au-delà, avaient d'emblée été pressenties comme un indicateur pronostic potentiel (Alarcon 1995), leur présence étant associée à un pronostic post-chirurgical favorable.

Les HFO ont rapidement été étudiées à l'aide de modèles animaux, puis chez les patients épileptiques, à distance des crises (^{interictal}HFO). Ces oscillations, dont la détection est corrélée à la présence d'une atrophie hippocampique pour les patients souffrant d'une épilepsie mésiotemporale (Staba et al 2002), ont également été retrouvées lorsque la zone épileptogène est néocorticale (Jirsch et al 2006). Leur topographie est corrélée à la *seizure onset zone* (SOZ), région corticale compromise au début de la crise. De façon surprenante, ces oscillations ont été peu étudiées à la phase ictale, bien que leur présence à ce stade soit avérée (Jirsch et al 2006, Worrell et al 2004). De même, les HFO de plus bas spectre fréquentiel ($HFO_{<100}$) ne sont que rarement pris en compte au cours des études détectant les HFO, quand bien même ces oscillations semblent refléter le degré d'épileptogénicité des régions corticales impliquées au cours de la crise (Bartolomei et al 2008).

Différentes méthodes se sont récemment attachées à utiliser les propriétés des $HFO_{<100}$ pour adapter leur étude à la pratique clinique. L'équipe Marseillaise (Bartolomei et al 2008) a ainsi établi un index d'épileptogénicité, basé sur la quantification, pour un patient donné, de l'activation ictale de spectre fréquentiel $\beta\gamma$ ($>12\text{Hz}$) comparativement aux basses fréquences. Ce ratio moyenné par rapport à la valeur maximale de l'index d'épileptogénicité du patient, fournit une valeur chiffrée relative évaluant le degré d'implication ictale de chaque structure implantée.

S'inspirant de cet index, l'équipe Grenobloise (David et al 2011) a rapporté une nouvelle méthode de quantification des $HFO_{<100}$. L'activation significative ictale des HFO_{60-100} , comparativement à leur puissance interictale, est représentée au moyen de cartographies statistiques. Une fois reportées sur l'IRM anatomique du patient, les zones significativement activées fournissent une image de la SOZ, ou cartographie d'épileptogénicité. Cette méthode avait principalement été utilisée pour des patients présentant une épilepsie méso-temporale. Notre étude s'est attachée à produire, pour tous les patients consécutivement implantés en stéréoelectroencéphalographie (SEEG) au CHU de Grenoble, des

cartographies d'épileptogénicité. Leur caractère localisateur de la SOZ comme leur valeur pronostique a également été étudiée.

PATIENTS ET METHODES

Parmi les 28 patients ayant bénéficié d'une implantation intracrânienne, au moyen d'électrodes de SEEG au CHU de Grenoble, 21 ont présenté des crises spontanées enregistrées, et ont bénéficié d'une résection de la zone épileptogène définie d'après les conclusions de la SEEG. Pour chaque patient inclus, les données d'imagerie (IRM anatomique, IRM per-SEEG) ont été transférées dans MATLAB®, fusionnées et normalisées dans le référentiel MNI. La position de chaque électrode implantée a ainsi été transcrite en coordonnées normalisées, permettant une analyse de groupe. L'onset de chaque crise a été déterminé visuellement, tandis qu'un tracé de base, situé à plus de 10 secondes de la crise, sans activité interictale majeure, a été défini pour chaque crise. Pour chaque électrode est réalisée une cartographie temps/fréquence des premières 10 secondes de la crise. La puissance à l'instant t pour les HFO_{60-100} est évaluée puis normalisée comparativement à la puissance de ces oscillations interictales (tracé de base). L'évolution de l'activité HFO_{60-100} au cours de la crise est quantifiée pour des périodes de 4 secondes ($D=4$) avec un chevauchement Δ de 1 seconde. La résolution temporelle dt est de 100ms, avec une résolution spectrale d'1 Hz. La puissance dans la bande de fréquence gamma est évaluée pour D/dt (ici 40) points et comparée au tracé de base pour chaque plot. Ces données sont normalisées à l'aide d'une fonction logarithmique, puis l'utilisation d'un test t permet une comparaison entre les données ictales et interictales (avec correction globale du taux d'erreurs FWE). Les données de la fonction logarithmiques sont lissées et transposées sur l'IRM anatomique du patient.

Ainsi sont obtenues, pour chaque crise d'un patient, des cartographies d'activation significative HFO_{60-100} pour les instants $\Delta=0$ à $\Delta=10$. Ces cartes sont obtenues pour chaque crise, comme pour le groupe de crises de chaque patient. A partir des données des cartographies et selon la résection réalisée (transférée et normalisée dans MATLAB® à partir de l'IRM post-opératoire) sont obtenues des valeurs de recouvrement (overlap) entre les zones contenant des HFO_{60-100} et la résection réalisée. L'étude de ces valeurs d'overlap en fonction du pronostic post-opératoire permettrait de valider les propriétés de « biomarqueur épileptogène » des HFO_{60-100} .

RESULTATS

Les cartographies réalisées pour chaque patient inclut retrouvent, de façon systématique, une activation significative des HFO_{60-100} au début de la crise. Cette donnée, avérée pour tous les patients, quel que soit la topographie de la SOZ, se vérifie notamment pour les patients présentant une épilepsie partielle cryptogénique, c'est-à-dire sans lésion définie sur l'IRM anatomique (figure 1). L'activation ictale des HFO n'avaient jusqu'alors jamais été rapportée. L'étude ictale des HFO_{80-500} (Jirsch 2006)

ne retrouvait notamment pas d'HFO lorsque la SOZ était mal définie. D'autres études plus récentes (Park 2012) ne retrouvaient pas d' HFO₆₀₋₁₀₀ dans près de 30% des cas, mais ces derniers étaient enregistrés au moyen de grids corticaux.

La comparaison des cartographies d'épileptogénicité avec le tracé obtenu en SEEG a également été réalisée (figure 2). Celle-ci retrouve de grandes similarités entre les deux méthodes. Les cartographies réalisées semblent confirmer, de manière objective, exhaustive et quantifiée, ce que fournit l'analyse précise du tracé EEG enregistré. L'analyse des HFO₆₀₋₁₀₀ conduit par ailleurs à hiérarchiser le rôle des différentes structures compromises au cours de la crise, en fonction du degré d'activation des HFO. Dans certaines situations, les cartographies soulignent également le rôle prépondérant d'une région corticale, présentant une décharge d'allure assez peu tonique en analyse visuelle. Ceci s'est avéré pertinent pour les patients présentant une épilepsie temporo-insulaire, pour laquelle la compromission insulaire avait été sous-estimée. Un de ces patients présente aujourd'hui un pronostic défavorable, et la symptomatologie de ses crises actuelles est typiquement insulaire.

Dans notre cohorte, les zones présentant l'activation ictale des HFO₆₀₋₁₀₀ la plus significative sont de même localisation que les lésions épileptogènes définies en IRM, (pour les quelques patients présentant des dysplasies corticales focales). La région définie par ces cartographies dépasse la lésion dysplasique, mais reste plus significative en regard du cortex dysplasique (figure 3). Ces données confortent les conclusions de l'index d'épileptogénicité marseillais, qui rapportait des valeurs plus élevées d'index en regard des lésions épileptogènes, mais une épileptogénicité également notable au-delà de la lésion.

Par ailleurs, les cartographies d'épileptogénicité s'avèrent reproductible d'une crise à l'autre, pour un patient donné, y compris après diminution du traitement antiépileptique (figure 4). Ces cartographies semblent de ce fait refléter fidèlement le caractère très stéréotypé des crises électro-cliniques de chaque patient. Cette forte stabilité des régions compromises n'avait pas été rapportée en interictal pour les HFO₈₀₋₅₀₀ (Zijlamns 2009). Cependant, les HFO interictales n'ont pas valeur de marqueur de la crise, mais reflètent plutôt le degré d'épileptogénicité d'une structure au cours des heures précédant la crise.

Enfin, le ratio entre cortex présentant une activation ictale significative HFO₆₀₋₁₀₀, et les zones cérébrales réséquées, a été établi pour onze patients (figure 5). Le pronostic chirurgical est corrélé à ce ratio, quelle que soit l'entité syndromique et topographique présentée par le patient. En d'autres termes, plus large est la résection des zones impliquées dans la cartographie d'épileptogénicité, meilleur semble s'avérer le pronostic chirurgical.

CONCLUSION

Cette étude, basée sur les données critiques obtenues au cours d'enregistrements stéréo-électroencéphalographiques (SEEG) a été menée auprès de 21 patients consécutifs présentant une épilepsie partielle pharmaco-résistante. Au terme de ce travail, un constat primordial s'impose: chacun des patients étudiés présente une activation ictale significative des oscillations hautes fréquences de 60 à 100Hz (HFO₆₀₋₁₀₀), comparativement à l'activité interictale. Cette activation des HFO₆₀₋₁₀₀ s'avère systématique, quelle que soit la région corticale impliquée dans la genèse de la crise. Ceci est également confirmé pour les patients présentant une épilepsie partielle cryptogénique et pour lesquels la définition de la zone épileptogène demeure souvent complexe.

La très grande hétérogénéité comme la taille limitée de notre cohorte n'ont malheureusement pas permis d'établir de corrélation statistique à l'échelle du groupe, pour un type d'épilepsie ou de zone épileptogène donné. Néanmoins, les cartographies d'épileptogénicité démontrent une corrélation topographique étroite entre les zones compromises à la phase ictale d'après l'analyse SEEG, et celles présentant une activation significative des HFO₆₀₋₁₀₀. De façon similaire, les cartographies d'épileptogénicité s'avèrent très reproductibles d'une crise à l'autre. Le caractère stéréotypé des HFO₆₀₋₁₀₀ n'est pas sans rappeler la grande stabilité topographique de la zone à l'origine des différentes crises d'un même patient.

Par ailleurs, les patients dont la résection chirurgicale inclut les HFO₆₀₋₁₀₀ ictales les plus significatives présentent un pronostic post-opératoire favorable. A notre connaissance, la valeur épileptogène des HFO, corrélée au pronostic post-opératoire, n'avait jamais été évaluée en fonction de la résection effective des zones compromises dans ce spectre fréquentiel. Nos résultats devront être confirmés à plus grande échelle, mais ils présagent d'emblée de la valeur clinique de l'étude des HFO₆₀₋₁₀₀, dans la détermination des régions corticales impliquées dans l'épileptogénèse. A l'instar de la magnéto-encéphalographie et de la tomographie par émission de positons, les cartographies d'épileptogénicité pourraient être utilisées au cours du bilan pré-chirurgical pour délimiter les régions corticales à réséquer. Ceci s'avèrerait d'autant plus pertinent en l'absence de lésion anatomique définie, comme lors des résections en zone fonctionnelle. Les HFO₆₀₋₁₀₀ permettraient de restreindre la résection aux régions corticales dont le degré d'épileptogénicité ainsi quantifié est le plus élevé.

Multiplés sont les problématiques à résoudre concernant le rôle propre des HFO au cours de l'ictogénèse. Nos futures recherches devront s'attacher à évaluer les relations entre HFO₆₀₋₁₀₀ épileptiques, et les activités cognitives de même spectre fréquentiel. La présence d'HFO₆₀₋₁₀₀ intercritiques devra également être quantifiée, et pourrait constituer une étape cruciale dans la compréhension des mécanismes physiopathologiques à l'origine de la « route vers la crise.»

REMERCIEMENTS

Je voudrais avant tout remercier Fabrice Bartolomei, Stephan Chabardes, et Philippe Kahane d'avoir accepté d'expertiser cette thèse et d'en composer le jury.

Ma profonde reconnaissance va également à mes deux directeurs de thèse, Lorella Minotti et Olivier David, qui ont encadré ce travail et m'ont encouragée depuis près de deux ans. Avec Philippe Kahane, ils ont su me transmettre leur expérience, avec patience, chaleur et disponibilité. Vous m'avez initiée au raisonnement clinique en épileptologie et à la rigueur nécessaire en recherche clinique. Le chemin de la connaissance neurologique est tout aussi complexe que la route vers la crise ! Mais ces débuts sont fondateurs.

Je remercie également tous les médecins, de Grenoble, Chambéry et Lyon qui m'ont aidé au cours de ces quatre années d'internat, tout en partageant leur savoir et leur expérience clinique.

Je n'oublie pas mes co-internes, avec lesquels j'ai partagé bon nombre d'expériences culinaires, œnologiques mais aussi médicales et humaines, le tout dans une bonne humeur et une entente constante. Ces moments passés ensemble furent et sont un agréable sas de décompression.

Je souhaite aussi remercier ma famille, grands-parents, parents, frère et sœurs, qui m'ont soutenu, tout en supportant ma drôle de vie depuis mes débuts en médecine, bien que ses enjeux leur semblent parfois abstraits. Je remercie aussi mes amis qui ont été présents ces dernières années. Un grand merci à Nina et Anaë, mes belles-filles, qui ont fait chuchoter leurs Playmobil pour me laisser travailler.

Enfin, je remercie Tony, mon presque-mari, pour sa présence quotidienne, sa patience stoïque face à mes questions existentielles, et son amour si précieux. Si cette thèse a abouti, c'est d'abord grâce à lui.

TABLE OF CONTENTS

ABSTRACT	1
RESUME	2
RESUME SUBSTANTIEL	3
TABLE OF CONTENTS	8
INTRODUCTION	11
I. Historical aspects of High Frequency oscillations (HFO)	11
A. <u>Involvement of interictal hippocampic ripples (80-150 Hz) and fast-ripples (170-250 Hz) in epileptogenicity</u>	
B. <u>Relationship between HFO and seizure onset zone</u>	
- Interictal HFO would be a potential biomarker of the SOZ	
- Ictal HFO are activated at seizure onset	
- Technical and methodological limitations	
- Beyond the dichotomy of physiologic ripples and epileptic fast-ripples	
II. Major involvement of ictal HFO_{<100} in epileptogenicity	14
• Epileptogenicity index: quantified evaluation of ictal HFO _{12,4-97} enhancement	
• Epileptogenicity mapping : imaging brain areas displaying significant ictal HFO ₆₀₋₁₀₀ at seizure onset	
III. Objectives	15
• Imaging the seizure onset zone in light of epileptogenicity mapping: are ictal HFO ₆₀₋₁₀₀ systematically implied?	
• Relationship between epileptogenicity maps and seizure onset zone	
PATIENTS AND METHODS	16
I. Inclusion criteria and seizure onset zone evaluation	16
II. Imaging epileptogenicity	16
• Images transformation	
• Measures of epileptogenicity	
• Comparison of Epileptogenicity map with resection mask	

RESULTS.....19

I. Patients main characteristics.....19

- Anatomical location of the seizure onset zone
- Clinical characteristics
- Recording conditions
- Neuropathological findings

II. Epileptogenicity Mapping: individual evaluation.....21

A. HFO₆₀₋₁₀₀ are found at onset for all patients

- Patient 2: temporo-insular onset
- Patient 7: temporo-basal and orbito-frontal epilepsy
- Frontal lobe seizures: patients 9, 13 and 18
- Patient 19: left occipital SOZ

B. Relationship between Epileptogenicity Map and SOZ

1. Correlation between visual analysis of SEEG and ictal HFO₆₀₋₁₀₀ activation
2. Patients with epileptogenic lesions: example of focal cortical dysplasia
3. Spatial stability of Epileptogenicity maps between seizures
4. Removal of areas with significant HFO₆₀₋₁₀₀ activity is associated to good surgical outcome

DISCUSSION.....44

I. Ictal activation of HFO₆₀₋₁₀₀ is significant for all patients.....44

- A. Why should we further focus on HFO₆₀₋₁₀₀?
- B. Prominent value of ictal *versus* interictal high frequency oscillations
- C. Epileptogenicity maps sometimes vary between seizures
 - Unsignificant HFO₆₀₋₁₀₀ at seizure onset
 - Clinical interpretation of statistical results is necessary
- D. Additional value of Epileptogenicity mapping: overcoming SEEG analysis
- E. Methodological limits and bias

II. Epileptogenicity mapping strongly correlates with seizure onset zone.....48

- A. Most significant ictal HFO₆₀₋₁₀₀ co-localize with epileptogenic lesions
- B. Epileptogenicity maps reflect and rank the conclusions of SEEG visual analysis
- C. Reproducibility of Epileptogenicity map

- D. Epileptogenicity maps might predict surgical outcome: a new objective biomarker for the delineation of the epileptogenic area

CONCLUSION.....51

REFERENCES.....54

INTRODUCTION

Far from Berger's first description of frequency bandwidth, comprised between 0.1 and 30 Hz, the involvement of high frequency oscillations (HFO) in seizure onset has been increasingly studied during the last fifteen years (Buzsacki et al 1992). HFO are currently supposed to be involved in epileptogenesis, and their relationship with the seizure onset zone (SOZ) is now admitted.

I. HISTORICAL ASPECTS OF HIGH FREQUENCY OSCILLATIONS (HFO)

HFO were first studied at seizure onset, because of their potential relationship with ictal fast activities, visually defined on intracranial EEG (iEEG). Fisher et al had mentioned (1992) the association of HFO (^{ictal}HFO₄₀₋₁₂₀) with electrodecremental events, at seizure onset, in five epileptic patients who underwent iEEG. He suggested that HFO could be helpful to determine the SOZ, as the resection of regions showing ictal fast activity was associated with a good surgical outcome. This strong correlation with outcome was reported later (Lee et al 2000) in 53 patients suffering from neocortical epilepsy. Alarcon et al (1995) also noticed that when patients presented focal high frequency activities (ranging from 20 to 80 Hz) at onset, the surgical resection succeeded. These first observations benefited from the development of EEG digitalization and new abilities to record EEG with low-pass filters up to 500 Hz. However, further studies mostly aimed at describing HFO that occurred between the seizures (interictal HFO).

A. Involvement of interictal hippocampic ripples (80-150 Hz) and fast-ripples (170-250 Hz) in epileptogenicity

High frequency activities were first described during the interictal state, in the mesial temporal epilepsy model. In humans, ripples (100-200 Hz) were recorded interictally in the hippocampus and entorhinal cortex of patients with mesio-temporal epilepsy undergoing intracranial evaluation (Bragin et al 1999).

Further studies demonstrated that patients with mesio-temporal seizures had reduction of interictal hippocampal ripples (80-150 Hz) and increase of interictal fast ripples rates (170-250 Hz) ipsilateral to the SOZ (Staba et al 2002). The logarithmic ratio between ripples and fast ripples rates was significantly different between ipsi and contralateral hippocampus, especially when hippocampal atrophy was present. Fast ripples were thus supposed to be a potential marker of the seizure onset zone. This was confirmed later, while an inverse relationship between the fast ripples/ripple rate, and hippocampal atrophy was noticed (Staba et al 2007).

B. Relationship between HFO and seizure onset zone

HFO (ripples and fast-ripples) have been mainly studied interictally during slow wave sleep. Studies usually combined visual and spectral analysis, with semi-automatic detection of interictal HFO and, in a second step, visual reviewing.

- **Interictal HFO would be a potential biomarker of the SOZ**

Interictal HFO were found to be correlated with the SOZ (Urresterazu et al 2007), with a better specificity than spikes (Jacobs et al 2009a). This was confirmed in neocortical and mesial temporal epilepsy. Interictal HFO seemed to be a marker of epileptogenicity, but did not increase on lesional electrode contacts (except for hippocampal sclerosis) (Jacobs et al 2009a). Interictal HFO were also supposed to be a marker of disease activity: high rates (>20/min) of fast ripples were associated to frequent seizures on the 6 previous months (Zijlmans et al 2009a). Both ripples and fast ripples increased during the seconds preceding seizure occurrence (Zijlmans et al 2011) and with anti-epileptic medication withdrawal (Zijlmans et al 2009b), but they were not predictive of seizure occurrence on the fifteen minutes preceding the seizure onset (Jacobs et al 2009b).

Finally, interictal HFO localization was compared to post-surgical outcome, taking into account the rates of channels with HFO, and rates of channels belonging to the SOZ removed by surgery. Jacobs et al. (2010a) demonstrated that the removal of contacts with high HFO rates (ripples and fast-ripples) was associated with a good surgical outcome. In this study, however, the removal of the seizure onset zone was not associated with a better outcome, which raises the issue on how the SOZ was clinically evaluated. Moreover, only a few electrodes contacts displayed high HFO rates (5.9 +/- 3.2 for fast ripples), and this highly focal representation of the epileptogenic zone goes against the hypothesis of an epileptogenic “network”. Therefore, relationships between interictal HFO and ictal HFO remains not clear, and ictal HFO have to be studied.

- **Ictal HFO are activated at seizure onset**

Surprisingly, only a few studies focused on ictal HFO, whereas they were the first high frequency oscillations to be reported (Alarcon et al 1995). Ictal HFO were admitted to co-localize with the fast ictal discharge as defined visually in neocortical (Fisher et al 1992) and frontal lobe epilepsy (Allen et al 1992). They were reported, in Worrell et al series, within the 60-100Hz range (Worrell et al 2004). Jirsch et al reported ^{ictal}HFO of higher frequency in ten consecutive patients (Jirsch et al 2006): ^{ictal}HFO₍₁₀₀₋₅₀₀₎ increased at seizure onset in most mesio-temporal epilepsy cases and some of neocortical seizures. However, these HFO were recorded on very focal areas (one to three electrodes contacts) whereas most contacts presented a prominent increase in the subgamma (<40 Hz) band. Moreover, 3 patients did not present HFO at seizure onset. Further studies (Ochi et al 2007) reported a

close correlation between the resection of areas displaying ictal HFO₆₀₋₂₅₀ and good surgical outcome. These ictal HFO could be helpful to quantify the role for each electrode contact in seizure onset (Zijlmans et al 2011). However, the clinical value of HFO has never been studied, whereas the analysis of fast discharges is used in clinical practice to define the SOZ. But the localizing value of fast discharge would have to be formally confirmed. Technical limitations encountered might be responsible for the lack of clinical studies concerning both ictal and interictal HFO.

- **Technical and methodological limitations**

Evaluating HFO involvement in epileptogenicity remains difficult because no “gold standard” exists to delineate the epileptogenic zone (EZ). Most studies evaluated the pathological value of interictal HFO on their co-localization with the SOZ, which is defined as the area of cortex from which seizures are generated (Rosenow and Lüders 2001), but this electrophysiological definition is subjective. The correct evaluation of the SOZ is confirmed when the resection of the EZ (including the SOZ) leads to a seizure-free status. But some patients did not have the expected outcome, although interictal HFO tissue was included in the resection (Jacobs et al 2010a). Moreover, in most studies, the SOZ definition remained difficult with only a few electrodes implanted. HFO appeared to be very specific of SOZ, only when a few number of intracerebral electrodes have been implanted. In addition, interictal HFO were often found to be significant on one to three electrodes contacts (Jirsch et al 2006, Jacobs et al 2009a, Zijlmans et al 2009a, Crepon et al 2010). However, the EZ is known to belong to a wider network and HFO might be too specific to be clinically relevant. Meanwhile, as previously noticed, a few depths electrodes were implanted per patient, and this might explain the low HFO rates reported. Are HFO too specific or insufficiently explored? This question remains debatable.

- **Beyond the dichotomy of physiologic ripples and epileptic fast-ripples**

The coexistence of pathological epileptogenic (Bragin et al 2002a 2002b, Jacobs et al 2010b) and normal cognitive (Staba et al 2002) HFO was previously reported: ripples could be physiologic events involved in memory processes such as encoding, and fast ripples would be the signature of cortical regions capable of generating spontaneous seizures. Such a distinction remains discussed (Engel et al 2009). The difference between pathologic and normal HFO cannot be made on the only basis of frequency. Blanco et al (2010) reported significant events of mixed frequency in neocortical epilepsy. Further research found that ripples were significant in the SOZ, whereas fast ripples were not (Blanco et al 2011). Otherwise, recording conditions may be too different from one center to another to conclude to the physiological and/or pathologic value of ripples and fast ripples (Crepon et al 2010). The hypothesis of a continuum between ripples and fast ripples was raised, as both can be implied on seizure occurrence and normal cognitive activities. Therefore, studying ictal HFO₆₀₋₁₀₀ in this continuum is of interest.

II MAJOR INVOLVEMENT OF $^{ictal}HFO_{<100}$ IN EPILEPTOGENICITY

HFO mainly focused on frequencies above 120 Hz, with high pass filters above 80 Hz. In this context, high ‘gamma’ activities (60-100 Hz) have rarely been studied, whereas their relevant role in ictogenesis has been demonstrated for neocortical epilepsy (Worrell et al 2004). Interictal HFO were located on the same electrodes than HFO_{60-100} activity at seizure onset and co-localize with the seizure onset zone.

- **Epileptogenicity index: quantified evaluation of $^{ictal}HFO_{12.4-97}$ enhancement**

Gamma activity at seizure onset was further developed by Bartolomei et al (2008), who demonstrated an increase of $^{ictal}HFO_{12.4-97}$ at the onset of mesio-temporal seizures recorded with SEEG electrodes. An epileptogenicity index (EI) was proposed in this paper, as a new tool to evaluate the likelihood of a brain region being involved in seizure onset. EI combined spectral and temporal parameters. It depended on the increase of fast oscillations (12.4-97 Hz) energy and low frequency oscillations (3.4-12.4Hz) energy decrease at seizure onset. This index also took into account the delay of appearance (after the onset) of gamma activity for a given structure. Epileptogenicity was normalized on the maximal value of epileptogenicity obtained for the patient.

This EI has provided many information of interest: the number of structures with high values of EI was correlated to the epilepsy duration, and to the post-resection outcome (Bartolomei et al 2008). Higher values of EI were found on lesional electrodes. EI was also applied in parietal lobe epilepsy cases and in patients suffering from hyperkinetic temporal lobe seizures to better evaluate the cortical areas underlying these different seizure types. Interestingly, higher values of EI could be found in several electrodes, classically with a network organization (Bartolomei et al 2010, Vaugier et al 2009, Aubert et al 2009). This network organization of EI seems to be more realistic than the hypothesis of very focal HFO responsible for the seizure, as described with fast ripples (Jacobs et al 2010a). However, the post-surgical outcome did not correlate with the number of electrodes of high EI, when EI was not strictly mesio-temporal. This could be explained by the fact that the EI is a composite data. As the delay of implication of a brain structure is as important as the frequency band, the role of high frequencies in epilepsy is not studied on its own.

- **Epileptogenicity mapping: imaging brain areas displaying significant $^{ictal}HFO_{60-100}$ at seizure onset**

We proposed, in David et al (2011), another quantification of epileptogenicity, based on spectral analysis of HFO_{60-100} at seizure onset. With this method, a t-test evaluated the significant activation of $^{ictal}HFO_{60-100}$ compared to a baseline, per seizure and for seizure group recorded for each patient. The

significantly activated electrodes were reported on the patient MRI and provide an anatomical cartography of seizure onset and propagation, named Epileptogenicity Map (EM). It was applied to 10 patients suffering from mesio-temporal lobe seizures, as well as in one posterior cortex and one insular lobe epilepsy. EM proved to provide an accurate picture of the SOZ. Also, for two patients with post-resection MRI, resection of ictal HFO₆₀₋₁₀₀ voxels seemed to be associated to a better post-surgical outcome.

III. OBJECTIVES

Herein, we have applied the same EM method to a series of consecutive patients undergoing intracranial EEG in a context of severe drug-resistant epilepsy between November 2009 and June 2011. We limited the study to patients who presented a spontaneous electroclinical seizure recorded with SEEG. Attention was focused on 21 patients whose surgical resection was performed. This cohort included 8 patients with temporal (or temporal plus) epilepsy, 10 with frontal lobe epilepsy and 3 posterior cortex epilepsy

- **Imaging the seizure onset zone in light of epileptogenicity mapping: are ictal HFO₆₀₋₁₀₀ systematically implied?**

Our first goal was to determine whether all patients had significant HFO₆₀₋₁₀₀ at seizure onset. Epileptogenicity mapping was performed for all seizures with a group analysis per patient.

- **Relationship between epileptogenicity maps and seizure onset zone**

In a second step, we aimed at imaging the SOZ (based on HFO₆₀₋₁₀₀ activation at seizure onset) and studied the stability of this mapping for several seizures. As no gold standard exists to delineate the SOZ, we wanted to determine whether the resection of structures significantly activated within the HFO₆₀₋₁₀₀ band could determine the surgical outcome. Eleven patients had a 3DT1 post-resection MRI, with a follow up of at least 9 months. We studied the overlap between significantly activated HFO₆₀₋₁₀₀ voxels and resection voxels for these patients. Overlap was compared for patients with good (Engel I) *versus* bad (Engel II to IV) outcome.

PATIENTS and METHODS

I. INCLUSION CRITERIA AND SOZ EVALUATION

Between November 2009 and June 2011, 27 patients suffering from severe drug-resistant epilepsy were implanted with intracranial SEEG macro-electrodes, at Grenoble University Hospital, France. SEEG exploration and implantation was determined according to clinical data, video-EEG monitoring, high resolution MRI (1.5 to 3 Tesla, Phillips), and neuropsychological examination. Most patients also underwent positron emission tomography (PET). All patients gave their informed consent for the clinical procedure before implantation. Among patients implanted, 21 were included in this study, based on the following inclusion criteria: at least one spontaneous seizure had to be recorded per patient, and patients underwent a surgical resection according to SEEG conclusions.

Intracerebral electrodes were implanted in stereotactic conditions. Preoperative targeting was performed using a 3D T1 brain MRI computed with a stereotactic software (VoximR, IVS solution, Germany), and a stereotactic and stereoscopic digitalized arteriography to determine avascular trajectories of the electrodes. Insertion of the electrodes (DIXI Médical, Besançon, France; diameter of 0,8 mm; 10 to 18 contacts, 2 mm length, 1.5 mm apart) was guided by a robotic arm (Neuromate, ISS, France) that was connected to the stereotactic frame and driven by the stereotactic software. Each electrode coordinate was expressed in the Montreal Neurological Institute (MNI) referential. All patients also underwent a per-implantation MRI, permitting the direct visualization of the trajectory of each electrode. This MRI was further used to confirm the coordinates of each lead in the MNI referential. SEEG recordings were carried out with a video-EEG monitoring system (Micromed, Trevisio, Italy) allowing to record simultaneously 256 contacts. Sampling rate was 512Hz with an acquisition band-pass filter between 0.1 and 200Hz.

II. IMAGING OF EPILEPTOGENICITY

SEEG lasted one to three weeks, in order to record, for each patient, at least one typical seizure. Anti-epileptic medication was reduced during the monitoring to favor seizure occurrence.

The Seizure Onset Zone (SOZ) was visually defined as the first clear SEEG change that occurred prior to the clinical onset of the seizure (fast synchronizing discharge with a low voltage fast activity over 20 Hz or a fast discharge of spikes).

Images transformation

All patients underwent a MRI during SEEG, co-registered with the anatomical 3DT1 MRI, and normalized into the MNI coordinates. In this way, all the electrodes contacts coordinates were expressed on the three-dimensional MNI referential, allowing further group analysis with our cohort.

Measures of epileptogenicity

In this cohort, we re-analyzed all seizures visually, in a retrospective way and apart from the pre-surgical analysis. The seizure onset was determined as the first electrical changes that precede the clinical onset of the seizure. This was defined with different possible electrical patterns: (1) low voltage fast activity (over 20 Hz) (2) rhythmic activity (around 10 Hz) of low amplitude, or (3) recruiting fast discharge of spikes and polyspikes. Baseline periods of 15 to 20 seconds were selected, 10 to 60 seconds before seizure onset, without artefact or epileptic activity, for each seizure.

As described in David et al. (2011), we aimed at evaluating the propensity of a brain region to generate an activity in the high gamma band (60-100Hz). This was carried out with an home-made toolbox compatible with Statistical Parametric Mapping (SPM) software (<http://www.fil.ion.ucl.ac.uk/spm>). Presence of ^{ictal}HFO₆₀₋₁₀₀ was quantified for each electrode contact, by transforming the raw-SEEG signal into a time/frequency chart. This time frequency chart began with seizure onset and lasted 10 seconds. A SEEG power (P) was then obtained at time t , and frequency f . This power was normalized with the mean HFO₆₀₋₁₀₀ power evaluated during the baseline, with a spectral resolution of 1 Hz. Temporal evolution of HFO₆₀₋₁₀₀ throughout the seizure was assessed for overlapping epochs (of duration $D=4$ sec), with a peri-onset time Δ from 0 to 10 s and a temporal resolution dt of 100 ms. HFO₆₀₋₁₀₀ power, evaluated for D/dt data points during the seizure onset, was compared with D/dt samples from the baseline, for each electrode channel. These data were log-transformed to obtain a normalized distribution. Statistics of the difference of log-power of fast discharges between seizure onset and baseline were obtained with a sample t-test, family-wise error (FWE) corrected to allow multiple comparisons. Results of this log transform were smoothed, and interpolated on isotropic voxels of 4mm, in order to transpose/transfer the data obtained on the patient anatomical MRI with a good precision.

Epileptogenicity was quantified for each peri-onset time Δ as the t -value of the differences in smoothed log-power between seizure and baseline. The p-value was set to 0.05 to obtain statistical significance.

This smoothed-log HFO₆₀₋₁₀₀ power was evaluated per seizure, and for all seizures at the patient level (thereafter defined as seizures group result). Several three-dimensional maps were produced, for each patient, from the significant smoothed-log HFO₆₀₋₁₀₀ at onset: maps of propagation delay, as described

in David et al. (2011), and maps of significant global maxima of HFO₆₀₋₁₀₀ activity at seizure onset. Both maps were obtained for each seizure and for the seizures group. We aimed at comparing propagation and global maxima between seizures and at evaluating the reproducibility of epileptogenicity maps over time and between seizures. These maps were represented on the patient anatomical 3DT1 MRI, normalized in the MNI referential.

Comparison of Epileptogenicity map with resection mask

Among our cohort, eleven patients who had post-surgical follow-up superior to 9 months underwent a post-resection MRI with 3DT1 sequences available. For these 11 patients, the voxels displaying significant HFO₆₀₋₁₀₀ at onset were compared (for each seizure and seizures group) with voxels resected. These resected voxels were evaluated on the post-surgical MRI, leading to a resection mask. A fusion of this resection mask with the anatomical MRI was performed.

For each patient, we evaluated the overlap between resected region (R) and areas displaying significant HFO₆₀₋₁₀₀ (Q_{HFO}).

$$O = \frac{Q_{HFO} \cap R}{Q_{HFO}}$$

However, many patients had widespread networks, and a complete resection would be illusive. In order to reach clinical relevance we limited Q_{HFO} to the brain regions displaying the 10% most significant HFO₆₀₋₁₀₀ at onset in the Epileptogenicity map.

RESULTS

I. PATIENTS MAIN CHARACTERISTICS

Anatomical location of the seizure onset zone

21 patients were selected according to the inclusion criteria described above. 8 had a SOZ in the right hemisphere, and 13 in the left. Eight suffered from temporal (n=5) or temporo-insular (n=3) epilepsy. Among 10 frontal lobe epilepsy patients, 3 had an opercular SOZ, 4 presented with a mesial frontal SOZ, and two had a frontal basal SOZ. The last patient had a widespread frontal seizure onset pattern. The SOZ was localized on temporo-occipital junction for the remaining 3 patients.

Clinical characteristics (table 1)

Patients were aged from 6 to 46 years (average 25) when they underwent SEEG exploration. Epilepsy duration was comprised between 4 and 29 years (average duration of 15.8 years), with an age at onset between 0 and 25 (average 10.5 years old).

Four patients had already overcome an epilepsy surgery. Two were implanted in order to discuss a second larger resection that became possible with awake resective surgery. Two others had a lesionectomy of a DNET (dysembryoplastic neuroepithelial tumor) but presented a poor overcome. Ten patients from the whole group were supposed to have a MRI negative epilepsy (temporal: 5, frontal: 4, posterior: 1). All of them underwent 3 Tesla MRI.

Recording conditions

SEEG duration lasted between one to three weeks. Patients were treated at the onset of SEEG with 0 to 4 antiepileptic drugs. Two patients had no antiepileptic medication during the SEEG in order to obtain seizures quickly, but they were treated before (Patient 16 because of striking difficulties to perform SEEG due to an autistic syndrome, patient 4 because only a few seizures were recorded during two previous scalp-EEG monitoring).

Patient	Sex	Age at onset(y)	Epilepsy duration(y)	Lesion on MRI	AED during SEEG	Nb of sz recorded	Surgery (cortectomy)	Outcome	Follow-up (months)
1	M	15	17	DNET	LCS ZNS CBZ CLZ	1	R temp.insular	Engel II	26
2	F	12	26	HS	LTG	3	R temp.insular	Engel IV	23
3	F	1,5	15	N	0	1	R Temp (neocort. + PHG + Hi)	Engel Ia	9
4	M	0,5	15	DNET	LCS OxCBZ CLZ	2	R Insular	Engel III	14
5	M	23	11	N	LCS ZNS CLZ	2	R mesio-temp	Engel Ib	8
6	M	18	20	N	LCS LTG	1	L Temp neocortic.	Engel IV	11
7	M	25	5	N	LCS LTG LTC	1	L temp neocort	Engel IV	5
8	F	22	4	N	LCS LTC CBZ	1	R temp	Engel II	6
9	M	12	33	N	ZNS CBZ	1	L operc.	Engel III	20
10	M	18	18	Cavernoma	LTC CBZ	3	L Basal frontal + insular	Engel Ia	18
11	M	18	12	N	LCS PB	4	L precentral+ operc.(uncomplete)	Engel IV	15
12	F	10	20	DNET	LTG CBZ	10	R frontal	/	/
13	F	10	21	N	LCS LTC OxCBZ	3	R basal frontal	Engel III	9
14	F	22	22	Stroke	CBZ	9	L mesial frontal + parasagg.	Engel IV	11
15	F	8	29	FCD	ZNS LCS PHT	5	L precentral	Engel I	8
16	M	0	9	FCD?	0	10	L basal frontal + frontal pole	Engel IV	16
17	M	2,5	4	N	CBZ OxCBZ ZNS CLZ	3	R mesial precentral	Engel Ia	14
18	F	5	7	FCD	LTC OxCBZ	3	L precentral premotor (lat+ mes)	Engel Ia	5
19	M	12	5	FCD	LCS LTC	3	L occipital	Engel Ia	18
20	M	10	8	NH	LTG CBZ	8	L occipito-temporal	Engel III	16
21	F	6	26	N	LCS FBM LZP	1	L Temp-occipital junction + temp-basal	Engel II	7

DNET (developmental neuroepithelial tumor) FCD (focal cortical dysplasia) HS (hippocampal sclerosis) N(none)
 CBZ (Carbamazepine) CLZ (Clobazam) FBM(Felbamate) LTG(Lamotrigine) LTC (Levetiracetam) LCS (lacosamide) oxCBZ (Oxcarbamazepine) PB (Phenobarbital)
 PHT(Phenytoine) ZNS(Zonisamide). L(left) R(right) Temp(temporal) Sz (seizure)

TABLE 1: Clinical characteristics from the 21 patients included

Neuropathological findings (table 2)

Twenty patients had a histopathological diagnosis after surgery. Interestingly, our group does not present the usual distribution of epileptogenic lesions, with only three patients with hippocampal sclerosis. Few patients (14.3%) had low grade-tumors, with three DNET. Most of the lesions (7 of them) were unspecific gliosis and chronic inflammatory local changes. The other cases included 6 focal cortical dysplasias (28.6%), 1 nodular heterotopia and 2 vascular lesions (cavernoma for patient 10, neonatal stroke and gliosis for patient 14).

Histopathological findings	Percentage of patients concerned	
Non specific Inflammatory changes	33,3%	Pat. 5.6.7.8.11.13.14
DNET	14,3%	Pat. 1.4.12
FCD (also diagnosed on MRI)	14,3%	Pat 16.17.19
FCD (MRI normal)	14,3%	Pat 2.9.18
Hippocampal sclerosis	4,8%	Pat. 1.2.3
Vascular lesions	9,5%	Pat 10.14
Nodular heterotopia	4,8%	Pat 20

DNET: dysembryoplastic non epithelial tumor. FCD: focal cortical dysplasia

II. EPILEPTOGENICITY MAPPING: INDIVIDUAL EVALUATION

We selected for this study all patients implanted between 2009 and 2011 who presented at least one spontaneous seizure during SEEG recordings. Our first aim was to describe significant HFO₆₀₋₁₀₀ activation at seizure onset for all seizures in each patient, and to compare this pattern with the seizure onset zone.

A. HFO₆₀₋₁₀₀ were found at seizure onset for all the patients.

HFO₆₀₋₁₀₀ were found to be significantly activated at seizure onset for all patients. This appears even convincing in our miscellaneous cohort of patients, with very different networks between patients, and no classical mesio-temporal epilepsy case (patient 2 presented hippocampal sclerosis but with temporo-insular onset). Moreover, ictal HFO₆₀₋₁₀₀ were found in the seizure onset zone, whether a lesion was diagnosed on MRI or not. This should be particularly interesting, and of clinical relevance, for MRI-negative patients, who accounted for almost half of our SEEG-studied patients. Therefore, HFO₆₀₋₁₀₀ appeared to have a core role at seizure onset, independent of the structural organization of cortex layers and anatomic area involved.

We describe here for illustration some exemplary cases of temporal+ epilepsy (one case of temporo-insular epilepsy associated to hippocampal sclerosis (patient 2), and a cryptogenic temporo-polar and frontal basal epilepsy case (patient 7)), and one posterior cortex epilepsy (Patient 19 had a left occipital seizure onset zone that co-localized with a focal cortical dysplasia)

Patient 2: temporo-insular onset (figure 1.1 A).

Patient 2 had complex febrile seizures at the age of 18 months. Seizures started 21 years later. Right hippocampal sclerosis was diagnosed on MRI. She was implanted with a hypothesis of right mesio-temporal and insular seizure onset. Epileptogenicity map highlights a “temporal-plus” network with hippocampal onset and simultaneous involvement of the anterior insular cortex for the seizure group analysis. Propagation delay map leads to the same conclusion. Right temporal cortectomy was performed with limited antero-insular resection. This patient had a poor surgical outcome (Engel IV).

Patient 7: temporobasal and orbito-frontal epilepsy (figure 1.1 B).

Patient 7 had a MRI-negative epilepsy with a complex seizure onset zone: SEEG indicated left orbitofrontal SOZ with insular and temporo-basal involvement. FDG-PET imaging was complex as well, showing a hypometabolism involving the frontal pole, lateral temporal neocortex and dorso-lateral parietal region. Epileptogenicity mapping confirmed this widely extended network, as shown on the propagation delay map. But statistical analysis at onset highlights the predominant involvement of the left orbitofrontal region. A left temporo-insular resection was decided first, because of predominant temporo-insular interictal abnormalities. Surgery did not succeed (Engel IV), and an orbito-frontal resection has been recently planned.

Frontal lobe seizures: patients 9, 13 and 18 (figure 1.2 D to F).

Patient 9 was supposed to have seizures originating in the left frontal opercular cortex with early propagation to the precentral, frontal inferior and mesial premotor regions. HFO₆₀₋₁₀₀ at onset exhibited the same network with most activity located on the opercular cortex (1D). Surgery was limited because of functional anatomical constraints (left hemispheric dominance for language) and a seizure free status was not achieved.

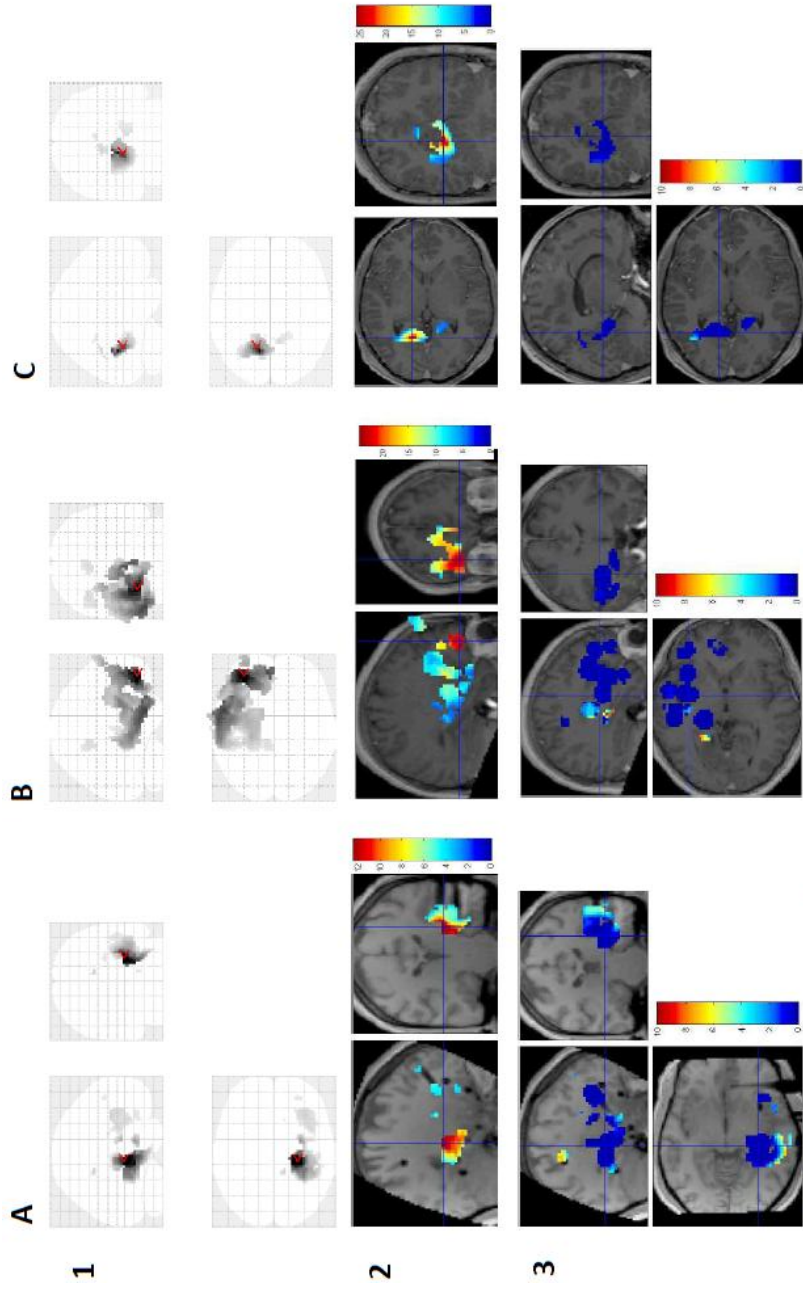


FIGURE 1.1: Most significant ictalHFO_{60-100} at onset overlaid on Epileptogenicity Map (statistical parametric map (1), and EM overlaid on MRI (2)). Propagation delay (3) is represented from $\Delta=0$ to $\Delta=10$ seconds. Patients had temporal (patient 2, A), and temporo-frontal seizures (patient 7(B), while patient 19(C) displayed left occipital network.

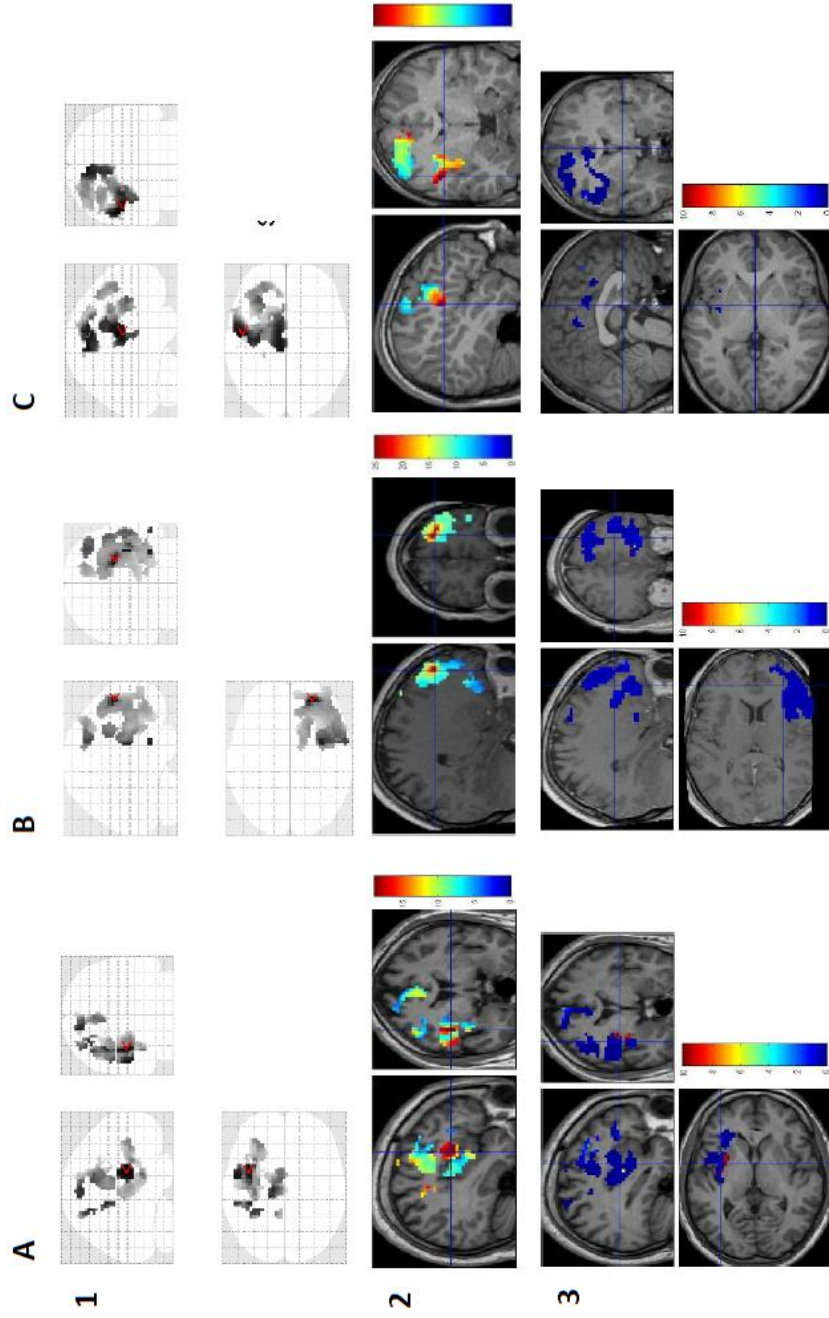


FIGURE 1.2: Most significant ictalHFO₆₀₋₁₀₀ at onset overlaid on EM (statistical parametric map (1) , MRI (2)), and propagation delay (3) from $\Delta=0$ to $\Delta=10$ seconds. All patients had frontal lobe epilepsy, with opercular (patient 9, (A)), frontal polar (patient 13,(B)) and premotor (patient 18, C) SOZ.

Seizures originated from frontal polar and frontal basal cortex in patient 13. No lesion was diagnosed on MRI, and a frontal polar resection was performed. HFO₆₀₋₁₀₀ involved the same regions, with dorsolateral prefrontal cortex involvement at onset and early propagation to orbitofrontal, frontal basal and premotor regions (1E). Patient 13 underwent a frontal polar resection sparing the frontal basal region, with an Engel III outcome.

Patient 18 had a dysplastic lesion on the left precentral cortex. Discharge originated in the left premotor cortex with involvement of supplementary motor area. Epileptogenicity map displayed similar network (1F), with mesial or lateral main activation that varied from one seizure to another. Propagation delay confirmed this premotor mesiolateral network. Large premotor surgery was performed, with an Engel class I outcome.

Patient 19: left occipital seizure onset zone (figure 1.1 C).

Patient 19 has already been described in (David et al. 2011). He presented left occipital seizures with a dysplastic lesion on the occipital mesial cortex. HFO₆₀₋₁₀₀ co-localize with the seizure onset zone diagnosed on SEEG data. Resection was carried out in this limited region and confirmed the focal cortical dysplasia. Patient 19 is seizure-free with 22 months of follow-up.

B. Relationship between epileptogenicity map and SOZ

Ictal HFO₆₀₋₁₀₀ were significantly found for all patients, but the relationship between these oscillations and the seizure onset zone has to be defined.

As previously underlined, our group of patients was very disparate. For this reason, and because of the limited number of patients included, we could not perform a group analysis, as described in David et al (2011).

Otherwise we focused on several parameters to evaluate the relationship between the SOZ and the epileptogenicity map: we compare first the SOZ as visually defined on SEEG analysis, with the localization of epileptogenicity map; then we evaluated whether HFO₆₀₋₁₀₀ and dysplastic lesions co-localized; finally, at the single patient level, we evaluated whether epileptogenicity maps exhibited a spatial stability from one seizure to another.

1. Correlation between visual analysis of SEEG and ictal HFO₆₀₋₁₀₀ activation

We assessed at the single patient level whether SEEG and epileptogenicity map had the same spatial localization. We aimed at demonstrating that electrodes supposed to be involved in low voltage fast

activity on raw SEEG displayed high epileptogenicity, based on their localization on the map of epileptogenicity.

Herein, we illustrate how we analysed the data with 5 cases, one with a temporal mesio-lateral epilepsy (patient 3), one with an insular epilepsy (patient 4), one with a frontal opercular SOZ (patient 11), one with a premotor mesial SOZ (patient 14), and one with a temporo-occipital network (patient 21). SEEG channels from electrodes contacts presenting the earlier and faster activities at onset were represented (with nearer contacts to evaluate the propagation of low voltage fast activity). For patients 3 and 21, there was only one seizure recorded. For the other 3, we chose one seizure presenting a very reproducible pattern on the epileptogenicity map (for instance, see also figure 5.2 for patient 14). Comparison was performed between epileptogenicity maps and SOZ as visually defined.

Mesio-temporal and basal temporal onset: patient 3 (figure 2.1)

Patient 3 had severe partial epilepsy since early childhood (first seizure at 17 months). She underwent a SEEG at the age of 15 years. She was implanted because the lateralization of the seizure onset zone remained unclear, with no lesion on MRI and no clear lateralization on a first FDG-PET study. Ictal SEEG recording showed a fast discharge that was prominent over the right amygdalo-hippocampal region (electrodes A and B) and over the temporo-basal cortex (electrode E on inner contacts), with early spread to the temporo-occipital junction (electrodes E and F). Seizure propagated later to the contralateral temporal lobe. SEEG conclusions pointed to a right mesial temporal and temporo-basal SOZ. Epileptogenicity map displayed a similar pattern: ictal HFO₆₀₋₁₀₀ activity was clearly prominent at onset on the right amygdalo-hippocampal complex. Propagation delay map showed early involvement of basal temporal cortex (blue spot). Left temporal mesial activation occurred four to six seconds later (light-blue and yellow spots). A right temporobasal and amygdalo-hippocampal resection was performed, and she has been seizure free for 13 months.

Patient 4: insular seizures (figure 2.2)

Patient 4 was 15 years old while undergoing SEEG recordings. He was suffering from severe partial epilepsy since the age of 6 months. A DNET was diagnosed on his MRI and a lesionectomy was performed in 2007. Because of poor surgical outcome, SEEG was decided based on the hypothesis of a right posterior insular onset. A total of fourteen electrodes were implanted, exploring insular, basal and mesial temporal regions, with 3 electrodes surrounding the lesionectomy area, and two additional electrodes on the frontal lobe to evaluate seizure spread as visualized on scalpEEG. Two seizures were recorded. We selected the first one for this comparison. On the SEEG visual evaluation, posterior insular (electrodes Z and T) and inner contacts of electrodes R, Y, X and Q (anterior insula) showed the earliest fast activity at onset. Electrode W (localized around the previous lesionectomy) only

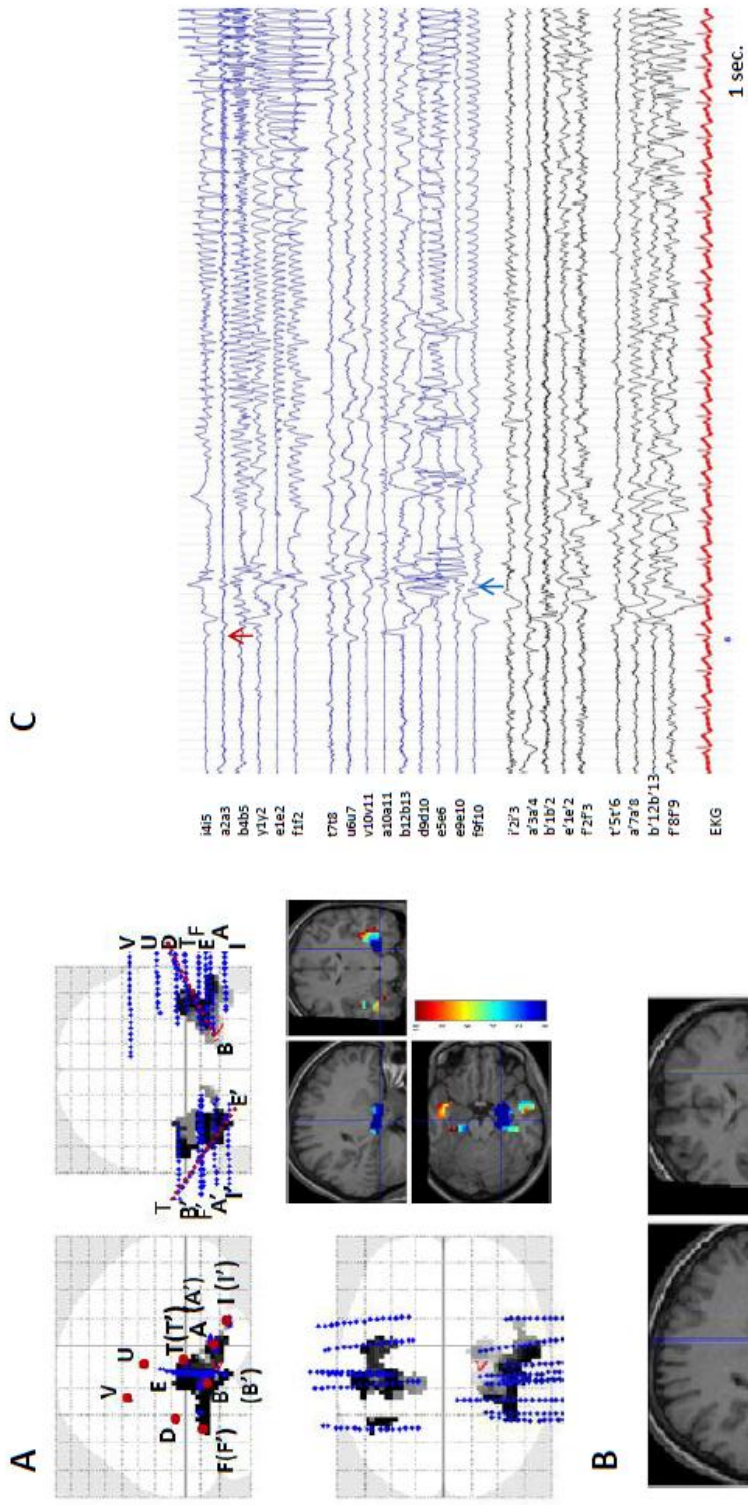


FIGURE 2.1: patient 3

Map of seizure propagation delay (A), and significant EM at (B), compared with SEEG (C).

Left amygdalo-hippocampal (A, B int.) and basal contacts (E, F) presented the earliest fast activity, with early propagation to neocortical cortex and temporo-occipital junction (A). Right temporo-mesial cortex (black channels) was involved but to a lesser extent.

Left amygdalo-hippocampal and basal contacts were similarly included on the HFO₆₀₋₁₀₀ activation at onset ($\Delta=0$). The temporo-occipital junction was involved two seconds later.

showed a discrete involvement. Electrode contacts over the temporo-parietal junction (electrode U) and the operculum (external contacts from X, Y, and Z) displayed a poor activity. This pattern of fast activity was represented quite similarly with epileptogenicity mapping: the most significant epileptogenicity at onset was localized in the insular cortex, but slightly more anteriorly (electrodes R and Q). Both SEEG and epileptogenicity map lead to the same conclusion concerning the seizure onset zone. A postero-insular resection was performed, and patient 4 was not seizure free (Engel III).

Patient 11: precentral and opercular involvement (figure 2.3).

One typical and reproducible seizure from patient 11 was compared with visual SEEG analysis and epileptogenicity map. A wide bilateral implantation was performed, with a hypothesis of left frontal opercular and premotor involvement at onset. This was confirmed with SEEG analysis, which showed an early low voltage fast activity at onset over the frontal opercular cortex (electrode S', R' and Q'), and frontal dorsolateral channels (lateral contacts of H'). Epileptogenicity map lead to similar conclusions: a large network was activated at onset (as shown in (A) on propagation delay map: light-grey spots on the upper map, blue activation on the MRI). But two regions had the most significant ictal HFO₆₀₋₁₀₀ activation (see (B)). Main epileptogenicity was localized on the frontal operculum, but premotor cortex (electrodes H', F', G' on external contacts) displayed early and significant HFO₆₀₋₁₀₀ activity as well. Therefore, the epileptogenicity map mirrored accurately a very complex frontal SOZ. In this case, HFO₆₀₋₁₀₀ map could help to organize and rank different parts of the seizure onset zone, with the most significant activation at onset on the frontal opercular cortex. Partial resection of the EZ was performed, since functional area co-localized with epileptogenic cortex. Patient involvement was insufficient to complete the per-operative stimulations. There was no significant improvement after surgery (Engel IV class)

Patient 14 (figure 2.4): mesial frontal seizure onset zone.

This patient had a neonatal stroke responsible for a large frontal lesion on the left hemisphere. Epilepsy started at the age of 7, and frontal implantation was carried out due to drug-resistance. We compared rapid discharge on SEEG with HFO₆₀₋₁₀₀ at onset for seizure 5, which belonged to very reproducible group of seizures. SEEG analysis concluded to a premotor network focused on F1-F2 sulcus (L'5-6) with a prominent frontal mesial cortex involvement (L'3-4, M'2-3, H'1-2). There was no opercular activity. On the epileptogenicity map, inner contacts of electrodes L', M', and H' were similarly included on the ictal HFO₆₀₋₁₀₀ activation. Significant HFO₆₀₋₁₀₀ activity at onset had the same localization than the one visually described on SEEG analysis. Early spread to more peripheral contacts was noticed both with epileptogenicity map and raw SEEG data. A frontal mesial resection

was performed. Different seizures started some weeks later and the hypothesis of bilateral SOZ was raised.

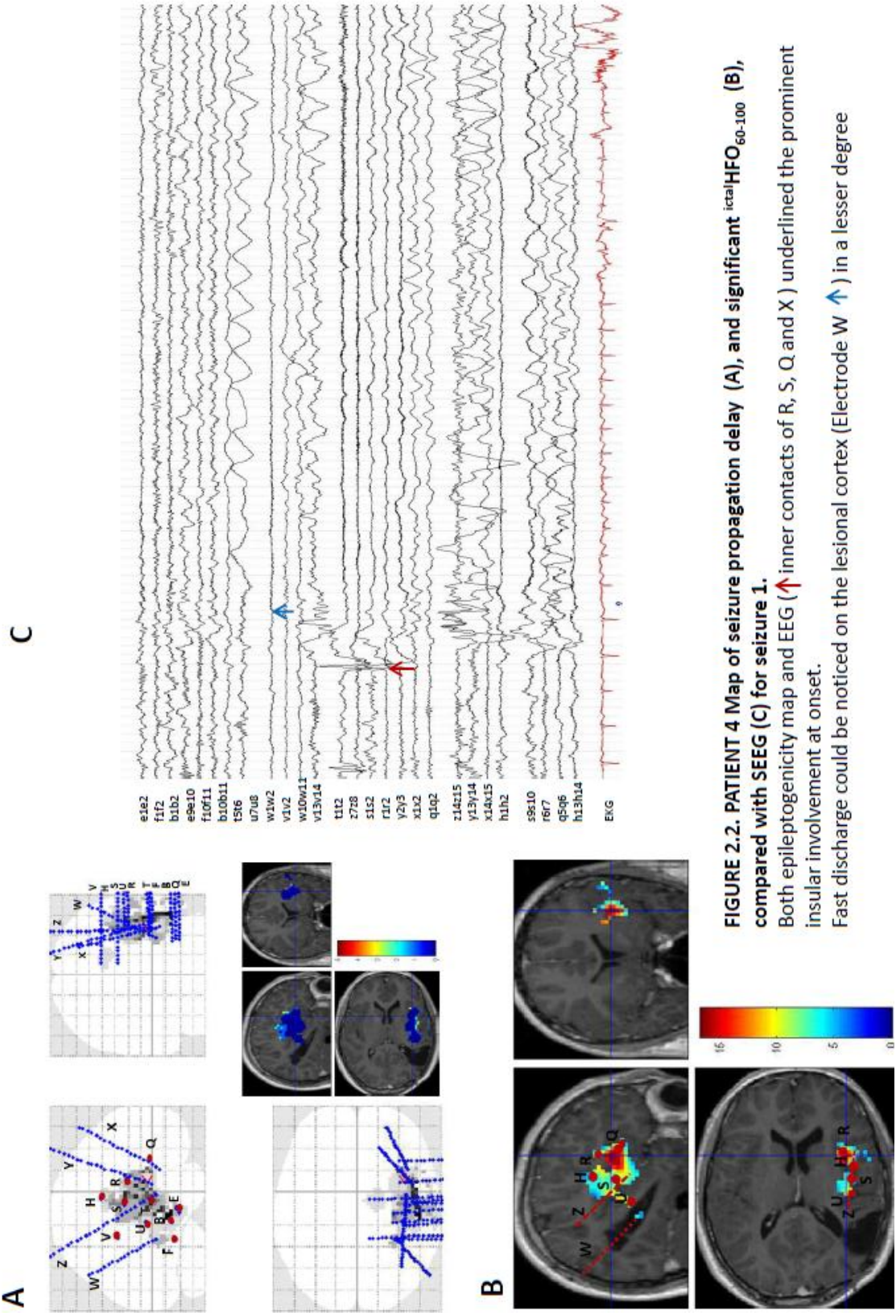


FIGURE 2.2. PATIENT 4 Map of seizure propagation delay (A), and significant ictal HFO₆₀₋₁₀₀ (B), compared with SEEG (C) for seizure 1.
 Both epileptogenicity map and EEG (↑ inner contacts of R, S, Q and X) underlined the prominent insular involvement at onset.
 Fast discharge could be noticed on the lesional cortex (Electrode W ↑) in a lesser degree

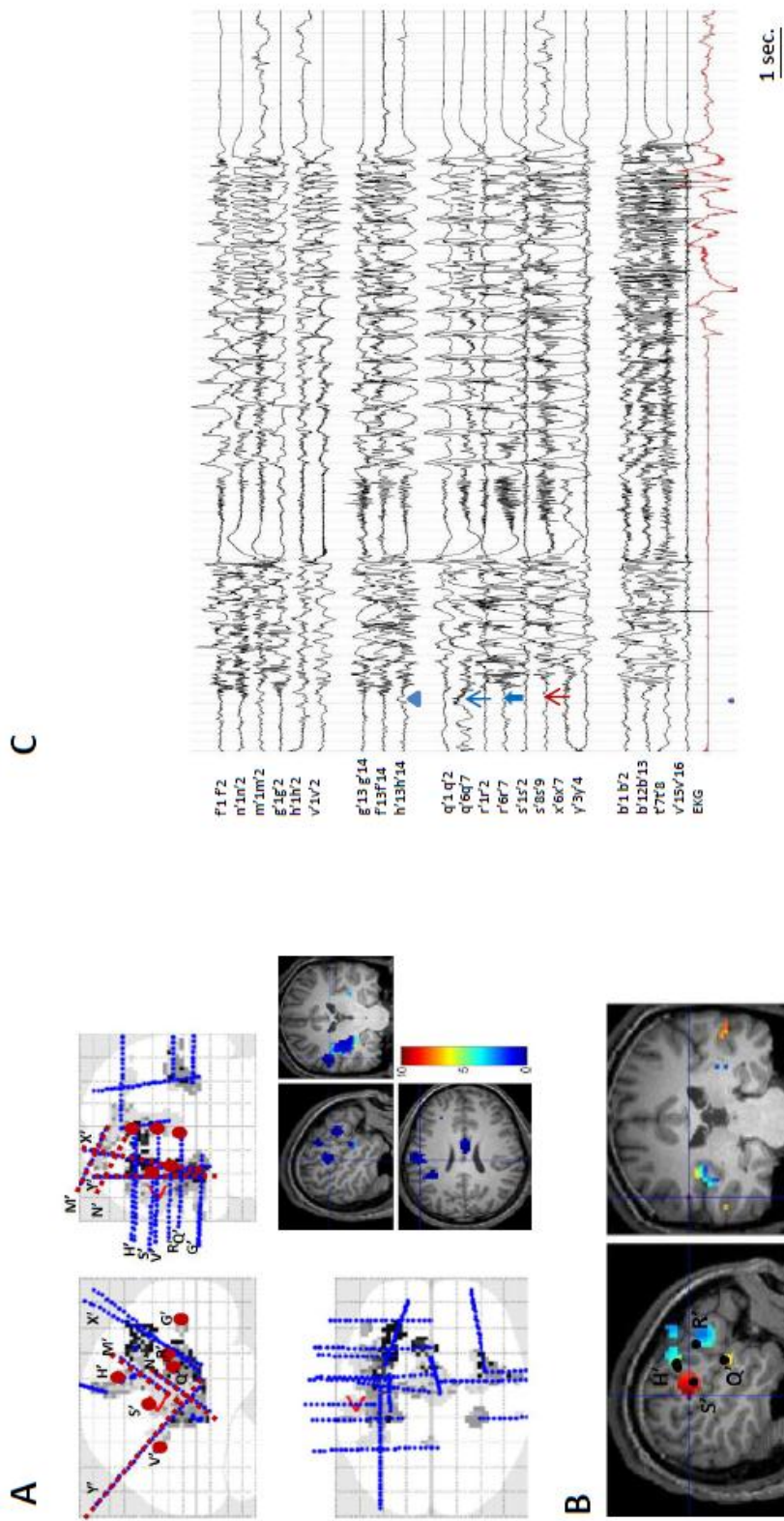


FIGURE 2.3: PATIENT 11
 Map of seizure propagation delay estimated from the analysis of all seizures (A), and significant ictalHFO_{60-100} on the EM for seizure 2 (B), compared with SEEG (C). Four spots on the EM corresponded to left opetcular S' (↑ external leads), R' (↑ external contacts), and Q' (↑ ext) discharge with lateral premotor H'ext. (▲) low voltage fast activity at onset ($\Delta=0$). Conclusions were the same with SEEG, but EM enhanced S' peripheral contacts' involvement.

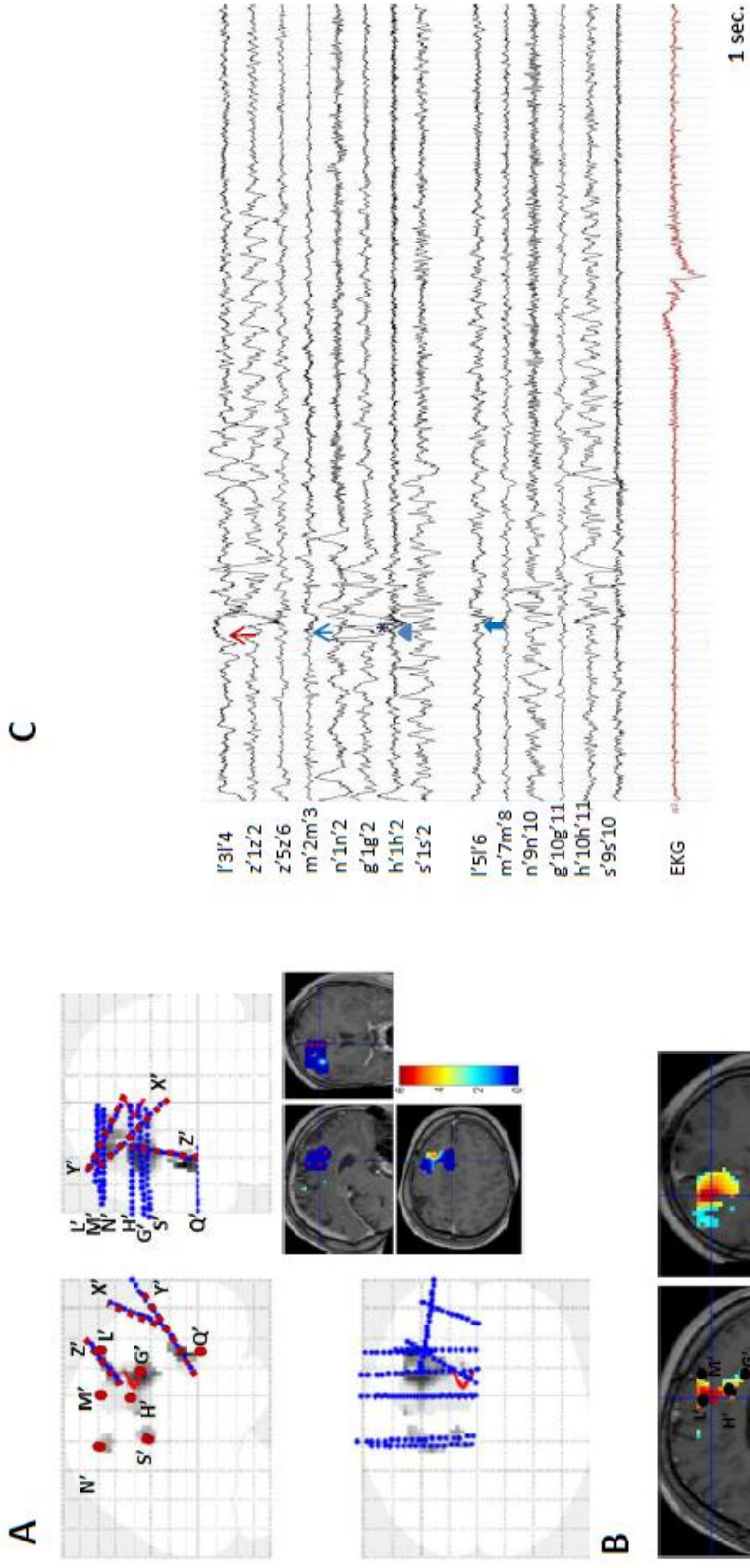


FIGURE 2.4. PATIENT 14: Map of seizure propagation delay estimated from the analysis of all seizures (A), and significant epileptogenicity map at onset for seizure 5 (B), compared with raw SEEG from seizure 8 (C). Inner contacts of electrodes L', M', H', and G' were included on the ictal HFO₆₀₋₁₀₀ activation. Same pattern was shown with SEEG: fast activity associated to slow waves was present on frontal mesial cortex (L'3-4, M'2-3, H'1-2, and later G'1-2*). More external contacts also localized on the F1-F2 sulcus (L'5-6, H'1-2, S'9-10) were involved with similar fast activity followed by slow waves. Central contacts displayed fast activity (N' S')

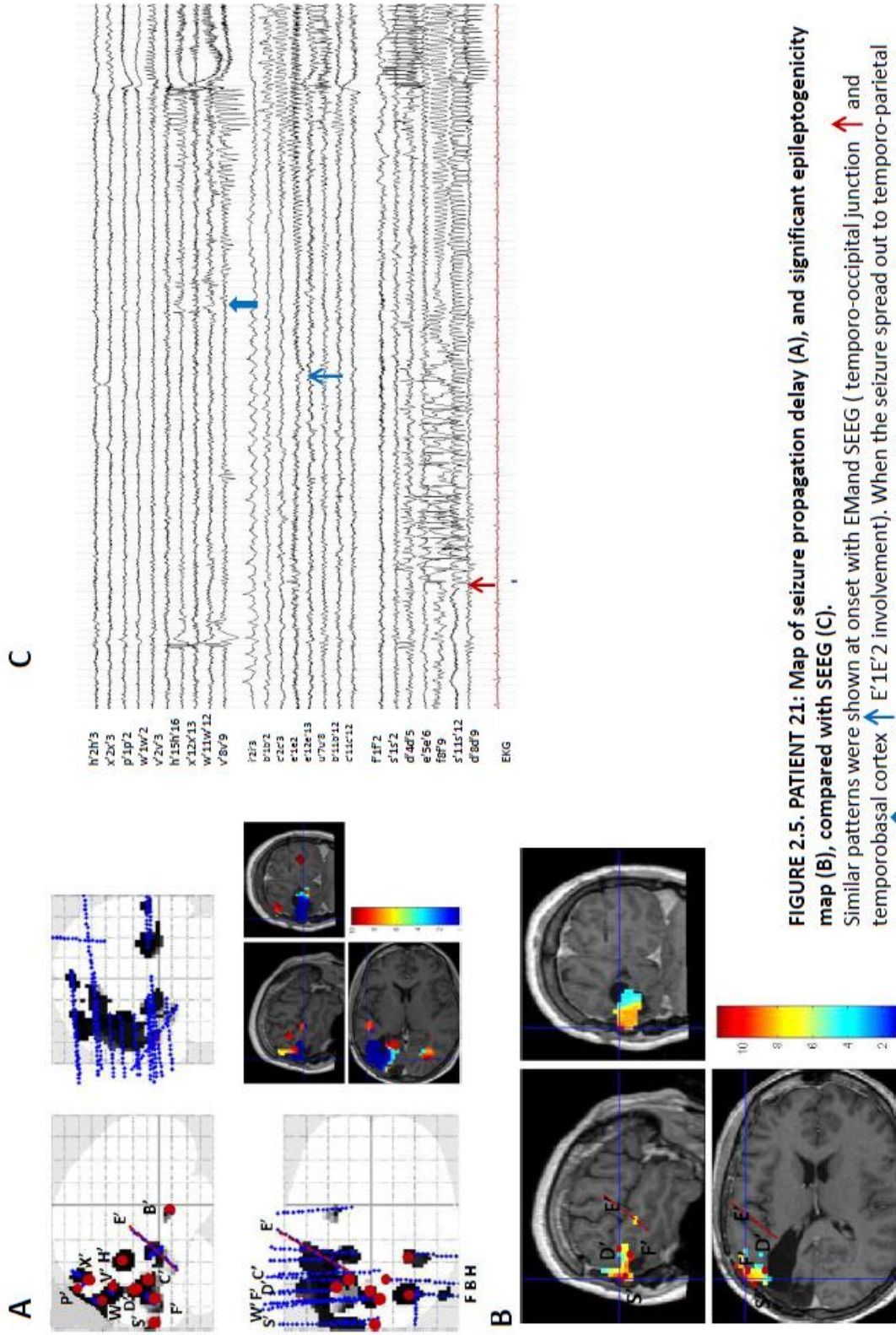


FIGURE 2.5. PATIENT 21: Map of seizure propagation delay (A), and significant epileptogenicity map (B), compared with SEEG (C). Similar patterns were shown at onset with EM and SEEG (temporo-occipital junction \uparrow and temporobasal cortex \uparrow E'1E'2 involvement). When the seizure spread out to temporo-parietal junction (\uparrow and yellow spot on the propagation delay) similar networks were underlined with both SEEG and EM.

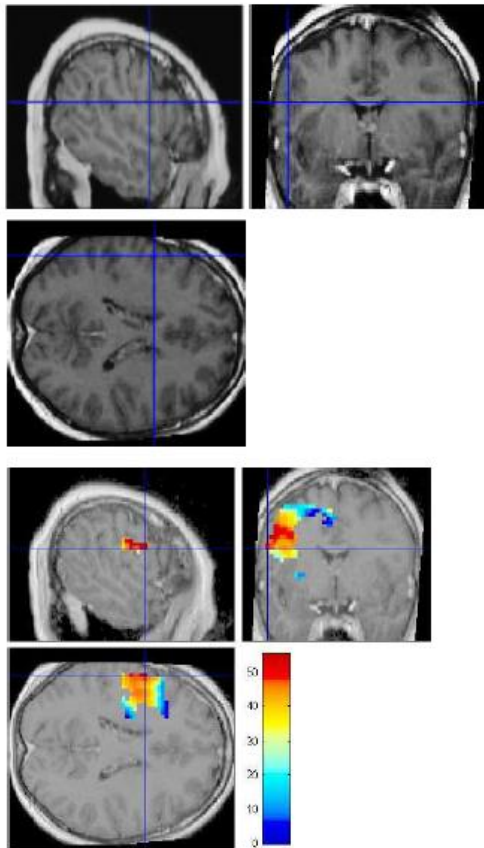
Patient 21 (figure 2.5) underwent a second SEEG study after a first surgery performed in 1998. A first SEEG showed a bilateral occipital SOZ with rapid involvement of basal temporal region. A left occipital cortectomy was performed but was limited due to functional anatomical constraints. Epilepsy became more severe over the years and a second implantation was finally decided. Based on SEEG analysis, the seizure started on the left lateral temporo-occipital junction (peripheral contacts of S', F', D'), with early propagation to the basal temporal cortex (E'1-2). Rapid involvement of temporo-parietal junction (V'8-9) was noticed. Right activation occurred 13 seconds after the onset. Epileptogenicity map was significant on the same electrode contacts: maximum of epileptogenicity was localized on S', D' and F', with a spread to the temporo-parietal and temporo-basal (inner E') areas. After surgery, a dysplastic lesion within the temporo-occipital junction was diagnosed on histopathological specimen. This lesion was not observed on the MRI, but co-localizes with the most significant ictal HFO₆₀₋₁₀₀ (electrodes F' S' and D'). She was supposed to be in Engel II class but with a short follow-up (6 months)

In these 5 patients, comparison between seizure onset zone (defined independently on electrophysiological findings) and epileptogenicity maps revealed, as previously described, high spatial correlation. Ictal HFO₆₀₋₁₀₀ included in map of epileptogenicity appeared to reflect electrophysiological conclusions, and might help to rank in an objective way simultaneous fast activities on their power degree.

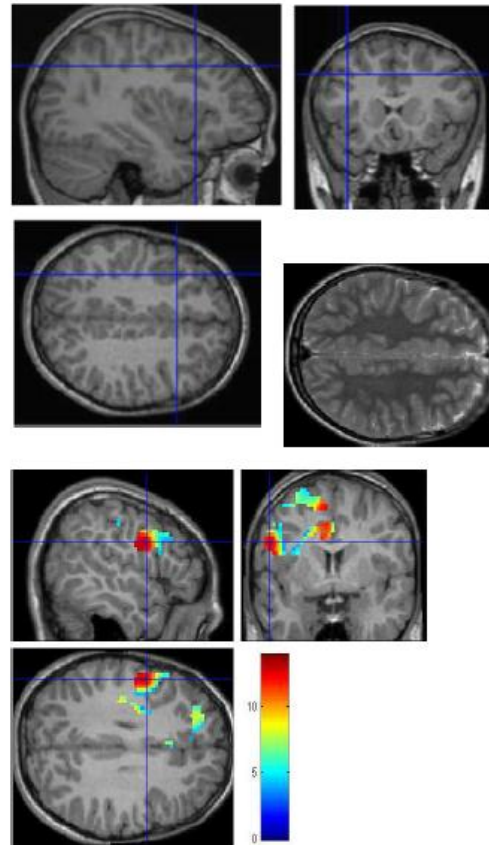
2. Patients with epileptogenic lesion: example of focal cortical dysplasia (*Figure 3*).

Since the seizure onset zone definition based on visual analysis remains subjective, we assessed the value of epileptogenicity mapping based on epileptogenic lesions. Focal cortical dysplasia (FCD), in particular, are known to have a high level of epileptogenicity (Palmini et al 1995), and their spatial extent closely correlates with the epileptogenic zone. In Chassoux et al (2000), a good surgical outcome for medically intractable epilepsy was significantly associated to the FCD. For this reason, we hypothesized that significant ictal HFO₆₀₋₁₀₀ could localize with the extent of FCD as evaluated on MRI, this would confirm the intrinsic value of this method to define the SOZ. Localization of epileptogenicity map and lesion were visually compared for the three patients concerned. We focused on the significant epileptogenic areas ($p=0.05$, family-wise error (FWE) corrected) at seizure onset ($\Delta=0$ sec) for the group of seizures, for each patient. We did not choose the propagation delay, because this representation rather showed the network involved and could not allow us to determine focal epileptogenic zones as suspected for FCD. Two patients had a frontal lesion (patients 15 and 18), one an occipital (Patient 19). Comparison between epileptogenicity map and FCD extent showed a high anatomical correlation, as presented in *Figure 3*. The most significant (patient 15 and 19) or almost most significant (patient 18) map of epileptogenicity at seizure onset had the same localization than the lesion. Mapping of epileptogenicity appeared to be highly specific for the lesion. As FCD are known to have an intrinsic epileptogenicity, we may conclude that epileptogenicity map was highly specific of the epileptogenic zone. However, epileptogenicity map sometimes extended beyond the lesion, with brain regions displaying less significant epileptogenicity: These three patients, however, had a limited resection including the FCD, and all are seizure-free. Epileptogenicity map on the earliest and most significant regions might be thus relevant to delineate the extent of the resection but whether such a conclusion in FCD cases can be applied also in MRI negative cases remain a debatable issue.

PATIENT 15



PATIENT 18



PATIENT 19

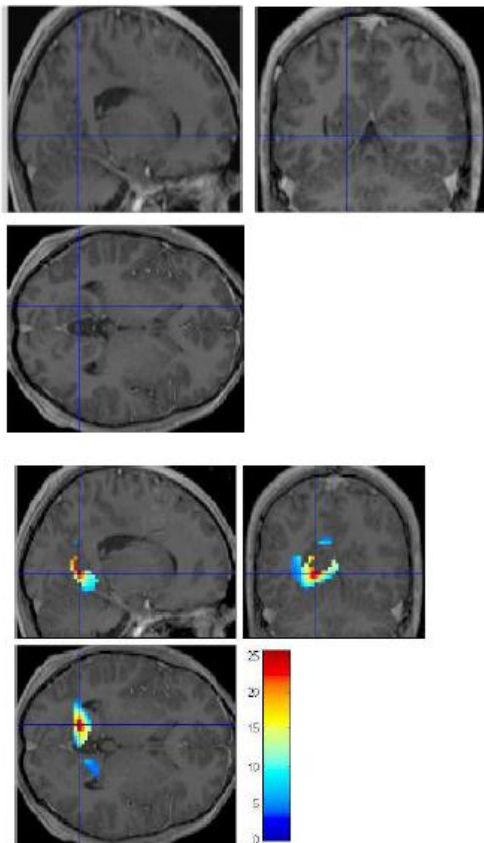


Figure 3: Visual comparison between most significant ictalHFO_{60-100} for the seizure group, and anatomical topography of the FCD on MRI. High correlation could be found between EM and FCD. Please note that ictalHFO_{60-100} was most (or nearly most for patient 18) significant on the dysplastic lesion.

3. Spatial stability of epileptogenicity maps between seizures

In our patients, one to ten seizures were recorded (average 3.47). Herein, we assessed spatial stability of epileptogenicity map over time and seizures, when more than two seizures were recorded for one patient. We assume the idea that spatial stability of epileptogenicity map might reflect the stereotyped nature of seizure initiation. Here we present 4 illustrative cases to show this stability. All these patients were selected because of their relative high number of seizures recorded. Most patients presented one – sometimes two - precise and reproducible ictal HFO₆₀₋₁₀₀ patterns at seizure onset. Those seizures were reproducible with epileptogenicity maps as well as using visual analysis. This high reproducibility was confirmed even when the vigilance state preceding the seizure varied, and with antiepileptic medication reduction.

Patient 12 (figure 4.1) had a second SEEG, with the aim of a second resective surgery. The first removal, limited to parietal lesionectomy of DNET, had failed. The main hypothesis was a residual epileptogenic area involving the frontal peri-sylvian region. More than ten seizures were recorded during the SEEG study, on the 13th day after electrodes implantation (seizure 1), on day 17 (seizures 2 to 4) and on day 18 (seizures 5 to 10). Seizure 1 was obtained with partial medication reduction, while the patient was awake. The other seizures occurred while the medication had been stopped, and during wakefulness. Three main patterns of predominant ictal HFO₆₀₋₁₀₀ were observed, with an opercular and premotor cortex predominant spread. Medication dosage did not seem to influence these patterns, as seizure 1 had the same organization (and even larger network) than seizure 10. Note that although last seizures (8-9-10) occurred in a status epilepticus, seizure patterns remained very stable and reproducible. Only the first seizures of status were selected for evaluation, in order to avoid unusual propagation due to status.

Nine seizures were analyzed using ictal HFO₆₀₋₁₀₀ for **patient 14 (figure 4.2)**. Four seizures did not display significant HFO₆₀₋₁₀₀ with family-wise error correction. Otherwise, ictal HFO₆₀₋₁₀₀ was found with $p < 0.05$ without correction. All seizures had similar SOZ and network. Seizures were recorded between 3 and 7 days after implantation, with the same medication. Seizures remain the same all along the intracranial investigation.

Patient 16 (figure 4.3) had a particular history because of autistic syndrome and epileptic spasms. Complete withdrawal of anti-epileptic drug was performed on the day following electrode implantation. Seizures were recorded on the third day following implantation. The seven first seizures were recorded during wakefulness, last seizures during slow-wave sleep. A large left frontal network was involved at seizure onset, with two SOZ (fronto-polar and fronto-basal). Behavioral parameters such as sleep or waking state did not seem to influence the seizure onset zone and propagation.

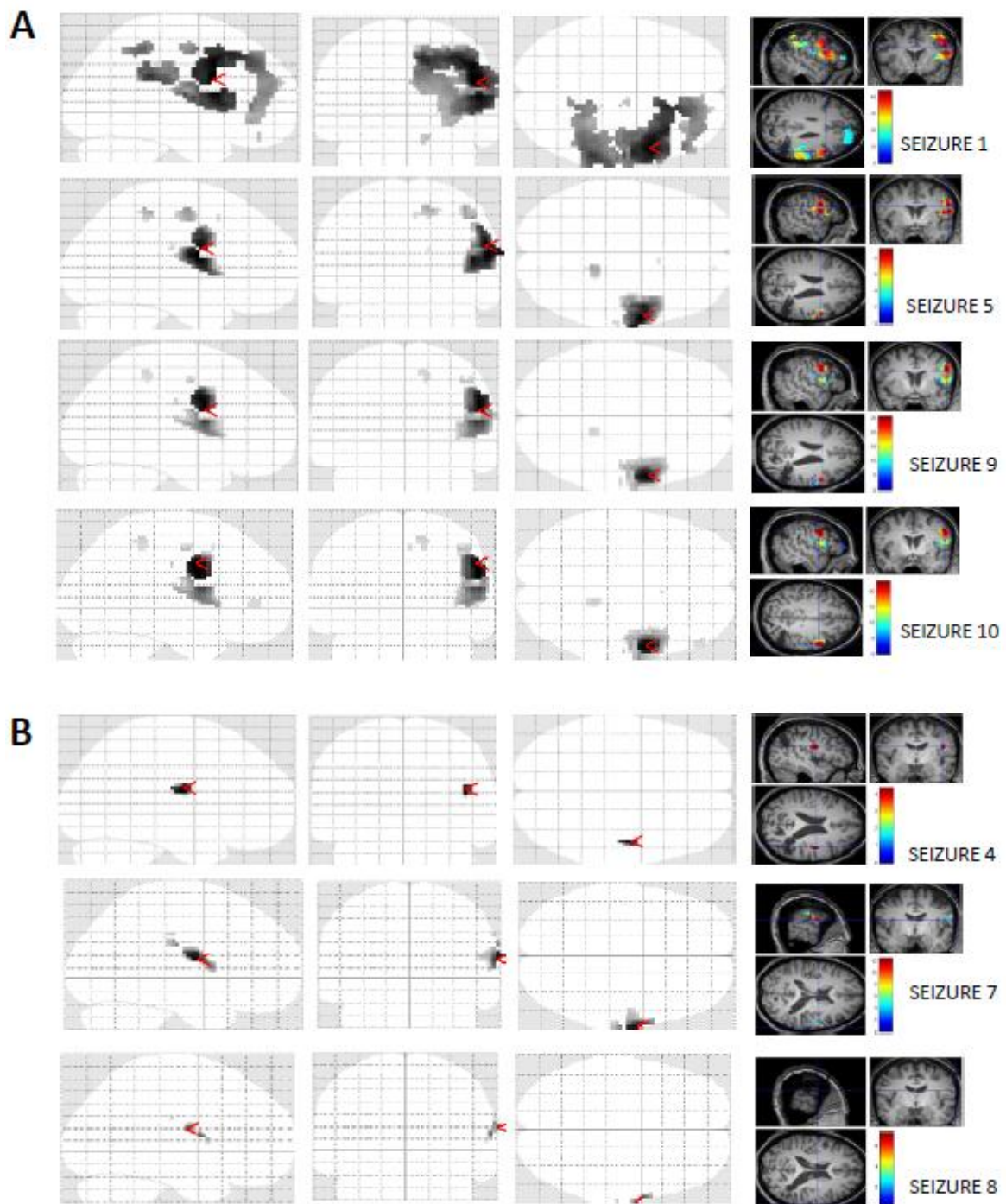


FIGURE 4.1A: PATIENT 12

SPATIAL STABILITY OF ictal HFO₆₀₋₁₀₀ FOR ALL SEIZURES

(A) MAIN ictal HFO₆₀₋₁₀₀ PATTERN : main HFO were found on right premotor and frontal opercular regions

(B) SIGNIFICANT ictal HFO₆₀₋₁₀₀ : second pattern involving lateral opercular cortex.

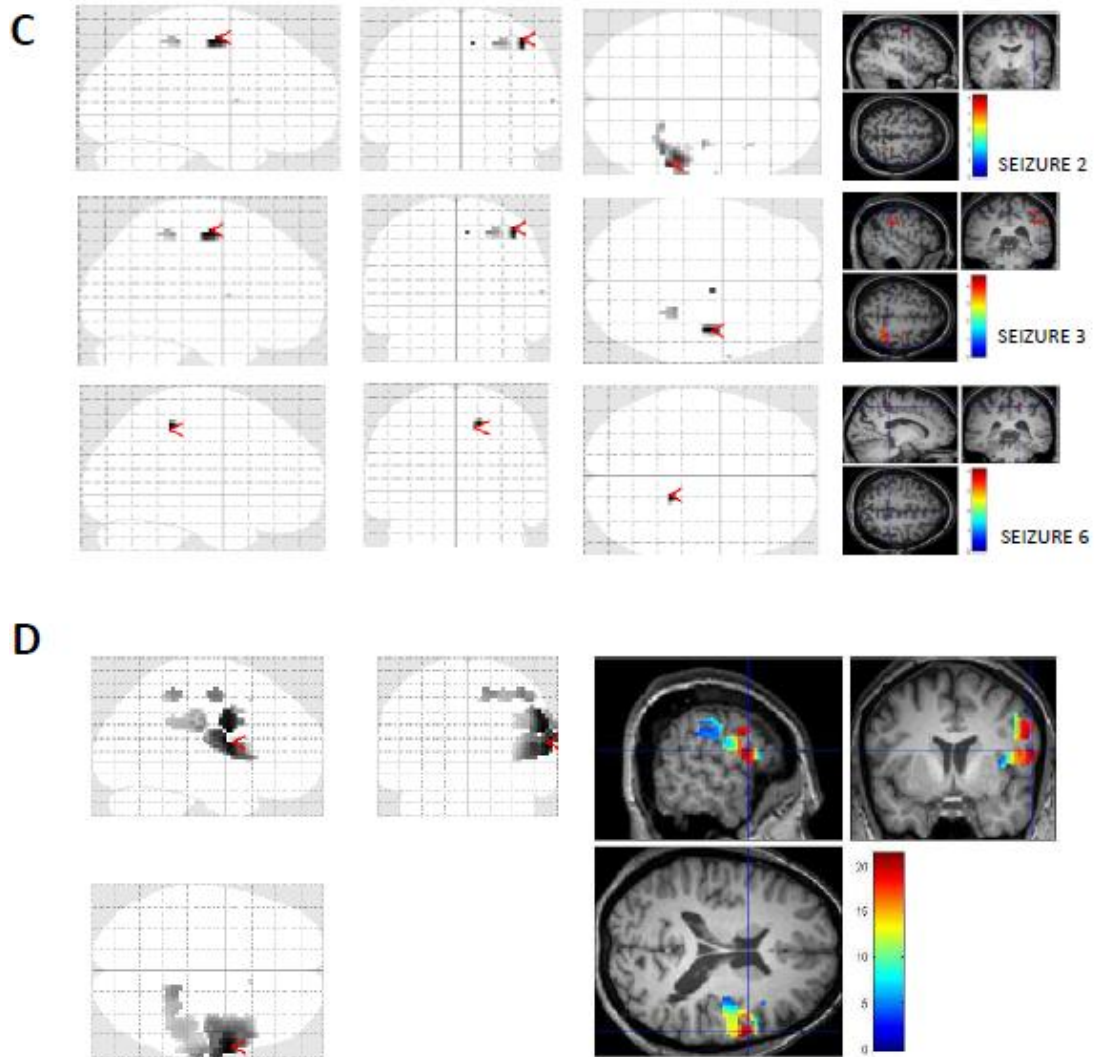


FIGURE 4.1B : PATIENT 12
 SPATIAL STABILITY OF ictalHFO₆₀₋₁₀₀ FOR ALL SEIZURES

(C) SIGNIFICANT ictalHFO₆₀₋₁₀₀ : CENTRAL HFO₆₀₋₁₀₀ PATTERN

(D) EPILEPTOGENICITY MAPPING AT ONSET FOR THE SEIZURES GROUP:

same opercular, premotor (red spots) and central involvement (blue region) were shown.

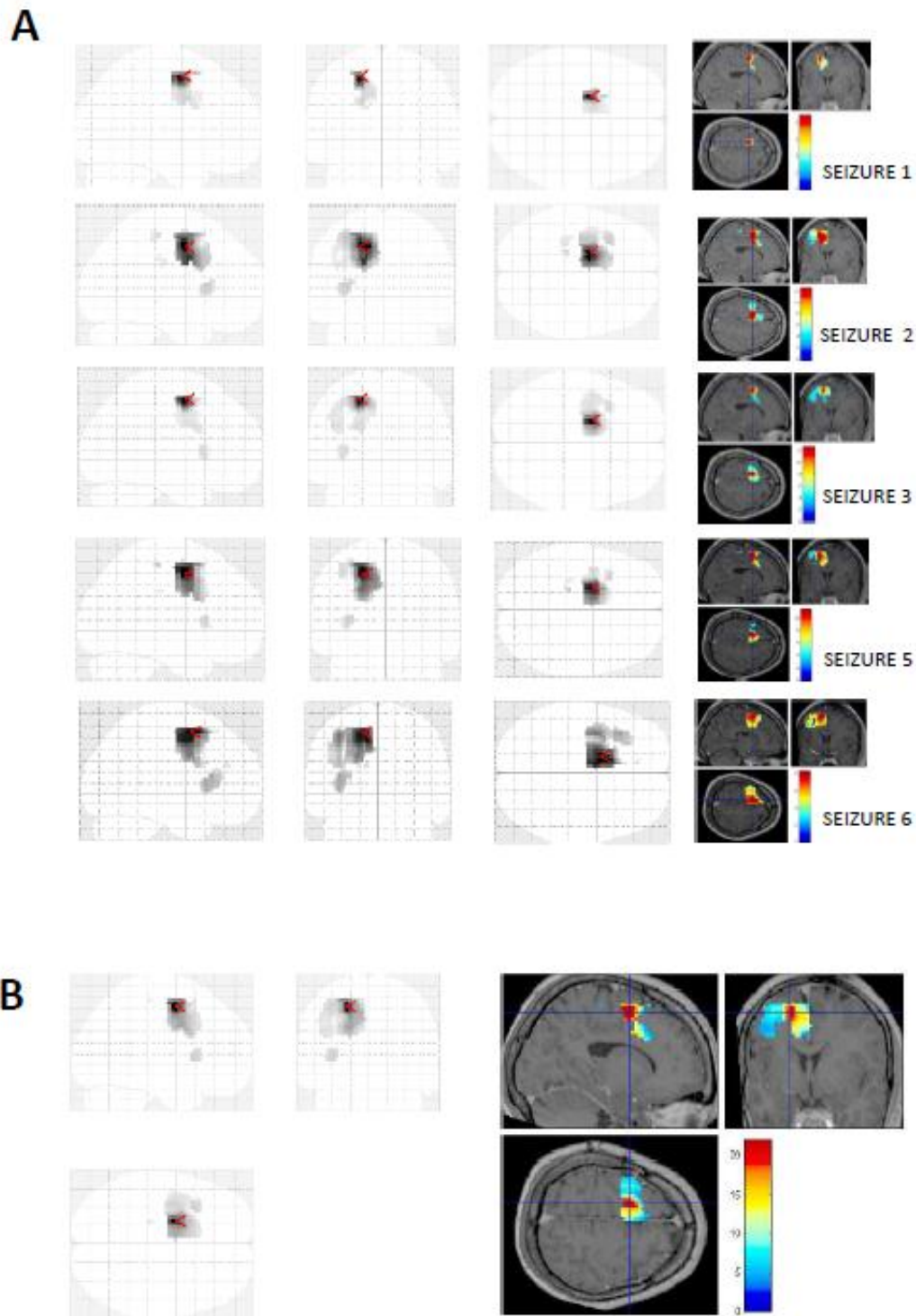


FIGURE 4.2 : PATIENT 14

SPATIAL STABILITY OF $ictalHFO_{60-100}$ FOR ALL SEIZURES: significant HFO activity was spatially stable over the SEEG period. (There were no significant HFO for seizures 1, 3, 5 and 6.)

(B) SIGNIFICANT $ictalHFO_{60-100}$ FOR THE SEIZURES GROUP (1 to 9) displayed the same network.




FIGURE 4.3: PATIENT 16: SPATIAL STABILITY OF ictalHFO₆₀₋₁₀₀ FOR ALL SEIZURES
 Similar HFO activation was found at onset, but with two different SOZ: lateral premotor activation for (A), basal frontal activation for seizures included in (B) Seizures indicated with * occurred during slow-wave sleep. (C) indicated the EM quantified for the seizures group.

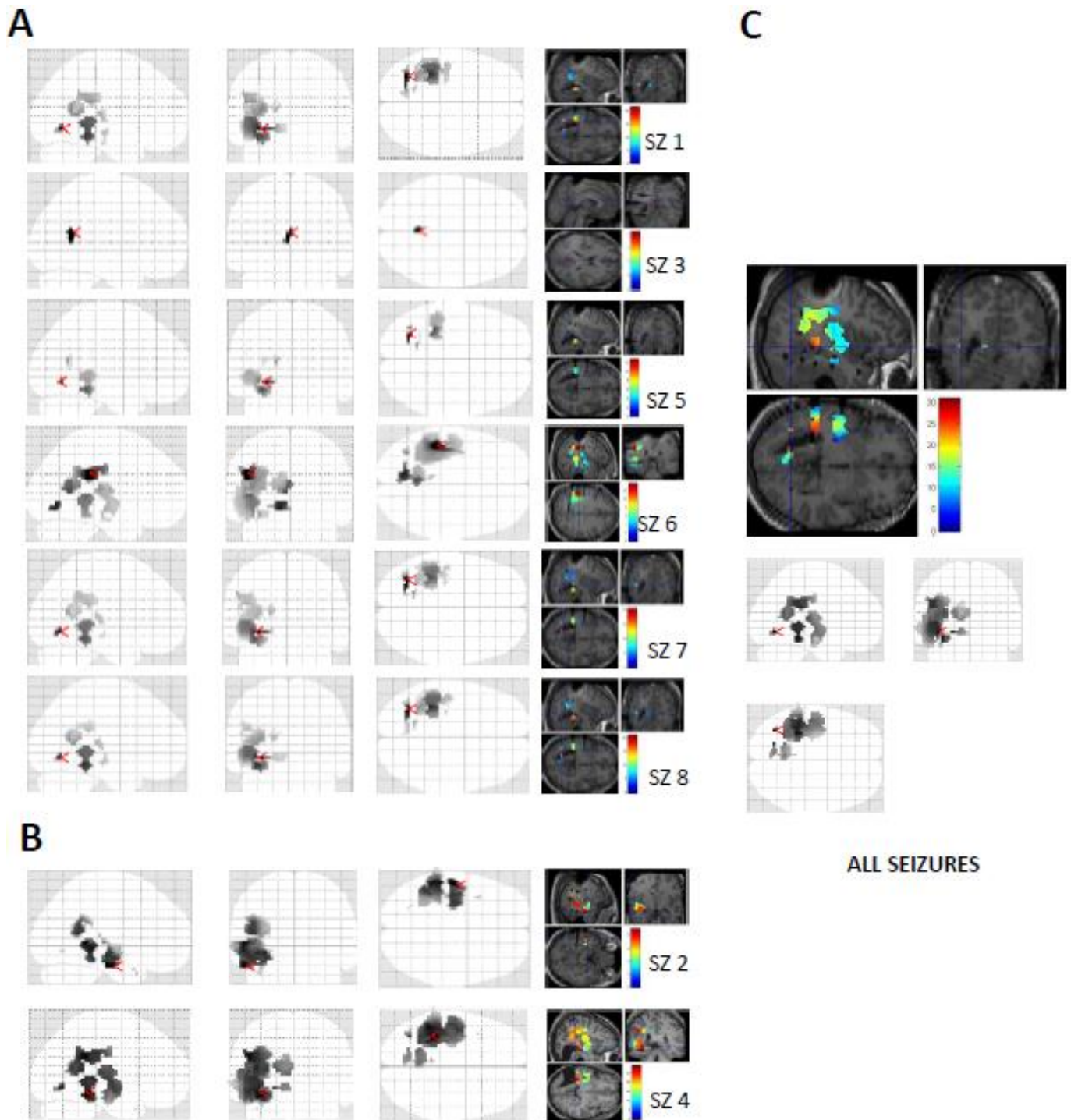


FIGURE 4.4: PATIENT 20

(A) SPATIAL STABILITY OF ictal HFO₆₀₋₁₀₀ SIGNIFICANT ictal HFO₆₀₋₁₀₀ FOR SEIZURES 1, 3 and 5 to 8 : main pattern of seizures started on the nodular heterotopia.

(B) SIGNIFICANT ictal HFO₆₀₋₁₀₀ FOR SEIZURES 2 and 4 : most significant HFO was localized on basal temporal region

(C) SIGNIFICANT ictal HFO₆₀₋₁₀₀ FOR THE SEIZURES GROUP revealed ictal HFO₆₀₋₁₀₀ on the nodular heterotopia with temporo-basal involvement at onset and propagation to parietal region.

Finally, patient 20 (figure 4.4) had left occipital seizures associated to nodular heterotopia. Seizures occurred on days 3 to 7, on waking state. Again, a high spatial stability was noticed during those 5 days, whereas medication dosage was progressively decreased.

Overall, HFO₆₀₋₁₀₀ activity was found for all seizures and patients, and epileptogenicity maps highly correlated with the SOZ, based on lesional and visual inspection of SEEG recordings. A spatial stability of ictal HFO₆₀₋₁₀₀ was also found from one seizure to another one in a given patient, which reinforces the idea that close relationships exist between epileptogenicity map and the seizure onset zone. This stability did not seem to depend on the vigilance state nor on the level of medication, but our group of patients was too restricted for statistical analysis.

4. Removal of areas with significant HFO₆₀₋₁₀₀ activity is associated to good surgical outcome.

The definition of the SOZ in routine, based on visual inspection of SEEG recordings, depends on the experience of the clinician who is interpreting the data. There is no clear consensus on the electrophysiological criteria that univocally point to the SOZ, so that a pragmatic way to evaluate the interest of epileptogenicity maps in clinical practice is to compare them with the extent of the resection and outcome. We therefore compared brain regions displaying most significant ictal HFO₆₀₋₁₀₀ to the resection mask. Ratio resulting from this comparison was studied according to the surgical outcome in the 11 patients in whom post-operative follow-up was long enough (at least 9 months) (*Figure 5*). Six patients had Engel I outcome, with a large ratio of resected ictal HFO₆₀₋₁₀₀. The others patients in whom surgery failed (Engel III and IV outcome) had a low ratio and most brain regions displaying HFO₆₀₋₁₀₀ were spared by surgery. For all patients, outcome appeared to be related to this ratio, with a real tendency from Engel IV (and low ratio) to Engel I (with high ratio values).

These results support the idea that surgical outcome depends on the amount of cortical areas exhibiting significant ictal HFO₆₀₋₁₀₀ that have been resected. In others words, the more HFO voxels are resected, the better outcome will be. When surgery includes most of ictal HFO₆₀₋₁₀₀ areas, patients are likely to have a better outcome.

Although our group was of limited size, the relationship between resection of epileptogenic areas based on this cartography and outcome strongly suggest that epileptogenicity map is not only a marker of the the seizure onset zone, but also of the epileptogenic area i.e. that has to be removed to render the patients seizure-free).

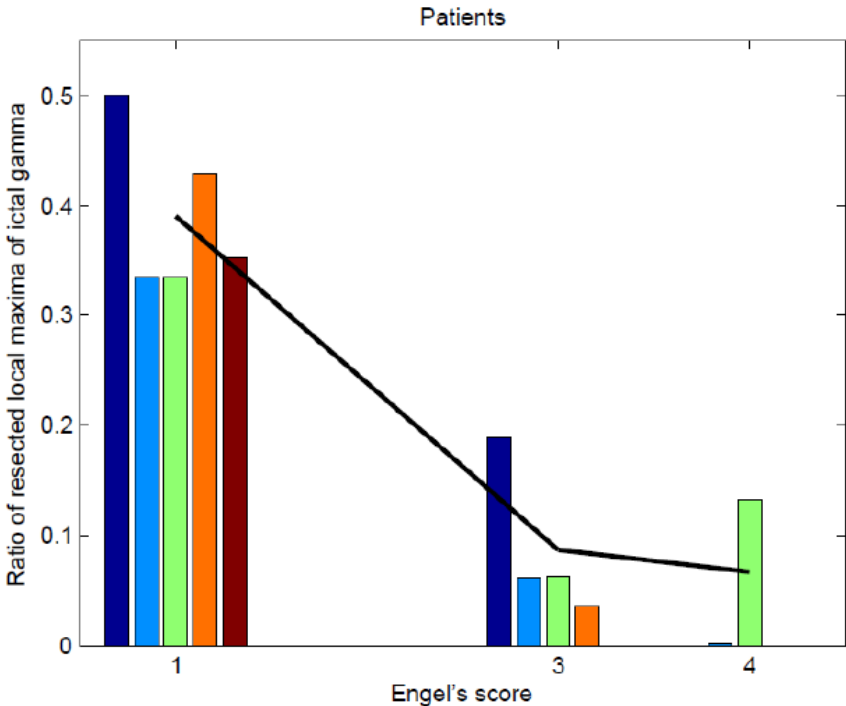


FIGURE 5 : Relationship between the ratio of resected ictalHFO₆₀₋₁₀₀ and surgical outcome, based on 11 patients.

Engel score (from Engel I= seizure free to Engel IV) correlated with the ratio of resected ictalHFO₆₀₋₁₀₀

DISCUSSION:

Involvement of fast activities at seizure onset has been described for 20 years (Fischer et al 1992, Lee et al 2000), and seems to be associated to the low voltage fast discharge defined visually at onset on SEEG. Although clinical relevance of fast discharges to define the SOZ was highly suspected, it has never been formally assessed. This study proposed to quantify the power of fast discharges in the 60-100 Hz band. We aimed at evaluating the clinical value of ictal fast activity at seizure onset, by comparing $^{ictal}HFO_{60-100}$ defined on epileptogenicity maps, with the SOZ defined visually.

I. ICTAL ACTIVATION OF HFO_{60-100} IS SIGNIFICANT FOR ALL PATIENTS

A. Why should we further focus on ictal HFO_{60-100} ?

From 21 patients selected independently of their seizure onset zone, we found significant $^{ictal}HFO_{60-100}$ oscillations for all of them. We focused on HFO_{60-100} frequencies, as these frequencies have already been described as the dominant spectral peak at onset in neocortical seizures (Worrell et al 2004). Furthermore, while wondering which frequencies are of interest at seizure onset, Gnatovsky et al (2011) showed that most patients had significant oscillations below 100 Hz.

The fact that $^{ictal}HFO_{60-100}$ are always activated at onset has not been previously described with SEEG and for all seizure localisations and different aetiologies.

Moreover, this systematic activation was not reported with higher frequency oscillations at onset. For instance, Jirsch and colleagues (Jirsch et al 2006) did not find significant $^{ictal}HFO_{100-500}$ at onset for 3 among ten patients studied. This was supposed to be due to “regional epilepsy” difficult to localize. However, these patients had an average of 3 intracranial electrodes implanted. An alternative interpretation of these results may be that HFO may not be so rare and specific, and would have been recorded with a higher number of electrodes and a larger sampling of the cortex. Further studies focused on patients with accurately-delineated SOZ (Jacobs et al 2009a), which is unfortunately not always the case in clinical practice.

Previous evaluations based on high frequencies ($HFO_{12,4-97}$) found significant epileptogenicity for all patients in more than one mesio-temporal structure (Bartolomei 2008) but the method was different. Epileptogenicity index was based on temporal delay and power at onset in high gamma band, averaged on the greatest epileptogenicity index for the seizure, at the patient level. High frequencies were demonstrated to be involved at seizure onset, with a high reproducibility among patients and SOZ. However, the threshold of high epileptogenicity index varied between studies (from 0.3 to 0.4). In our study, epileptogenicity mapping quantified the power in the 60-100 Hz band at seizure onset when it reached statistical significance.

The prominent role of HFO₆₀₋₁₀₀ at seizure onset raises the question of the relevant frequencies that have to be studied. The relationship between the frequency band and the pathogenic role of high frequencies oscillations has been described previously. A first hypothesis stated that lower frequencies (notably gamma activities and ripples in the 70-150 Hz range) reflected normal cognitive activities whereas fast ripples (170-250 Hz) were witnessing epileptogenic tissue. Such a distinction made on the basis of frequency alone remains, however, a debatable issue (Engel et al 2009, Engel et al 2012). Therefore, we will have to take into account these ictal HFO₆₀₋₁₀₀, involved at seizure onset for each patient. Furthermore, similar reasoning on co-existing normal and pathological high frequencies might apply to the 60-100 Hz band. One future challenge will consist in defining the relationship between epileptic and cognitive HFO in order to study pathological and physiological mechanisms (Jerbi et al 2009) underlying these oscillations.

B. Prominent value of ictal *versus* interictal high frequency oscillations

We decided to focus on ictal activation because close relationship between ^{ictal}HFO and low voltage fast activity had been previously studied and proved to be helpful for a better delineation of the epileptogenic area (Alarcon et al 1995, Fisher et al 1992). Fast discharges seemed to highly correlate with the seizure onset zone, and resection of cortex area displaying these activities was associated to a good surgical outcome (Alarcon et al 1995). More generally, interictal abnormalities (notably spikes) are known to be not reliable enough to delineate the epileptogenic tissue to be removed. Interictal HFOs, however, do not co-localize systematically with spikes and a number of recent studies have pointed to their potential localizing value (Jacobs 2011) However, we assume that the relationships between interictal and ictal HFOs has not been fully elucidated yet, which means first to have an objective tool for quantifying the fast activities at seizure onset.

In our study, epileptogenicity mapping was evaluated versus a baseline period. The choice of this baseline was decisive: if too closed to the ictal onset, this baseline would consist in the preictal period, where high frequencies may increase. If localized on the interictal abnormalities period, baseline would minor ictal high frequency activities. Consequently, we chose a baseline that ends more than ten second before ictal onset. This may appear too close to the seizure onset. However, studies based on temporal progression of HFO reported a later increase in HFO power (Khosravani et al 2009). Also, the MNI group did not find any preictal increase of HFO during the 15 minutes that preceded seizure (Jacobs et al 2009b). We assume that the baseline we choosed in our study was far enough from the onset of the seizures, and might not contain much Moreover, the baseline was defined visually on raw SEEG, in order to reduce the risk of including too many spikes and artefacts that could lead to a misinterpretation of the epileptogenicity maps.

C. Epileptogenicity maps sometimes vary between seizures

- **Unsignificant HFO₆₀₋₁₀₀ at seizure onset**

All patients displayed HFO₆₀₋₁₀₀ activation but some particularities need to be underlined. As previously noticed, some patients (for instance patient 12 or 14) displayed significant ictal HFO₆₀₋₁₀₀ on the group analysis, but some seizures had no significant epileptogenicity at seizure onset. Time-frequency charts, for these patients and for each seizure, found ictal increase in the 60-100Hz band, and maps of epileptogenicity without family-wise error correction displayed significant epileptogenicity in the same cortical region than for the other seizures. Why ictal HFO₆₀₋₁₀₀ were not significant for these seizures remain an interesting issue. It did not depend on the absence of a lesion on MRI, since these 2 patients had a lesional epilepsy (DNET for patient 12 and neonatal stroke for patient 14). Both of them, however, were suffering from frontal lobe seizures, where ictal discharges are sometimes difficult to identify. Epileptogenicity maps may thus encounter the same difficulties than visual analysis does. Nevertheless, although HFO₆₀₋₁₀₀ were not significant for each seizure, epileptogenicity mapping could be defined for the seizures group, and reflected the extent of the SOZ.

- **Clinical interpretation of statistical results is necessary**

Epileptogenicity map requires some interpretation. Maps of most significant epileptogenicity regions are sometimes limited to a small spot, as for patient 20. This spot was near the nodular heterotopia of the patient, but the ictal SEEG pattern was much larger than restricted to this small area, even for fast discharges, what was shown with maps of propagation delay. A similar problem was noticed for patient 16. Also, some zones that are not the most significant, but that displayed significant activations at seizure onset should be included in the seizure onset zone to have a global overview on ictal activation. For this situation, maps of propagation delay, displaying the seizure network between $\Delta=0$ and $\Delta=10$ seconds, are useful. Therefore, the definition of the SOZ based on epileptogenicity mapping has to take into account both parameters: the most significant epileptogenicity which provides an objective evaluation of ictal HFO₆₀₋₁₀₀, and the propagation delay which displays a realistic map of the ictal discharge.

D. Additional value of Epileptogenicity mapping: overcoming SEEG analysis

Do these data provided by epileptogenicity mapping differ from those that are described visually? In most cases, epileptogenicity maps reflected the conclusion of traditional SEEG analysis. But in two patients with temporal epilepsy, our conclusions slightly differed from visual analysis. Epileptogenicity mapping emphasized insular involvement, underlying a “temporal-plus” network (Ryvlin and Kahane 2005), which was not obvious on SEEG traditional evaluation. This was particularly relevant for patient 2, who underwent a temporal (and small insular) unsuccessful resection, and who presents now prominent insular symptoms during the residual seizures. Thus, some fast activities difficult to define visually could be underlined on epileptogenicity maps. This tool

provides an exhaustive definition of the seizure onset zone by analysing simultaneously all the intracranial electrode contacts, which is not so easy to do when using the traditional visual inspection of the SEEG traces. It also provides a quantified and objective assessment of the rapid components of the ictal discharges, and therefore opens the window for comparison with other diagnostic tools.

Finally, epileptogenicity map sometimes underlined large networks, with distant electrodes contacts being activated at the same time. Simultaneous involvement of distinct and distant brain regions has already been described with gamma prominent activation (Wendling et al 2003). Several hypotheses on pathophysiological phenomenon leading to distant co-activation have been exposed, including the respective role of desynchronisation and hypersynchronisation in the genesis of gamma activities, and the role of inhibitory interneurons.

E. Methodological limits and bias

We encountered some methodological difficulties in this study. First, our cohort was miscellaneous and very different SEEG patterns between the patients. We could not perform statistical group analysis of epileptogenicity for several patients.

Surgical outcome was poor for this group of patients, with only 7 patients displaying a good (Engel I) outcome. As for many centres, patients undergoing invasive evaluation are often very difficult cases with complex epileptogenic networks. Many of them had MRI-negative epilepsy, and four patients were implanted after a first unsuccessful resection.

The definition of seizure onset time ($\Delta=O$) was defined visually. Thus this method combines visual interpretation of seizure onset, with statistical evaluation of electrodes involved. However, visual interpretation may be more reliable to dissociate seizure onset from interictal abnormalities.

Finally, the accuracy of our epileptogenicity map depends on the implantation scheme decided for SEEG. It cannot be totally exhaustive, but our patients underwent large implantations, which provided large view of intracranial activity.

II. EPILEPTOGENICITY MAPPING STRONGLY CORRELATES WITH SEIZURE ONSET ZONE

Significant ictal HFO₆₀₋₁₀₀ was found at seizure onset for all the patients. Additionally, our results clearly suggest a close relationship between HFO₆₀₋₁₀₀ localisation and the seizure onset zone.

A. Most significant ictal HFO₆₀₋₁₀₀ co-localize with epileptogenic lesions

The few patients who showed a FCD lesion on MRI also exhibited during their seizures an epileptogenicity that was most significant on the lesional area. All of them presented other areas with ictal HFO₆₀₋₁₀₀, but this was less (but still) significant. This finding is in line with recent literature data (Augier et al 2009), which showed that the epileptogenicity index is higher within dysplastic lesions, but is also significant outside. These results enhance the idea that epileptic networks are organised around the dysplastic tissue, but extends out of the lesion. Conclusions seem different with interictal HFO, since ripples and fast ripples are related to the SOZ rather than to the lesion itself, with the exception of hippocampal sclerosis (Jacobs et al 2009a). However those results do not contradict with our findings: the 3 patients reported here were seizure-free after the removal of the FCD. In their cases, HFO₆₀₋₁₀₀ reflected an lesional cortex that was highly epileptogenic.

In the particular case of MRI-negative patients, epileptogenicity map might be useful since ictal HFO₆₀₋₁₀₀ were always found significant on epileptogenicity maps. Further studies are needed in larger cohort of patients to evaluate the reliability of this tool in this subgroup of particularly difficult cases.

B. Epileptogenicity maps reflect and rank the conclusions of SEEG analysis

In the whole cohort, comparing SEEG conclusions with our epileptogenicity maps demonstrated a high spatial correlation between low voltage fast activity as visually defined, and ictal HFO₆₀₋₁₀₀ localisation. Epileptogenicity mapping therefore provides a reliable reflect of fast discharges involved at seizure onset and confirms, in an objective way, what was highly suspected on visual analysis. This new tool also helps the clinician to organize into a hierarchical way how the different parts of the epileptogenic network behave at the onset of the seizures. Furthermore, some fast discharge difficult to define visually can be underlined with epileptogenicity mapping, as previously described for frontal lobe epilepsy cases (see above). Epileptogenicity mapping strengthens the hypothesis that rapid discharges containing HFO co-localize with the SOZ. HFO₆₀₋₁₀₀ defined on the EM would constitute a biomarker of the seizure onset zone, and might help to delineate accurately the cortex area to remove.

C. Reproducibility of Epileptogenicity map

A high spatial stability of epileptogenicity maps was found among different seizures in the same patient. Epileptogenicity map was always localized on the same cortical areas, displaying reproducible

patterns among seizures. Neither anti-epileptic drugs reduction, nor the sleep-waking cycle, influenced these patterns, as previously suggested by Gnatovsky et al (2011): in this study, 8 patients were evaluated on the basis of frequencies of interest. When patients presented several reproducible seizures, they had similar patterns in terms of frequency and type of electrodes involved. But, in this article, stability was mainly studied for lower frequencies, and different types of seizures were recorded for each patient. In our study, stereotypical patterns were reproducible both visually and with epileptogenicity maps. Epileptogenicity mapping mirrored what was analysed on raw-SEEG. This reproducibility of HFO₆₀₋₁₀₀ networks confirmed the strength of this parameter to define the seizure onset zone. The MNI group previously quantified ^{interictal}HFO₈₀₋₅₀₀ for the recording period, and reported that their rates were increasing with drug reduction, and decreased after the seizure (Zijlmans et al 2009b). This finding suggests that ^{interictal}HFO₈₀₋₅₀₀ are a marker of the disease activity, while ^{ictal}HFO₆₀₋₁₀₀ seem to reflect both SOZ and epileptogenic zones. Whether ^{ictal}HFO₈₀₋₅₀₀ co-localize with the epileptogenic zone will be critical to confirm the epileptogenic value of HFO₈₀₋₅₀₀. More generally, further research must focus on the relationships between interictal and ictal HFO, to understand whether both are a single biomarker, or reflect the continuum between ictogenesis and the seizure itself. Those relationships remain unclear and may be crucial to understand the “route to seizure”.

D. Epileptogenicity maps might predict surgical outcome: a new objective biomarker for the delineation of the epileptogenic area?

We aimed at studying the relationship between HFO₆₀₋₁₀₀ activity and surgical outcome, according to the resection of brain areas displaying significant epileptogenicity at seizure onset. This relationship appears to be crucial, but was strikingly rarely studied until now. Interictal HFO were evaluated according to the outcome (Jacobs et al 2010a), but comparison was made between HFO and the seizure onset zone, and has never been quantified according to the extent of the removed area. Indeed, seizure onset zone definition remains unclear and subjective, and the resection does not necessarily co-localize with it.

Relationship between ^{ictal}HFO_{12,4-90} and surgical outcome was evaluated by Bartolomei et al (2010) in patients with temporal lobe epilepsy: high epileptogenicity index in extra-temporal cortices lead to a poorer outcome. Moreover seizure free patients had a significantly lower number of structures with significant epileptogenicity index, than patients in whom surgery failed.

The only way to evaluate clinical relevance of HFO₆₀₋₁₀₀ increase at seizure onset was to compare their degree of removal with the surgical outcome. This has been performed in children epilepsy, with intraoperative electrocorticography recordings (Wu et al 2010): when the brain regions that displayed significant ^{interictal}HFO₂₅₀₋₅₀₀ were removed, seizure freedom was achieved. All those paediatric patients had lesional epilepsy, although HFO₂₅₀₋₅₀₀ did not systematically co-localize with the lesion. More recently Park reported that the removal of grid contacts displaying ^{ictal}HFO₆₀₋₉₉ in neocortical epilepsy

was associated to a good outcome (Park et al 2012). He noticed that the removal of the grid contacts displaying ictal HFO₆₀₋₉₉ of higher amplitude was associated to a good post-operative outcome. However, in this article, the comparison was made with the grid contacts, but little is known about the deepest brain regions potentially involved in HFO. Indeed, 30% of the patients included did not display HFO, and the sensitivity of this method would need to be further assessed.

In our study, we compared the genuine resection performed, based on the post-surgical MRI, with the brain areas displaying most significant ictal HFO₆₀₋₁₀₀. This was carried out on 11 patients only, because of missing post-operative MRI or insufficient follow-up. The results clearly support the hypothesis of a strong relationship between HFO₆₀₋₁₀₀ removal and good post-operative outcome: patients in Engel class III or IV had a low overlap between areas exhibiting HFO₆₀₋₁₀₀ and areas removed by surgery, whereas patients in Engel class I presented high ratio. Outcome did not depend on the presence of a lesion on MRI in this cohort, since 3 MRI negative cases were present in both groups (Engel I versus Engel III-IV). This confirms the prominent involvement of HFO₆₀₋₁₀₀ increase at seizure onset: ictal HFO₆₀₋₁₀₀ are related to epileptogenic lesions, associated to fast discharges, and outcome depends on their removal. Epileptogenicity map might thus provide biomarker of the seizure onset zone, as described with interictal HFO (Worrell et al 2011). This could provide a significant help in epilepsy surgery, as it applies to all seizure onset locations, whether a lesion is diagnosed or not, and even in cases of extended SOZ.

CONCLUSION

This study, conducted in patients undergoing a SEEG study, leads to a major finding: significant ictal HFO₆₀₋₁₀₀ can be found in all patients, for all seizure localization, and whether they present a lesion diagnosed on MRI or not. Ictal HFO₆₀₋₁₀₀ appear to mirror the fast discharge visually found at seizure onset, and confirm their localizing value for the SOZ. These results confirm what was previously reported in David et al in mesio-temporal epilepsy patients.

We could not perform, unfortunately, a group analysis between patients, because of the high heterogeneity of their SOZ. However, epileptogenicity maps highly correlate with seizure onset zone defined on SEEG data, with a high spatial stability throughout seizures.

Moreover, when resective surgery included most significant ictal HFO₆₀₋₁₀₀ areas, patients had a better outcome. To our knowledge, this relationship had never been reported with the genuine resection performed, based on the post-resection MRI. This result needs to be confirmed, because our number of patients was too small to enable statistical comparison in this subgroup. But it enhanced the relevance of epileptogenicity mapping in clinical practice. This new tool should be employed similarly to PET-FDG or fMRI, in order to help to define the brain regions to remove. This would be of use for MRI-negative patients, and might maybe help to limit the resection when functional cortex is involved at seizure onset. Future research will have to study the relationship between epileptic HFO₆₀₋₁₀₀ and others high gamma oscillations, especially those that have been evidenced during the interictal period. Those relationships might be crucial to understand the complex pathophysiology underlying HFO involvement in ictogenesis.

THESE SOUTENUE PAR :Anne-Sophie JOB

TITRE :

Cartographies des réseaux épileptiques évalués en stéréo-électroencéphalographie. Apport des oscillations hautes fréquences (60-100 Hz) ictales dans la définition de la zone épileptogène.

CONCLUSION

Cette étude, basée sur les données critiques obtenues au cours d'enregistrements stéréo-électroencéphalographiques (SEEG) a été menée auprès de 21 patients consécutifs présentant une épilepsie partielle pharmaco-résistante. Au terme de ce travail, un constat primordial s'impose: chacun des patients étudiés présente une activation ictale significative des oscillations hautes fréquences de 60 à 100Hz (HFO₆₀₋₁₀₀), comparativement à l'activité interictale. Cette activation des HFO₆₀₋₁₀₀ s'avère systématique, quelle que soit la région corticale impliquée dans la genèse de la crise. Ceci est également confirmé pour les patients présentant une épilepsie partielle cryptogénique et pour lesquels la définition de la zone épileptogène demeure souvent complexe.

La très grande hétérogénéité comme la taille limitée de notre cohorte n'ont malheureusement pas permis d'établir de corrélation statistique à l'échelle du groupe, pour un type d'épilepsie ou de zone épileptogène donné. Néanmoins, les cartographies d'épileptogénicité démontrent une corrélation topographique étroite entre les zones compromises à la phase ictale d'après l'analyse SEEG, et celles présentant une activation significative des HFO₆₀₋₁₀₀.

De façon similaire, les cartographies d'épileptogénicité s'avèrent très reproductibles d'une crise à l'autre. Le caractère stéréotypé des HFO₆₀₋₁₀₀ n'est pas sans rappeler la grande stabilité topographique de la zone à l'origine des différentes crises d'un même patient.

Par ailleurs, les patients dont la résection chirurgicale inclut les HFO₆₀₋₁₀₀ ictales les plus significatives présentent un pronostic post-opératoire favorable. A notre connaissance, la valeur épiléptogène des HFO, corrélée au pronostic post-opératoire, n'avait jamais été évaluée en fonction de la résection effective des zones compromises dans ce spectre fréquentiel. Nos résultats devront être confirmés à plus grande échelle, mais ils présagent d'emblée de la valeur clinique de l'étude des HFO₆₀₋₁₀₀, dans la détermination des régions corticales impliquées dans l'épileptogénèse. A l'instar de l'IRM et de la tomographie par émission de positons, les cartographies d'épileptogénicité pourraient être utilisées au cours du bilan pré-chirurgical pour délimiter les régions corticales à réséquer. Ceci s'avèrerait d'autant plus pertinent en l'absence de lésion anatomique définie, comme lors des résections en zone fonctionnelle. Les HFO₆₀₋₁₀₀ permettraient de restreindre la résection aux régions corticales dont le degré d'épileptogénicité ainsi quantifié est le plus élevé.

Multiplés sont les problématiques à résoudre concernant le rôle propre des HFO au cours de l'ictogénèse. Nos futures recherches devront s'attacher à évaluer les relations entre HFO₆₀₋₁₀₀ épiléptiques, et activités cognitives de mêmes fréquences. La présence d'HFO₆₀₋₁₀₀ intercritiques devra également être quantifiée, et pourrait constituer une étape cruciale dans la compréhension des mécanismes physiopathologiques à l'origine de la «route vers la crise».

VU ET PERMIS D'IMPRIMER

Grenoble, le 20 avril 2012.

LE DOYEN



JP ROMANET

LE PRESIDENT DE LA THESE


PROFESSEUR P. KAHANE

REFERENCES

1. Alarcon, G, Binnie CD, Elwes RD, Polkey CE. Power spectrum and intracranial EEG patterns at seizure onset in partial epilepsy. *Electroencephalography and clinical neurophysiology* 1995; 94 (5): 326-337
2. Allen PJ, Fish DR, Smith SJ. Very high frequency rhythmic activity during SEEG suppression in frontal lobe epilepsy. *Electroencephalogr Clin Neurophysiol* 1992; 82(2):155-159
3. Akiyama T, McCoy B, Go CY, Ochi A, Elliot IM, Akiyama M et al. Focal resection of fast ripples on extraoperative intracranial EEG improves seizure outcome in pediatric epilepsy. *Epilepsia* 2011; 52(10):1802-1811
4. Aubert S, Wendling F, Regis J, McGonigal A, Figarella-Branger D, Peragut JC, Girard N, Chauvel P, Bartolomei F. Local and remote epileptogenicity in focal cortical dysplasias and neurodevelopmental tumours. *Brain* 2009; 132: 3072-3086
5. Bartolomei F, Chauvel P, Wendling F. Epileptogenicity of brain structure in human temporal lobe epilepsy: a quantified study from intracerebral EEG. *Brain* 2008; 131: 1818-1830
6. Bartolomei F, Cosandier-Rimele D, Mc Gonigal A, Aubert S, Regis J, Gavaret JM et al.. From mesial temporal lobe to temporoparietal seizures: A quantified study of temporal lobe seizure networks. *Epilepsia* 2010; 51: 2147-2158
7. Bartolomei F, Gavaret M, Hewett R, Valton L, Aubert S, Régis J et al. Neural networks underlying parietal lobe seizures: a quantified study from intracerebral recordings. *Epilepsy research* 2011; 93(2-3):164-176
8. Blanco JA, Stead M, Krieger A, Viventi J, Marsh R, Lee KH et al. Unsupervised classification of High-frequency oscillations in human neocortical epilepsy and control patients. *Journal of neurophysiology* 2010; 104 (5): 2900-2912
9. Blanco JA, Stead M, Krieger A, Stacey W, Maus D, Marsh E et al. Data mining neocortical high frequency oscillations in epilepsy and controls. *Brain* 2011; 134:2948-2959
10. Buzsaki G, Horvath Z, Urioste R, Hetke J, Wise K. High-frequency network oscillation in the hippocampus. *Science* 1992; 256: 1025-1027
11. Bragin A, Engel J, Wilson C, Fried I, Mathern G. Hippocampal and entorhinal cortex high frequency oscillations (100-500 Hz) in human epileptic brain and in Kainic acid-treated rats with chronic seizures. *Epilepsia* (1999); 40(2): 127-137
12. Bragin A, Wilson C, Staba RJ, Reddick M, Fried I, Engel JR. Interictal High-frequency oscillations (80 -500hz) in the human epileptic brain: entorhinal cortex . *Annals of Neurology* 2002; 52: 407-415

13. Bragin A, Mody I, Wilson CL, Engel J. Local generation of fast ripples in epileptic brain. *The Journal of neurosciences* 2002; 22(5): 2012-2021
14. Chassoux F, Devaux B, Landre E, Turak B, Nataf F, Varlet P, Chodkiewicz J, Daumas-Duport C. Stereoelectroencephalography in focal cortical dysplasia. A 3D approach to delineating dysplastic cortex. *Brain* 2000; 123: 1733-1751
15. Chatillon CE, Zelmann R, Bortel A, Avoli M, Gotman J. Contact size does not affect high frequency oscillation detection in intracerebral EEG recordings in a rat epilepsy model. *Clinical Neurophysiology* 2011; 122 (9):1701-1705
16. Crepon B, Navarro V, Hasboun D, Clemenceau S, Martinerie J, Baulac et al. Mapping interictal oscillations greater than 200 Hz recorded with intracranial macroelectrodes in human epilepsy. *Brain* 2001; 133 (1): 33-45
17. David O, Blauwblomme T, Job AS, Chabardes S, Hoffmann D, Minotti L, Kahane P. Imaging the seizure onset zone with stereo-electroencephalography. *Brain* 2011; 134 (10): 2898-2911
18. De Curtis M, Gnatkovsky V. Reevaluating the mechanisms of focal ictogenesis: the role of low-voltage fast activity. *Epilepsia* 2009; 50 (12): 2514-2525
19. Engel J , Bragin A, Staba RJ, Mody I. High-Frequency Oscillations: what is normal and what is not? *Epilepsia* 2009; 50 (4): 598-604
20. Engel J, da Silva FL. High-Frequency Oscillations. Where we are and where we need to go. *Progress in Neurobiology* (2012). DOI 10.1016/j.pneurobio.2012.02.001
21. Fisher RS, Webber R, Lesser RP, Arroyo S, Uematsu S. High frequency activity at the start of seizures. *Journal of Clinical Neurophysiology* 1992; 9(3): 441-448
22. Gnatkovsky V, Francione S, Cardinale F, Mai R, Tassi L, Lo Russo G, de Curtis M. Identification of reproducible ictal patterns based on quantified frequency analysis of intracranial EEG signals. *Epilepsia* 2011; 52(3): 477-488
23. Jacobs et al J, LeVan P, Chander R, Hall J, Dubeau F, Gotman J. Interictal High-Frequency Oscillations (80-500 Hz) are an indicator of seizure onset areas independent of spikes in the human epileptic brain. *Epilepsia* 2008; 49 (11): 1893-1907
24. Jacobs et al J, LeVan P, Chatillon CE, Olivier A, Dubeau F, Gotman J. High frequency oscillations in intracranial EEG mark epileptogenicity rather than lesion type. *Brain* 2009;132 (4): 1022-1037
25. Jacobs et al J, Zelmann R, Jirsch J, Chander R, Chatillon CE, Dubeau F et al. High frequency oscillations (80-500 Hz) in the preictal period in patients with focal seizures. *Epilepsia* 2009; 50(7): 1780-1792
26. Jacobs J, Zijlmans M, Zelmann R, Chatillon CE, Hall J, Olivier A, Dubeau F, Gotman J. High-frequency electroencephalographic oscillations correlate with outcome of epilepsy surgery. *Annals of neurology* 2010; 67 (2): 209-220

27. Jacobs J, Zijlmans M, Zelmann R, Olivier A, Hall J, Gotman J, Dubeau F. Value of electrical stimulation and high frequency oscillations (80–500 Hz) in identifying epileptogenic areas during intracranial EEG recordings. *Epilepsia* 2010; 51(4): 573-582
28. Jacobs J, Kobayashi K, Gotman J. High-frequency changes during interictal spikes detected by time-frequency analysis. *Clinical Neurophysiology* 2011; 122(1): 32-42
29. Jerbi K, Ossandon T, Hamame C, Senova S, Dalal S, Jung J et al. Task-related gamma-band dynamics from an intracerebral perspective: review and implications for surface EEG and MEG. *Human brain mapping* 2009; 30(6): 1758-1771
30. Jirsch J. D, Urresterazu E, Le Van P, Olivier A, Dubeau F, Gotman J. High-frequency oscillations during human focal seizures. *Brain* 2006; 129(6): 1593-1608
31. Khosravani H, Mehrotra N, Rigby M, Hader WJ, Pinnegar CR, Pillay N et al. Spatial localization and time-dependant changes of electrographic high-frequency oscillations in human temporal lobe epilepsy. *Epilepsia* 2009; 50 (4): 605-616
32. Lee SA, Spencer DD, Spencer SS. Intracranial EEG seizure-onset patterns in neocortical epilepsy. *Epilepsia* 2000; 41 (3): 297-307
33. Ochi A, Otsubo H, Donner EJ, Elliott I, Iwata R, Funaki T et al. Dynamic changes of ictal high-frequency oscillations in neocortical epilepsy: using multiple band frequency analysis. *Epilepsia* 2007; 48 (2): 286-296
34. Ogren JA, Bragin A, Wilson CL, Hoftman GD, Lin JL, Dutton RA et al. Three-dimensional surface maps link local atrophy and fast ripples in human epileptic hippocampus. *Annals of neurology* 2009; 66(6): 783-791
35. Palmi A, Gambardella A, Andermann F, Dubeau F, da Costa J, Olivier A, Tampieri D, Gloor P et al. Intrinsic epileptogenicity of human dysplastic cortex as suggested by corticography and surgical results. *Annals of neurology* 1995; 37(4): 476-487
36. Park SC, Kun Lee S, Che H., Chung CK. Ictal high-gamma oscillation (60-99 Hz) in intracranial electroencephalography and postoperative seizure outcome in neocortical epilepsy. *Clinical Neurophysiology* 2012 DOI 10, 1016/clinph.2012.01.008
37. Rosenow F, Luder H. Presurgical evaluation of epilepsy. *Brain* 2001; 124(9): 1683-1700
38. Ryvlin P, Kahane P. The hidden causes of surgery-resistant temporal lobe epilepsy: extratemporal or temporal plus? *Current opinion in neurology* 2005 18(2): 125
39. Staba RJ, Wilson CL, Bragin A, Fried I, Engel J. Quantitative analysis of high-frequency oscillations (80-500 Hz) recorded in human epileptic hippocampus and entorhinal cortex. *Journal of neurophysiology* 2002; 88: 1743-1752
40. Staba RJ, Frigetto L, Behnke E, Mathern GH, Fields T, Bragin A et al. Increased fast ripple to ripple ratio correlates with reduced hippocampal volume and neuron loss in temporal lobe epilepsy. *Epilepsia* 2007; 48(11): 2130-2138

41. Urrestarazu E, Chander E, Dubeau F, Gotman J. Interictal High-frequency oscillations (100-500 Hz) in the intracerebral EEG of epileptic patients. *Brain* 2007; 130: 2354-2366
42. Vaugier L, Aubert S, McGonigal A, Trébuchon A, Guye M, Gavaret M, Regis J, Chauvel P, Wendling F, Bartolomei F. Neural networks underlying hyperkinetic seizures of "temporal lobe" origin. *Epilepsy research* 2009; 86: 200-208
43. Wendling F, Bartolomei F, Bellanger JJ, Bourien J, Chauvel P. Epileptic fast intracerebral EEG activity: Evidence for spatial decorrelation at seizure onset. *Brain* 2003; 126:1449-1459
44. Worrell GA, Parish L, Cranstoun SD, Jonas R, Baltuch R, Litt B. High-frequency oscillations and seizure generation in neocortical epilepsy. *Brain* 2004, 127, 1496-1506
45. Worrell GA, Gotman J. High frequency oscillations and other neurophysiological biomarkers of epilepsy: clinical studies. *Biomark Med* 2011; 5(5): 557-566
46. Wu JY, Sankar R, Lerner JT, Matsumoto JH, Vinters HV, Mathern GW. Removing interictal fast ripples on electrocorticography linked with seizure freedom in children. *Neurology* 2010;75:1686-1694
47. Zijlmans M, Jacobs J, Zelmann R, Dubeau F, Gotman J. High frequency oscillations and seizure frequency in patients with focal epilepsy. *Epilepsy Research* 2009; 85: 287-292
48. Zijlmans M, Jacobs J, Zelmann R, Dubeau F, Gotman J. High-frequency oscillations mirror disease activity in patients with epilepsy. *Neurology* 2009; 72(11): 979-986
49. Zijlmans M, Jacobs J, Kahn Y, Zelmann R, Dubeau F, Gotman J. Ictal and interictal high frequency oscillations in patients with focal epilepsy. *Clinical Neurophysiology* 2011; 122(4): 664-671