



HAL
open science

Intérêt de l'anticorps Immunoglobulines G Anti Hsp70.1 dans le diagnostic de toxoplasmose oculaire

Antoine Lesoin

► **To cite this version:**

Antoine Lesoin. Intérêt de l'anticorps Immunoglobulines G Anti Hsp70.1 dans le diagnostic de toxoplasmose oculaire. Médecine humaine et pathologie. 2013. dumas-00999405

HAL Id: dumas-00999405

<https://dumas.ccsd.cnrs.fr/dumas-00999405v1>

Submitted on 3 Jun 2014

HAL is a multi-disciplinary open access archive for the deposit and dissemination of scientific research documents, whether they are published or not. The documents may come from teaching and research institutions in France or abroad, or from public or private research centers.

L'archive ouverte pluridisciplinaire **HAL**, est destinée au dépôt et à la diffusion de documents scientifiques de niveau recherche, publiés ou non, émanant des établissements d'enseignement et de recherche français ou étrangers, des laboratoires publics ou privés.

AVERTISSEMENT

Ce document est le fruit d'un long travail approuvé par le jury de soutenance et mis à disposition de l'ensemble de la communauté universitaire élargie.

Il n'a pas été réévalué depuis la date de soutenance.

Il est soumis à la propriété intellectuelle de l'auteur. Ceci implique une obligation de citation et de référencement lors de l'utilisation de ce document.

D'autre part, toute contrefaçon, plagiat, reproduction illicite encourt une poursuite pénale.

Contact au SICD1 de Grenoble : **thesebum@ujf-grenoble.fr**

LIENS

Code de la Propriété Intellectuelle. articles L 122. 4

Code de la Propriété Intellectuelle. articles L 335.2- L 335.10

http://www.cfcopies.com/V2/leg/leg_droi.php

<http://www.culture.gouv.fr/culture/infos-pratiques/droits/protection.htm>

UNIVERSITÉ JOSEPH FOURIER
FACULTÉ DE MÉDECINE DE GRENOBLE

Année : 2013

Thèse N°

THÈSE
PRÉSENTÉE POUR L'OBTENTION DU DOCTORAT EN
MÉDECINE
DIPLOME D'ÉTAT

**Intérêt de l'anticorps
Immunoglobulines G Anti Hsp70.1
dans le diagnostic de toxoplasmose oculaire**

M. Antoine LESOIN, né le 20 mars 1984 à Lille

THÈSE SOUTENUE PUBLIQUEMENT À LA FACULTÉ DE MÉDECINE DE
GRENOBLE*

Le 24 Octobre 2013

DEVANT LE JURY COMPOSE DE :

Président du jury : Professeur Jean-Paul ROMANET

Membres : Professeur Laurence BOUILLET

Professeur Hervé PELLOUX

Professeur Christophe CHIQUET, Directeur de thèse

*La Faculté de Médecine de Grenoble n'entend donner aucune approbation ni improbation aux opinions émises dans les thèses; ces opinions sont considérées comme propres à leurs auteurs.

Occupation des postes de PU-PH 2013-2014

ALBALADEJO Pierre Depuis 01/09/2008	Anesthésiologie-réanimation
ARVIEUX- BARTHELEMY Catherine Depuis de 01/09/2007	Chirurgie générale
BACONNIER Pierre Depuis 01/10/1993	Biostat, informatique médicale et technologies de communication
BAGUET Jean-Philippe Depuis 01/09/2006	Cardiologie
BALOSSO Jacques Depuis 01/09/2003	Radiothérapie
BARRET Luc Depuis 01/10/1992	Médecine légale et droit de la santé
BAUDAIN Philippe Depuis 01/05/1990	Radiologie et imagerie médicale
BEANI Jean-Claude Depuis 01/10/1992	Dermato-vénérologie
BENHAMOU Pierre Yves Depuis 01/09/2003	Endocrinologie, diabète et maladies métaboliques
BERGER François Depuis 01/09/2001	Biologie cellulaire
BETTEGA Georges Depuis 01/09/2013	Chirurgie maxillo-faciale et stomatologie
BONAZ Bruno Depuis 01/09/2001	Gastro-entérologie, hépatologie, addictologie
BOSSON Jean-Luc Depuis 01/01/2006	Biostat, informatique médicale et technologies de communication
BOUGEROL Thierry Depuis 01/09/1998	Psychiatrie d'adultes
BOUILLET Laurence Depuis 01/09/2012	Médecine interne
BRAMBILLA CHRISTIAN Depuis 01/10/1989	Pneumologie
BRAMBILLA Elisabeth Depuis 01/10/1993	Anatomie et cytologie pathologiques
BRICAULT Ivan Depui 01/09/2011	Radiologie et imagerie médicale
BRICHON Pierre-Yves Depuis 01/10/1993	Chirurgie thoracique et cardio-vasculaire
CAHN Jean-Yves Depuis 01/09/2004	Hématologie

CARPENTIER Françoise Depuis 01/09/1997	Thérapeutique, médecine d'urgence
CARPENTIER Patrick Depuis 01/10/1990	Chirurgie vasculaire, médecine vasculaire
CESBRON Jean-Yves Depuis 01/09/1999	Immunologie
CHABARDES Stephan Depuis 01/09/2010	Neurochirurgie
CHABRE Olivier Depuis 01/09/2002	Endocrinologie, diabète et maladies métaboliques
CHAFFANJON Philippe Depuis 01/09/2005	Anatomie
CHAVANON Olivier Depuis 01/09/2006	Chirurgie thoracique et cardio-vasculaire
CHIQUET Christophe Depuis 01/09/2007	Ophtalmologie
CHIROSSEL Jean-Paul Depuis 01/06/1990	Anatomie
CINQUIN Philippe Depuis 01/10/1992	Biostat, informatique médicale et technologies de communication
COHEN Olivier Depuis 01/09/2003	Biostat, informatique médicale et technologies de communication
COUTURIER Pascal Depuis 01/09/2007	Gériatrie et biologie du vieillissement
CRACOWSKI Jean-Luc Depuis 01/09/2009	Pharmacologie fondamentale, pharmacologie clinique
DE GAUDEMARIS Régis Depuis 01/07/1992	Médecine et santé au travail
DEBILLON Thierry Depuis 01/09/2003	Pédiatrie
DEMATTEIS Maurice Depuis 01/09/2010	Addictologie
DEMONGEOT Jacques Depuis 01/10/1989	Biostat, informatique médicale et technologies de communication
DESCOTES Jean-Luc Depuis 01/09/1997	Urologie
ESTEVE François Depuis 01/09/2004	Biophysique et médecine nucléaire
FAGRET Daniel Depuis 01/10/1992	Biophysique et médecine nucléaire
FAUCHERON Jean-Luc Depuis 01/09/2001	Chirurgie générale
FERRETTI Gilbert Depuis 01/09/2000	Radiologie et imagerie médicale
FEUERSTEIN Claude Depuis 01/07/1992	Physiologie

FONTAINE Eric Depuis 01/01/2006	Nutrition
FRANCOIS Patrice Depuis 01/09/1998	Epidémiologie, économie de la santé et prévention
GARBAN Frédéric Depuis 01/09/2011	Hématologie, transfusion
GAUDIN Philippe Depuis 01/09/2001	Rhumatologie
GAVAZZI Gaetan Depuis 01/09/2011	Gériatrie et biologie du vieillissement
GAY Emmanuel Depuis 01/09/2004	Neurochirurgie
GODFRAIND Catherine Depuis 01/09/2013	Anatomie et cytologie pathologiques
GRIFFET Jacques Depuis 01/03/2010	Chirurgie infantile
HALIMI Serge Depuis 01/10/1990	Nutrition
HENNEBICQ Sylviane Depuis 01/09/2012	Biologie et médecine du développement et de la reproduction
HOFFMANN Pascale Depuis 01/09/2012	Gynécologie-obstétrique
HOMMEL Marc Depuis 01/09/1995	Neurologie
JOUK Pierre-Simon Depuis 01/09/1997	Génétique
JUVIN Robert Depuis 01/10/1993	Rhumatologie
KAHANE Philippe Depuis 01/09/2007	Physiologie
KRACK Paul Depuis 01/09/2003	Neurologie
KRAINIK Alexandre Depuis 01/09/2009	Radiologie et imagerie médicale
LABARERE José Depuis 01/09/2012	Epidémiologie, économie de la santé et prévention
LANTUEJOL Sylvie Depuis 01/09/2008	Anatomie et cytologie pathologiques
LECCIA Marie-Thérèse Depuis 01/09/2002	Dermato-vénérologie
LEROUX Dominique Depuis 01/09/1996	Génétique
LEROY Vincent Depuis 01/09/2007	Gastro-entérologie, hépatologie, addictologie
LETOUBLON Christian Depuis 01/05/1992	Chirurgie générale

LEVY Patrick Depuis 01/09/1997	Physiologie
MACHECOURT Jacques Depuis 01/10/1989	Cardiologie
MAGNE Jean-Luc Depuis 01/07/1990	Chirurgie vasculaire
MAITRE Anne Depuis 01/09/2007	Médecine et santé au travail
MAURIN Max Depuis 01/09/2002	Bactériologie-virologie
MERLOZ Philippe Depuis 01/10/1991	Chirurgie orthopédique et traumatologie
MORAND Patrice Depuis 01/09/2007	Bactériologie-virologie
MOREAU-GAUDRY Alexandre Depuis 01/09/2013	Biostat, informatique médicale et technologies de communication
MORO Elena Depuis 01/09/2012	Neurologie
MORO-SIBILOT Denis Depuis 01/09/2005	Pneumologie
MOUSSEAU Mireille Depuis 01/09/1994	Cancérologie
MOUTET François Depuis 01/10/1990	Chirurgie plastique, reconstructrice & esthétique, brûlologie
PALOMBI Olivier Depuis 01/09/2011	Anatomie
PARK Sophie Depuis 01/09/2013	Hématologie
PASSAGIA Jean-Guy Depuis 01/09/1994	Neurochirurgie
PAYEN DE LA GARANDERIE Jean-François Depuis 01/09/1996	Anesthésiologie-réanimation
PELLOUX Hervé Depuis 01/09/2001	Parasitologie et mycologie
PEPIN Jean-Louis Depuis 01/09/2004	Physiologie
PERENNOU Dominique Depuis 01/04/2008	Médecine physique et de réadaptation
PERNOD Gilles Depuis 01/09/2007	Médecine vasculaire
PIOLAT Christian Depuis 01/09/2009	Chirurgie infantile
PISON Christophe Depuis 01/09/1994	Pneumologie

PLANTAZ Dominique Depuis 01/09/2003	Pédiatrie
POLACK Benoît Depuis 01/09/1998	Hématologie
POLOSAN Mircea Depuis 01/09/2013	Psychiatrie d'adultes
PONS Jean-Claude Depuis 01/09/1998	Gynécologie-obstétrique
RAMBEAUD Jean-Jacques Depuis 01/07/1991	Urologie
REYT Emile Depuis 01/10/1992	Oto-rhyno-laryngologie
RIGHINI Christian Depuis 01/09/2010	Oto-rhyno-laryngologie
ROMANET J. Paul Depuis 01/10/1991	Ophtalmologie
SARAGAGLIA Dominique Depuis 01/07/1992	Chirurgie orthopédique et traumatologie
SCHMERBER Sébastien Depuis 01/09/2005	Oto-rhyno-laryngologie
SCHWEBEL Carole Depuis 01/09/2012	Réanimation, médecine d'urgence
SCOLAN Virginie Depuis 01/09/2013	Médecine légale et droit de la santé
SERGENT Fabrice Depui 01/09/2011	Gynécologie-obstétrique
SESSA Carmine Depuis 01/09/2005	Chirurgie vasculaire
STAHL Jean-Paul Depuis 01/10/1992	Maladies infectieuses, maladies tropicales
STANKE Françoise Depuis 01/09/2011	Pharmacologie fondamentale
TAMISIER Renaud Depuis 01/09/2013	Physiologie
TIMSIT Jean-François	Réanimation
TONETTI Jérôme 01/09/2007 au 31/12/2010	Chirurgie orthopédique et traumatologie
TOUSSAINT Bertrand Depuis 01/09/2008	Biochimie et biologie moléculaire
VANZETTO Gérald Depuis 01/09/1999	Cardiologie
VUILLEZ Jean-Philippe Depuis 01/09/1999	Biophysique et médecine nucléaire
WEIL Georges Depui 01/09/2011	Epidémiologie, économie de la santé et prévention

ZAOUI Philippe Depuis 01/09/2002	Néphrologie
ZARSKI Jean-Pierre Depuis 01/09/1994	Gastro-entérologie, hépatologie, addictologie

Occupation des postes de MCU-PH 2013-2014

APTEL Florent Depuis 01/09/2012	Ophtalmologie
BOISSET Sandrine Depuis 01/09/2012	Bactériologie, virologie
BONNETERRE Vincent Depuis 01/09/2011	Médecine et santé au travail
BOTTARI Serge Depuis 01/10/1993	Biologie cellulaire
BOUZAT Pierre Depuis 01/09/2012	Anesthésiologie-réanimation
BRENIER-PINCHART M.Pierre Depuis 01/11/2001	Parasitologie et mycologie
BRIOT Raphaël Depuis 01/09/2009	Thérapeutique, médecine d'urgence
CALLANAN-WILSON Mary Depuis 01/09/2002	Hématologie, transfusion
DECAENS Thomas Depuis 01/09/2013	
DERANSART Colin Depuis 01/09/2004	Physiologie
DETANTE Olivier Depuis 01/09/2009	Neurologie
DIETERICH Klaus Depuis 01/09/2012	Génétique
DUMESTRE-PERARD Chantal Depuis 01/09/2004	Immunologie
EYSSERIC Hélène Depuis 01/10/2009	Médecine légale et droit de la santé
FAURE Julien Depuis 01/09/2008	Biochimie et biologie moléculaire
GILLOIS Pierre Depuis 01/09/2010	Biostat, informatique médicale et technologies de communication
GRAND Sylvie Depuis 01/09/1995	Radiologie et imagerie médicale
GUZUN Rita Depuis 01/09/2012	Nutrition

LAPORTE François Depuis 01/10/1991	Biochimie et biologie moléculaire
LARDY Bernard Depuis 01/09/2007	Biochimie et biologie moléculaire
LARRAT Sylvie Depuis 01/09/2009	Bactériologie, virologie
LAUNOIS-ROLLINAT Sandrine Depuis 01/09/2001	Physiologie
LONG Jean-Alexandre Depuis 01/09/1999	Urologie
MAIGNAN Maxime Depuis 01/09/2013	Médecine d'urgence
MALLARET Marie-Reine Depuis 01/08/1992	Epidémiologie, économie de la santé et prévention
MARLU Raphaël Depuis 01/09/2013	Hématologie
MAUBON Danièle Depuis 01/09/2010	Parasitologie et mycologie
MC LEER (FLORIN) Anne Depuis 01/09/2011	Cytologie et histologie
MOUCHET Patrick Depuis 01/10/1992	Physiologie
PACLET Marie-Hélène Depuis 01/09/2007	Biochimie et biologie moléculaire
PAYSANT François Depuis 01/02/2008	Médecine légale et droit de la santé
PELLETIER Laurent Depuis 01/01/2006	Biologie cellulaire
RAY Pierre Depuis 01/09/2003	Génétique
RIALLE Vincent Depuis 01/09/2001	Biostat, informatique médicale et technologies de communication
ROUSTIT Matthieu Depuis 01/08/1990	Pharmacologie clinique
ROUX-BUISSON Nathalie Depuis 01/09/2012	Biochimie et génétique moléculaire
SATRE Véronique Depuis 01/09/2005	Génétique
SEIGNEURIN Arnaud Depuis 01/09/2013	Epidémiologie, économie de la santé et prévention
STASIA Marie-Josée Depuis 01/08/1992	Biochimie et biologie moléculaire

REMERCIEMENTS

Aux Membres de mon jury

Monsieur le Professeur Jean-Paul ROMANET, vous avez accepté de présider ce jury. Votre sens de la pédagogie et de la clinique n'ont d'égal que votre dévouement pour vos patients.

Madame le Professeur Laurence BOUILLET, vous avez accepté de faire partie de ce jury. Recevez ici le témoignage de ma gratitude et de mon profond respect.

Monsieur le Professeur Hervé PELLOUX, vous m'avez accueilli au sein de votre dynamique service. Recevez ici mes sincères remerciements pour votre disponibilité.

A mon directeur de thèse

Monsieur le Professeur Christophe CHIQUET, j'ai eu la chance de profiter de votre savoir et votre investissement pour la recherche. Vous m'avez poussé à me dépasser.

Aux équipes qui ont participé au projet Bioluve, et plus particulièrement

A Bernabé, pour ta disponibilité et ton engagement.

A tous les médecins qui ont contribué à ma formation, et plus particulièrement

A Tiffany, sans ton travail, ce projet n'aurait pas abouti.

A Olivier et Adel, ainsi que l'équipe de Chambéry, qui concilient sérieux et bonne humeur.

A Karine, pour ton coup de vitréotome aussi sûr que tes goûts musicaux.

A Florent, pour vos connaissances et votre rigueur.

A Diane, ton énergie n'enlève rien à ton dévouement pour tes patients, j'espère que ta méthode « pour les nuls » de la phaco continuera à nous faire progresser. Le monde de la cornée ne tournerait plus rond sans ton disque de Placido.

A Pierre et Dominique, pour vos bonnes ondes.

A Brigitte, Jean-Yves, Viviane, Ruxandra, avec vous la rétine nous livre ses secrets.

A Denis, le seul à pouvoir communiquer avec les Dieux de l'orbite.

A Elisabeth, le trait d'union entre la montagne et l'ophtalmologie.

A Ralitsa, exigeante mais pas intransigeante, j'ai vraiment appris à te connaître en dehors du boulot.

A Magali, profite de ta nouvelle vie.

A Aurélie, travailler avec toi a été un plaisir.

A mes cointernes

A Thierry, ne change rien.

A Benjamin, nous avons usé nos volk sur le banc de l'école annécienne.

A Joséphine, sous le soleil bien mérité, ne nous oublie pas.

A ma complice Caroline, le Sud ave l'accent !

A Mathilde, merci pour tes petites attentions toute en discrétion mais très appréciées.

A Cécile, de la dentelle sous le néoprène. Prends soins de toi.

A Nischal, le sommet népalais de zenitude.

A Frédéric et Georges, le semestre à Chambéry m'aura appris à vous connaître. Depuis, nous avant tant partagé.

A Marco, tu es le rayon de soleil du service avec ton humour à toute épreuve et ta joie de vivre communicative.

A Rachel, Julie, Adriane, Olivier, Perrine, merci pour nos échanges. Bonne continuation à vous.

Aux équipes médicales

Du 8^{ème} et du bloc, votre soutien durant toutes ces années, et plus particulièrement ces dernières semaines, m'a permis de traverser les épreuves.

A mes amis

Aymeric et Hélène, Pierre et Claire, Chap et Marie, Elise, Anne, Domitille et Quentin, Camille et Benoit, Priscilla, pour nos années d'étude lilloises. Malgré la distance, nous avons su entretenir ce lien qui nous a uni et qui continue à nous rapprocher.

Aurélié, Morine, Thibaut, Benjamin, Cécile, Laurence, Julien, Anne, Clotilde, à la chance que l'internat nous a offert de nous connaître.

A Valentin, plus qu'un ami, tu es comme un frère. J'attends de toi que tu enseignes à Jules l'école de la vie.

A Johanna, je compte sur toi pour me remettre à niveau quand Jules entrera au CP.

Aux amis de toujours, Fanny et Vianney. Les mots sont dérisoires pour exprimer ce que vous représentez pour moi et ce que je vous dois depuis toutes ces années.

A ma famille

A ma belle-famille, vous m'avez accueilli sans préjugés comme un fils ou un frère j'ai trouvé auprès de vous un deuxième foyer.

A mes belles sœurs et mes frères, nous avons partagé tant de bons moments.

A ma petite sœur, qui aime bien châtie bien.


A maman, je suis fier d'être ton fils. Ton dévouement n'a eu de cesse de faire de tes enfants des adultes avec des racines et des ailes.

A Bon Papa Jules et mon fils Jules, vos présences illuminent ma vie.

A Bonne Maman, ta mémoire est vivante.

A Christine, derrière chaque grand homme, se cache une femme d'exception. Vivre à tes côtés fais de moi un homme accompli. Te quiero

SERMENT D'HIPPOCRATE



En présence des Maîtres de cette Faculté, de mes chers condisciples et devant l'effigie d'Hippocrate,

Je promets et je jure d'être fidèle aux lois de l'honneur et de la probité dans l'exercice de la Médecine.

Je donnerai mes soins gratuitement à l'indigent et n'exigerai jamais un salaire au-dessus de mon travail. Je ne participerai à aucun partage clandestin d'honoraires.

Admise dans l'intimité des maisons, mes yeux n'y verront pas ce qui s'y passe ; ma langue taira les secrets qui me seront confiés et mon état ne servira pas à corrompre les mœurs, ni à favoriser le crime.

Je ne permettrai pas que des considérations de religion, de nation, de race, de parti ou de classe sociale viennent s'interposer entre mon devoir et mon patient.

Je garderai le respect absolu de la vie humaine.

Même sous la menace, je n'admettrai pas de faire usage de mes connaissances médicales contre les lois de l'humanité.

Respectueuse et reconnaissante envers mes Maîtres, je rendrai à leurs enfants l'instruction que j'ai reçue de leurs pères.

Que les hommes m'accordent leur estime si je suis fidèle à mes promesses.

Que je sois couverte d'opprobre et méprisée de mes confrères si j'y manque.

TABLE DES MATIÈRES

RÉSUME.....	14
INTRODUCTION.....	15
MATÉRIEL ET MÉTHODE.....	17
RÉSULTATS	21
DISCUSSION.....	25
CONCLUSION.....	27
RÉFÉRENCES BIBLIOGRAPHIQUES.....	28
FIGURES ET TABLEAUX.....	34

Prospective study of serum anti-Hsp70.1 IgG antibody levels in the diagnostic certainty of clinically suspected ocular toxoplasmosis

B.F.F. Chumpitazi¹, H. Fricker-Hidalgo¹, M-P. Brenier-Pinchart¹, H. Pelloux^{1,9}
A. Lesoin², F. Aptel², J-P Romanet², C. Chiquet²
N. Campolmi⁵, P. Flori⁶,
C. Vasseneix⁷,
O. Savy⁸,
L. Bouillet^{3,4}

¹ Laboratory of Parasitology and Mycology, ² Department of Ophthalmology, ³ Department of Internal medicine, Joseph Fourier University (Grenoble 1), Grenoble University Hospital, France; ⁴ INSERM unit 1036, CEA-Grenoble, Joseph Fourier University (Grenoble 1), France; ⁵ Department of Ophthalmology, ⁶ and Laboratory of Parasitology and Mycology, University Hospital of Saint Etienne and Jean Monnet University, Saint Etienne, France; ⁷ Department of Ophthalmology, Valence Hospital, France; ⁸ Department of Ophthalmology, Chambéry Hospital, France; ⁹ CNRS UMR 5163, Joseph Fourier University (Grenoble 1), France

Running head: Serum anti-Hsp70 antibodies in ocular toxoplasmosis

Correspondence: Dr. Bernabé F. F. Chumpitazi, Laboratoire de Parasitologie-Mycologie, DAI, Pôle Biologie, CHU de Grenoble, Hôpital Michallon, BP 217, F-38043 Grenoble, FRANCE

Fax: +33-4-76-76-56-60; phone: +33-4-76-76-54-90

E-mail: BChumpitazi@chu-grenoble.fr

Key words: ocular toxoplasmosis, uveitis, diagnosis, anti-Hsp70 antibody, *Toxoplasma gondii*

ABSTRACT

PURPOSE. Laboratory diagnosis of ocular toxoplasmosis (OT) needs to be improved mainly in clinical atypical cases. In a retrospective previous study, infected patients could display serum IgG anti-Hsp70.1 antibodies and that these antibodies could be used to improve the diagnosis of OT. The purpose of this multicentre prospective case-control study was to correlate clinical features with IgG anti-Hsp70 antibodies.

METHODS. We have included patients with confirmed (Group A1) or suspected OT (Group A2), and with cataract (Control Group B). The diagnosis was based on the ocular presentation, Goldmann-Witmer's coefficient, immunoblotting and/or PCR. Serum and aqueous humour (AH) were sampled at the time of uveitis. ELISA was used to measure serum anti-Hsp70.1-antibody levels. The OT patients were clinically followed up to six months and laboratory monitored up to three months.

RESULTS. Serum IgG anti-Hsp70.1 antibody levels were related to the affected retinal zone ($p=0.006$) and were correlated significantly to the retinal lesion size ($p<0.05$). Serum anti-Hsp70.1 and AH IgG anti-*Toxoplasma* antibodies were respectively positive in 10 and 5 out of 18 cases of Group A2 that were finally classified as true-clinically suspected OT.

CONCLUSIONS. Anti-Hsp70 may be involved directly or indirectly in the retinal lesions during ocular *Toxoplasma* infection and related to the affected retinal zone. Anti-Hsp70.1 antibody may confirm biologically suspected OT with an increasing specificity when associated with the presence of AH IgG anti-*Toxoplasma* antibodies. The value of AH anti-Hsp-70 antibody levels in the laboratory diagnosis of OT will further evaluated.

Toxoplasma gondii is a parasite widespread throughout the world; the seroprevalence has been estimated up to one third of the human population with considerable geographical differences that are also related to environmental, social and food hygiene factors.¹ Ocular toxoplasmosis (OT) may lead to a poor visual prognosis especially when the macula is impaired or when other complications occur.² Active creamy-white focal retinitis with or without a previous pigmented chorioretinal scar is the classical presentation of OT.³⁻⁵ This presentation can also be atypical such as punctuate outer retinal toxoplasmosis, retinal vasculitis, retinal detachment, unilateral pigmentary retinopathy mimicking retinitis pigmentosa, neuroretinitis, papillitis and pseudo-multiple retinochoroiditis.^{6,7}

Laboratory testing is useful to confirm the infection in the cases of the atypical lesions, macular lesions and/or unexpected therapeutic response. For the diagnosis of OT, the sensitivity of the Desmots' coefficient or Goldmann-Witmer coefficient (GWC) is 74% with a specificity of 100%, and these values may vary in terms of studies and when sampling was performed⁸⁻¹⁰. In atypical OT cases, GWC sensitivity may decrease to 36 % and specificity to 93%¹¹. Despite improvement of diagnostic tests such as the Polymerase Chain Reaction (PCR) and quantification of anti-*Toxoplasma* antibodies^{7, 12, 13}, the sensitivity of the laboratory diagnosis remains unsatisfactory at the present time.

Heat shock protein 70 (Hsp70) is up-regulated during cellular stress, it is involved in the novo protein folding, refolding of stress denatured proteins, protein transport as well as in intracellular antigen processing and inflammatory process.¹⁴⁻¹⁷ The expression of *T. gondii* Hsp70 and bag1/Hsp30 has been linked with bradyzoite growth and during the conversion of bradyzoites to tachyzoites during *Toxoplasma* reactivation.^{18, 19} The expression of *T. gondii* Hsp70 is also related with the virulent

strains and is up regulated just before death of the host cell.^{20, 21} Hsp70 is released from cells during necrosis and/or through physiological secretion mechanisms, enters the bloodstream and possesses the capacity to operate at distant sites in the body.²² Moreover, significant protection against *Toxoplasma* infection in B6 and Balb/C mice may be induced by vaccination with *T. gondii* Hsp70 gene that is associated with dendritic cell activation and Th1 polarization.^{23, 24} Anti-Hsp70 IgG autoantibody, produced by B-1 cells of C57BL/6 mice, has been observed after *T. gondii* infection.^{25,}

26

The presence of human anti-Hsp70.1 antibody has been previously investigated in a retrospective study with patients clinically suspected of OT.²⁷ We showed: a) the serum anti-Hsp70.1 antibody test could confirm clinically suspected OT and b) these levels correlated to the retinal lesion size.²⁷ We hypothesized that anti-Hsp70 antibodies: (1) are also present in aqueous humour of clinically suspected OT patients and their quantifications may improve the diagnostic strategy; (2) decrease in the follow-up of OT patients, and (3) are not present in patients with cataract.

The purpose of this prospective multicentre study was to confirm the contribution of anti-Hsp70 IgG antibody in the diagnosis of OT and their relationship with the retinal lesion size. The secondary objectives were the study: (1) of the association among anti-Hsp70 IgG antibody levels and clinical characteristics of inflammation, and (2) the contribution of anti-Hsp70 IgG antibody levels during the clinical follow up.

PATIENTS, MATERIALS AND METHODS

Patient and control groups

Our research adhered to the tenets of the Declaration of Helsinki and to Good Clinical Practice guidelines and was approved by the local Institutional Review Board (IRB #6705). This multicentre prospective study included patients from four French hospitals (Grenoble, Chambéry, Saint-Etienne and Valence) between 2010 and 2013. The inclusion criteria were patients with uveitis and one or more retinitis lesions (Group A1, confirmed OT and Group A2, suspected OT) or patient operated on for cataract surgery (control Group B) being older than 18 years old and signed informed consent. The exclusion criteria were: pregnant woman, nursing mother, patients refusing anterior chamber puncture and patients with non-predictable follow-up. Group A2 was divided in two sub-groups: true suspected clinically OT (Sub-group A2-Toxoplasmosis (A2-T)) and other uveitis different than OT (Sub-group A2-Non-Toxoplasmosis (A2-NT)). The Gold standard group was composed of Group A1 and Sub-group A2-T.

The definition of clinical OT was the presence of at least one active creamy-white focal retinal lesion in either eye combined or not with pigmented lesion scars in either eye³⁻⁵. Atypical clinical OT was defined as neuroretinitis, papillitis, iridocyclitis, retinal detachment and acute retinal necrosis⁶.

GWC is defined as X/Y ; where $X = \textit{Toxoplasma}$ IgG antibody in aqueous humour (AH) divided by total IgG in AH; and $Y = \textit{Toxoplasma}$ IgG antibody in serum divided by total IgG in serum. Laboratory confirmed OT required at least one of the following criteria: a $GWC \geq 2$; AH anti-*T. gondii* neo-synthesized antibodies detected by immunoblotting (WB, *Toxoplasma* Western-blot IgG-IgM, LDBIO Diagnostics, Lyon, France); and positive genomic *T. gondii* DNA amplification by polymerase chain

reaction (PCR) in the AH (target *T. gondii* rep452, LightCycler 2.0, Roche, Grenoble, France).^{9, 12, 28, 29 30}

For each patient, five visits with a detailed ocular examination were performed: at time of inclusion, at 3, 6, 12 and 24 weeks. The data were collected at each site using the same case report form (CRF). The OT patients were laboratory monitored up to 12 weeks. Underlying diseases, immunosuppression and other causes of uveitis were also examined.

Patients were grouped according to clinical and biological criteria. Group A1 included patients with at least one manifestation of retinitochoroiditis and laboratory confirmed OT by at least one three tests cited above. Group A2 included patients with at least one manifestation of retinitochoroiditis and non-laboratory confirmed OT by any of the three tests cited above. Control Group (B) included patients with cataract without associated ocular disease (including uveitis or diabetes).

Ophthalmologic parameters

Each patient underwent a completed ophthalmologic examination, including the best corrected visual acuity (BCVA) expressed in logarithm of minimum angle of resolution (LogMAR), intraocular pressure (IOP), score of inflammation (anterior chamber cells and the reflection of light from proteins in the AH (flare)),³¹ vitritis, number and localization of active lesions and scar related to posterior and anterior segments,³² retinal vasculitis, retinal necrosis, or papillitis.³³

Colour retinal fundus (Topcon TRC50EX®, Tokyo, Japan) was performed at each visit. Fluorescein and indocyanine green (ICG) angiographic photographs (Spectralis ® HRA-OCT, Heidelberg, Germany) were also performed at the inclusion visit. Images were analysed by counting pixels using the Image J software (National

Institute of Health) for the calculation of the ratio of the lesion size and size of the optic nerve disc on ICG and colour frames. However good quality photos could not be done for all patients caused by cataract or vitritis.

A mapping of the posterior pole was performed by optical coherence tomography (OCT) (Spectralis®, HRA-OCT, Heidelberg, Germany). Foveal central subfield thickness was defined as the average thickness in the central 1- μ m-diameter circle of the Early Treatment Diabetic Retinopathy Study (ETDRS) region after verification of the centring the macula.

Location of lesion was defined within zone 1 of the retina (region extending 3000 μ m from the foveal centre), zone 2 (the region extending from the border of zone 1 to the equator) and zone 3 (the region from the border of zone 2 to the ora serrata).³⁴

Anti-Toxoplasma therapy

In cases of active toxoplasmic retinochoroiditis, the anti-*Toxoplasma* treatment was at the discretion of the investigator: pyrimethamine (1 mg/kg/day; n=9), sulfadiazine (100 mg/kg/day) and folinic acid (50 mg/week) or trimetoprim (160 mg/day; n=24) + sulfamethoxazole (800 mg/day) (TMP/SMX) or pyrimethamine (1 mg/kg/day; n=15) + azithromycin (500 mg/day) for at least six weeks. The initial anti-*Toxoplasma* treatment was changed if adverse effects were noted. The anti-*Toxoplasma* treatment was prolonged in OT cases if healing of ocular lesion was not observed.

Combination of anti-parasite drugs with corticosteroids (prednisone per os at initial dosage of 1 mg/kg/day) was usually administered and tapered for limited periods of 1 or 2 months in case of active toxoplasmic lesions near the macula or optic nerve or in case of severe intra-ocular inflammatory response.³⁵

Anti-Toxoplasma antibodies

Indirect Immunofluorescence and Enzyme Linked Fluorescent Assay (ELFA) screened all groups for serum IgG and IgM anti-*Toxoplasma* antibodies (Toxo IgG, IgM, bioMérieux, Marcy l'Etoile, France)³⁶. The combination of ISAGA (Toxo IgM, bioMérieux) and IgG avidity test (VIDAS, bioMérieux) was used to confirm acute toxoplasmosis in patients.³⁷

Anti-Hsp70.1 antibodies

Serum anti-Hsp70.1 levels were assayed by ELISA as described elsewhere^{27, 38} but with some modifications: a) coating was with 100 µl of human recombinant Hsp70 (NSP-555, Stressgen- Enzo Laboratories, Villeurbanne, France) /well at 2 µg of protein/ml; b) each assay was repeated three times; c) the wells were incubated with 100 µl of sera diluted to 1/200 for 1 h at 37°C; d) the enzymatic activity was developed with 0.75 mg/ml *o*-phenylene-diamine dihydrochloride, 0.03 % sodium perborate in 0.05 M citrate phosphate buffer, pH 5, for ten minutes at room temperature in the dark. The reaction was stopped with 200 µl of 2 N H₂SO₄ and absorbance read at 492 nm. Reproducibility for intra and inter assays was higher than 95%. The confirmation of the test specificity was established by inhibition of the antibody response with human recombinant Hsp70 (5µg/ml).³⁸

Determination of cut-offs

The most appropriate cut-off level of IgG anti-Hsp70.1 antibodies was determined as previously described except for using the cataract Group B without uveitis and diabetes as control instead the blood-donor healthy group³⁸. Briefly, the cut-off was selected by the best addition of the Youden's index and Yule's Q coefficient. The cut-offs were represented and calculated in a receiver operating characteristic (ROC) curves for serum IgG anti-Hsp70.1, and AH IgG anti-*Toxoplasma* antibodies.

Statistical analysis

For data with normal distribution the mean, standard deviation (SD) and the range were given, otherwise the median, 10th centile and 90th centile were reported. Non-parametric tests were employed. The correlations were established with Z correlation coefficients. Kruskal-Wallis Test (3 groups) and then by the Mann-Whitney's U Test (2 groups) were used to establish significant differences between data sets. Friedman's test (3 groups) and then Wilcoxon's rank test (2 groups) were used for paired variables. The statistical analysis was performed using Statview software (SAS Institute Inc.). Statistical significance was defined as a two-tailed p-value less than 0.05.

RESULTS

The characteristics of the enrolled patients are shown in Table 1. Twenty-one patients were included with clinically suspected and biological confirmed OT (Group A1), 30 patients with a clinically suspected OT but lacking laboratory confirmation (Group A2) and 42 patients with cataract (Control group B, Table 1). The biological confirmation was done by GWC and/or PCR and/or immunoblotting (Table 1). The number of retinochoroiditis-affected eyes was 24 and 32 for Group A1 and A2, respectively (Table 1). At the beginning of the study, eleven of these affected eyes (5 in Group A1 and 6 in Group A2) presented bordered pigmented and active lesions indicating a possible *Toxoplasma* reactivation with or without a previous OT history. Ten patients (6 in Group A1 and 4 in Group A2) presented medical history of former OT episodes. None of these ten patients had a medical history of congenital toxoplasmosis. Patients' BCVA gain was ≥ 2.8 lines at 3 months (Table 1). Retinal lesion size, IOP, and mean time of ocular lesion healing are also shown in Table 1 as well as the toxoplasmic serological status of the patients.

Serum IgG or IgM anti-*T. gondii* antibody levels in the three study groups (Figure 1)

The three groups A1, A2 and B showed a significant statistical difference in the levels of serum IgG or IgM anti-*Toxoplasma* antibodies ($p=0.009$ and $p=0.02$, respectively; figure 1). Significant differences were observed between A1 and B groups for IgG ($p=0.02$) and IgM anti-*Toxoplasma* antibodies ($p=0.004$) as well as for IgG anti-*Toxoplasma* antibodies ($p=0.008$) between A2 and B groups. Non-statistical significant differences in the levels of serum IgG or IgM anti-*Toxoplasma* antibodies were observed between A1 and A2 groups.

Serum anti-Hsp70.1 IgG antibodies among the groups

The levels of serum IgG anti-Hsp70.1 antibodies among the three groups at the time of inclusion are shown in Figure 2a. Figure 2b shows the levels of anti-Hsp70.1 antibodies in the sub-group A2-T (toxoplasmosis), true suspected clinically OT, and A2-NT (non-toxoplasmosis), other uveitis different than OT. The kinetics of serum IgG anti-Hsp70.1 antibody levels in three patients is illustrated in Figure 3a-c. The Figure 3d shows the box plots of serum IgG anti-Hsp70 antibody levels in the gold standard group during the follow up at to 24 weeks. These levels had a tendency to decrease during the follow-up.

Relationships among OT parameters, local and systemic immunity

Table 2 shows the relationships among OT findings, ocular and systemic immunity. Serum IgG anti-Hsp70.1 antibodies were significantly correlated with the chorioretinal lesion size. Despite lesion size measured by ICG was higher than size obtained by the colour photographs ($n=27$, $p=0.0001$) both measurements were highly correlated ($r=0.919$, $p<0.0001$).

Serum IgG anti-Hsp70.1 antibodies were related to the affected retinal zones (n=41, p=0.006; Figure 4) with higher values in affected retinal zone 1 (0.361 ± 0.218) and 2 (0.341 ± 0.186) (n=30, p=0.002 and n=17, p=0.005, respectively) than in the zone 3 (0.151 ± 0.040). After the Bonferroni adjustment the p values remained significantly.

AH IgG anti-*Toxoplasma* antibody levels were not statistically related to the affected retinal zones (n=29, p=0.23): zone 1 (9.2 (mean) \pm 20.1 (SD)), zone 2 (20.2 ± 27.9) and zone 3 (3.4 ± 4.7).

Serum IgG anti- *Toxoplasma* antibody levels were not statistically associated to the affected retinal zones (n=41, p=0.992): zone 1 (212 ± 386); zone 2 (258 ± 533) and zone 3 (304 ± 488).

Serum IgM anti- *Toxoplasma* antibody levels were equally not statistically connected to the affected retinal zones (n=41, p=0.136): zone 1 (1.07 ± 2.14); zone 2 (0.43 ± 1.06) and zone 3 (0.08 ± 0.08).

The affected retinal zones were related to the number of active chorioretinal lesions (n=39, p=0.04): zone 1 (1.3 ± 0.8); zone 2 (0.9 ± 0.3) and zone 3 (1.5 ± 0.5). The number of active chorioretinal lesions was significantly higher in affected retinal: zone 1 than zone 2 (n=33, p=0.05) and zone 3 than zone 2 (n=16, p=0.02).

Serum IgG anti-Hsp70.1 antibody levels were not associated to the presence (0.349 ± 0.237) or absence (0.308 ± 0.182) of macular oedema (n=44, p=0.94) nor with the presence (0.258 ± 0.065) or absence (0.328 ± 0.185) of vasculitis at the time of patient's inclusion in the study (n=40, p=0.52).

Serum IgG anti-Hsp70.1 antibody levels were not related with the three groups of vitritis formed in terms of vitreous haze grading scale: A <1; B ≥ 1 and ≤ 2 ; C >2: (n=44, p=0.11).

Discrimination among groups using serum IgG antibodies anti-Hsp70 and AH IgG antibodies anti-*Toxoplasma*

Table 3 shows the evaluation of diagnostic value of OT using the serum IgG antibodies anti-Hsp70 and AH IgG antibodies anti-*Toxoplasma* in terms of the cut-offs obtained by the ROC curve. Ten and five patients of sub-Group A2-T were positive in serum IgG anti-Hsp70 and AH IgG anti-*Toxoplasma* antibodies, respectively.

After revision of clinical data, a gold standard Group was formed with Group A1 and Sub-Group A2-T (Figure 5a). The Sub-Group A2-T was a part of the Group A2 and represents the true clinically OT cases (Figure 5a). Ten out of 39 patients of the gold standard group (25.6%) presented medical history of OT episodes from one to 46 months before the study. Three patients presented OT recurrences from one to six months during the study and two patients an OT recurrence after 18 months.

Serum IgG anti-Hsp70 antibodies were not statistically different among the OT gold standard, non-OT and control groups (n=93, p=0.57).

AH IgG anti-*Toxoplasma* antibodies were statistically different among confirmed OT, true clinically OT and other uveitis different than OT (n=32, p=0.002). These antibodies were significantly higher between confirmed OT (A1) than in true clinically OT (A2-T; n=25, p=0.01) and between A1 and other uveitis different than OT (A2-NT; n=21, p=0.002). However no significant difference was observed between A2-T and A2-NT sub-group (n=18, p=0.30).

Value of serum anti-Hsp70.1 antibodies to confirm clinically suspected cases of OT

The number of biologically confirmed OT cases was 21 (Group A1) after taking into account the sensitivities of the tests used. After review of the clinical records of Group A2 and the evolution after treatment, the OT clinical diagnosis was considered for 18 (A2-T Sub-Group) out of 30 patients (Figure 5a); Ten out of these 18 patients

were found positive for serum IgG antibodies anti-Hsp70. Four out of these ten patients (nd=3) were positive for AH IgG anti-*Toxoplasma* antibodies. We have established that four out of the twelve patients (A2-NT Sub-Group) who had initially uncertain diagnosis or not diagnosed as OT, were positive for serum IgG anti-Hsp70 antibodies while other diagnosis were finally selected: idiopathic occlusive vasculitis (n=1), endogenous endophthalmitis (n=1), PCR-proved-HSV keratouveitis (n=1) and idiopathic uveitis (n=1). Absence of AH IgG anti-*Toxoplasma* antibody was observed in these four cases. Thus, AH IgG anti-*Toxoplasma* antibody test can help to increase the specificity of the anti-Hsp70 serology. A case of VZV acute retinal necrosis presented positive AH IgG anti-*Toxoplasma* antibody levels were associated with negative anti-Hsp70 serology. In the eight patients of the A2-NT Sub-Group with negative IgG anti-Hsp70 serology, the other diagnoses were: PCR-proved-HSV keratouveitis (n=3), idiopathic uveitis (n=1), multifocal chorioretinitis (n=1) and PCR-proved-VZV acute retinal necrosis (n=3).

DISCUSSION

Our results of this prospective study show the presence of anti-Hsp70.1 antibodies in sera of patients with laboratory confirmed and clinically suspected OT that were related to the affected retinal zone and to retinal lesion size. These findings are consistent with the production of anti-Hsp-70 auto-antibodies by resistant Balb/C and susceptible C57BL/6 mice²⁵ and with our previous retrospective report.²⁷ The conserved Hsp70 N-terminal ATP binding domain of *T. gondii* may be involved in the induction of IgG antibodies anti-Hsp70 by a cross reaction mechanism.^{26, 39} The production of these antibodies is transitory in mice and in all probability in humans as demonstrated in several cases in the present study.^{40 27} Antibody transfer across the

blood retina barrier is uncommon⁴¹. The presumably hypothesis of Chen et al was that *T. gondii* Hsp70 could penetrate the blood-retina barrier.²⁵ Calderwood et al suggested that Hsp70 can go into the bloodstream after release of intracellular Hsp70 by active secretion mechanisms or following necrosis.²² *T. gondii* Hsp70 might be captured by antigen presenting cells via their Hsp70 receptors and be carried through the trabecular meshwork via the blood vessels.⁴² A relationship between intraocular toxoplasmic immunity and the systemic immunity is suggested by a positive correlation between these antibodies and the retinal lesion size in the present prospective study and in the former study.²⁷

We consider that the gold standard for the diagnosis of OT remains the ophthalmologic examination, although atypical lesions may complicate the clinical diagnosis.^{6, 7, 43, 44} Laboratory tests are then usually used to confirm the suspicion of OT. In the present prospective study, fourteen of our cases were confirmed by a GWC \geq 2, four by PCR, and five by immunoblotting. Additional diagnosis was suggested in ten and five patients of sub-Group A2-T by the presence of serum IgG anti-Hsp70 and AH IgG anti-*Toxoplasma* antibodies, respectively. As observed in the present and in the former study anti-Hsp70 antibody responses are in some cases complementary to the classical immunological response to *T. gondii* antigens.²⁷ This complementary immune response may be due to the deviant immune response in the eye.^{45, 46} The fact that the eye immune response comprises the classical and non-classical ones with some particularities was supported elsewhere.⁴⁷ To confirm clinically suspected OT cases, we recommend the following algorithm: a) perform GWC and/or PCR and/or immunoblotting; b) if GWC or PCR or immunoblotting are not informative carry out complementary analysis with the anti-Hsp70 antibody test; c) if this test is positive the clinically suspected case could be confirmed. Nevertheless,

Hsp70 may be expressed as a result of other diseases like ocular myasthenia gravis and thus the ophthalmologic information should always be taken into reflection when diagnosing OT.⁴⁸ In the present study the specificity of the anti-Hsp70 test was increased when associated with the presence of AH IgG anti-*Toxoplasma* antibodies. This also emphasizes the significance of the kinetics of evolution of anti-Hsp70 antibody levels in each patient, before, during and after the episode of OT and of obtaining the ophthalmological clinical data. After the successful treatment of OT, serum anti-Hsp70 may decrease as do the retinal lesion size; these results emphasize the possible relationship between levels of serum anti-Hsp70 antibodies and the lesion size. In immunocompetent OT patients, serum anti-Hsp70 antibodies may be regarded as a potential marker of OT. This conclusion is in agreement with the fact that a) Hsp70 is expressed during *T. gondii* growth and differentiation¹⁸⁻²⁰; b) Hsp70 expression is related to the virulence strain⁴⁹; c) Anti-Hsp70 IgG antibody has been observed experimentally in mice after *T. gondii* infection^{25, 26} and in humans during OT episodes.²⁷

Acknowledgements

The authors would like to thank: a) Dr T. Lacharme (CH Chambéry), Dr Poppa (CH Valence), Dr M. Tonini (CH Annecy) for their help in this prospective study; b) Dr M. Baccard (Laboratory of Virology, Grenoble University Hospital, France) for the accessibility to the serum library facilities; c) Mr. J-L Quesada and Dr. A. Foote (Clinical Research Centre, Grenoble University Hospital, France) for helpful statistical discussions and for English editing, respectively.

This study was supported by the Grant N° 0919 of the “Direction de la Recherche Clinique et de l’Innovation” of the Grenoble University hospital, France.

No conflicts of interest exist for any of the authors.

References

1. Furtado JM, Winthrop KL, Butler NJ, Smith JR. Ocular toxoplasmosis I: parasitology, epidemiology and public health. *Clin Experiment Ophthalmol* 2013;41:82-94.
2. Dodds EM, Holland GN, Stanford MR, et al. Intraocular inflammation associated with ocular toxoplasmosis: relationships at initial examination. *Am J Ophthalmol*. 2008;146:856-65.
3. Weiss LM, Dubey JP. Toxoplasmosis: A history of clinical observations. *Int J Parasitol*. **2009**;39:895-901.
4. Holland GN, O'Connor GR, Belfort RJr, Remington JS. Toxoplasmosis. In: Pepose JS, Holland GN, Wilhelmus KR, eds. *Ocular infection and Immunity*. St. Louis MO: Mosby-Year book, **1996**.
5. Vasconcelos-Santos DV, Dodds EM, Oréface F. Review for disease of the year: differential diagnosis of ocular toxoplasmosis. *Ocul Immunol Inflamm* 2011;19:171-9.
6. Smith JR, Cunningham ETJr. Atypical presentations of ocular toxoplasmosis. *Curr Opin Ophthalmol*. **2002**;13:387-92.
7. Fardeau C, Romand S, Rao N, et al. Diagnosis of toxoplasmic retinochoroiditis with atypical clinical features. *Am J Ophthalmol*. **2002**;134:196-203.
8. Goldmann H, Witmer R. Antikörper im kammerwasser. *Ophthalmologica* **1954**;127:323-30.
9. Desmots G. Definitive serological diagnosis of ocular toxoplasmosis. *Arch Ophthalmol*. **1966**;76:839-51.
10. Talabani H, Asseraf M, Yera H, et al. Contributions of immunoblotting, real-time PCR, and the Goldmann-Witmer coefficient to diagnosis of atypical toxoplasmic retinochoroiditis. *J Clin Microbiol*. **2009**;47:2131-5.

11. Errera MH, Goldschmidt P, Batellier L, et al. Real-time polymerase chain reaction and intraocular antibody production for the diagnosis of viral versus toxoplasmic infectious posterior uveitis. *Graefes Arch Clin Exp Ophthalmol* 2011;249:1837-46.
12. Fekkar A, Bodaghi B, Touafek F, et al. Comparison of immunoblotting, calculation of the Goldmann-Witmer coefficient and real-time PCR using aqueous humor samples for diagnosis of ocular toxoplasmosis. *J Clin Microbiol.* **2008**;46:1965-7.
13. Garweg JG. Determinants of immunodiagnostic success in human ocular toxoplasmosis. *Parasite Immunol.* **2005**;27:61-8.
14. Zügel U, Kaufmann SH. Role of heat shock proteins in protection from and pathogenesis of infectious diseases. *Clin Microbiol Rev.* **1999**;12:19-39.
15. Asea A, Kraeft SK, Kurt-Jones EA, et al. HSP70 stimulates cytokine production through a CD14-dependant pathway, demonstrating its dual role as a chaperone and cytokine. *Nat Med.* **2000**;6:435-42.
16. Asea A, Rehli M, Kabingu E, et al. Novel signal transduction pathway utilized by extracellular HSP70: role of toll-like receptor (TLR) 2 and TLR4. *J Biol Chem.* **2002**;277:15028-34.
17. Kim YE, Hipp MS, Bracher A, et al. Molecular chaperone functions in protein folding and proteostasis. *Annu Rev Biochem* 2013;82:323-55.
18. Ma YF, Zhang Y, Kim K, Weiss LM. Identification and characterisation of a regulatory region in the *Toxoplasma gondii* hsp70 genomic locus. *Int J Parasitol.* **2004**;34:333-46.

19. Silva NM, Gazzinelli RT, Silva DA, et al. Expression of *Toxoplasma gondii*-specific heat shock protein 70 during in vivo conversion of bradyzoites to tachyzoites. *Infect Immun.* **1998**;66:3959-63.
20. Lyons RE, Johnson AM. Heat shock proteins of *Toxoplasma gondii*. *Parasite Immunol.* **1995**;17:353-9.
21. Fang H, Aosai F, Mun H, et al. Anaphylactic reaction induced by *Toxoplasma gondii*-derived heat shock protein 70. *Int Immunol.* **2006**;18:1487-97.
22. Calderwood SK, Mambula SS, Gray PJJr, Theriault JR. Extracellular heat shock proteins in cell signaling. *FEBS Lett.* **2007**;581:3689-94.
23. Mohamed RM, Aosai F, Chen M, et al. Induction of protective immunity by DNA vaccination with *Toxoplasma gondii* HSP70, HSP30 and SAG1 genes. *Vaccine* **2003**;21:2852-61.
24. Makino M, Uemura N, Moroda M, et al. Innate immunity in DNA vaccine with *Toxoplasma gondii*-heat shock protein 70 gene that induces DC activation and Th1 polarization. **2011**;29:1899-905.
25. Chen M, Aosai F, Mun HS, et al. Correlation between the avidity maturation of anti-HSP70 IgG autoantibody and recombination activating gene expressions in peripheral lymphoid tissues of *Toxoplasma gondii*-infected mice. *Microbiol Immunol.* **2003**;47:217-21.
26. Chen M, Aosai F, Norose K, et al. The role of anti-HSP70 autoantibody-forming V(H)1-J(H)1 B-1 cells in *Toxoplasma gondii*-infected mice. *Int Immunol.* **2003**;15:39-47.
27. Chumpitazi BF, Bouillet L, Fricker-Hidalgo H, et al. Contribution of anti-Hsp70.1 IgG antibody levels to the diagnostic certainty of clinically suspected ocular toxoplasmosis. *Invest Ophthalmol Vis Sci* 2010;51:5530-6.

28. Pelloux H, Mouillon M, Romanet JP, et al. Toxoplasmose oculaire: comparaison de deux méthodes biologiques pour l'étude de l'humeur aqueuse. *Presse Med*. **1991**;20:1655-8.
29. Brenier-Pinchart MP, Morand-Bui V, Fricker-Hidalgo H, et al. Adapting a conventional PCR assay for *Toxoplasma gondii* detection to real-time quantitative PCR including a competitive internal control. *Parasite* **2007**;14:149-54.
30. Garweg JG, Garweg SD, Flueckiger F, et al. Aqueous humor and serum immunoblotting for immunoglobulin types G, A, M, and E in cases of human ocular toxoplasmosis. *J Clin Microbiol* 2004;42:4593-8.
31. Holland GN. A reconsideration of anterior chamber flare and its clinical relevance for children with chronic anterior uveitis (an American ophthalmological society thesis). *Am Ophthalmol Soc* 2007;105:344-64.
32. Trusko B, Thorne J, Jabs D, et al. The Standardization of Uveitis Nomenclature (SUN) Project. Development of a clinical evidence base utilizing informatics tools and techniques. *Methods Inf Med* 2013;52:259-65.
33. Butler NJ, Furtado JM, Winthrop KL, Smith JR. Ocular toxoplasmosis II: clinical features, pathology and management. *Clin Experiment Ophthalmol* 2013;41:95-108.
34. Holland GN, Lewis KG. An update on current practices in the management of ocular toxoplasmosis. *Am J Ophthalmol* 2002;134:102-14.
35. Jasper S, Vedula SS, John SS, et al. Corticosteroids as adjuvant therapy for ocular toxoplasmosis. *Cochrane Database Syst Rev* 2013;4:CD007417.
36. Fricker-Hidalgo H, Bulabois CE, Brenier-Pinchart MP, et al. Diagnosis of toxoplasmosis after allogeneic stem cell transplantation: results of DNA detection and serological techniques. *Clin Infect Dis* 2009;48:e9-e15.

37. Flori P, Chene G, Varlet MN, Sung RT. Sérologie de la toxoplasmose chez la femme enceinte: caractéristiques et pièges. *Ann Biol Clin (Paris)* 2009;67:125-33.
38. Chumpitazi BF, Bouillet L, Drouet MT, et al. Biological autoimmunity screening in hepatitis C patients by anti-HepG2 lysate and anti-heat shock protein 70.1 autoantibodies. *Eur J Clin Microbiol Infect Dis.* 2009;28:137-46.
39. Brocchieri L, Conway de Macario E, Macario AJ. Hsp70 genes in the human genome: Conservation and differentiation patterns predict a wide array of overlapping and specialized functions. *BMC Evol Biol.* 2008;8:19.
40. Mun HS, Aosai F, Yano A. Role of *Toxoplasma gondii* HSP70 and *Toxoplasma gondii* HSP30/bag1 in antibody formation and prophylactic immunity in mice experimentally infected with *Toxoplasma gondii*. *Microbiol Immunol.* 1999;43:471-9.
41. Correa D, Cañedo-Solares I, Ortiz-Alegría LB, et al. Congenital and acquired toxoplasmosis: diversity and role of antibodies in different compartments of the host. *Parasite Immunol.* 2007;29:651-60.
42. Streilein JW, Masli S, Takeuchi M, Kezuka T. The eye's view of antigen presentation. *Hum Immunol.* 2002;63:435-43.
43. Johnson MW, Greven GM, Jaffe GJ, et al. Atypical, severe toxoplasmic retinochoroiditis in elderly patients. *Ophthalmology* 1997;104:48-57.
44. Labalette P, Delhaes L, Margaron F, et al. Ocular toxoplasmosis after the fifth decade. *Am J Ophthalmol.* 2002;133:506-15.
45. Stein-Streilein J. Immune regulation and the eye. *Trends Immunol.* 2008; 29:548-54.
46. Matzinger P, Kamala T. Tissue-based class control: the other side of tolerance. *Nat Rev Immunol* 2011;11:221-30.

47. Forrester JV, Xu H. Good news-bad news: the Yin and Yang of immune privilege in the eye. *Front Immunol* 2012;3:338.
48. Helgeland G, Petzold A, Hoff JM, et al. Anti-Heat Shock Protein 70 antibody levels are increased in myasthenia gravis and Guillain-Barré syndrome. *J Neuroimmunol* 2010;225:180-3.
49. Dobbin CA, Smith NC, Johnson AM. Heat shock protein 70 is a potential virulence factor in murine *Toxoplasma* infection via immunomodulation of host NF-kappa B and nitric oxide. *J Immunol.* **2002**;169:958-65.

FIGURE LEGENDS

FIGURE 1. Box graph of serum IgG and IgM anti-*T. gondii* antibodies in the control group (B) and in suspected toxoplasmic uveitis patients (A1 and A2).

IgG (a), IgM (b) antibody anti- *T. gondii* levels observed by ELFA in sera of confirmed OT (A1), clinically suspected OT (A2) and control (B) patients. All data represents one sample per patient. The box-and-whisker plots show: the median of 21 (A1), 30 (A2) and 42 (B) measurements, respectively; the lower and upper quartiles (box) and 10th to 90th centiles (vertical bars); points above or below these levels are shown separately. The P-values for data from figure 1A and 1B were 0.009 and 0.02, respectively. Significant differences were observed between Group A1 and B (for IgG and IgM) as well as between Group A2 and B (only for IgG).

FIGURE 2. Serum levels of anti-Hsp70.1 antibodies in the control Group (B) and in suspected toxoplasmic uveitis patients (A1 and A2).

(A) The box-and-whisker plots show: the median of 21 (A1), 30 (A2) and 42 (B) averages of 3 measurements, respectively. (B) The box-and-whisker plots show: the median of 18 (A2-T) and 12 (A2-NT) averages of 3 measurements, respectively; the lower and upper quartiles (box) and 10th to 90th centiles (vertical bars); points above or below these levels are shown separately. All data represents one sample per patient.

FIGURE 3. Kinetics of serum IgG anti-Hsp70.1 antibodies in patients suspected of OT.

During this study the ocular lesions were healed in an average of 13.3±6.9 (from 5.1 to 31 weeks) after the first clinical sign of ocular inflammation. The patients were laboratory followed-up to 3 months. A sample collected at the inclusion visit was considered as the patient's reference signal. A) In one patient with laboratory

confirmed OT (Group A1) a significant decrease (47.4%) in the marker was observed (from Day 20 to Day 82); B) In one patient classified as having true-clinically OT (Sub-Group A2-T) a significant decrease (64.2%) in the marker was observed (from D5 to D87); C) In one patient with other ocular inflammation different than OT (Sub-Group A2-NT) in who a significant decrease of the marker was not observed and (D) Levels of serum IgG anti-Hsp70 antibodies during the study in the OT gold standard group. The box-and-whisker plots of Figure 3D show: the median at 0, 6 and 24 weeks, respectively; the lower and upper quartiles (box) and 10th to 90th centiles (vertical bars); points above or below these levels are shown separately. The medians had a tendency to decrease during the follow-up.

FIGURE 4. Box graph of serum IgG anti-Hsp70.1 antibodies according to the location of the chorioretinal lesion.

Serum IgG anti-Hsp70.1 antibodies were different according to the location of the chorioretinal lesion (n=41, p=0.006). Serum IgG anti-Hsp70.1 antibody levels were higher in affected retinal zone 1 (n=30, p=0.002) and 2 (n=17, p=0.005) than in the corresponding zone 3.

FIGURE 5. Serum IgG anti-Hsp70.1 antibody levels in the Gold standard group of toxoplasmic uveitis.

(A) Flow chart describing the OT gold standard group. (B). Figure 5B illustrates the variation of the serum IgG antibodies anti-Hsp70 in terms of the OT gold standard, Sub-Group-A2-NT and control Group B.

TABLE 1. Characteristics of the patients of the study

Parameters	Group A1	Group A2	Group B
Ocular toxoplasmosis	Confirmed	Suspected	Absent
Number of patients	21	30	42
Mean age years \pm SD*	41.1 \pm 15.5	51.6 \pm 21.2	73.6 \pm 13.9
Male/Female	15/6	19/11	21/21
Retinochoroiditis: affected eye	24	32	0
Lesion size, disc diameter (range)	1.9 \pm 1.4 (0.5-6)	1.1 \pm 0.9 (0-4)	
BCVA* (LogMAR) t0 \pm SD	0.73 \pm 0.80	0.59 \pm 0.77	0.65 \pm 1.08
BCVA (LogMAR) t3months \pm SD	0.45 \pm 0.63	0.29 \pm 0.52	
Improvement BCVA* (LogMAR)	0.28	0.30	
Mean time of healing (weeks) \pm SD	13.6 \pm 5.8	13.1 \pm 7.6	
Goldmann-Witmer Coefficient, GWC	Positive (n=14/16)	Negative (n=9/9); Incalculable (n=8/8) [†]	ND*
DNA <i>T. gondii</i> PCR	Positive (n=3/6)	Negative (n=14/21)	ND
Immunoblotting (WB)	Positive (n=5/6)	Negative (n=6/6)	ND
Aqueous humour (AH) IgG anti- <i>Toxoplasma</i> : IU/ml, median (range)	11 (0.9-83)	0 (0-18)	ND
Acute/Acquired toxoplasmosis ‡	2/19	3/26	0/42

Note: *BCVA: best correct visual acuity; IU: international unit; ND: not done; SD: standard deviation; [†] absence of AH IgG anti-*Toxoplasma* antibodies; ‡ ISAGA, avidity test.

TABLE 2. Z correlation coefficient (Z) among AH IgG anti-*Toxoplasma* antibody, chorioretinal lesion size, number of lesion, IOP, healing of lesion, central macular thickness by optical coherence tomography (OCT), and serum IgG anti-Hsp70.1 antibodies

Serum IgG anti-Hsp70.1 antibody and	Z	P
AH IgG anti- <i>Toxoplasma</i> antibody (n=32)	0.263	0.15
Lesion size by colour image (DD; n=32)	0.381	0.03
Lesion size by ICGA (DD; n=30)	0.343	0.06
Number of lesion (n=42)	-0.064	0.69
Intra ocular pressure (n=43)	-0.184	0.24
Healing of lesion in weeks (n=38)	0.077	0.65
Central macular thickness, μ m (n=29)	0.249	0.20

NOTE. DD: optical disc diameter; ICGA: indocyanine green angiography; Z: Z correlation coefficient.

TABLE 3. Discrimination among groups with suspected clinically OT (A1 and A2) and control Group B using serum IgG anti-Hsp70.1 and AH IgG anti-*Toxoplasma*

Parameter	IgG antibody anti-	
	Hsp70.1 (serum)	<i>Toxoplasma</i> (AH)
Youden's index	0.191	0.607
Yule's Q coefficient	0.386	0.895
Cut-offs	0.284	0.9 IU/ml
Area under de curve (AUC)	0.58	0.79
Group A1; (n=21) % (95 % CI) †	43 (9/21)† (24-64)	93 (13/14)† (72-100)
Group A2 (n=30) % (95 % CI)	47 (14/30)† (30-64)	32 (6/19)† (15-54)
Sub-Group A2-T (n=18) (95 % CI)	56 (10/18)† (34-76)	45 (5/11)† (21-72)
Sub-Group A2-NT (n=12) (95 % CI)	33 (4/12)† (13-60)	14 (1/7)† (11-48)
Cataract Control Group B (n=42) % (95 % CI)	24 (10/42)† (14-37)	Not done
Sensitivity (%) confirmed clinical OT	49 (19/39)	75 (18/24)
Specificity (%)	70	85.7
Positive Predictive Value (%)	54	94.7
Negative Predictive Value (%)	66	50

NOTE. n= number of patients; AH= Aqueous humour. OT= Ocular toxoplasmosis

† Prevalence in %; between first parentheses number of positive cases out of number of total cases; and second ones 95% confidence intervals (95% CI).

FIGURE 1. Box graph of serum IgG and IgM anti-*T. gondii* antibodies in the control group (B) and in suspected toxoplasmic uveitis patients (A1 and A2).

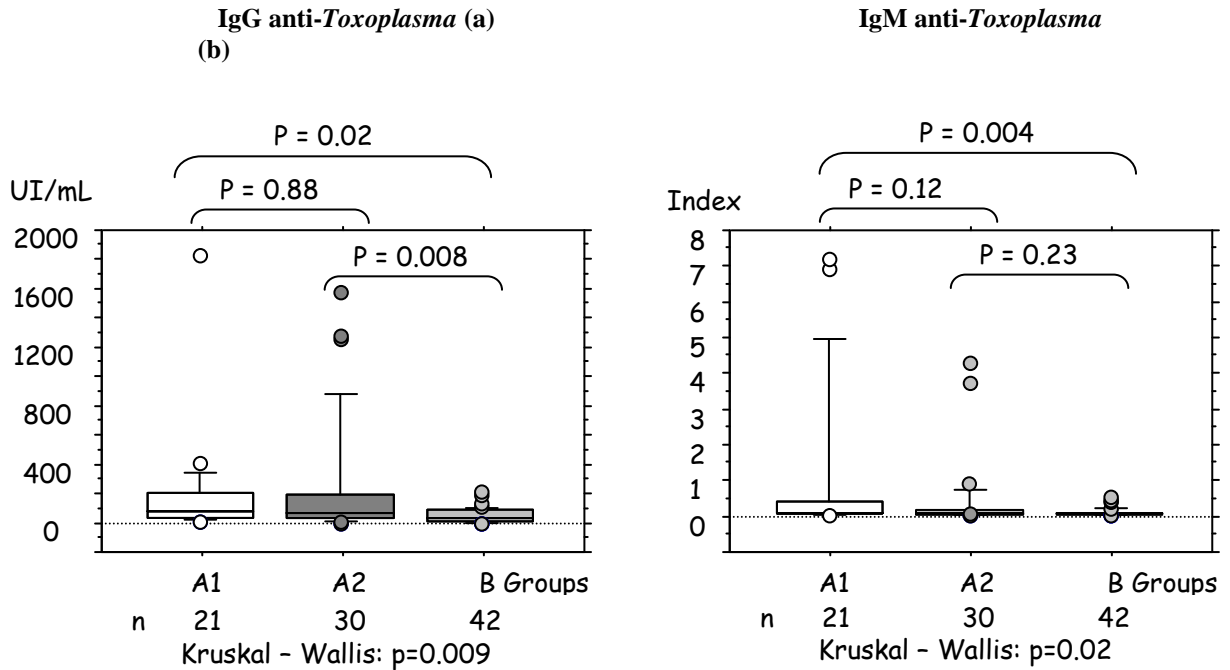


FIGURE 2. Serum levels of anti-Hsp70.1 antibodies in the control Group (B) and in suspected toxoplasmic uveitis patients (A1 and A2).

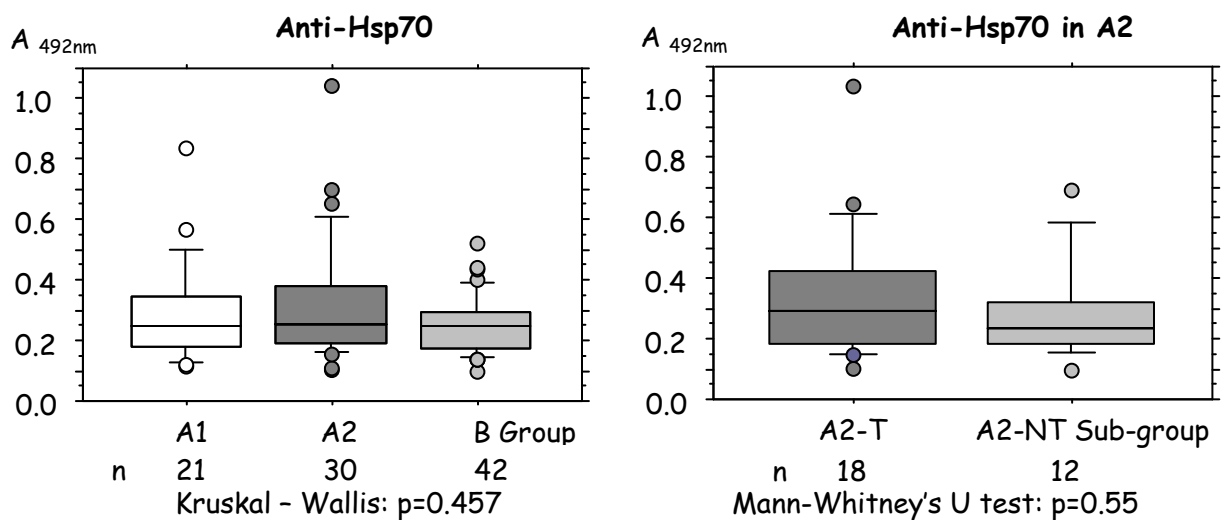


FIGURE 3. Kinetics of serum IgG anti-Hsp70.1 antibodies in patients suspected of OT.

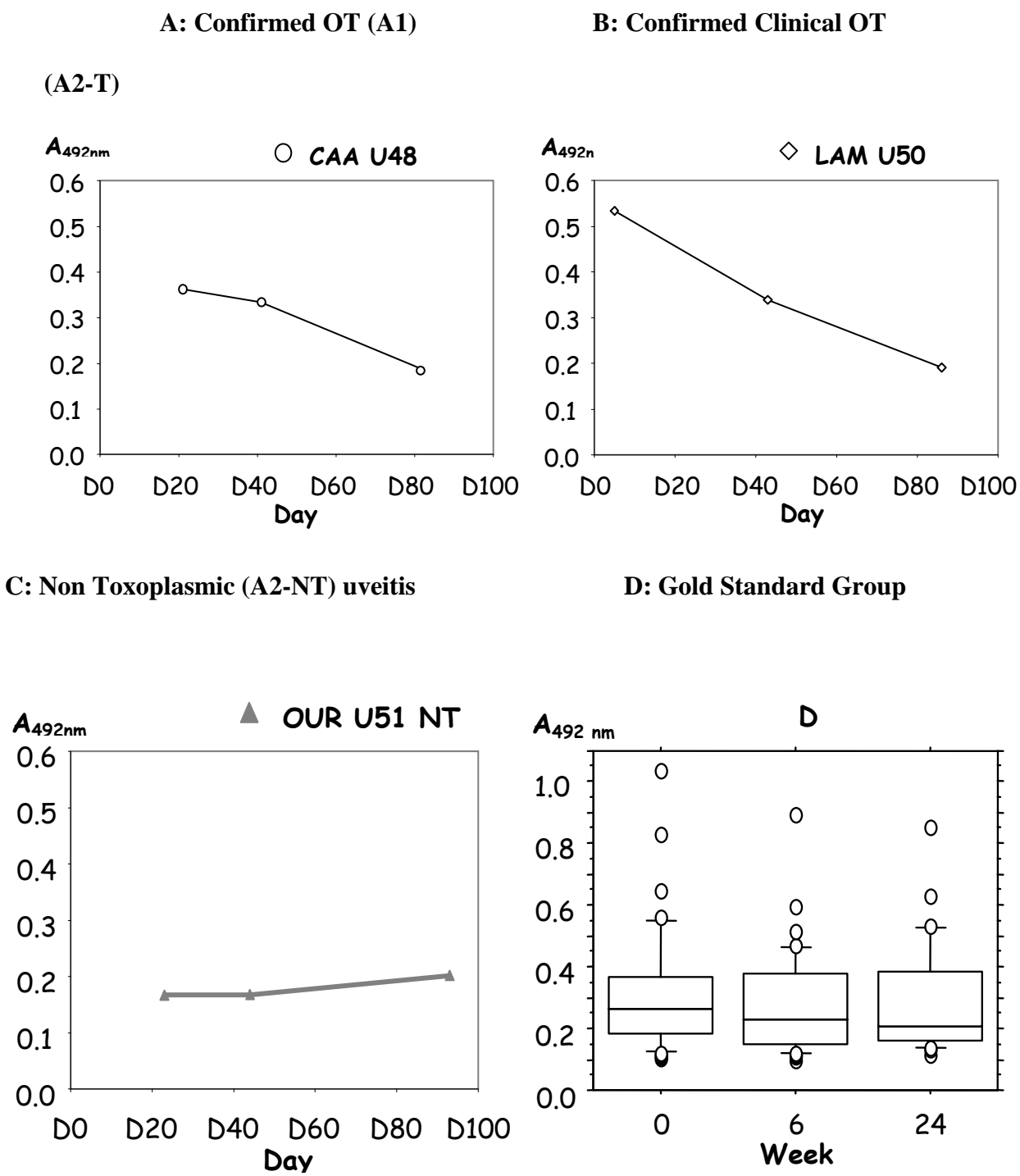


FIGURE 4 Box graph of serum IgG anti-Hsp70.1 antibodies according to the location of the chorioretinal lesion.

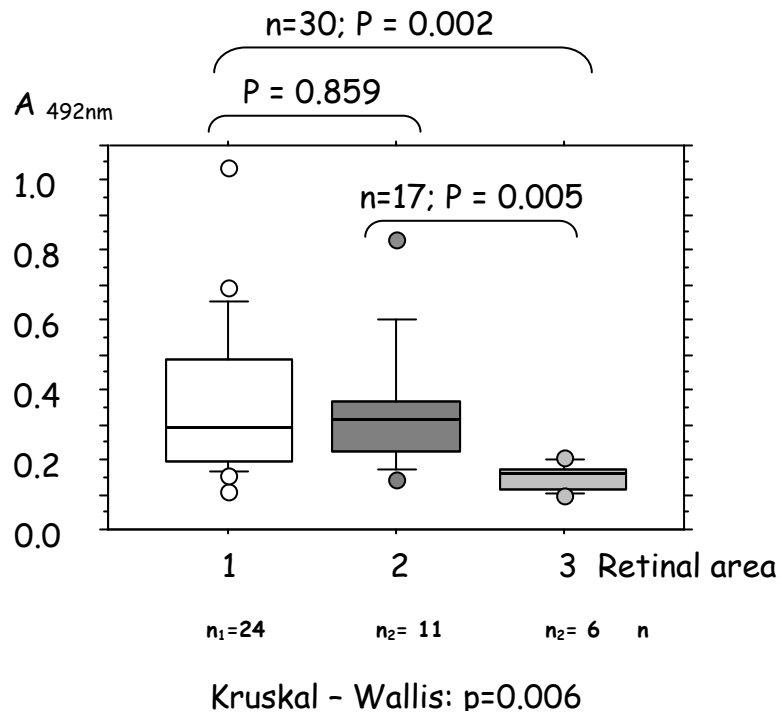
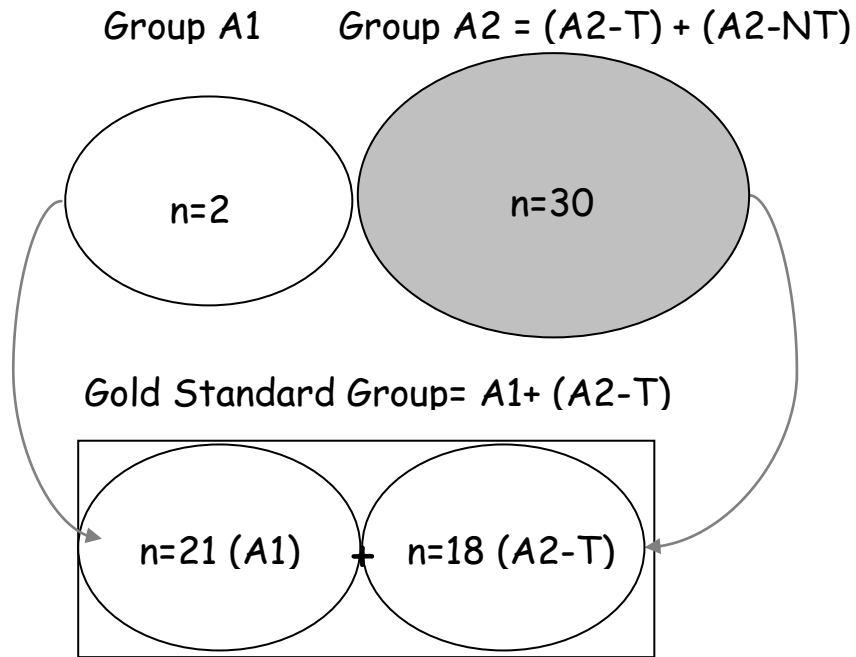
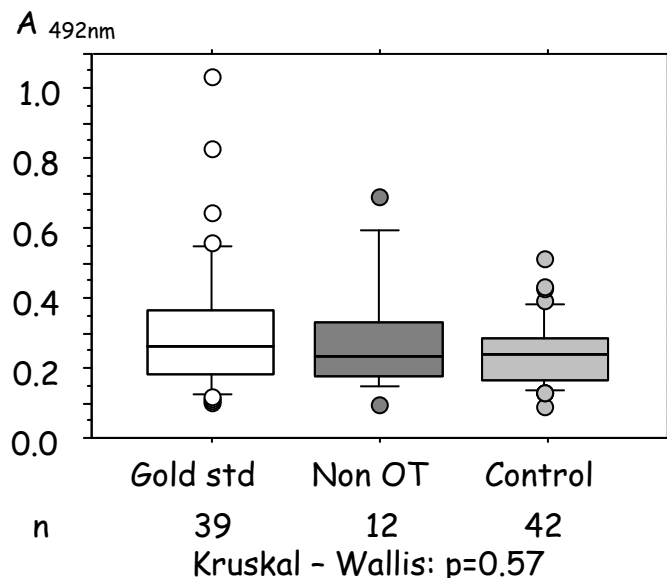


FIGURE 5. Serum IgG anti-Hsp70.1 antibody levels in the Gold standard group of toxoplasmic uveitis.

(A) Flow chart describing the OT gold standard group



(B). Box graph of serum IgG antibody anti-Hsp70 in OT Gold standard, Non-OT and Control group



THESE SOUTENUE PAR : Antoine LESOIN

TITRE : Intérêt de l'anticorps Immunoglobulines G Anti Hsp70.1 dans le diagnostic de toxoplasmose oculaire

La toxoplasmose oculaire est la première cause d'uvéite postérieure, dont le retentissement peut conduire à la cécité. L'objectif de cette étude était d'améliorer le diagnostic des formes atypiques de toxoplasmose oculaire (TO) grâce au dosage sérique d'un nouveau marqueur l'anticorps Immunoglobulines G Anti Hsp70.1 (Ac IgG Anti Hsp70.1).

Cette étude prospective et multicentrique a inclus 21 patients atteints de TO confirmés par la biologie, 30 patients suspects de toxoplasmose présentant une chorioretinite et 42 patients témoins (atteints de cataracte). La confirmation biologique faisait appel au coefficient de Goldmann-Witmer, Western Blot ou la PCR. Les taux d'anticorps ont été déterminés par méthode ELISA.

La valeur sérique de l'Ac IgG anti Hsp70.1 était significativement différente selon la zone de rétine atteinte ($p=0.006$) ainsi qu'en fonction de la taille de la lésion chorioretinienne ($p=0.03$). La détermination par la méthode de la courbe ROC d'un seuil de l'Ac IgG anti Hsp70.1 à partir des valeurs des Anticorps anti toxoplasmose dans l'humeur aqueuse n'a pas montré de différence entre nos 3 groupes ($p=0.57$). Dans le groupe suspect de toxoplasmose, la mesure de l'Ac IgG anti Hsp70.1 a permis de confirmer biologiquement 10 patients sur 18 présentant une TO clinique.

En conclusion, l'Ac IgG Anti Hsp 70.1 peut être utilisé, en complément des autres méthodes biologiques, pour confirmer l'étiologie toxoplasmique d'une chorioretinite. Une étude complémentaire de son dosage dans l'humeur aqueuse devrait permettre de mieux appréhender la relation entre l'Ac IgG Anti Hsp 70.1 et le diagnostic, ainsi que la sévérité de la toxoplasmose oculaire

VU ET PERMIS D'IMPRIMER

Grenoble, le 10/10/2013

LE DOYEN

M. le Professeur J.P. ROMANET

LE PRESIDENT DE LA THESE

M. Le Professeur J.P. ROMANET



