



HAL
open science

Early brain MRI interest in infective endocarditis clinical management: a prospective study

Julia Champey

► **To cite this version:**

Julia Champey. Early brain MRI interest in infective endocarditis clinical management: a prospective study. Human health and pathology. 2015. dumas-01154337

HAL Id: dumas-01154337

<https://dumas.ccsd.cnrs.fr/dumas-01154337>

Submitted on 21 May 2015

HAL is a multi-disciplinary open access archive for the deposit and dissemination of scientific research documents, whether they are published or not. The documents may come from teaching and research institutions in France or abroad, or from public or private research centers.

L'archive ouverte pluridisciplinaire **HAL**, est destinée au dépôt et à la diffusion de documents scientifiques de niveau recherche, publiés ou non, émanant des établissements d'enseignement et de recherche français ou étrangers, des laboratoires publics ou privés.

AVERTISSEMENT

Ce document est le fruit d'un long travail approuvé par le jury de soutenance et mis à disposition de l'ensemble de la communauté universitaire élargie.

Il n'a pas été réévalué depuis la date de soutenance.

Il est soumis à la propriété intellectuelle de l'auteur. Ceci implique une obligation de citation et de référencement lors de l'utilisation de ce document.

D'autre part, toute contrefaçon, plagiat, reproduction illicite encourt une poursuite pénale.

Contact au SICD1 de Grenoble : **thesebum@ujf-grenoble.fr**

LIENS

Code de la Propriété Intellectuelle. articles L 122. 4

Code de la Propriété Intellectuelle. articles L 335.2- L 335.10

<http://www.cfcopies.com/juridique/droit-auteur>

<http://www.culture.gouv.fr/culture/infos-pratiques/droits/protection.htm>

Année : 2014/2015

UNIVERSITE JOSEPH FOURIER
FACULTE DE MEDECINE DE GRENOBLE

THESE PRESENTEE POUR L'OBTENTION DU DOCTORAT EN MEDECINE

DIPLOME D'ETAT

Early brain MRI interest in infective endocarditis clinical management:

A prospective study

Julia, Hélène, CHAMPEY
née le 07 mars 1985 à Toulon

Thèse soutenue publiquement à la Faculté de Grenoble* le 30 avril 2015

devant le jury composé de :

Monsieur le Professeur Jean-François Payen, président du jury

Madame le Professeur Carole Schwebel


Monsieur le Professeur Patrice François

Monsieur le Docteur Gilles Francony

Madame le Docteur Hélène Bouvaist

Madame le Docteur Patricia Pavese, directrice de thèse

* La faculté de Médecine de Grenoble n'entend donner aucune approbation ni improbation aux opinions émises dans les thèses ; ces opinions sont considérées comme propres à leur auteurs.



SERMENT D'HIPPOCRATE

En présence des Maîtres de cette Faculté, de mes chers condisciples et devant l'effigie d'HIPPOCRATE,

Je promets et je jure d'être fidèle aux lois de l'honneur et de la probité dans l'exercice de la Médecine.

Je donnerais mes soins gratuitement à l'indigent et n'exigerai jamais un salaire au-dessus de mon travail. Je ne participerai à aucun partage clandestin d'honoraires.

Admis dans l'intimité des maisons, mes yeux n'y verront pas ce qui s'y passe ; ma langue taira les secrets qui me seront confiés et mon état ne servira pas à corrompre les mœurs, ni à favoriser le crime.

Je ne permettrai pas que des considérations de religion, de nation, de race, de parti ou de classe sociale viennent s'interposer entre mon devoir et mon patient.

Je garderai le respect absolu de la vie humaine.

Même sous la menace, je n'admettrai pas de faire usage de mes connaissances médicales contre les lois de l'humanité.

Respectueux et reconnaissant envers mes Maîtres, je rendrai à leurs enfants l'instruction que j'ai reçue de leurs pères.

Que les hommes m'accordent leur estime si je suis fidèle à mes promesses.

Que je sois couvert d'opprobre et méprisé de mes confrères si j'y manque.

**LISTE DES PROFESSEURS DES UNIVERSITES ET
MAITRES DE CONFERENCE DES UNIVERSITES –
PRATICIENS HOSPITALIERS**

ANNEE 2014-2015

Université Joseph Fourier

Faculté de Médecine

Domaine de la Merci

38700 La Tronche

Doyen de la Faculté de Médecine :
Monsieur le Professeur Jean-Paul ROMANET

CORPS	NOM-PRENOM	Discipline universitaire
PU-PH	ALBALADEJO Pierre	Anesthésiologie réanimation
PU-PH	APTTEL Florent	Ophthalmologie
PU-PH	ARVIEUX-BARTHELEMY Catherine	chirurgie générale
PU-PH	BALOSSO Jacques	Radiothérapie
PU-PH	BARRET Luc	Médecine légale et droit de la santé
PU-PH	BENHAMOU Pierre Yves	Endocrinologie, diabète et maladies métaboliques
PU-PH	BERGER François	Biologie cellulaire
PU-PH	BETTEGA Georges	Chirurgie maxillo-faciale, stomatologie
MCU-PH	BIDART-COUTTON Marie	Biologie cellulaire
MCU-PH	BOISSET Sandrine	Agents infectieux
PU-PH	BONAZ Bruno	Gastro-entérologie, hépatologie, addictologie
MCU-PH	BONNETERRE Vincent	Médecine et santé au travail
PU-PH	BOSSON Jean-Luc	Biostatistiques, informatique médicale et technologies de communication
MCU-PH	BOTTARI Serge	Biologie cellulaire
PU-PH	BOUGEROL Thierry	Psychiatrie d'adultes
PU-PH	BOUILLET Laurence	Médecine interne
MCU-PH	BOUZAT Pierre	Réanimation
PU-PH	BRAMBILLA Christian	Pneumologie
PU-PH	BRAMBILLA Elisabeth	Anatomie et cytologie pathologiques
MCU-PH	BRENIER-PINCHART Marie Pierre	Parasitologie et mycologie
PU-PH	BRICAULT Ivan	Radiologie et imagerie médicale
PU-PH	BRICHON Pierre-Yves	Chirurgie thoracique et cardio-vasculaire
MCU-PH	BRIOT Raphaël	Thérapeutique, médecine d'urgence
PU-PH	CAHN Jean-Yves	Hématologie
MCU-PH	CALLANAN-WILSON Mary	Hématologie, transfusion
PU-PH	CARPENTIER Françoise	Thérapeutique, médecine d'urgence
PU-PH	CARPENTIER Patrick	Chirurgie vasculaire, médecine vasculaire
PU-PH	CESBRON Jean-Yves	Immunologie
PU-PH	CHABARDES Stephan	Neurochirurgie

PU-PH	CHABRE Olivier	Endocrinologie, diabète et maladies métaboliques
PU-PH	CHAFFANJON Philippe	Anatomie
PU-PH	CHAVANON Olivier	Chirurgie thoracique et cardio- vasculaire
PU-PH	CHIQUET Christophe	Ophthalmologie
PU-PH	CINQUIN Philippe	Biostatistiques, informatique médicale et technologies de communication
PU-PH	COHEN Olivier	Biostatistiques, informatique médicale et technologies de communication
PU-PH	COUTURIER Pascal	Gériatrie et biologie du vieillissement
PU-PH	CRACOWSKI Jean-Luc	Pharmacologie fondamentale, pharmacologie clinique
PU-PH	DE GAUDEMARIS Régis	Médecine et santé au travail
PU-PH	DEBILLON Thierry	Pédiatrie
MCU-PH	DECAENS Thomas	Gastro-entérologie, Hépatologie
PU-PH	DEMATTEIS Maurice	Addictologie
PU-PH	DEMONGEOT Jacques	Biostatistiques, informatique médicale et technologies de communication
MCU-PH	DERANSART Colin	Physiologie
PU-PH	DESCOTES Jean-Luc	Urologie
MCU-PH	DETANTE Olivier	Neurologie
MCU-PH	DIETERICH Klaus	Génétique et procréation
MCU-PH	DOUTRELEAU Stéphane	Physiologie
MCU-PH	DUMESTRE-PERARD Chantal	Immunologie
PU-PH	EPAULARD Olivier	Maladies Infectieuses et Tropicales
PU-PH	ESTEVE François	Biophysique et médecine nucléaire
MCU-PH	EYSSERIC Hélène	Médecine légale et droit de la santé
PU-PH	FAGRET Daniel	Biophysique et médecine nucléaire
PU-PH	FAUCHERON Jean-Luc	chirurgie générale
MCU-PH	FAURE Julien	Biochimie et biologie moléculaire
PU-PH	FERRETTI Gilbert	Radiologie et imagerie médicale
PU-PH	FEUERSTEIN Claude	Physiologie
PU-PH	FONTAINE Éric	Nutrition
PU-PH	FRANCOIS Patrice	Epidémiologie, économie de la santé et prévention
PU-PH	GARBAN Frédéric	Hématologie, transfusion
PU-PH	GAUDIN Philippe	Rhumatologie
PU-PH	GAVAZZI Gaétan	Gériatrie et biologie du vieillissement
PU-PH	GAY Emmanuel	Neurochirurgie
MCU-PH	GILLOIS Pierre	Biostatistiques, informatique médicale et technologies de communication
PU-PH	GODFRAIND Catherine	Anatomie et cytologie pathologiques (type clinique)
MCU-PH	GRAND Sylvie	Radiologie et imagerie médicale
PU-PH	GRIFFET Jacques	Chirurgie infantile
MCU-PH	GUZUN Rita	Endocrinologie, diabétologie, nutrition, éducation thérapeutique
PU-PH	HALIMI Serge	Nutrition
PU-PH	HENNEBICQ Sylviane	Génétique et procréation

PU-PH	HOFFMANN Pascale	Gynécologie obstétrique
PU-PH	HOMMEL Marc	Neurologie
PU-PH	JOUK Pierre-Simon	Génétique
PU-PH	JUVIN Robert	Rhumatologie
PU-PH	KAHANE Philippe	Physiologie
PU-PH	KRACK Paul	Neurologie
PU-PH	KRAINIK Alexandre	Radiologie et imagerie médicale
PU-PH	LABARERE José	Epidémiologie ; Eco. de la Santé
PU-PH	LANTUEJOL Sylvie	Anatomie et cytologie pathologiques
MCU-PH	LAPORTE François	Biochimie et biologie moléculaire
MCU-PH	LARDY Bernard	Biochimie et biologie moléculaire
MCU-PH	LARRAT Sylvie	Bactériologie, virologie
MCU-PH	LAUNOIS-ROLLINAT Sandrine	Physiologie
PU-PH	LECCIA Marie-Thérèse	Dermato-vénérologie
PU-PH	LEROUX Dominique	Génétique
PU-PH	LEROY Vincent	Gastro-entérologie, hépatologie, addictologie
PU-PH	LETOUBLON Christian	chirurgie générale
PU-PH	LEVY Patrick	Physiologie
MCU-PH	LONG Jean-Alexandre	Urologie
PU-PH	MACHECOURT Jacques	Cardiologie
PU-PH	MAGNE Jean-Luc	Chirurgie vasculaire
MCU-PH	MAIGNAN Maxime	Thérapeutique, médecine d'urgence
PU-PH	MAITRE Anne	Médecine et santé au travail
MCU-PH	MALLARET Marie-Reine	Epidémiologie, économie de la santé et prévention
MCU-PH	MARLU Raphaël	Hématologie, transfusion
MCU-PH	MAUBON Danièle	Parasitologie et mycologie
PU-PH	MAURIN Max	Bactériologie - virologie
MCU-PH	MCLEER Anne	Cytologie et histologie
PU-PH	MERLOZ Philippe	Chirurgie orthopédique et traumatologie
PU-PH	MORAND Patrice	Bactériologie - virologie
PU-PH	MOREAU-GAUDRY Alexandre	Biostatistiques, informatique médicale et technologies de communication
PU-PH	MORO Elena	Neurologie
PU-PH	MORO-SIBILOT Denis	Pneumologie
MCU-PH	MOUCHET Patrick	Physiologie
PU-PH	MOUSSEAU Mireille	Cancérologie
PU-PH	MOUTET François	Chirurgie plastique, reconstructrice et esthétique, brûlogie
MCU-PH	PACLET Marie-Hélène	Biochimie et biologie moléculaire
PU-PH	PALOMBI Olivier	Anatomie
PU-PH	PARK Sophie	Hémato - transfusion
PU-PH	PASSAGGIA Jean-Guy	Anatomie
PU-PH	PAYEN DE LA GARANDERIE Jean-François	Anesthésiologie réanimation
MCU-PH	PAYSANT François	Médecine légale et droit de la santé

à jour le 14 novembre 2014

MCU-PH	PELLETIER Laurent	Biologie cellulaire
PU-PH	PELLOUX Hervé	Parasitologie et mycologie
PU-PH	PEPIN Jean-Louis	Physiologie
PU-PH	PERENNOU Dominique	Médecine physique et de réadaptation
PU-PH	PERNOD Gilles	Médecine vasculaire
PU-PH	PIOLAT Christian	Chirurgie infantile
PU-PH	PISON Christophe	Pneumologie
PU-PH	PLANTAZ Dominique	Pédiatrie
PU-PH	POLACK Benoît	Hématologie
PU-PH	POLOSAN Mircea	Psychiatrie d'adultes
PU-PH	PONS Jean-Claude	Gynécologie obstétrique
PU-PH	RAMBEAUD Jacques	Urologie
MCU-PH	RAY Pierre	Génétique
PU-PH	REYT Émile	Oto-rhino-laryngologie
MCU-PH	RIALLE Vincent	Biostatistiques, informatique médicale et technologies de communication
PU-PH	RIGHINI Christian	Oto-rhino-laryngologie
PU-PH	ROMANET J. Paul	Ophthalmologie
MCU-PH	ROUSTIT Matthieu	Pharmacologie fondamentale, pharmacologie clinique, addictologie
MCU-PH	ROUX-BUISSON Nathalie	Biochimie, toxicologie et pharmacologie
PU-PH	SARAGAGLIA Dominique	Chirurgie orthopédique et traumatologie
MCU-PH	SATRE Véronique	Génétique
PU-PH	SAUDOU Frédéric	Biologie Cellulaire
PU-PH	SCHMERBER Sébastien	Oto-rhino-laryngologie
PU-PH	SCHWEBEL-CANALI Carole	Réanimation médicale
PU-PH	SCOLAN Virginie	Médecine légale et droit de la santé
MCU-PH	SEIGNEURIN Arnaud	Epidémiologie, économie de la santé et prévention
PU-PH	STAHL Jean-Paul	Maladies infectieuses, maladies tropicales
PU-PH	STANKE Françoise	Pharmacologie fondamentale
MCU-PH	STASIA Marie-José	Biochimie et biologie moléculaire
PU-PH	TAMISIER Renaud	Physiologie
PU-PH	TONETTI Jérôme	Chirurgie orthopédique et traumatologie
PU-PH	TOUSSAINT Bertrand	Biochimie et biologie moléculaire
PU-PH	VANZETTO Gérald	Cardiologie
PU-PH	VUILLEZ Jean-Philippe	Biophysique et médecine nucléaire
PU-PH	WEIL Georges	Epidémiologie, économie de la santé et prévention
PU-PH	ZAOUI Philippe	Néphrologie
PU-PH	ZARSKI Jean-Pierre	Gastro-entérologie, hépatologie, addictologie

TABLE OF CONTENTS

- ABSTRACT 9
- 1. RATIONAL (context and hypothesis) 13
- 2. PATIENTS AND METHODS 15
 - A. Population
 - B. Data collection
 - C. Magnetic Resonance Imaging (MRI)
 - D. Assessment of MRI utility
 - E. Statistical analysis
- 3. RESULTS 19
 - F. Study population
 - G. IE characteristics
 - H. MRI results
 - I. Assessment of diagnosis and treatment by panels of experts
- 4. DISCUSSION.....**Erreur ! Signet non défini.**
- 5. CONCLUSION 26
- 6. REFERENCES 28
- 7. FIGURES AND TABLES..... 31

Annexes are provided under a separate cover.

Abstract

Introduction

In Infective Endocarditis (IE), brain Magnetic Resonance Imaging (MRI) is helpful to diagnose clinically silent neurologic events, especially micro ischemic and micro haemorrhagic lesions. Brain MRI may be fitted in a complete imaging check-up including, at an early stage, chest abdomen, pelvis Computered Tomography (CT) and echocardiography for a thoroughly asymptomatic lesions mapping.

Objective

We aimed to assess the usefulness of systematic early brain MRI in IE diagnosis and medico-surgical cares management.

Methods

During one year, all patients admitted in one of the 3 hospitals participating and fulfilling Duke's criteria for definite or possible IE, underwent cerebral MRI with angiography within the 7 days of IE-suspicion.

To assess the MRI contribution, records were analyzed a posteriori by 8 panels of experts. For each case, one record with and one record without the MRI results, were randomly assigned to 2 panels who determined theoretical diagnosis and treatment. Inter-rater concordances were assessed through Cohen Kappa test.

Results

Thirty-seven brain MRI were realized in a median time of 5 days after inclusion. MRI was pathological in 26 patients (70%) showing 62 % of micro ischemia and 58% of microbleeds.

Experts advices were significantly concordant between the 2 evaluations with or without the MRI results. Diagnosis differed in 2 cases (5.4%) with an upgrading of diagnosis from possible to definite IE using MRI results. Discrepancies concerning therapeutic attitudes occurred in 8 cases (21.5 %) including one change in the indication to operate, 3 modifications of timing of surgery namely 2 earlier and one postponed surgery with the MRI results and 1 disagreement over the choice of prosthesis. Changes concerned anticoagulation in 2 cases. Rifampicin was added to the antimicrobial therapy in 1 case.

Conclusion

Because it does not seem to plenty affect diagnosis and medico-surgical cares; our results do not support the need for a systematic use of early brain MRI in IE. Further studies are necessary to clearly define if MRI is mandatory in IE management within a multidisciplinary approach; the better timing to realize it and the subset of patients in which it could be beneficial.

Keywords

Infective endocarditis, brain magnetic resonance imaging, brain micro ischemia, cerebral microbleeds, cardiac surgery procedures.

Résumé

Introduction

L'Imagerie encéphalique par Résonance Magnétique (IRM) est utile pour le diagnostic des lésions neurologiques silencieuses, particulièrement pour la mise en évidence des micro-ischémies et microhémorragies dans l'Endocardite Infectieuse (EI). Associée au scanner thoraco-abdomino-pelvien et à l'échocardiographie, l'IRM permet de dresser une cartographie précoce et exhaustive des lésions emboliques septiques.

Objectifs

Cette étude avait pour objectif d'évaluer la place de l'IRM cérébrale dans le diagnostic et la prise en charge médico-chirurgicale de l'EI.

Méthode

Tous les patients hospitalisés pendant un an dans un des 3 hôpitaux participants, pour une EI certaine ou probable, étaient éligibles pour l'étude. Il était proposé de réaliser une IRM encéphalique avec angiographie avant le 7^{ème} jour d'évolution.

Pour évaluer l'apport de l'IRM, les dossiers ont été analysés, a posteriori, par 8 panels d'experts. Pour chaque patient, un dossier avec IRM et un dossier sans IRM étaient assignés au hasard à 2 panels qui statuaient sur le diagnostic et proposaient un traitement. La concordance des avis sur un même cas était évaluée à l'aide du test Kappa de Cohen.

Résultats

Trente-sept patients ont bénéficié d'une angio-IRM cérébrale dans un délai médian de 5 jours. Vingt-six IRM étaient pathologiques (70%) montrant 62% de micro-ischémies et 58% de microbleeds.

Les avis des experts étaient significativement concordants entre les deux évaluations avec ou sans IRM. Le diagnostic d'EI différait dans 2 cas (5.4%) passant de probable sans IRM à certain avec IRM. Des discordances concernant les traitements ont été notées dans 8 cas (21.5 %). Dans l'évaluation avec IRM : une indication de chirurgie valvulaire n'était pas retenue ; le délai opératoire était raccourci dans 2 cas et retardé dans un cas ; un choix différent de prothèse a été fait ; Deux choix différents d'anticoagulation ont été fait. la rifampicine était ajoutée à l'antibiothérapie dans 1 cas.

Conclusion

L'utilisation précoce de l'IRM encéphalique ne semble pas influencer de façon majeure le diagnostic ou le traitement médico-chirurgical des EI. D'autres études sont nécessaires pour clairement définir l'intérêt de l'IRM cérébrale dans la prise en charge des endocardites au sein d'une concertation multidisciplinaire, le délai de réalisation le plus approprié et les patients pour lesquels cet examen serait plus particulièrement utile.

Mots-clés

Endocardite infectieuse, imagerie encéphalique par résonance magnétique, micro-ischémies cérébrales, microbleeds cérébraux, chirurgie cardiaque.

1. RATIONAL (context and hypothesis)

Infective Endocarditis (IE) is a serious disease carrying a considerable risk of morbi-mortality (1–5). Despite improvements in therapy, mortality remains high from 15 to 22 % (5). Mortality rates vary among subgroups of patients reaching 40 % for *Staphylococcus aureus* prosthetic valve IE patients and 50% in Intensive Care Unit (ICU) (1).

With regards to extra-cardiac complications, cerebral lesions are frequent with an incidence rate ranging from 10 to 65 % (5,6). Recent data suggest that neurological failure is a major determinant for short-term prognosis (2). Neurologic damages are numerous and various (7,8). The IE neuroimaging findings can be classified as follows: ischemic stroke, intra parenchyma macro and micro-haemorrhages, subarachnoid haemorrhage, mycotic aneurysm, brain abscess and meningitis (5). Because a part of them are clinically silent (9,10), some medical teams suggest to perform neuroimaging for all IE patients, even those without clinical neurologic symptoms (11–14). Additionally, since embolic risk and neurologic worsening remain high during the first week of anti-microbial therapy (15,16), neuroimaging diagnosis need to be performed early in care management (17,18).

First, we performed a systematic review of the literature regarding the overall brain MRI interest in acute IE. [Annex 1, to be published]. Because Brain Magnetic Resonance Imaging (MRI) is more sensitive and less toxic than Computered Tomography (CT) scan, this exam appears to have more value to detect cerebral micro lesions. Diffusion-weighted echo planar imaging (DWI) and T2*-weighted Gradient Recalled Echo (GRE) sequences are especially used in this field (17,19).

Secondly, in order to clarify the prevalence and the type of cerebral MRI lesions in IE (including cerebral micro-haemorrhages, also call Cerebral Microbleeds (CMBs)) and to compare them with CT scan lesions, we achieved a retrospective observational study, from 2010 to 2012, in the Grenoble University hospital [Annex 2, in revision]. In the 62 IE patients of this series, CT-scan was abnormal in 26 (49%) patients whereas MRI demonstrated lesions in 32 (74%) cases. Regarding asymptomatic patients, 37 of 43 (74 %) had MRI lesions while 12 of 53 (46%) had CT-scan lesions. MRI shown more ischemia lesions (48% vs. 35%) and micro bleeds (34% vs. 0%) than CT-scan. This preliminary study was concordant with literature data (9,11,12,20).

Allowing an early and precise neurological status, MRI may influence therapeutic plans (14) and lead to faster surgical decision (7,11).

Actually, if urgent surgery is well agreed for patients with poor hemodynamic tolerance, embolic events remain a controversial indication for surgery (21,22). Risk factors of embolic events are well known: *Staphylococcus aureus* infection (23) more so in a mitral location, large (> 10 mm) and highly mobile vegetation, other systemic embolisms (13–15). The change in the vegetation size with antibiotics is also relevant (23).

For those patients, several studies have shown that in order to prevent recurrent embolic events and to decrease mortality (24,25), surgery has to be performed without delay (13,20,26).

If cerebral bleeding or major ischemia is a temporary surgical contra-indication, cardiac surgery can be safely performed after silent cerebrovascular complications (16,27,28).

In this way, brain MRI fitted in a complete imaging check-up could lead clinicians to change the surgical strategy with regards to cardiac surgery indication and timing of valve replacement (14).

The additional information provided by cerebral MRI may also impact diagnosis classification (14). If small ischemic lesions, as peripheral manifestations of IE, obviously upgrade the Duke's classification, the role of CMBs is still unclear. This small foci of haemorrhage, only visible by using T2*- weighted GRE MRI sequences, have a strong IE association (9) with a specific distribution in cortical areas (9,19). The value of this phenomenon as a pyogenic vasculitis (7) may testify the infection severity (19). As an IE feature, CMBs could also be considered like a new imaging minor criterion (19).

Overall, few studies analyzed the interest of brain MRI in the management of IE. The effect on clinical decision-making and the influence of micro ischemia and CMBs on diagnosis have not been fully evaluated. Prospective data are limited. IE guidelines are still mainly based on experts opinions (5). [Annex 1]

The present study aims to evaluate the impact of systematic early brain MRI in IE management: diagnosis of IE according to Duke's modified classification [Annex 3] and treatment (surgical indication, time of surgery, anticoagulation management and antimicrobial choice).

2. PATIENTS AND METHODS

A. Study design

Between November 2013 and November 2014, an observational prospective multicentric study was conducted at the Grenoble University Hospital and at the Annecy and Chambéry General Hospitals, France. IE patients underwent brain angio-MRI within the 7 days of diagnosis.

In a second step, records, with or without the MRI results, were randomly assigned to panels of experts who theoretically chose diagnosis and treatments.

The protocol was approved by the local ethic committee.

B. Population

A consecutive series of patients hospitalized with IE was prospectively achieved during one year. Only adult patients (≥ 18 years) with definite or possible IE according to the modified international Duke's criteria, and presenting at least a major criterion (evidence of endocardial involvement, repeated positive blood cultures) were enrolled in the study. After the diagnosis confirmation by an expert (infectious disease specialist or cardiologist), brain MRI was quickly performed.

The patients were screened thanks to daily blood cultures in collaboration with the bacteriology department and through contacts with physicians in the more concerned departments (cardiology, infectious disease, intensive care, cardiac surgery).

Patients were excluded if they had undergone cardiac surgery in emergency (during the first 24 hours after diagnosis), if they had a MRI absolute contraindication [Annex 5], if they presented an IE on an implantable device incompatible with a MRI achievement, or if IE initial cares were done in another hospital where more than a week of adapted antibiotic treatment was received.

Written informed consent was obtained from all patients [Annex 7].

C. Data collection

Demographic, clinical, biological and imaging data [Annex 3] were collected on a standardized form, at the inclusion and during the hospitalization. Chest abdomen pelvis and brain CT, transthoracic and/or transoesophageal echocardiographies were performed as clinically indicated as soon as possible. After discharge, a follow-up care was organized with an infectious disease specialist by a consultation at 3 months. In cases of missing data, the information was collected by calling the patient's general practitioner.

D. MRI

Cerebral MRI with angiography was performed **before the seventh day after diagnosis**.

The following type sequences were included in a standardized neuroimaging protocol:

Axial diffusion, axial FLAIR, axial T2 Gradient Echo Recalled, axial or sagittal T1, axial or sagittal T1 3D with gadolinium injection, intracranial Angiography MRI in time of fly and with gadolinium.

An experienced neuroradiologist reviewed all MRI images.

E. Assessment of MRI utility

Eight multidisciplinary panels of experts (Infectious Diseases Specialist, Cardiologist and Intensivist) met, a posteriori, and worked independently from each other. The panels were blinded for real care. The patient data, with or without the MRI results were randomly assigned to one panel of experts. Experts reviewed the whole patient's medical history, biological and imaging results. Completing a standardized questionnaire, panels established the diagnosis and the best medico-surgical treatment for each case [Annex 4]. Treatment was supposed to be determined on the basis of available guidelines (22).

F. Statistical analysis:

Continuous variables were presented as median and interquartile ranges (IQR). Categorical variables were presented as numbers and percentages.

Cohen's kappa coefficient was used to quantify the concordance between expert advices on diagnosis and therapeutic strategies, with and without MRI results, for each cases.

The level of 0.05 was used for statistical significance. Statistical analyses were performed with *Stata 11* software.

3. RESULTS

A. Study population

During the inclusion period, 247 patients with a possible or definite IE were recorded on the hospital database of the Grenoble University Hospital (155), the general hospital of Annecy (54) and Chambéry (38) and 45 patients were eligible for the study. Among them, 37 underwent brain angio-MRI examination within the 7 days of management. The median duration from diagnosis to MRI was 5 days (IQR 3-7) ([figure 1](#)).

Patients' baseline characteristics are detailed in [table 1](#). The median age was 71 years (IQR 66-81). Twenty-six cases (70%) of IE developed on native valves. 11 patients (30%) had prosthetic material IE. The median Charlson comorbidity score (29) was 5 (IQR 3-6) and the forecast surgical risk (median Euroscore I) (30) was 14 (IQR 11-17).

Clinical characteristics are listed in [table 2](#). Twenty-six patients (70%) had a definite IE according to Duke's criteria. Neurologic symptoms were present in eleven patients (30%): 5 deliriums (14%), 4 focal deficits (11%) 3 impaired consciousnesses (8%) with Coma Glasgow Scale under 14 and 2 meningeal syndromes (5%). IE was health-care associated in 10 cases (29%). *Staphylococcus aureus* was the most common microorganism, identified in 12 cases (32%). Echocardiography showed 30 vegetations (81%) with a 10 mm median length (IQR 5-14). Mitral and aortic valves were involved in respectively 11 (41%) and 13 (48%) cases. Three right-IE happened (8%). Five patients (17%) had severe regurgitation. Five trigon abscesses (15%) and 1 acute valve obstruction (3.5%) were diagnosed.

Ten patients (27 %) underwent cardiac surgery with a median delay of 8 days (IQR 6-59) from diagnosis to surgery ([table 3](#)). Nine patients (24%) required implantable device removal.

Six patients (16%) died within the 3 months follow-up. One patient died after cardiac surgery on the grounds of a multi-organ failure. Seven patients (23%) suffered from neurologic complications within the 3 months follow-up but only one died from this complication per se.

B. Neuroimaging findings

Neuroimaging data are summarized in [table 4](#). IE-related lesions were highlighted in 26 patients (70%). MRI showed acute ischemia for 16 patients (62%). All but one were punctiform lesions. MRI detected CMBs in 15 cases (58%). Four patients (9%) had hemorrhagic lesions; 1 (4%) had a microbial aneurysms and 1 (4%) had a brain abscess. Among the 26 patients without neurological symptoms, silencious MRI lesions were detected in 8 (31%) cases.

C. Assessment of diagnosis and treatment by panels of experts

After analysis of expert's reports, IE management was finally changed in 10 patients (27%) including diagnosis amendment for 2 patients (5.4%) and therapeutic change in 8 patients (21.5%).

The IE diagnosis, according to Duke's criteria, was upgraded in 2 cases (5.4%) from possible to define. Agreement for diagnosis evaluation was high between panels (κ coefficient 0.89 (95% CI, 0.74 to 1)) ([Table 5](#))

Variations in surgical strategies concerned 1 indication, 3 variations in timing of surgery out of 12 theoretical surgical patients (25%) i.e. one postponed and 2 earlier surgery with the MRI results, and the choice of 1 type of prosthesis. Medical treatment differed in 3 cases (8%):

anticoagulant therapy in 2 cases (5.4%) and antimicrobial therapy in 1 case (use of rifampicin). Inter-expertise concordance of panels was high concerning indication of surgery (κ coefficient of 0.94 (95% CI, 0.82 to 1), choice of kind of prosthesis (κ coefficient of 0.93 (95% CI, 0.81 to 1)), anticoagulation and antibiotic management (respectively κ coefficient of 0.89 (95% CI, 0.74 to 1) and of 0.98 (95% CI, 0.86 to 1)) ([Table 6](#)). Inter-expertise concordance was moderate for surgery delay (κ coefficient of 0.53 (95% CI, 0.17 to 0.84)) ([Table 7](#)).

Hence, IE management was not statistically influenced by MRI results.

4. DISCUSSION

Decisions of the experts differ in 27 % of patients in the light of MRI results but concordance between experts advices were high according to Cohen Kappa test results. Thus, there is no statistical argument proving that brain MRI could be associated with a major change on IE clinical decision-making.

In the literature, this approach had already yielded opposite advices. A recent French trial conducted on 130 IE patients demonstrated that the MRI findings before the seventh day of evolution changed diagnosis and therapeutic plans in 28% of patients including medical and surgical plan modifications in 18 % of cases (11). Accurately, excluding CMBs and solely basis on MRI results, Duval et al, achieved 14% of surgical plan adjustments. In this study, the methodology differed since a pair of 2 experts established IE diagnosis and therapeutic strategy 24 hours before and 24 hours after MRI achievement and the decision were compared. Experts may have overestimated the MRI usefulness by a confirmation bias. In the present study panels were blinded for the opinion of other groups and results are probably more reliable.

Some other elements could provide explanations for these results.

First, because of the major risk of neurologic worsening due to extracorporeal circulation, per operative hypotension and anticoagulant use (7,11), appropriate timing of surgery remains controversial; it is team-dependent. The earlier surgery policy in our referral center could explain the minor role of MRI in this study.

Moreover, new European guidelines incite to prevent recurrent embolisms and support the routine use of an early valve replacement (22). The early removal of vegetation is, beyond obvious contra-indications, the best way to impede neurologic injury.

Surgery is overall fostered before the end of the first week of antimicrobial treatment in cases of isolated large vegetation (15 mm) or in presence of a 10 mm vegetation following one or more clinical or even asymptomatic embolic events (15).

In the last thirty years, surgeon's behavior changed and they operate earlier with less fear of relapse, complications and postoperative neurological worsening. Nonetheless, optimal therapeutic strategy may vary for individual patient and precocious surgical decision remains difficult as proved by the low inter-observer concordance rate concerning the timing of surgery in our study.

A multidisciplinary team should discuss the benefit-risk ratio and the period of surgery in litigious cases, with regards to the risk of fatal embolic recurrence and the risk of major cardiac surgery (31). The root role of comorbidities has assuredly to be considered. Thus, a randomized study comparing conventional treatment and early valve replacement revealed that, for patients with large vegetation, early surgery decreases the composite end point of death and embolic events though declining embolism. In this trial, patients were young with a low operative risk. MRI should maybe be more beneficial for this sub-group of patients (24).

Otherwise, as silent neurologic lesions do not represent a major risk of bleeding, no great difference were observed on anticoagulation and type of surgery (12). The prominence of bio prosthesis in our ageing population is causing a less use of anticoagulants in the immediate postoperative period (32).

The low rate of cerebral abscess in our sample, which could lead to the addition of a high cerebral diffusion antimicrobial agent, may also explain why we did emphasized the interest of MRI for an IE antibiotic adjustment.

The discovery of silent lesions might also impact diagnosis classification. As Duke's criteria have some limitations in clinical practice (15), IE diagnose is not always easy and is frequently delayed inducing progress of systemic damages. The diagnosis is even more difficult as echocardiography can be negative in around 5 to 10 % of cases, mostly for intra-cardiac device IE, prosthetic valve IE or pre-existent valvular severe lesions (20). Rarely, negative blood cultures are also still a diagnosis challenge. Identification of cerebral micro lesions (micro infarctions, micro abscesses and CMBs) as minor criteria in the Duke classification may allow upgrading the diagnosis. In the prospective study IMAGE, solely based on MRI results and excluding CMBs, they upgraded the IE classification in 32 % of cases to non- defined to either defined or possible IE (14). Including CMBs, the authors upgraded the diagnoses in 51% of patients with initially non-defined endocarditis (11). In our study, taking CMBs into account, the diagnosis changes prompted by MRI were modest as demonstrated by the high inter-observer concordance.

However, using highly sensitive cerebral imaging, CMBs detection should become an additional diagnosis marker forasmuch as these non-pathognomonic IE lesions have a specific endocarditis pattern (19,27,33). This small vessel vasculitis marker witnesses for tissue damages (34,35). In the same way as Positron Emission Tomography Scan using, CMBs may

represent the IE activity (20). Future approaches for elucidating the role of these common lesions are necessary. More generally, no sufficient data are available to set up CMBs clinical implication. [Annex 1]

Lastly, demographic and clinical characteristics of our population are consistent with the IE featuring in industrialized country (3,36). Nowadays IE occurred mainly in elderly patients with significant co-morbid medical illness like hemodialysis and diabetes (15,37). As a result of increasing cardiac surgery indications and invasive intravascular procedures the proportion of health-care associated IE (nosocomial or not) is rising. The present series shows a substantial proportion of prosthetic valve and pace-maker IE. The IE mortality around 20% is still high as historically described (5,36) as are the 27 % surgical rate (16,36) and the 16 % systemic embolic events rate (15). Our bacteriological data support recent epidemiological changes: the increasing frequency of nosocomial IE is correlated to the growth of *Staphylococcus aureus*, *Staphylococcus epidermidis* and enterococci (36). Given *Staphylococcus aureus* propensity to affect the brain (2), our cerebral lesion rate is relatively low.

Thirty per cent of patients had neurologic symptom as in recent studies (38). Using brain MRI in 37 patients at an early stage of IE, the present study shows 70 % of brain lesions like in previous research (12,14,16,19). On the contrary, the 32% rate of silencing brain damages was not so high. Hess et al, in a 109 patients study found 71% of occult cerebral lesions including CMBs (19). As expected according to the pathogenesis of IE stroke, MRI infarction were mainly small lesions disseminated in watershed territories (junctional cortical and sub-cortical arterial territories) (19).

Study limitations:

The small sample size is the first weakness of this study. A lack of statistical power is possible and our results should be interpreted with caution.

Secondly, the subjective featuring of group expertise, especially in link with some leadership skills, can originate some variations in expert's decisions.

Thirdly, the single institution expertise may be not representative of all current cardiac surgery and antimicrobial IE management.

Some other advantages of brain MRI use in endocarditis must be taken to account: non-irradiation and, above all, non-iodine injection have to be considered in these frail patients who often have a renal failure.

With practical experience, this sensitive exam can be done even in critically unstable patients.

Obviously, clinicians are always limited by the availability of early MRI and cost-effectiveness studies have to be done in this field.

To date, the usefulness of brain MRI remains unclear and this one should not be systematically included in an infective endocarditis algorithm management

5. CONCLUSION

Thèse soutenue par: Julia, Hélène CHAMPEY

Titre: « Early brain MRI interest in infective endocarditis clinical management:

A prospective study »

As confirmed by our 70 % rate of IE brain lesions discovered through MRI, endocarditis broader affected the brain.

Recent reports suggest that brain MRI may lead to diagnose advances in this elusive systemic disease, still severe and misdiagnosed. MRI could contribute to a more accurate risk-benefit estimation of the therapeutic approach as well.


The present study, conducted on a prospective cohort of 37 patients benefiting from early brain MRI within 7 days of IE-suspicion, compared two theoretical strategies, one with and one without the MRI results, and provided no convincing evidence for a major effect of cerebral MRI in endocarditis management. With expertises, IE clinical decision was finally changed in 10 patients (27 %) including diagnosis changed in 2 patients (5.4 %) and therapeutic changed in 8 patients (21.5 %). This contrasts with the excellent inter-group concordances calculated with Kappa over than 0.9 for all the variables expected for the period of surgery in which the Kappa was lower at 0.5.

Early brain MRI examination appears to have a subordinate role in the clinical IE decision-making. Yet, when available, it should be preferred to CT scan, for a clearer risk stratification of embolism mainly useful in the early surgical controversial decision. Such exam may be especially indicated in cases of doubt about diagnosis and for young and severe IE patients. Even more, non-iodine injection advantages of MRI imaging should be beneficial for frail patients. In any case, early therapeutic decision in a multidisciplinary approach must be undertaken.

To date, the usefulness of brain MRI remains unclear and this one should not be systematically included in an infective endocarditis algorithm management

Signature du Président du jury:

3/06/18
Professeur Jean-François PAYEN
Pôle Anesthésie-Réanimation
CHU GRENOBLE



Signature du Doyen de la faculté :



6. REFERENCES

1. Sonnevile R, Mourvillier B, Bouadma L, Wolff M. Management of neurological complications of infective endocarditis in ICU patients. *Ann Intensive Care*. 2011;1(1):10.
2. Sonnevile R, Mirabel M, Hajage D, Tubach F, Vignon P, Perez P, et al. Neurologic complications and outcomes of infective endocarditis in critically ill patients: the ENDOcardite en REAnimation prospective multicenter study. *Crit Care Med*. juin 2011;39(6):1474.81.
3. Corral I, Martín-Dávila P, Fortún J, Navas E, Centella T, Moya JL, et al. Trends in neurological complications of endocarditis. *J Neurol*. sept 2007;254(9):1253.9.
4. García-Cabrera E, Fernández-Hidalgo N, Almirante B, Ivanova-Georgieva R, Noureddine M, Plata A, et al. Neurological complications of infective endocarditis: risk factors, outcome, and impact of cardiac surgery: a multicenter observational study. *Circulation*. 11 juin 2013;127(23):2272.84.
5. Hoen B, Duval X. Infective endocarditis. *N Engl J Med*. 22 août 2013;369(8):785.
6. Corr P, Wright M, Handler LC. Endocarditis-related cerebral aneurysms: radiologic changes with treatment. *AJNR Am J Neuroradiol*. avr 1995;16(4):745.8.
7. Goulenok T, Klein I, Mazighi M, Messika-Zeitoun D, Alexandra JF, Mourvillier B, et al. Infective endocarditis with symptomatic cerebral complications: contribution of cerebral magnetic resonance imaging. *Cerebrovasc Dis Basel Switz*. 2013;35(4):327.36.
8. Grabowski M, Hryniewiecki T, Janas J, Stępińska J. Clinically overt and silent cerebral embolism in the course of infective endocarditis. *J Neurol*. juin 2011;258(6):1133.9.
9. Klein I, Iung B, Labreuche J, Hess A, Wolff M, Messika-Zeitoun D, et al. Cerebral microbleeds are frequent in infective endocarditis: a case-control study. *Stroke J Cereb Circ*. nov 2009;40(11):3461.5.
10. Klein I, Iung B, Wolff M, Brochet E, Longuet P, Laissy J-P, et al. Silent T2* cerebral microbleeds: a potential new imaging clue in infective endocarditis. *Neurology*. 5 juin 2007;68(23):2043.
11. Duval X, Iung B, Klein I, Brochet E, Thabut G, Arnoult F, et al. Effect of early cerebral magnetic resonance imaging on clinical decisions in infective endocarditis: a prospective study. *Ann Intern Med*. 20 avr 2010;152(8):497.504, W175.
12. Cooper HA, Thompson EC, Lauren R, Fuisz A, Mark AS, Lin M, et al. Subclinical brain embolization in left-sided infective endocarditis: results from the evaluation by MRI of the brains of patients with left-sided intracardiac solid masses (EMBOLISM) pilot study. *Circulation*. 18 août 2009;120(7):585.91.
13. Thuny F, Avierinos J-F, Tribouilloy C, Giorgi R, Casalta J-P, Milandre L, et al. Impact of cerebrovascular complications on mortality and neurologic outcome during infective endocarditis: a prospective multicentre study. *Eur Heart J*. mai 2007;28(9):1155.61.

14. Iung B, Klein I, Mourvillier B, Olivot J-M, Détaint D, Longuet P, et al. Respective effects of early cerebral and abdominal magnetic resonance imaging on clinical decisions in infective endocarditis. *Eur Heart J Cardiovasc Imaging*. août 2012;13(8):703.10.
15. Habib G. Management of infective endocarditis. *Heart Br Card Soc*. janv 2006;92(1):124.30.
16. Snygg-Martin U, Gustafsson L, Rosengren L, Alsiö A, Ackerholm P, Andersson R, et al. Cerebrovascular complications in patients with left-sided infective endocarditis are common: a prospective study using magnetic resonance imaging and neurochemical brain damage markers. *Clin Infect Dis Off Publ Infect Dis Soc Am*. 1 juill 2008;47(1):23.30.
17. Morofuji Y, Morikawa M, Yohei T, Kitagawa N, Hayashi K, Takeshita T, et al. Significance of the T2*-weighted gradient echo brain imaging in patients with infective endocarditis. *Clin Neurol Neurosurg*. juin 2010;112(5):436.40.
18. Derex L, Bonnefoy E, Delahaye F. Impact of stroke on therapeutic decision making in infective endocarditis. *J Neurol*. mars 2010;257(3):315.21.
19. Hess A, Klein I, Iung B, Lavallée P, Ilic-Habensus E, Dornic Q, et al. Brain MRI findings in neurologically asymptomatic patients with infective endocarditis. *AJNR Am J Neuroradiol*. août 2013;34(8):1579.84.
20. Thuny F, Gaubert J-Y, Jacquier A, Tessonnier L, Cammilleri S, Raoult D, et al. Imaging investigations in infective endocarditis: current approach and perspectives. *Arch Cardiovasc Dis*. janv 2013;106(1):52.62.
21. Barsic B, Dickerman S, Krajinovic V, Pappas P, Altclas J, Carosi G, et al. Influence of the timing of cardiac surgery on the outcome of patients with infective endocarditis and stroke. *Clin Infect Dis Off Publ Infect Dis Soc Am*. janv 2013;56(2):209.17.
22. Guidelines on the prevention, diagnosis, and treatment of infective... - PubMed - NCBI <http://www.ncbi.nlm.nih.gov/pubmed/19713420>
23. Vilacosta I, Graupner C, San Román JA, Sarriá C, Ronderos R, Fernández C, et al. Risk of embolization after institution of antibiotic therapy for infective endocarditis. *J Am Coll Cardiol*. 1 mai 2002;39(9):1489.95.
24. Kang D-H, Kim Y-J, Kim S-H, Sun BJ, Kim D-H, Yun S-C, et al. Early surgery versus conventional treatment for infective endocarditis. *N Engl J Med*. 28 juin 2012;366(26):2466.73.
25. Funakoshi S, Kaji S, Yamamuro A, Tani T, Kinoshita M, Okada Y, et al. Impact of early surgery in the active phase on long-term outcomes in left-sided native valve infective endocarditis. *J Thorac Cardiovasc Surg*. oct 2011;142(4):836.42.e1.
26. Piper C, Wiemer M, Schulte HD, Horstkotte D. Stroke is not a contraindication for urgent valve replacement in acute infective endocarditis. *J Heart Valve Dis*. nov 2001;10(6):703.11.

27. Ruttmann E, Willeit J, Ulmer H, Chevtchik O, Höfer D, Poewe W, et al. Neurological outcome of septic cardioembolic stroke after infective endocarditis. *Stroke J Cereb Circ*. août 2006;37(8):2094.9.
28. Kim SJ, Lee JY, Kim TH, Kim SC, Choi YH, Pai H, et al. Imaging of the neurological complications of infective endocarditis. *Neuroradiology*. févr 1998;40(2):109.13.
29. Charlson ME, Pompei P, Ales KL, MacKenzie CR. A new method of classifying prognostic comorbidity in longitudinal studies: development and validation. *J Chronic Dis*. 1987;40(5):373.83.
30. Roques F, Nashef SA, Michel P, Gauducheau E, de Vincentiis C, Baudet E, et al. Risk factors and outcome in European cardiac surgery: analysis of the EuroSCORE multinational database of 19030 patients. *Eur J Cardio-Thorac Surg Off J Eur Assoc Cardio-Thorac Surg*. juin 1999;15(6):816-22; discussion 822.3.
31. Botelho-Nevers E, Thuny F, Casalta JP, Richet H, Gouriet F, Collart F, et al. Dramatic reduction in infective endocarditis-related mortality with a management-based approach. *Arch Intern Med*. 27 juill 2009;169(14):1290.8.
32. Nishimura RA, Otto CM, Bonow RO, Carabello BA, Erwin JP, Guyton RA, et al. 2014 AHA/ACC Guideline for the Management of Patients With Valvular Heart Disease: executive summary: a report of the American College of Cardiology/American Heart Association Task Force on Practice Guidelines. *Circulation*. 10 juin 2014;129(23):2440.92.
33. Loitfelder M, Seiler S, Schwingenschuh P, Schmidt R. Cerebral microbleeds: a review. *Panminerva Med*. sept 2012;54(3):149.60.
34. Greenberg SM, Vernooij MW, Cordonnier C, Viswanathan A, Al-Shahi Salman R, Warach S, et al. Cerebral microbleeds: a guide to detection and interpretation. *Lancet Neurol*. févr 2009;8(2):165.74.
35. Subramaniam S, Puetz V, Dzialowski I, Barber PA. Cerebral microhemorrhages in a patient with mycotic aneurysm: relevance of T2-GRE imaging in SBE. *Neurology*. 14 nov 2006;67(9):1697.
36. Murdoch DR, Corey GR, Hoen B, Miró JM, Fowler VG Jr, Bayer AS, et al. Clinical presentation, etiology, and outcome of infective endocarditis in the 21st century: the International Collaboration on Endocarditis-Prospective Cohort Study. *Arch Intern Med*. 9 mars 2009;169(5):463.73.
37. Moreillon P, Que Y-A. Infective endocarditis. *Lancet*. 10 janv 2004;363(9403):139.49.
38. Grecu N, Tiu C, Terecoasa E, Bajenaru O. Endocarditis and stroke. *Mædica*. déc 2014;9(4):375.81.

7. TABLES AND FIGURES

Figure 1. Flow chart

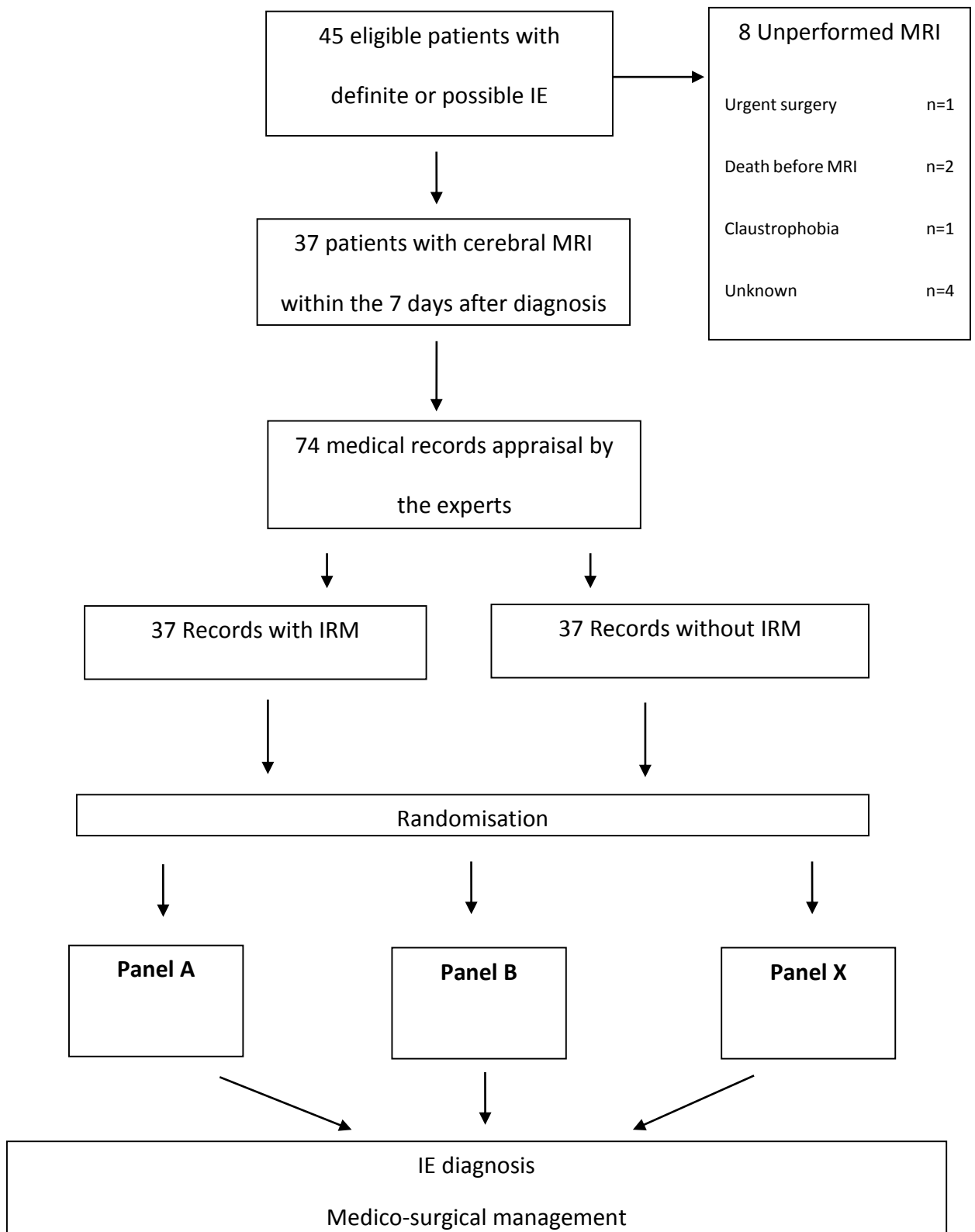


Table 1. Baseline characteristics of patients

	N or median	% Or IQR
Age	71	66-81
Men	21	57
IE risk factors		
Mechanical heart valves	4	11
Bioprothesis	4	11
Implantable cardiac device	3	8
Previous endocarditis	3	8
Pre-existing valvulopathy	6	16
Intravenous drugs use	2	5
Underlying disease		
Respiratory disease	4	11
Heart disease	16	43
Hepatic or digestive disease	3	8
Neurological disease	2	5
Hematologic disease	5	14
Kidney disease	3	8
Diabetes mellitus	15	41
Immunodepression	8	22
Cancer	8	22
Treatment		
Dialysis	1	3
Ambulatory chemotherapy	3	8
Home care	7	19
Prior anticoagulant therapy	12	32

Table 2. Clinical features and IE characteristics

	N or (median)	% Or (IQR)
Definite IE (Dukes criteria)	26	70
Clinical presentation at admission		
Cardiovascular failure	8	22
Prolonged fever (> 15d)	12	32
Respiratory failure	5	14
Hematologic failure	1	3
Neurological symptoms	11	30
Gastro-intestinal symptoms	4	11
Abnormal neurological presentation		
Coma	3	8
Delirium	5	14
Meningeal syndrome	2	5
Focal deficit	4	11
Neurological complications at 3 months	7	23
SOFA^a score at J0		
	(2.2)	(0-3)
SIRS	14	38
Sepsis	10	27
Severe sepsis	4	11
Septic shock	4	11
Intensive care transfer within 24 hours of diagnosis	10	27
SOFA^a score at J3		
	(2.7)	(0-3)
SOFA score at 3 months		
	(0.9)	(0-2)
Charlson comorbidity index		
	(5)	(3-6)
Euroscore I		
	(14)	(11-17)
Positive blood culture/ valvular cultures		
	26	70
Micro-organism identified		
	33	89
Staphylococci	15	41
<i>Staphylococcus aureus</i>	12	32
Coagulase-negative <i>Staphylococcus</i>	3	8
Streptococci	15	41
<i>Streptococcus gallolyticus</i>	7	19
<i>Streptococcus viridans</i>	5	14

<i>Streptococcus agalactiae</i>	1	3
<i>Streptococcus pyogenes</i> (group A)	2	5
Enterococci	2	5
<i>Escherichia coli</i>	2	5
Others microorganism	3	8
No microorganism identified	4	11
Polymicrobial infection	3	8
Health-care associated IE	10	29
Echocardiography data		
Regurgitation > 3/4 ¹	5	17
Vegetation ²	30	81
Mitral	11	41
Aortic	13	48
Tricuspid	3	11
Mobile vegetations	17	77
Vegetation length (cm)	10	5-14
Size ≥ 1 cm	13	50
Cardiac abscess	5	15
Valvular perforation	2	6
Ultrasound heart failure	8	24
MRI abnormalities	26	70
Chest-abdomino-pelvic CT scan abnormalities	12	33
Embolic lesions	7	19
Systemic abscesses	5	16

a Sequential Organ failure Assessment

b Systemic Inflammatory Response Syndrome

c Simplified Severity Index

¹ Valvular regurgitation was assessed semi quantitatively from 0 to 4

² Length was considered at zero for patients without vegetation

Table 3. Surgical cares and patient's outcomes

	N or (median)	% Or (IQR)
Surgical care		
None	15	41
Necessary but not feasible	3	8
Cardiac surgery	10	27
Mechanical valve replacement	2	5
Biological valve replacement	8	22
Duration from inclusion to surgery (days)	(8)	(6-59)
Death at 3 months	6	16
Cardiovascular failure	1	17
Cerebrovascular complication	1	17
Others (sudden death, post-operative Multiorgan failure, sepsis)	4	67
Limiting care strategies	4	13
Disease's recurrence	2	7
Recovery	24	80

Table 4. Neuroimaging data

Angio-MRI data	N = 37 or (median)	% Or (IQR)
Duration from diagnosis to MRI (days)	(5)	(3-7)
MRI abnormalities	26	70
MRI lesions without neurologic symptom	8	31
Ischemia	16	62
Ischemia: territorial lesion	1	6
Ischemia: punctiform lesions	15	94
Haemorrhage	4	15
Microbleeds	15	58
Microbial aneurysm	1	4
Brain abscess	1	4
Others	5	19

Table 5. Expert diagnosis according to Duke Criteria

		With MRI		
		Define	Possible	Excluded
Without MRI	Define	23	0	0
	Possible	2	9	0
	Excluded	0	0	3

Kappa=0.89 (IC95%:[0.74;1])
p<0.01

Table 6. Difference between indication of surgery, type of prostheses and choice of curative anticoagulation

	Yes without MRI		No without MRI		K	Kappa (IC95%)	P
	Yes without MRI	No with MRI	Yes with MRI	No with MRI			
Surgery	11	1	0	25	0.94	[0.82; 1]	P < 0.01
Bioprosthesis	10	1	0	26	0.93	[0.81; 1]	p < 0.01
Curative anticoagulation	19	1	1	16	0.89	[0.74; 1]	p < 0.01
High cerebral diffusion antibiotic addition	0	0	1	26	0.98	[0.86; 1]	p < 0.01

Table 7. Difference regarding timing of surgery

		With MRI		
		Emergency (within 24H)	Urgent (after 48H of antibiotherapy)	Postponed
Without MRI	Emergency	4	2	0
	Urgent	1	3	0
	Postponed	0	0	1

Kappa = 0.53 (IC 95%: [0.17; 0.84])
p=0.01

Abstract

Introduction

In Infective Endocarditis (IE), brain Magnetic Resonance Imaging (MRI) is helpful to diagnose clinically silent neurologic events, especially micro ischemic and micro haemorrhagic lesions. Brain MRI may be fitted in a complete imaging check-up including, at an early stage, chest abdomen, pelvis Computered Tomography (CT) and echocardiography for a thoroughly asymptomatic lesions mapping.

Objective

We aimed to assess the usefulness of systematic early brain MRI in IE diagnosis and medico-surgical cares management.

Methods

During one year, all patients admitted in one of the 3 hospitals participating and fulfilling Duke's criteria for definite or possible IE, underwent cerebral MRI with angiography within the 7 days of IE-suspicion.

To assess the MRI contribution, records were analyzed a posteriori by 8 panels of experts. For each case, one record with and one record without the MRI results, were randomly assigned to 2 panels who determined theoretical diagnosis and treatment. Inter-rater concordances were assessed through Cohen Kappa test.

Results

Thirty-seven brain MRI were realized in a median time of 5 days after inclusion. MRI was pathological in 26 patients (70%) showing 62 % of micro ischemia and 58% of microbleeds.

Experts advices were significantly concordant between the 2 evaluations with or without the MRI results. Diagnosis differed in 2 cases (5.4%) with an upgrading of diagnosis from possible to definite IE using MRI results. Discrepancies concerning therapeutic attitudes occurred in 8 cases (21.5 %) including one change in the indication to operate, 3 modifications of timing of surgery namely 2 earlier and one postponed surgery with the MRI results and 1 disagreement over the choice of prosthesis. Changes concerned anticoagulation in 2 cases. Rifampicin was added to the antimicrobial therapy in 1 case.

Conclusion

Because it does not seem to plenty affect diagnosis and medico-surgical cares; our results do not support the need for a systematic use of early brain MRI in IE. Further studies are necessary to clearly define if MRI is mandatory in IE management within a multidisciplinary approach; the better timing to realize it and the subset of patients in which it could be beneficial.

Keywords

Infective endocarditis, brain magnetic resonance imaging, brain micro ischemia, cerebral microbleeds, cardiac surgery procedures.

