



HAL
open science

Functional results of cervical rib resection for thoracic outlet syndrome: impact on professional activity

Jessica Morel

► **To cite this version:**

Jessica Morel. Functional results of cervical rib resection for thoracic outlet syndrome: impact on professional activity. Human health and pathology. 2018. dumas-01757873

HAL Id: dumas-01757873

<https://dumas.ccsd.cnrs.fr/dumas-01757873>

Submitted on 4 Apr 2018

HAL is a multi-disciplinary open access archive for the deposit and dissemination of scientific research documents, whether they are published or not. The documents may come from teaching and research institutions in France or abroad, or from public or private research centers.

L'archive ouverte pluridisciplinaire **HAL**, est destinée au dépôt et à la diffusion de documents scientifiques de niveau recherche, publiés ou non, émanant des établissements d'enseignement et de recherche français ou étrangers, des laboratoires publics ou privés.



AVERTISSEMENT

Ce document est le fruit d'un long travail approuvé par le jury de soutenance et mis à disposition de l'ensemble de la communauté universitaire élargie.

Il n'a pas été réévalué depuis la date de soutenance.

Il est soumis à la propriété intellectuelle de l'auteur. Ceci implique une obligation de citation et de référencement lors de l'utilisation de ce document.

D'autre part, toute contrefaçon, plagiat, reproduction illicite encourt une poursuite pénale.

Contact au SID de Grenoble :
bump-theses@univ-grenoble-alpes.fr

LIENS

Code de la Propriété Intellectuelle. articles L 122. 4

Code de la Propriété Intellectuelle. articles L 335.2- L 335.10

<http://www.cfcopies.com/juridique/droit-auteur>

<http://www.culture.gouv.fr/culture/infos-pratiques/droits/protection.htm>



UNIVERSITÉ GRENOBLE ALPES
UFR DE MÉDECINE DE GRENOBLE

Année 2018

**FUNCTIONAL RESULTS OF CERVICAL RIB RESECTION FOR THORACIC
OUTLET SYNDROME: IMPACT ON PROFESSIONAL ACTIVITY**

THÈSE
PRÉSENTÉE POUR L'OBTENTION DU TITRE DE DOCTEUR EN MÉDECINE
DIPLOME D'ÉTAT

MOREL Jessica

[Données à caractère personnel]

THÈSE SOUTENUE PUBLIQUEMENT À LA FACULTÉ DE MÉDECINE DE GRENOBLE

Le 30/03/2018

DEVANT LE JURY COMPOSÉ DE

Monsieur le Professeur Jean – Luc MAGNE : Président du jury

Monsieur le Professeur Pierre – Yves BRICHON

Monsieur le Professeur Gilles PERNOD

Madame le Docteur Rafaëlle SPEAR : Directeur de thèse

Monsieur le Docteur Augustin PIRVU

L'UFR de Médecine de Grenoble n'entend donner aucune approbation ni improbation aux opinions émises dans les thèses ; ces opinions sont considérées comme propres à leurs auteurs.

Doyen de la Faculté : Pr. Patrice MORAND

Année 2017-2018

ENSEIGNANTS A L'UFR DE MEDECINE

CORPS	NOM-PRENOM	Discipline universitaire
PU-PH	ALBALADEJO Pierre	Anesthésiologie réanimation
PU-PH	APTEL Florent	Ophthalmologie
PU-PH	ARVIEUX-BARTHELEMY Catherine	Chirurgie générale
PU-PH	BAILLET Athan	Rhumatologie
PU-PH	BARONE-ROCHETTE Gilles	Cardiologie
PU-PH	BAYAT Sam	Physiologie
PU-PH	BENHAMOU Pierre Yves	Endocrinologie, diabète et maladies métaboliques
PU-PH	BERGER François	Biologie cellulaire
MCU-PH	BIDART-COUTTON Marie	Biologie cellulaire
MCU-PH	BOISSET Sandrine	Agents infectieux
PU-PH	BONAZ Bruno	Gastro-entérologie, hépatologie, addictologie
PU-PH	BONNETERRE Vincent	Médecine et santé au travail
PU-PH	BOREL Anne-Laure	Endocrinologie, diabète et maladies métaboliques
PU-PH	BOSSON Jean-Luc	Biostatistiques, informatique médicale et technologies de communication
MCU-PH	BOTTARI Serge	Biologie cellulaire
PU-PH	BOUGEROL Thierry	Psychiatrie d'adultes
PU-PH	BOUILLET Laurence	Médecine interne
PU-PH	BOUZAT Pierre	Réanimation
MCU-PH	BRENIER-PINCHART Marie Pierre	Parasitologie et mycologie
PU-PH	BRICAULT Ivan	Radiologie et imagerie médicale
PU-PH	BRICHON Pierre-Yves	Chirurgie thoracique et cardio-vasculaire
MCU-PH	BRIOT Raphaël	Thérapeutique, médecine d'urgence
MCU-PH	BROUILLET Sophie	Biologie et médecine du développement et de la reproduction
PU-PH	CAHN Jean-Yves	Hématologie
PU-PH	CARPENTIER Françoise	Thérapeutique, médecine d'urgence
PU-PH	CARPENTIER Patrick	Chirurgie vasculaire, médecine vasculaire
PU-PH	CESBRON Jean-Yves	Immunologie
PU-PH	CHABARDES Stephan	Neurochirurgie
PU-PH	CHABRE Olivier	Endocrinologie, diabète et maladies métaboliques
PU-PH	CHAFFANJON Philippe	Anatomie
PU-PH	CHARLES Julie	Dermatologie
PU-PH	CHAVANON Olivier	Chirurgie thoracique et cardio-vasculaire
PU-PH	CHIQUET Christophe	Ophthalmologie

PU-PH	CHIRICA Mircea	Chirurgie générale
PU-PH	CINQUIN Philippe	Biostatistiques, informatique médicale et technologies de communication
MCU-PH	CLAVARINO Giovanna	Immunologie
PU-PH	COHEN Olivier	Biostatistiques, informatique médicale et technologies de communication
PU-PH	COURVOISIER Aurélien	Chirurgie infantile
PU-PH	COUTURIER Pascal	Gériatrie et biologie du vieillissement
PU-PH	CRACOWSKI Jean-Luc	Pharmacologie fondamentale, pharmacologie clinique
PU-PH	CURE Hervé	Oncologie
PU-PH	DEBILLON Thierry	Pédiatrie
PU-PH	DECAENS Thomas	Gastro-entérologie, Hépatologie
PU-PH	DEMATTEIS Maurice	Addictologie
MCU-PH	DERANSART Colin	Physiologie
PU-PH	DESCOTES Jean-Luc	Urologie
MCU-PH	DETANTE Olivier	Neurologie
MCU-PH	DIETERICH Klaus	Génétique et procréation
MCU-PH	DOUTRELEAU Stéphane	Physiologie
MCU-PH	DUMESTRE-PERARD Chantal	Immunologie
PU-PH	EPAULARD Olivier	Maladies Infectieuses et Tropicales
PU-PH	ESTEVE François	Biophysique et médecine nucléaire
MCU-PH	EYSSERIC Hélène	Médecine légale et droit de la santé
PU-PH	FAGRET Daniel	Biophysique et médecine nucléaire
PU-PH	FAUCHERON Jean-Luc	Chirurgie générale
MCU-PH	FAURE Julien	Biochimie et biologie moléculaire
PU-PH	FERRETTI Gilbert	Radiologie et imagerie médicale
PU-PH	FEUERSTEIN Claude	Physiologie
PU-PH	FONTAINE Éric	Nutrition
PU-PH	FRANCOIS Patrice	Epidémiologie, économie de la santé et prévention
MCU-MG	GABOREAU Yoann	Médecine Générale
PU-PH	GARBAN Frédéric	Hématologie, transfusion
PU-PH	GAUDIN Philippe	Rhumatologie
PU-PH	GAVAZZI Gaétan	Gériatrie et biologie du vieillissement
PU-PH	GAY Emmanuel	Neurochirurgie
MCU-PH	GILLOIS Pierre	Biostatistiques, informatique médicale et technologies de communication
MCU-PH	GRAND Sylvie	Radiologie et imagerie médicale
PU-PH	GRIFFET Jacques	Chirurgie infantile
PU-PH	GUEBRE-EGZIABHER Fitsum	Néphrologie
MCU-PH	GUZUN Rita	Endocrinologie, diabétologie, nutrition, éducation thérapeutique
PU-PH	HAINAUT Pierre	Biochimie, biologie moléculaire
PU-PH	HENNEBICQ Sylviane	Génétique et procréation
PU-PH	HOFFMANN Pascale	Gynécologie obstétrique
PU-PH	HOMMEL Marc	Neurologie
PU-MG	IMBERT Patrick	Médecine Générale
PU-PH	JOUK Pierre-Simon	Génétique
PU-PH	JUVIN Robert	Rhumatologie

PU-PH	KAHANE Philippe	Physiologie
MCU-PH	KASTLER Adrian	Radiologie et imagerie médicale
PU-PH	KRACK Paul	Neurologie
PU-PH	KRAINIK Alexandre	Radiologie et imagerie médicale
PU-PH	LABARERE José	Epidémiologie ; Eco. de la Santé
MCU-PH	LABLANCHE Sandrine	Endocrinologie, diabète et maladies métaboliques
MCU-PH	LANDELLE Caroline	Bactériologie - virologie
MCU-PH	LAPORTE François	Biochimie et biologie moléculaire
MCU-PH	LARDY Bernard	Biochimie et biologie moléculaire
MCU-PH	LARRAT Sylvie	Bactériologie, virologie
MCU - PH	LE PISSART Audrey	Biochimie et biologie moléculaire
PU-PH	LECCIA Marie-Thérèse	Dermato-vénérologie
PU-PH	LEROUX Dominique	Génétique
PU-PH	LEROY Vincent	Gastro-entérologie, hépatologie, addictologie
PU-PH	LEVY Patrick	Physiologie
PU-PH	LONG Jean-Alexandre	Urologie
PU-PH	MAGNE Jean-Luc	Chirurgie vasculaire
MCU-PH	MAIGNAN Maxime	Thérapeutique, médecine d'urgence
PU-PH	MAITRE Anne	Médecine et santé au travail
MCU-PH	MALLARET Marie-Reine	Epidémiologie, économie de la santé et prévention
MCU-PH	MARLU Raphaël	Hématologie, transfusion
MCU-PH	MAUBON Danièle	Parasitologie et mycologie
PU-PH	MAURIN Max	Bactériologie - virologie
MCU-PH	MC LEER Anne	Cytologie et histologie
PU-PH	MERLOZ Philippe	Chirurgie orthopédique et traumatologie
PU-PH	MORAND Patrice	Bactériologie - virologie
PU-PH	MOREAU-GAUDRY Alexandre	Biostatistiques, informatique médicale et technologies de communication
PU-PH	MORO Elena	Neurologie
PU-PH	MORO-SIBILOT Denis	Pneumologie
PU-PH	MOUSSEAU Mireille	Cancérologie
PU-PH	MOUTET François	Chirurgie plastique, reconstructrice et esthétique ; brûlologie
MCU-PH	PACLET Marie-Hélène	Biochimie et biologie moléculaire
PU-PH	PALOMBI Olivier	Anatomie
PU-PH	PARK Sophie	Hémato - transfusion
PU-PH	PASSAGGIA Jean-Guy	Anatomie
PU-PH	PAYEN DE LA GARANDERIE Jean-François	Anesthésiologie réanimation
MCU-PH	PAYSANT François	Médecine légale et droit de la santé
MCU-PH	PELLETIER Laurent	Biologie cellulaire
PU-PH	PELLOUX Hervé	Parasitologie et mycologie
PU-PH	PEPIN Jean-Louis	Physiologie
PU-PH	PERENNOU Dominique	Médecine physique et de réadaptation
PU-PH	PERNOD Gilles	Médecine vasculaire
PU-PH	PIOLAT Christian	Chirurgie infantile
PU-PH	PISON Christophe	Pneumologie

PU-PH	PLANTAZ Dominique	Pédiatrie
PU-PH	POIGNARD Pascal	Virologie
PU-PH	POLACK Benoît	Hématologie
PU-PH	POLOSAN Mircea	Psychiatrie d'adultes
PU-PH	PONS Jean-Claude	Gynécologie obstétrique
PU-PH	RAMBEAUD Jacques	Urologie
PU-PH	RAY Pierre	Biologie et médecine du développement et de la reproduction
PU-PH	REYT Émile	Oto-rhino-laryngologie
PU-PH	RIGHINI Christian	Oto-rhino-laryngologie
PU-PH	ROMANET Jean Paul	Ophthalmologie
PU-PH	ROSTAING Lionel	Néphrologie
MCU-PH	ROUSTIT Matthieu	Pharmacologie fondamentale, pharmaco clinique, addictologie
MCU-PH	ROUX-BUISSON Nathalie	Biochimie, toxicologie et pharmacologie
MCU-PH	RUBIO Amandine	Pédiatrie
PU-PH	SARAGAGLIA Dominique	Chirurgie orthopédique et traumatologie
MCU-PH	SATRE Véronique	Génétique
PU-PH	SAUDOU Frédéric	Biologie Cellulaire
PU-PH	SCHMERBER Sébastien	Oto-rhino-laryngologie
PU-PH	SCHWEBEL-CANALI Carole	Réanimation médicale
PU-PH	SCOLAN Virginie	Médecine légale et droit de la santé
MCU-PH	SEIGNEURIN Arnaud	Epidémiologie, économie de la santé et prévention
PU-PH	STAHL Jean-Paul	Maladies infectieuses, maladies tropicales
PU-PH	STANKE Françoise	Pharmacologie fondamentale
MCU-PH	STASIA Marie-José	Biochimie et biologie moléculaire
PU-PH	STURM Nathalie	Anatomie et cytologie pathologiques
PU-PH	TAMISIER Renaud	Physiologie
PU-PH	TERZI Nicolas	Réanimation
MCU-PH	TOFFART Anne-Claire	Pneumologie
PU-PH	TONETTI Jérôme	Chirurgie orthopédique et traumatologie
PU-PH	TOUSSAINT Bertrand	Biochimie et biologie moléculaire
PU-PH	VANZETTO Gérald	Cardiologie
PU-PH	VUILLEZ Jean-Philippe	Biophysique et médecine nucléaire
PU-PH	WEIL Georges	Epidémiologie, économie de la santé et prévention
PU-PH	ZAOUÏ Philippe	Néphrologie
PU-PH	ZARSKI Jean-Pierre	Gastro-entérologie, hépatologie, addictologie

PU-PH : Professeur des Universités et Praticiens Hospitaliers
MCU-PH : Maître de Conférences des Universités et Praticiens Hospitaliers
PU-MG : Professeur des Universités de Médecine Générale
MCU-MG : Maître de Conférences des Universités de Médecine Générale

Remerciements :

A mes Maîtres et juges

Au professeur Jean-Luc MAGNE.

Vous me faites l'honneur de présider cette thèse. Je vous remercie de m'avoir acceptée parmi les vôtres. Merci de votre formation, de votre calme, votre patience, votre disponibilité, votre humanité et votre bienveillance rassurante au quotidien. Je suis fière d'être issue de votre école et de bénéficier de votre savoir. J'aimerais pouvoir un jour exercer la chirurgie vasculaire avec la même précision et la même sagesse que vous.

Au professeur Pierre-Yves BRICHON

Merci de me faire l'honneur de juger cette thèse (qui est quand même un peu de la chirurgie thoracique). Votre rapidité et votre discrète omniscience dans le travail me laisse très admirative. C'est toujours un grand moment d'être votre aide, tant pour votre humour que pour le plaisir des yeux de vous regarder opérer.

Au professeur Gilles PERNOD

Je vous remercie d'avoir accepté de faire partie de ce jury. Merci de votre disponibilité sur nos interrogations médicales. J'espère que la collaboration de nos services perdurera.

Au docteur Rafaëlle SPEAR

Je te remercie d'avoir accepté si rapidement et avec autant d'investissement la direction de ce travail. Merci pour ton soutien, ta disponibilité, tes nombreuses relectures, tes conseils et tout ce temps que tu m'as consacré. J'ai beaucoup appris à tes côtés en 4 mois et j'espère pouvoir encore continuer ainsi.

Au docteur Augustin PIRVU

Je te remercie d'avoir accepté de faire partie de ce jury. Il était naturel pour moi que tu sois à cette place aujourd'hui pour tout ce que tu m'as appris tout au long de mon internat. J'admire beaucoup ton sang-froid, ton calme inébranlable en toute situation et ta grande maîtrise de tout.

A mes Maîtres en chirurgie

Au professeur Philippe CHAFFANJON pour votre incroyable pédagogie de chaque instant et de chaque détail au bloc opératoire. L'anatomie nous apparaît facile avec vous et j'admire beaucoup votre éventail de connaissance et la mémoire qui va avec.

Aux professeurs Jean-Pierre FAVRE et Jean-Noël ALBERTINI pour m'avoir accueillie un semestre à Saint Etienne.

Au docteur Roberto GULINO, pour cette nouvelle vision des choses que tu nous apportes. Merci de ta disponibilité, de l'attention que tu nous portes. C'est un plaisir de travailler avec toi.

Aux docteurs Emmanuel COCHET et Caroline DUCOS pour ce tout premier semestre avec vous. Vous m'avez convaincue que ce métier était vraiment génial. Merci pour votre patience, votre enseignement et pour m'avoir donné le goût de la chirurgie. Ne pas revenir travailler un semestre avec vous restera le regret de mon internat et je n'oublierai pas votre calme et ce plaisir de vous voir opérer tous les jours. Je vous souhaite le meilleur pour la suite à Annecy.

Au docteur Sébastien PEROU pour tout ce que tu m'as enseigné, ta rigueur et ta prévoyance que j'aimerais égaler. Et aussi parce que Édouard et toi étiez les meilleurs internes de tout mon externat et que vous m'avez vraiment donné envie de suivre votre voie.

Au docteur Albéric DE LAMBERT et au docteur Kheira HIRECHE pour tout ce que vous m'avez enseigné pendant ce trop court semestre passé avec vous.

Au docteur Sébastien GUIGARD pour ta bonne humeur et ton entrain quotidien au travail.

Au docteur Julio ABBA pour m'avoir presque donné envie de faire de la chirurgie digestive, pour ton enseignement permanent de tes compétences chirurgicales et ta gentillesse quotidienne.

Au docteur Olivier RISSE pour votre pédagogie avec toujours une touche d'humour. C'est toujours un plaisir de vous croiser dans l'ascenseur.

Nico pour ton humour décapant et ta pédagogie à notre égard au quotidien.

Amandine pour ton amitié et ta façon si optimiste de voir la vie.

A tous ceux qui ont été mes co-internes un jour (petite mention spéciale à Venkiki pour les cafés/daubage, Mel parce que t'étais vraiment la meilleure co-interne d'apéro, Bastien et Greg pour m'avoir supportée ces dernières semaines).

A mes co-internes stéphanois, pour ce semestre formateur, difficile mais à tous ces moments réconfortants qu'on a su créer.

Aude et Bertrand pour votre ténacité et votre gentillesse.

A toute l'équipe du bloc vasculaire et thoracique, anesthésistes, infirmières et brancardiers, actuelle et tous ceux qui sont parti, pour votre travail, votre professionnalisme et votre bonne humeur. Vous contribuez beaucoup au plaisir que j'ai à exercer ce métier au quotidien et je me réjouis d'avance de partager encore beaucoup de moments avec vous.

A toute l'équipe du 10^{ème} A,B et D (infirmiers/aides-soignants/ASH/kinés et secrétaires (mention spéciale à Jo et Dolo pour les dossiers !)) pour votre professionnalisme de tous les jours, tous ceux présents actuellement et tous les anciens qui ont quitté le service. Vous êtes pour nous un soutien quotidien et c'est un réel plaisir de travailler avec vous chaque jour.

A tout l'équipe du bloc CCV de Saint Etienne pour votre compétence, votre travail et votre gentillesse. Vous êtes géniaux, je ne vous oublierai jamais.

A mes parents, pour votre soutien et votre présence toujours discrets mais sans faille. J'espère pouvoir vous rendre un jour tout ce que je vous dois.

A Pascal, Nicolas & Caro et les petits : Téo, Léonie, Tabatha et Scarlett. Je ne vous vois pas assez mais je pense beaucoup à vous.

Pierre, Annie et Paulette pour votre accueil toujours chaleureux et tous ces moments passés en votre compagnie.

Laura, ma blonde, pour ton amitié infinie et tous ces moments, de joies ou de peines, partagés, impossibles à résumer en quelques mots. Et Alix qui est à tes côtés chaque jour.

A mes anciennes co-équipières que je n'oublie pas malgré le temps : Marie Lou, Anne et Adeline en souvenir de ce 4 juillet 2004.

Ludo, Astrid, Phiphi, Papass, Loïc et Amélie pour ces supers semaines en Laponie !

Mes Michels adorés, Raph, Marianne, Yoann, Marjo, Marine, Renaud, Marine, Josie, Delphine, Gaëlle, Mathieu, Bastien, Gueuëlle, Eva, Umberto, Robin pour cette solide amitié maintenue depuis des années, malgré les allers et venues des uns et des autres à l'autre bout de la France ou de la Terre. Pour toute cette folie qui se dégage de nous à chaque michellerie.

Martin, pour ta présence et ton soutien éternel, pour chaque instant toujours trop court, pour toutes ces petites choses que l'on partage, ici ou ailleurs, pour cette vie ensemble qui ne fait que commencer.

Table des matières

ABSTRACT:	8
INTRODUCTION:	10
METHODS:	11
RESULTS:	14
<i>Demographic data</i>	14
<i>Procedure results</i>	15
<i>Early outcomes</i>	15
<i>Professional activity</i> :	17
ANNEXES	23
REFERENCES	29

ABSTRACT:

Objective: The aim of this study is to report long-term functional results following cervical rib (CR) resection for thoracic outlet syndrome (TOS).

Methods: This monocentric study included all cases of resection of CR for TOS performed between January 2004 and December 2016. Data were retrospectively collected from the hospital electronic database including pre-operatively symptoms and the evaluation of occupational well-being, intraoperative data, and early clinical evaluation and occupational well-being during the post-operative period. Patients were categorized as neurogenic TOS (NTOS), arterial TOS (ATOS), arterial and neurogenic (ANTOS), venous TOS (VTOS) or asymptomatic according to preoperative evaluation. We evaluated the improvement in work life between the preoperative and the post-operative period. Further assessment was a negative Roos or elevated arm stress test (EAST) during the post-operative period.

Results: Thirty-three patients with a median age of 38.5 years (30-46) were included. Thirty-six procedures were performed: 33 % to treat ATOS (12/36), 39% for NTOS (14/36), 19% for ANTOS (7/36), 3% for VTOS (1/36) and 6% (2/36) for asymptomatic lesions. There were 9 cases of subclavian artery aneurysms leading to additional arterial repair. Due to distal embolization, a cervical sympathectomy was associated in 5 procedures. First rib resection (FRR) was associated in 4 procedures (11%) and C7 transverse process resection was performed in 15 procedures (42%). The technical success rate was 100% and intra-operative complications were observed in 4 patients (11%) with favorable postoperative outcomes. During the early postoperative period, 3 Claude Bernard Horner's syndrome and 1 asymptomatic subclavian dissection were detected. Late complications included 2 bypass thromboses (6%) at 6 weeks and 16 months. Post-operative EAST improved in 16 limbs (44%).

Prior to the procedure, only 27% (9/33) patients had normal work lives. After the procedure, 64% (21/33) of patients were able to return to their normal work activity.

Conclusion: Cervical rib resection for TOS seems to be a safe procedure leading to good short and long-term clinical results with a favorable impact on recovering a normal work life in these young patients.

INTRODUCTION:

Cervical rib (CR) is an abnormal bone originating from the seventh vertebra (1). CR is observed in 0.2 to 1% of the general population (2,3). Only 10 % of CR are responsible of thoracic outlet syndrome (TOS). TOS is secondary to the compression of the neurovascular bundle. CR is associated with an increased rate of arterial compression in TOS (4,5) . Arterial injury is classified as Grüber stage 3 or 4.

Surgical decompression in TOS without anatomical abnormality is indicated when physiotherapy fails. Where CR is present, it must be surgically withdrawn. CR resection was first described by Coote in 1861 (6). Many studies report short and long-term results of surgical decompression for TOS (7). First rib resection and scalenectomy (FRRS) associated with CR resection when it presents is the surgical treatment of TOS. The association of FRRS and CR resection is controversial. Most studies report results of combined FRRS and CR resection. There is a lack of literature about CR resection without FRRS for TOS. Nevertheless, the presence of CR can cause specific vascular complications like subclavian aneurysms which require appropriate treatment.

In this study, we report the monocentric experience of CR resection in TOS over 12 years. We evaluate long term functional results following cervical rib resection for TOS and the occupational impact of the surgery.

METHODS:

Study population:

All patients who underwent CR resection were selected from the hospital electronic database. Research was made with keywords “rib resection” and “thoracic outlet syndrome” and all operative reports were reviewed. In this analysis, we only included patients who required CR resection. Those with only FFRS without CR resection were excluded.

Demographic and clinical data such as gender, age at the time of surgery, medical history, active smoking, pre-operative symptoms, and the orthopedic history of the upper limb, medical therapy, professional activity and potential occupational disability were collected. The Roos or elevated arm stress test (EAST) was performed as part of the clinical examination before the procedure and 1 month following the procedure (8).

Patients were classified according to reporting standards (9). Preoperative symptoms could be arterial (ATOS) (arm claudication, the absence of radial pulse, finger ulcer or necrosis, upper limb acute ischemia or sub ischemia), neurogenic (NTOS) (paresthesia, weakness, muscle atrophy of the upper limb), both arterial and neurogenic (ANTOS) or venous (VTOS) (edema, deep vein thrombosis).

All patients underwent a chest X Ray, the primary examination to diagnose cervical rib (Figure 1). Patients were retrospectively categorized in accordance with Grüber’s classification. Grüber’s classification of cervical rib was described in 1968 and differentiates 4 anatomical presentations (10) : 1: a rudimentary rib that does not penetrate the transverse process; 2: a small cervical rib that extends beyond the transverse process of the seventh cervical vertebra with a free distal end; 3: a cervical rib continued by a fibrous or fibromuscular band ending to the first thoracic rib and 4: a cervical rib connected to the first thoracic rib with true cartilage.

Dynamic Doppler ultrasound was systematically performed to confirm ATOS and to diagnose potential associated arterial injuries. Computed tomography angiography (CTA) was systematically performed to further analyze arterial impairment. An angiogram was performed pre-operatively if distal emboli were depicted on CTA or in case of distal ulcers, lack of radial or ulnar pulses. Electromyogram (EMG) was performed in patients with symptoms evoking NTOS. The increase of distal nerve conduction and low velocities suggested a brachial plexus impairment.

Surgical technique:

All surgeries were performed under general anesthesia as described by Shein in 1971 (11). The phrenic nerve was systematically assessed by external monitoring at the beginning and at the end of the procedure. Access was supraclavicular (Figure 2). CR was systematically performed. FRR and/or C7 transverse process resection was performed if dynamic maneuvers still depicted a stress compression of vessels or of neurologic bundles after CR resection. Bone resection was performed with a Kerisson clamp. Adjunctive cervical sympathectomy (CS) was performed prior to 2015 in patients presenting with aneurysms and distal emboli. Data on intra-operative complications and on additional arterial subclavian repair (aneurysmorrhaphy, aneurysmal resection, bypass, embolectomy) were collected. At the end of the procedure, dynamic maneuvers were systematically performed to confirm the release of the neurovascular bundle during upper limb abduction. When confirmed, the procedure was considered as a technical success. All patients but isolated NTOS received antiplatelet therapy following surgery. A postoperative Doppler ultrasound was systematically performed in ATOS and ANTOS at one month.

For the purpose of this study, we updated the follow-up for each patient either using the report of their last medical visit in the year (general practitioner, neurologist or Doppler ultrasound) or by phone.

We evaluated each patient's quality of work life pre-and post-operatively. We also evaluated the EAST during the post-operative period.

Early outcome was the 30 first days follow up. Late outcomes were those thereafter.

Statistical analysis:

Categorical variables were presented as percentages and continuous variables were expressed as median with interquartile ranges (Q1-Q3).

RESULTS:

Demographic data

From January 2004 to December 2016, 36 cervical ribs were resected in 33 patients at the Grenoble University Hospital. Three patients (9%) required bilateral treatment of TOS by CR resection.

The population consisted in 27 women and 6 men with a median age of 38.5 (30-46) at the time of surgery. The youngest patient was 13 years old and the oldest 58 years old. Nineteen patients had cardiovascular risk factors including 1 dyslipidemia and 18 active in smoking. One patient had a history of ipsilateral collarbone fracture and 7 were followed for upper limb orthopedic disease. Details of demographic data are summarized in Table 1. Among the 36 cervical resections, 22 were on the right side and 14 on the left side. The most common Grüber's category treated was the fourth for the resected cervical rib side (61%). Contralateral CR was present in 27 patients (82%) with a predominance of the category 3.

There were 14/36 procedures (39%) in patients suffering from NTOS, 12/36 (33%) from ATOS, 7/36 (19%) from ANTOS and 1/36 (3%) from VTOS. There were 2 asymptomatic patients (6%) (Table 2). The youngest patient of this study a 13-year-old girl who presented with a severe scoliosis treated with a back brace. A unilateral CR was discovered on the X Ray of the spine. The CR was removed after multidisciplinary discussion including orthopedic and vascular surgeons. A second asymptomatic rib was resected in a 28-year-old female who presented with a left cervical rib complicated with a voluminous subclavian aneurysm. It was decided to remove the contralateral CR preventively.

Preoperative EAST was positive for 23 limbs: 5 ATOS (42%) 12 NTOS (86%), and 6 ANTOS (87%).

On preoperative exams, 9 subclavian aneurysms, 6 subclavian stenosis and 6 subclavian post-stenotic dilations (3 aneurysms and 3 ectasia) were depicted. EMG was performed in 23 limbs and reported suffering of brachial plexus in 49% (11/23).

Procedure results

Details of surgical outcomes are summarized in Table 3.

Among patients with upper limb ischemia, 19% (7/36) two (6%) required CR resection associated with urgent revascularization. The last required anticoagulation therapy before CR resection.

The resection of CR was complete in 94% (34/36) of procedures. CR resection was left incomplete when the release of the neurovascular bundle was obtained and the whole CR could not be accessed without risking neurologic or vascular damage. Fifteen procedures (42%) were associated with the resection of the C7 transverse process. Four procedures (11%) were associated with first rib resection (FRR). There were 5 associated cervical sympathectomies.

Additional arterial procedures were required during 9 procedures (25%) with arterial aneurysms: 1 aneurysmorrhaphy, 5 aneurysmal resection and direct reconstruction and 3 prosthetic bypasses. Three subclavian ectasias were left untreated.

The technical success rate was 100%.

Intraoperative complications were observed in 11% of procedures: 4 pleural effusion treated by adjunctive chest tube. All pleural effusion resolved favorably at 48h. No brachial plexus or phrenic nerve injury was described.

Early outcomes

The median length of hospitalization was 3.5 days (3-4).

Postoperative complications were detected in 11% of the cases studied: 3 (8%) Claude Bernard Horner's (CBH) syndrome, spontaneously resolved and an asymptomatic subclavian dissection (3%) depicted in a postoperative Doppler ultrasound. This dissection was treated only by antiplatelet therapy with good results. No access complication was observed.

On clinical exam at 1 month, 7 limbs (19%) were EAST positive: 4 NTOS (29%) and 3 ATOS (25%) (Table 4a). All patients treated with adjunctive CS had a radial pulse postoperatively.

Late outcomes:

The median follow-up was 91 months (39-123). The last procedure practiced had a follow-up of eleven months and the earliest 165 months. Two patients were lost to follow up because they could not be reached by phone. They were both considered as unable to have a normal professional activity. One of them had no clinical evaluation during the postoperative period and was considered worsened (EAST positive on follow-up).

Late complications were two bypass thromboses (6%), at 6 weeks and 16 months. One required a secondary procedure. The embolectomy in emergency was not successful and a thoracic sympathectomy by videothoracoscopy was required at one year to treat upper limb claudication with a good clinical outcome. The last bypass occlusion was asymptomatic and detected at 16 months by standard follow up Doppler ultrasound.

During follow-up, patients with ATOS, ANTOS or VTOS had control of permeability by Doppler ultrasound or CTA. The patency rate was 75 % at 1 year, 67% at two years, 67% at 5 years.

Three patients presented with a reoccurrence of symptoms at 6 weeks, at 4 years and at 10 years after the surgery. The first patient was the patient who presented a bypass thrombosis.

The two other were NTOS.

Professional activity:

During the pre-operative period, 9 patients (27%) had a normal work life and 24 (73%) couldn't work before the surgery. On follow up, 64% (21/33) had a normal work life: 14 (42%) were improved and seven (21%) patients showed no improvement. Patients were unable to work after the surgery in 36% of cases (12/33). Ten patients (30%) showed no modification and two patients (6%) were worsened: one patient suffering from fibromyalgia who required a reorganization of activity and one lost to follow-up considered as worsened. Details according to symptoms are summarized in Table 4b.

DISCUSSION:

This study suggests the safety and effectiveness of CR resection in the treatment of TOS. Functional results and quality of life after surgery of TOS in the literature have already been analyzed (7). Nevertheless, only few studies cover CR resection and the majority with FRRS. CR is not common and is generally asymptomatic. We described in this study outcomes of our surgical approach of CR resection for TOS with a supraclavicular access associated with FRR only if neurovascular entrapment is persistent during intraoperative dynamic maneuvers. Our postoperative outcomes are acceptable considering both clinical and functional evaluation. Only a few studies evaluate postoperative pain and disability. We focused on the occupational ability in our evaluation of postoperative functional outcome in this young population.

In our population 61% had symptoms on the right side. The majority of our patients were women (82%, 27/33) and our population was young with a median age of 38.5 (30-46) similarly to that described in the literature (3). The rate of bilateral CR in our study is higher than that observed in the literature : CR was bilateral in 82% of our patients (1,3,12). TOS has been associated with a history of neck trauma with or without CR (12). Interestingly, we report only one patient with a history of collarbone fracture and eleven cases (31%) associated with rheumatologic disease (shoulder or neck). TOS could be associated with neurological compression disorder of the upper limb. It is the double crush syndrome, including carpal tunnel syndrome, elbow nerve compression or cervical root compression. The rate is 51% of patients for Degeorges et al (13) whereas we found only 9% of double crush syndrome (carpal tunnel). In our series, two procedures were performed on asymptomatic patients with CR. One was justified preventively in a context of contralateral CR associated with an aneurysm,

the second was to allow orthopedic contention. The CR resection was performed in order to prevent a TOS associated with rheumatologic disease.

Among symptomatic patients, arterial symptoms were observed in a majority (53%, 19/36). This observation is similar to prior studies suggesting a strong association between the presence of CR and the incidence of TOS, notably ATOS (3,14) but only few VTOS (4).

CR resection for TOS is mandatory (15). Little evidence is available when considering CR resection alone (12,13,16,17). Whether CR resection must be associated with FRRS remains controversial. Many studies described removing CR along with the first rib to prevent a late recurrence (12,15,16). However, the FRR may increase the risk of morbidity because of a deeper dissection (18). Our technique is to remove FRR only when the neurovascular bundle is still compressed even after CR resection as described by Davies et al, Desai and Robbs and Ambrad-Chalela et al (19–21). Interestingly, FRR resection was only required in NTOS patients and was performed partially in one half of cases. One of them was not improved after surgery. Recurrence of symptoms appeared after three procedures (9%, 3/36). None was associated with FRRS. Recurrence of TOS is described after FRRS in 11,5% with a reoperation rate of 2,5% (22) . Recently, Gelabert et al (23) advocated the necessity to withdraw completely CR bone or the first rib bone to avoid the recurrence of symptoms. Recurrent TOS after CR resection only has not been studied to our knowledge.

C7 transverse process resection was performed in 42% of procedures when a large apophysis was found. Cormier et al (24) also described a C7 process resection in their study in 1989. No results considering the association with C7 process resection are available to our knowledge.

Two CR resections were not complete. In these two procedures, technical success was reached as the complete release of neurovascular bundle was obtained after partial resection (18). We

did not observe any recurrence of symptoms postoperatively. One of them was the only VTOS of this study and required the release of the subclavian vein. The second is an ANTOS with a negative EAST. He was able to return at work post-operatively.

In their ATOS patients, Marine and al (5) described favorable outcomes of revascularization of the ischemic upper limb without CS. CS were described in cases of distal embolization, particularly when associated with digital trophic disorder (20,24). In this study, all patients treated with CS were improved by this technique and a radial pulse was detected after surgery while absent prior to surgery. One thoracic sympathectomy was performed during the postoperative period because of a symptomatic bypass thrombosis.

Long term functional results for limbs with additional arterial procedures were good. Nonetheless, the patency rate of bypasses was low. Two bypasses (66%) were occluded during follow-up. One was asymptomatic and depicted on regular ultrasound exam. The second required an early thoracic sympathectomy to treat a claudication of the upper limb. Dacron grafts were used in 3 bypasses. The patency rate is lower than described in TOS using veins or PTFE grafts (90 à 100%) (5,25,26). These data suggest that an autologous vein graft or PTFE graft must be preferred to Dacron graft. Aneurysm resection and direct anastomosis of subclavian artery seem to provide good results as described previously (24). It should be considered as the first treatment whenever feasible.

Subclavian ectasia were left untreated and were not associated with any aneurysmal evolution once CR resected as reported in other studies (26,27).

Association between CR and ATOS (5) and severity of ATOS could justify the preventive resection of a complete CR in case of contralateral arterial injury (16,28). In this study, one patient was treated preventively as described above.

CR resection is safe and associated in our experience with a low rate of early complications (11%). No neurogenic injury was observed, according to the literature with a rate < 1% (29). CBH and pleural breach (11%) were similar as other TOS studies (1 to 23%) (4,5,13,24,28) .

One asymptomatic subclavian dissection in the post-operative period was discovered on scheduled Doppler ultrasound at 16 months. In a recent study, Rinehardt et al (29) found an association between vascular symptoms of TOS and the reintervention or new admission rate within 30 days.

Post-operative clinical results are good in our study with a real improvement of EAST. The ability of patients to go back to their occupation in this chronic and disabling disease is indicative of favorable long-term functional results. Outcomes are better in associated arterial and neurogenic TOS (0% of positive EAST in post-operative period) and less favorable in NTOS (29% of positive EAST in post-operative period). Divi et al in 2005 found the same results in return to work for patients presenting venous and neurogenic TOS (30) .

Our study is one of the largest on CR resection in TOS. However, limits are numerous. It is a retrospective and monocentric study with a small population due to the rarity of this disease.

CONCLUSION:

CR resection is safe and efficient to treat TOS. Association with FRRS is not mandatory. This technique is associated with favorable long-term outcomes in terms of occupation.

ANNEXES

Table 1: Pre-operative demographics data (N=33)

Median age	38.5 [30;46]	
		N (%)
Male	6	(18)
Female	27	(82)
Cardiovascular risk		
Smoking	18	(55)
Obesity	3	(9)
Dyslipidemia	1	(3)
Associated orthopedic issues		
Collarbone fracture	1	(3)
Rheumatoid polyarthritis	2	(6)
Scoliosis	3	(9)
Cervical discopathy	3	(9)
Cervical osteosynthesis	1	(3)
Shoulder tendinopathy	1	(3)
Shoulder capsulitis	1	(3)
Carpal tunnel	3	(9)
Ipsilateral	1	(3)
Bilateral	2	(6)

Table 2: Pre-operative symptoms N = 36

	N	(%)
ATOS	12	(39)
Upper limb Ischemia	7	(19)
Claudication of arm	8	(22)
Finger ulcer or necrosis	5	(14)
Radial pulselessness	7	(19)
NTOS	14	(33)
Paresthesia	8	(22)
Weakness	13	(36)
Muscle's atrophy	4	(11)
ANTOS	7	(19)
Claudication	6	(17)
Paresthesia	4	(11)
Muscle weakness	6	(17)
Muscle's atrophy	1	(3)
VTOS	1	(3)
Deep venous thrombosis	1	(3)
Asymptomatic	2	(6)

ATOS: Arterial Thoracic Outlet Syndrome. NTOS Neurogenic Thoracic Outlet Syndrome.
 ANTOS: Arterial and Neurogenic Thoracic Outlet Syndrome. VTOS: Venous Thoracic Outlet Syndrome.

Table 3: Procedure data and complications N = 36

	N	(%)
Sub clavicular access	36	(100)
<hr/>		
Bones resection		
Cervical rib resection	36	(100)
Total	34	(94)
Partial	2	(6)
First rib resection	4	(11)
Total	2	(6)
Anterior bow	1	(3)
Posterior bow	1	(3)
C7 transverse process resection	15	(42)
<hr/>		
Muscle resection		
Anterior scalene		
Section during access	35	(97)
Distal resection on first rib	19	(53)
Posterior scalene	1	(3)
<hr/>		
Additional arterial procedure		
Aneurysmorrhaphy	1	(3)
Aneurysm resection- anastomosis	5	(14)
Bypass	3	(8)
Proximal embolectomy	0	(0)
Distal embolectomy	2	(6)
<hr/>		
Additional cervical sympathectomy	5	(14)
<hr/>		
Technical success	36	(100)
<hr/>		
Intraoperative complications		
Pleural breach	4	(11)

Table 4a: Clinical evaluation: Positive EAST (N=36)

	ATOS (n=12)	NTOS (n=14)	ANTOS (n=7)	VTOS (n=1)	Asymptomatic (n=2)	Total (n=36)
Pre-operative	5 (42)	12 (86)	6 (87)	0 (0)	0 (0)	23 (64)
Post-operative	3 (25)	4 (29)	0 (0)	0 (0)	0 (0)	7 (19)

Table 4b: Clinical evaluation: Professional ability (N=33)

	ATOS (n=12)	NTOS (n=12)	ANTOS (n=7)	VTOS (n=1)	Asymptomatic (n=1)	Total (n=33)
Improvement	3 (25)	6 (50)	5 (71)	0 (0)	0 (0)	14 (42)
Stabilization	9 (75)	4 (33)	2 (29)	1 (100)	1 (100)	17 (52)
Worsening	0 (0)	2 (17)	0 (0)	0 (0)	0 (0)	2 (6)

EAST: Elevated Arm Stressed Test. ATOS: Arterial Thoracic Outlet Syndrome. NTOS Neurogenic Thoracic Outlet Syndrome. ANTOS: Arterial and Neurogenic Thoracic Outlet Syndrome. VTOS: Venous Thoracic Outlet Syndrome.

Figure 1: Right cervical rib on chest X- Ray.

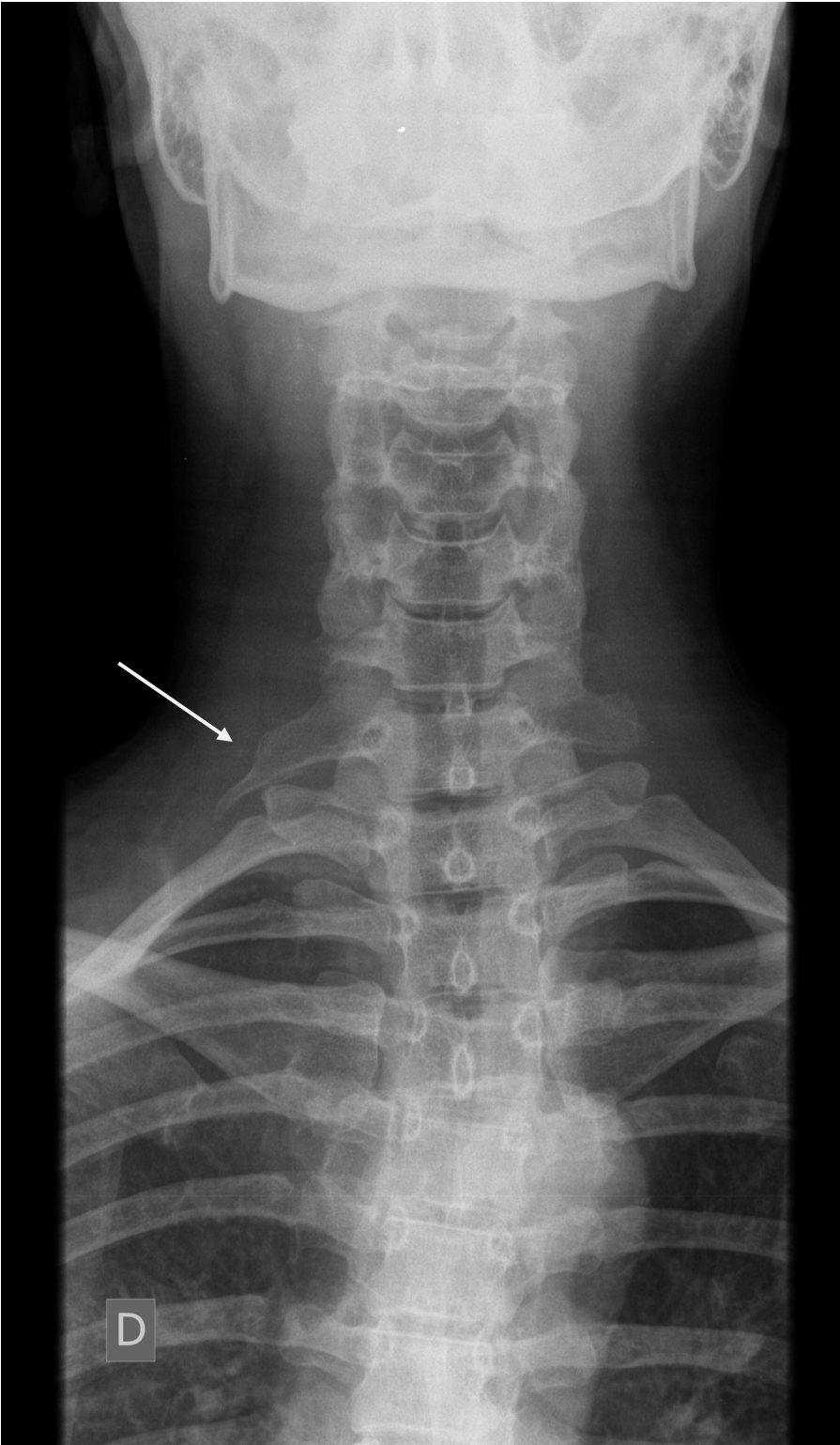
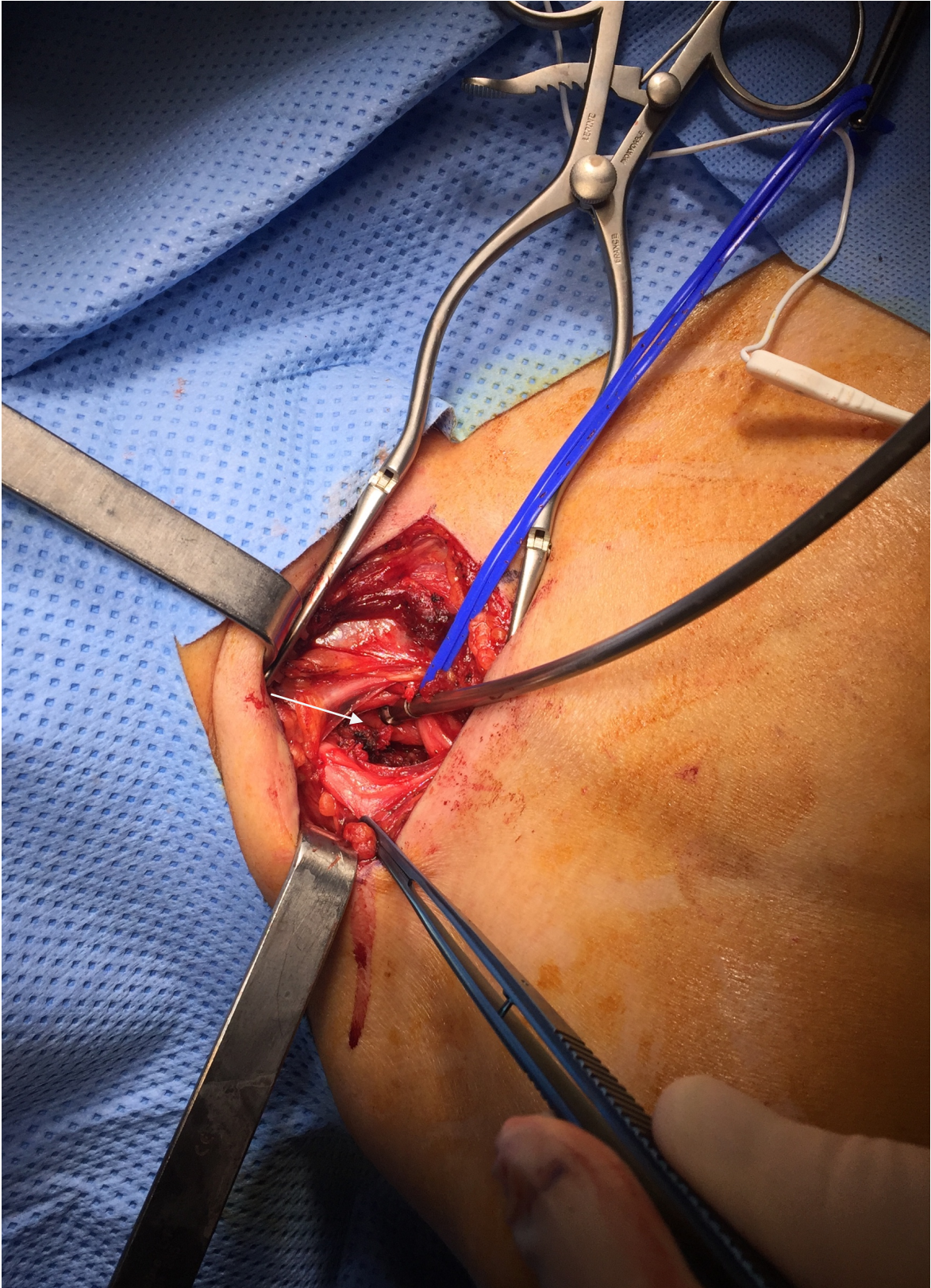


Figure 2: per operative visualization of cervical rib



REFERENCES

1. McNally E, Sandin B, Wilkins RA. The ossification of the costal element of the seventh cervical vertebra with particular reference to cervical ribs. *J Anat.* 1990;170:125.
2. Guttentag AR, Salwen JK. Keep your eyes on the ribs: the spectrum of normal variants and diseases that involve the ribs. *Radiographics.* 1999;19:1125–42.
3. Henry BM, Vikse J, Sanna B, Tattera D, Gomulska M, Pękala PA, et al. Cervical rib prevalence and its association with Thoracic Outlet Syndrome: a meta-analysis of 141 studies with surgical considerations. *World Neurosurg.* 2018 Feb;110:965-978
4. Orlando MS, Likes KC, Mirza S, Cao Y, Cohen A, Lum YW, et al. A Decade of Excellent Outcomes after Surgical Intervention in 538 Patients with Thoracic Outlet Syndrome. *J Am Coll Surg.* 2015;220:934–9.
5. Marine L, Valdes F, Mertens R, Kramer A, Bergoeing M, Urbina J. Arterial Thoracic Outlet Syndrome: A 32-year Experience. *Ann Vasc Surg.* 2013;27:1007–13.
6. Coote H. Exostosis of the left transverse process of the seventh cervical vertebra, surrounded by blood vessels and nerves; successful removal. *Lancet.* 1861;
7. Peek J, Vos CG, Ünlü Ç, van de Pavoordt HDWM, van den Akker PJ, de Vries J-PPM. Outcome of Surgical Treatment for Thoracic Outlet Syndrome: Systematic Review and Meta-Analysis. *Ann Vasc Surg.* 2017;40:303–26.
8. Roos DB. Congenital anomalies associated with thoracic outlet syndrome. Anatomy, symptoms, diagnosis, and treatment. *Am J Surg.* 1976;132:771–8.
9. Illig KA, Donahue D, Duncan A, Freischlag J, Gelabert H, Johansen K, et al. Reporting standards of the Society for Vascular Surgery for thoracic outlet syndrome. *J Vasc Surg.* 2016;64:23–35.
10. Grüber W. *Über die Halsrippen des Menschen.* St Petersburg; 1869.
11. Schein CJ. A technic for cervical rib resection. *Am J Surg.* 1971;121:623–7.
12. Sanders RJ, Hammond SL. Management of cervical ribs and anomalous first ribs causing neurogenic thoracic outlet syndrome. *J Vasc Surg.* 2002;36:51–6.
13. Degeorges R, Reynaud C, Becquemin J-P. Thoracic Outlet Syndrome Surgery: Long-Term Functional Results. *Ann Vasc Surg.* 2004;18:558–65.
14. Sanders RJ, Pearce WH. The treatment of thoracic outlet syndrome: a comparison of different operations. *J Vasc Surg.* 1989;10:626–34.
15. Toso C, Robert J, Berney T, Pugin F, Spiliopoulos A. Thoracic outlet syndrome: influence of personal history and surgical technique on long-term results. *Eur J Cardio-Thorac*

Surg Off J Eur Assoc Cardio-Thorac Surg. 1999;16:44–7.

16. Chang KZ, Likes K, Davis K, Demos J, Freischlag JA. The significance of cervical ribs in thoracic outlet syndrome. *J Vasc Surg.* 2013;57:771–5.
17. Brown SCW, Charlesworth D. Results of excision of a cervical rib in patients with the thoracic outlet syndrome. *Br J Surg.* 1988;75:431–3.
18. Sanders RJ, Annest SJ. Technique of supraclavicular decompression for neurogenic thoracic outlet syndrome. *J Vasc Surg.* 2015 Mar;61:821–5.
19. Davies AH, Walton J, Stuart E, Morris PJ. Surgical management of the thoracic outlet compression syndrome. *Br J Surg.* 1991;78:1193–5.
20. Desai Y, Robbs JV. Arterial complications of the thoracic outlet syndrome. *Eur J Vasc Endovasc Surg.* 1995;10:362–5.
21. Ambrad-Chalela E, Thomas GI, Johansen KH. Recurrent neurogenic thoracic outlet syndrome. *Am J Surg.* 2004;187:505–10.
22. Urschel Jr HC, Kourlis Jr H. Thoracic outlet syndrome: a 50-year experience at Baylor University Medical Center. In: *Baylor University Medical Center Proceedings.* 2007. p. 125–35.
23. Gelabert HA, Jabori S, Barleben A, Kiang S, O’Connell J, Jimenez JC, et al. Regrown First Rib in Patients with Recurrent Thoracic Outlet Syndrome. *Ann Vasc Surg.* 2014;28:933–8.
24. Cormier JM, Amrane M, Ward A, Laurian C, Gigou F. Arterial complications of the thoracic outlet syndrome: fifty-five operative cases. *J Vasc Surg.* 1989;9:778–87.
25. Davidovic LB, Kostic DM, Jakovljevic NS, Kuzmanovic IL, Simic TM. Vascular Thoracic Outlet Syndrome. *World J Surg.* 2003;27:545–50.
26. Vemuri C, McLaughlin LN, Abuirqeba AA, Thompson RW. Clinical presentation and management of arterial thoracic outlet syndrome. *J Vasc Surg.* 2017;65:1429–39.
27. Short DW. The subclavian artery in 16 patients with complete cervical ribs. *J Cardiovasc Surg (Torino).* 1975 Apr;16:135–41.
28. Rochlin DH, Orlando MS, Likes KC, Jacobs C, Freischlag JA. Bilateral first rib resection and scalenectomy is effective for treatment of thoracic outlet syndrome. *J Vasc Surg.* 2014;60:185–90.
29. Rinehardt EK, Scarborough JE, Bennett KM. Current practice of thoracic outlet decompression surgery in the United States. *J Vasc Surg.* 2017;66:858–65.
30. Divi V, Proctor MC, Axelrod DA, Greenfield LJ. Thoracic outlet decompression for subclavian vein thrombosis: experience in 71 patients. *Arch Surg.* 2005;140:54–7.

CONCLUSION

THESE SOUTENUE PAR: MOREL Jessica

TITRE: Functional results of cervical rib's resection for thoracic outlet syndrome: impact on professional activity.

RESUME :

Objectif : Cette étude évaluait les résultats à long terme de la résection de la côte cervicale (CC) dans le syndrome du défilé thoraco-brachial (STTB).

Méthodes : Dans cette étude monocentrique, toutes les résections de CC pratiquées entre janvier 2004 et décembre 2016 pour une décompression du défilé thoraco-brachial étaient incluses. Les données recueillies de manière rétrospective comprenaient les symptômes préopératoires, les examens paracliniques, les techniques chirurgicales ainsi que l'évaluation clinique post-opératoire précoce (inférieure ou égal à 30 jours) et tardive (supérieure à 30 jours). Les STTB étaient classés en 5 catégories : artérielle (aSTTB), neurologique (nSTTB), artérielle et neurologique (anSTTB), veineuse (vSTTB) et asymptomatique traité préventivement. Les résultats fonctionnels de la résection de CC évalués par le test de Roos ainsi que l'impact sur l'activité professionnelle étaient comparés à la période préopératoire.

Résultats : Trente-trois patients d'âge médian de 38,5 ans (IQR 30-46) étaient inclus. Dans cette cohorte, 73% (24/33) ne pouvait exercer leur activité professionnelle (arrêt de travail, adaptation du travail en temps ou en activité). Trente-six procédures étaient réalisées : 33% pour aSTTB (12/36), 39% nSTTB (14/36), 19% anSTTB (7/36), 3% vSTTB (1/36) et 6% pour STTB asymptomatique (2/36). Dans le même temps opératoire, 9 anévrismes artériels (25%) étaient traités et 5 sympathectomies cervicales (14%) réalisées. Le test de Roos était positif dans 23 cas (64%) en préopératoire versus 7 (19%) en postopératoire. Le taux de complications précoces était de 11% (3 syndromes de Claude Bernard Horner et 1 dissection sous-clavière) d'évolution spontanément favorable. La durée médiane de suivi était de 91 mois (IQR 39-123). Lors du suivi tardif, les complications étaient de 6% (2/36) (2 occlusions de pontage à 6 semaines et 16 mois). Une reprise ou un maintien de l'activité professionnelle postopératoire était

observé dans 64% des cas (43%, 14/33 et 21%, 7/33 respectivement). Aucune activité professionnelle n'était possible pour 36% des patients : interruption de l'activité dans 6% des cas (2/33) ou invalidité et reclassement professionnel pour 30% des patients (10/33).

Conclusion : Le STTB est associé à des difficultés professionnelles. Les résultats fonctionnels à long terme de cette série monocentrique sont associés à un taux satisfaisant de reprise et de maintien de l'activité professionnelle.

VU ET PERMIS D'IMPRIMER
Grenoble, le 28/02/2018

LE DOYEN


LE PRESIDENT DE LA THESE

Patrice MORAND


Le Doyen de l'UFR de Médecine
Pr. Patrice MORAND

PROFESSEUR JL MAGNE





SERMENT D'HIPPOCRATE

En présence des Maîtres de cette Faculté, de mes chers condisciples et devant l'effigie d'HIPPOCRATE,

Je promets et je jure d'être fidèle aux lois de l'honneur et de la probité dans l'exercice de la Médecine.

Je donnerai mes soins gratuitement à l'indigent et n'exigerai jamais un salaire au dessus de mon travail. Je ne participerai à aucun partage clandestin d'honoraires.

Admis dans l'intimité des maisons, mes yeux n'y verront pas ce qui s'y passe ; ma langue taira les secrets qui me seront confiés et mon état ne servira pas à corrompre les mœurs, ni à favoriser le crime.

Je ne permettrai pas que des considérations de religion, de nation, de race, de parti ou de classe sociale viennent s'interposer entre mon devoir et mon patient.

Je garderai le respect absolu de la vie humaine.

Même sous la menace, je n'admettrai pas de faire usage de mes connaissances médicales contre les lois de l'humanité.

Respectueux et reconnaissant envers mes Maîtres, je rendrai à leurs enfants l'instruction que j'ai reçue de leurs pères.

Que les hommes m'accordent leur estime si je suis fidèle à mes promesses.

Que je sois couvert d'opprobre et méprisé de mes confrères si j'y manque.

ABSTRACT:

Objective: The aim of this study was to report long-term functional results following cervical rib (CR) resection for thoracic outlet syndrome (TOS).

Methods: This study included all cases of resection of CR for TOS performed between January 2004 and December 2016. Data were retrospectively collected including pre-operative symptoms, occupational well-being, intraoperative data, and early clinical evaluation in the post-operative period. Patients were categorized into neurogenic TOS (NTOS), arterial TOS (ATOS), arterial and neurogenic (ANTOS), venous TOS (VTOS) or asymptomatic. We evaluated the improvement in work life between the preoperative and the post-operative period. Further assessment was a negative Roos test or elevated arm stressed test (EAST) in the post-operative period.

Results: Thirty-three patient with a median age of 38.5 years (30-46) were included. Thirty-six procedures were performed: 33 % to treat ATOS (12/36) of procedures, 39% for NTOS (14/36), 19% for ANTOS (7/36), 3% for VTOS (1/36) and 6% (2/36) for asymptomatic lesions.

There were 9 cases of subclavian artery aneurysms leading to additional arterial repair.

Intra-operative complications were observed in 4 patients (11%) with favorable postoperative outcomes. EAST was improved in 16 limbs (44%) in the postoperative period.

Prior to the procedure, only 27% (9/33) patients had a normal work life. After the procedure, 64% (21/33) of patients were able to recover a normal work activity.

Conclusion: Cervical rib resection for TOS seems to be a safe procedure leading to good short and long-term clinical result with a favorable impact on recovering a normal work life in these young patients.