



**THÈSE D'EXERCICE / UNIVERSITÉ DE RENNES 1**

*sous le sceau de l'Université Bretagne Loire*

Thèse en vue du

**DIPLÔME D'ÉTAT DE DOCTEUR EN CHIRURGIE DENTAIRE**

présentée par

**Fanny HENRY**

née le 06 Octobre 1993 à Schoelcher.

---

**Gestion  
pluridisciplinaire  
du sens vertical  
squelettique et  
dentaire des  
patients atteints  
d'Amélogénèse  
Imparfaite isolée.**

**Thèse soutenue à Rennes  
le 14 septembre 2018**

devant le jury composé de :

**Olivier SOREL**

Professeur des Universités - UFR de Rennes  
Président du Jury

**Damien BREZULIER**

Assistant Hospitalo Universitaire - UFR de Rennes  
Directeur de Thèse

**Jean-Louis SIXOU**

Professeur des Universités - UFR de Rennes  
Assesseur

**Justine LE CLERC**

Maître de Conférences des Universités - UFR de  
Rennes  
Assesseur

**Julien CARDONA**

Praticien attaché- UFR de Rennes  
Assesseur

---

**Section 56 : Développement, croissance et prévention**

---

**Sous-section 56-01 Odontologie pédiatrique et orthopédie dento-faciale :**

Discipline Odontologie pédiatrique

<b>SIXOU Jean-Louis</b>	<i>Professeur des universités</i>
<b>MARIE-COUSIN Alexia</b>	<i>Maître de conférences des universités</i>
LARADH Imen	<i>Assistant hospitalier universitaire</i>

Discipline Orthopédie dento-faciale

<b>SOREL Olivier</b>	<i>Professeur des universités</i>
<b>MANO Marie-Charlotte</b>	<i>Maître de conférences des universités</i>
DUCROZ Bertrand	<i>Assistant hospitalier universitaire</i>
BREZULIER Damien	<i>Assistant hospitalier universitaire</i>
ALLEREAU Béatrice	<i>Assistant hospitalier universitaire</i>

**Sous-section 56-02 Prévention, épidémiologie, économie de la santé, odontologie légale**

<b>BERTAUD-GOUNOT Valérie</b>	<i>Professeur des universités</i>
<b>PRIGENT Hervé</b>	<i>Maître de conférences des universités</i>
COUATARMANACH Antoine	<i>Assistant hospitalier universitaire</i>

---

**Section 57 : Chirurgie orale ; parodontologie ; biologie orale**

---

**Sous-section 57-01 Chirurgie orale ; parodontologie ; biologie orale :**

Discipline Chirurgie orale

<b>LEJEUNE-CAIRON Sophie</b>	<i>Maître de conférences des universités</i>
<b>LIMBOUR Patrick</b>	<i>Maître de conférences des universités</i>
<b>BADER Gérard</b>	<i>Maître de conférences des universités</i>
DULONG Arnaud	<i>Assistant hospitalier universitaire</i>
DERRIEN Anthony	<i>Assistant hospitalier universitaire</i>
FAU Victor	<i>Assistant hospitalier universitaire</i>

Discipline Parodontologie

<b>JEANNE Sylvie</b>	<i>Professeur des universités</i>
<b>BOLLE Caroline</b>	<i>Maître de conférences associé des universités</i>
SOENEN Anne-Hélène	<i>Assistant hospitalier universitaire</i>
NOVELLO Solen	<i>Assistant hospitalier universitaire</i>

Discipline Biologie orale

<b>BONNAURE-MALLET Martine</b>	<i>Professeur des universités</i>
<b>MARTIN Bénédicte</b>	<i>Professeur associé des universités</i>
<b>MEURIC Vincent</b>	<i>Maître de conférences des universités</i>
BOYER Emile	<i>Assistant hospitalier universitaire</i>
CHATHOTH Kanchana	<i>Assistant associé universitaire</i>

---

## Section 58 : Réhabilitation orale :

---

### Sous-section 58-01 Dentisterie restauratrice, endodontie, prothèses, fonction-dysfonction, imagerie, biomatériaux :

#### Discipline Dentisterie restauratrice, endodontie

<b>DAUTEL Anne</b>	<i>Maître de conférences des universités</i>
<b>LE GOFF Anne</b>	<i>Maître de conférences des universités</i>
<b>TURPIN Yann-Loïc</b>	<i>Maître de conférences des universités</i>
<b>PERARD Matthieu</b>	<i>Maître de conférences des universités</i>
<b>LE CLERC Justine</b>	<i>Maître de conférences des universités</i>
DUMONT Laure-Anne	<i>Assistant hospitalier universitaire</i>
BINET Sophie	<i>Assistant hospitalier universitaire</i>
VO VAN Thomas	<i>Assistant hospitalier universitaire</i>

#### Discipline Prothèses

<b>BEDOUIN Yvan</b>	<i>Maître de conférences des universités</i>
<b>CHAUVEL Brice</b>	<i>Maître de conférences des universités</i>
<b>RAVALEC Xavier</b>	<i>Maître de conférences des universités</i>
POIRIER Charles-Edouard	<i>Assistant hospitalier universitaire</i>
VASLIN Marc	<i>Assistant hospitalier universitaire</i>
PERRIGAULT Sébastien	<i>Assistant hospitalier universitaire</i>
SAINT-ETIENNE Clothilde	<i>Assistant hospitalier universitaire</i>
GOUBIN William	<i>Assistant hospitalier universitaire</i>

#### Discipline Fonction-dysfonction, imagerie, biomatériaux

<b>CATHELINEAU Guy</b>	<i>Professeur des universités</i>
<b>CHAUVEL-LEBRET Dominique</b>	<i>Maître de conférences des universités</i>
<b>MEARY Fleur</b>	<i>Maître de conférences des universités</i>
MELOU Caroline	<i>Assistant hospitalier universitaire</i>

---

## Enseignants autres sections

---

### Section 41 - Sciences biologiques

<b>TAMANAI-SHACOORI Zohreh</b>	<i>Maître de conférences des universités</i>
--------------------------------	--

### Section 64-65 – Biochimie et biologie moléculaire, biologie cellulaire

<b>GAUTIER-COURTEILLE Carole</b>	<i>Maître de conférences des universités</i>
----------------------------------	--

## REMERCIEMENTS

**A Monsieur le Professeur Olivier SOREL,**  
Docteur en Chirurgie-Dentaire Professeur des Universités  
Praticien Hospitalier - Orthopédie dento-faciale.

Vous me faites l'honneur de présider le jury de ma thèse et je vous en suis extrêmement reconnaissante. Je vous remercie par ailleurs pour la qualité de votre enseignement de la spécialité d'ODF. Veuillez trouver ici le témoignage de mon plus grand respect et de ma très sincère gratitude.

**A Monsieur le Docteur Damien BREZULIER,**  
Docteur en Chirurgie-Dentaire,  
Assistant des Universités en Orthopédie Dento-Faciale,  
Praticien Hospitalier du Centre de Soins Dentaires de Rennes 1.

Pour avoir accepté de diriger ce travail, je te remercie pour ton aide à chaque étape de la réalisation, pour ta grande réactivité et disponibilité (malgré un timing bien serré!), la qualité de ton écoute et de ton enseignement. Sois également remercié pour la gentillesse et la bonne humeur. Tu resteras une référence, sur le plan professionnel et humain, que je m'efforcerais de suivre pendant toute ma carrière. Je suis fière d'avoir travaillé avec toi et de soutenir cette thèse aujourd'hui. Je t'exprime ma profonde reconnaissance et mes respectueux remerciements.

**A Madame Justine LECLERC,**  
Docteur en Chirurgie-Dentaire, Maître de Conférence des Universités,  
Praticien Hospitalier du Centre de Soins Dentaires de Rennes 1.

Je te remercie d'avoir accepté de siéger dans ce jury. Ta pédagogie et ta bienveillance m'ont permis de vivre un apprentissage serein. Je t'exprime mes respectueux remerciements et ma sincère reconnaissance.

**A Monsieur le Professeur Jean-Louis SIXOU,**  
Docteur en Chirurgie-Dentaire, Professeur des Universités,  
Praticien Hospitalier du Centre de Soins Dentaires de Rennes,  
Chef de l'Unité Fonctionnelle de Pédodontie.

Je vous remercie de siéger dans ce jury et d'avoir accepté d'évaluer mon travail. Veuillez trouver ici le témoignage de ma sympathie, de mon admiration, et de mon profond respect. Je vous remercie également de m'avoir fait partager votre passion pour la prise en charge dentaire des patients atteints de maladies rares et pour la pédodontie. Je vous remercie également de m'avoir permis d'effectuer un semestre à l'université Laval à Québec et de maintenir les échanges avec nos amis Québécois.

**A Monsieur le Docteur Julien CARDONA**  
Docteur en Chirurgie-Dentaire,  
Praticien Hospitalier du Centre de Soins Dentaires de Rennes.

Je te remercie d'avoir accepté mon invitation et de participer au sein de ce jury. Toujours de bon conseil, ton professionnalisme et ton humour m'ont beaucoup apporté. Merci pour ta sympathie, ta transmission chaleureuse aussi bien lors des nombreux Travaux Pratiques en 2ème et 3ème années si bien animés, tes enseignements et ce goût de la perfection que tu as su transmettre.

**A Madame le Docteur Joanna M DANCER,**  
PhD MBA MDentSci BChD DOrth MOrth FDS(Orth), Consultant in Orthodontics  
Chair - Lancashire and South Cumbria Orthodontic Managed Clinical Network  
Deputy Director - BOS Clinical Practice Directorate.

Je vous remercie tout particulièrement pour votre contribution, les heures que vous avez consacrées à la relecture de cette thèse, pour vos multiples conseils et transmission. Vos nombreuses suggestions ont grandement amélioré la qualité de ce travail et la correction de la rédaction en anglais m'a été une aide précieuse. Votre réactivité et votre confiance ont été des éléments moteurs pour moi.

I sincerely thank you for your help, kindness and for your rich contribution. I wish to express to you my profound gratitude.

**A Marco MAZEVET,**

Marco, je n'aurai pas assez de place sur ces quelques lignes pour t'exprimer ma plus profonde reconnaissance pour ton soutien, tes conseils avisés ces derniers mois que ce soit à travers mon parcours universitaire, mes questionnements quant à mon futur parcours professionnel ou ce travail de rédaction. Tu as toujours répondu présent, Outre-Atlantique, outre-Manche ou sur le sol breton ; tes réflexions et tes commentaires précieux m'ont beaucoup aidée à avancer. Le pari de rédaction dans la langue de Shakespeare n'était pas gagné...I wish you the best, thank you.

**A Matthieu PERARD,**

C'est bien sous ta supervision, en cinquième année que j'ai pu découvrir la prise en charge clinique des patients atteints d'Amélogénèse Imparfait. Tu as suscité chez moi le grand intérêt que je porte à la réalisation précise et ordonnée de chaque étape d'un traitement dentaire conservateur ou prothétique et plus particulièrement à la gestion de cas esthétiques. Je te remercie pour ta bienveillance et la confiance que tu as su me communiquer.

***A Madame le Professeur JEANNE et le Docteur Caroline BOLLE,***

Je vous remercie, pour votre écoute, vos conseils pour la suite de mon parcours, votre disponibilité, et les nombreuses réponses aux questions qui se sont posées en ce début d'année 2018 à mon retour du Canada. Vous m'avez transmis au cours de ces années d'études cette passion pour la spécialité, merci de m'avoir encouragée à poursuivre le cursus.

**A Julien LAMBERT**

Pour ta précieuse aide à l'élaboration de la présentation orale, ton professionnalisme et tes conseils pédagogiques dans la gestion des traitements des patients atteints d'Amélogénèse Imparfait. J'admire l'investissement dont tu fais preuve pour permettre le développement de la conception de travaux CFAO.

***A Caroline LEGRAND,***

Notre cher Directeur de Thèse est bien à l'origine de nos échanges ! Je te remercie pour ton réel soutien durant ces quelques mois de travail, tu as su me guider ! Tes excellents conseils lors de la préparation de cette thèse, ainsi que ton humour et tes petites phrases motivantes et rassurantes ont été précieux.

**A mes chers Professeurs,**

J'en profite donc pour vous exprimer ma reconnaissance et vous remercier pour vos enseignements, vos conseils, ainsi que cette belle opportunité d'avoir pu effectuer le premier semestre de sixième année au Canada. Je vous remercie de m'avoir transmis vos compétences pour l'exercice de l'Art dentaire. Je garderai un très bon souvenir des ces belles années d'études.

**Aux personnels administratifs de la Faculté de Chirurgie Dentaire et de la Bibliothèque Universitaire de Médecine et d'Odontologie,**

Un grand merci pour votre professionnalisme et votre écoute.

***A ma précieuse famille pour votre soutien et votre affection,***

***A mes parents et à mes sœurs chéris,***

Merci de m'avoir épaulée et soutenue, par votre bienveillance et votre amour, à chaque étape de mon parcours. Je vous dédie cette thèse. Merci pour tout ce que vous avez fait pour moi et surtout ce que vous êtes.

***A tous mes chers amis français et québécois,***

Les merveilleuses Queens, Servane, Lucie, Aude, Justine, Estelle, Laure, Wensie, Anastasia, Philippine, pour cette sacrée amitié depuis la O2 et tout ce qui va avec... Corentin, Eric, Simon, Francois, Tyber, pour ces joyeux moments durant ces 5 années, les dentaires pour toutes nos soirées mémorables et ces belles années en TP et en clinique, Mes supers copines de médecine, Agnès, Astrid, Clémence, Camélia, Marion avec qui chaque moment est si précieux, malgré la distance, Amélie, Corentin D, Angélique, Hélène, Domitille, Guillemette, Mélanie, Charlotte, Floriane, Kathleen, Anne-Lise, Jimmy, le tripode, Ghazal pour tous nos précieux moments passés et à venir, et à toutes les personnes qui me sont chères. A François, un grand merci du fond du cœur.

« Je certifie sur l'honneur ne pas avoir repris pour mon compte des propos, citations, ou illustrations  
déjà publiées »

# TABLE OF CONTENTS

<b>1</b>	<b>INTRODUCTION .....</b>	<b>9</b>
<b>2</b>	<b>METHODS.....</b>	<b>10</b>
2.1	SELECTION CRITERIA APPLIED FOR THE REVIEW, INCLUSION CRITERIA .....	10
2.2	EXCLUSION CRITERIA .....	10
2.3	SEARCH STRATEGY .....	10
2.4	DATA EXTRACTION AND MANAGEMENT .....	11
<b>3</b>	<b>RESULTS .....</b>	<b>11</b>
3.1	INCLUSION OF STUDIES .....	11
3.2	PATIENT'S GENERAL CHARACTERISTICS [TABLE 7, CF ANNEX].....	13
3.3	MALOCCLUSION CHARACTERISTICS. [TABLE 8, SEE ANNEX] .....	14
3.3.1	<i>General consideration and evaluation methods.....</i>	<i>14</i>
3.3.2	<i>Vertical dimension analysis .....</i>	<i>14</i>
3.3.2.1	Skeletal vertical dimension.....	14
3.3.2.2	Dental vertical dimension.....	15
3.3.2.3	Occlusal vertical dimension (OVD) .....	15
3.3.3	<i>Association with sagittal status.....</i>	<i>16</i>
3.3.3.1	Skeletal relationship.....	16
3.3.3.2	Dental relationship. [Table 4] .....	16
3.3.4	<i>Association between skeletal/dental vertical dimension with DVO .....</i>	<i>16</i>
3.3.4.1	Skeletal and dental vertical dimension relationships.....	17
3.3.4.2	Skeletal vertical dimension and OVD association.....	17
3.3.4.3	Dental vertical dimension and OVD association.....	17
3.4	TREATMENT OPTIONS.....	18
3.4.1	<i>Management of the treatment and place of each therapeutic.....</i>	<i>18</i>
3.4.2	<i>Treatment options and vertical dimension considerations.....</i>	<i>18</i>
3.4.2.1	Treatment options and skeletal vertical dimension [Fig 6] .....	18
3.4.2.2	Treatment options and dental vertical dimension. [Fig 7] .....	19
3.4.2.2.1	Open-bite and OVD decrease.....	19
3.4.2.2.2	Open-bite and normal OVD.....	19
3.4.2.2.3	OVD decrease and no open-bite .....	19
3.4.3	<i>Therapeutics used.....</i>	<i>21</i>
3.4.3.1	Orthodontics and Orthognathic Surgery [Fig 8]. .....	21
3.4.3.1.1	Orthodontic therapy.....	21
3.4.3.1.2	Orthodontic and surgery therapy.....	21
3.4.3.1.3	Surgery only.....	22
3.4.3.2	Periodontology treatment.....	22
3.4.3.2.1	Periodontology prophylaxis .....	23

3.4.3.2.2	Periodontology surgery .....	23
3.4.3.3	Prosthodontic management.....	23
3.4.3.3.1	Prosthodontic plan .....	23
3.4.3.3.2	Restorations materials' [Fig 11].....	24
<b>4</b>	<b>DISCUSSION.....</b>	<b>25</b>
4.1	CASE REPORT SELECTION.....	25
4.2	PATIENT'S CHARACTERISTICS ANALYSIS .....	26
4.2.1	<i>Clinical problems associated with Amelogenesis Imperfecta. ....</i>	<i>26</i>
4.2.2	<i>Skeletal and dental diagnosis of the patients with Amelogenesis Imperfecta.....</i>	<i>26</i>
4.2.3	<i>OVD diagnosis of patients with Amelogenesis Imperfecta. ....</i>	<i>27</i>
4.3	TREATMENTS CONCEPTS OF PATIENTS WITH AMELOGENESIS IMPERFECTA.....	28
4.3.1	<i>Therapeutics used to treat these patients. ....</i>	<i>28</i>
4.3.2	<i>Management of vertical dimension.....</i>	<i>28</i>
4.3.3	<i>Surgical therapy.....</i>	<i>29</i>
4.3.4	<i>Orthodontic therapy .....</i>	<i>31</i>
4.3.5	<i>Periodontal therapy.....</i>	<i>31</i>
4.3.6	<i>Restorative treatment .....</i>	<i>32</i>
<b>5</b>	<b>CONCLUSION .....</b>	<b>35</b>
	<b>BIBLIOGRAPHIC REFERENCES.....</b>	<b>37</b>
	<b>TABLE OF ILLUSTRATIONS.....</b>	<b>40</b>
	<b>ANNEX .....</b>	<b>41</b>
	<b>SERMENT D'HIPPOCRATE MODIFIE ET ACTUALISE POUR LES MEDECINS DENTISTES.....</b>	<b>44</b>



## TABLE OF ABBREVIATIONS

AI : Amelogenesis Imperfecta

AOB : Anterior Open-Bite

OVD : Occlusal Vertical Dimension

VD : Vertical Dimension

Fig : Figure

**Titre :** Gestion pluridisciplinaire du sens vertical squelettique et dentaire des patients atteints d'Amélogénèse Imparfaite isolée.

**Title:** Multidisciplinary management of skeletal and dental vertical dimensions of patients with Amelogenesis Imperfecta isolated type.

**Auteurs :**

HENRY F, SOREL O, BREZULIER D.

Service Orthopédie Dento-Faciale du CHU de Rennes,

2 rue Henri-Le Guilloux, 35033 RENNES

fanny.henry@univ-rennes1.fr

**Résumé :**

Introduction : : L'Amélogénèse Imparfaite est une affection génétique héréditaire rare touchant la structure de l'émail en denture temporaire et permanente et est à l'origine d'anomalies squelettiques et dentaires ayant des conséquences notables sur la dimension verticale des patients atteints. L'objectif du travail est d'analyser les traitements proposés aux patients atteints d'Amélogénèse Imparfaite (AI) isolée, afin d'appréhender les possibilités de gestion du sens vertical de ces cas complexes, en fin de croissance.

Méthode : La revue a été entreprise à partir des bases de données PubMed en juin 2018. Les recherches ont permis de sélectionner seize cas cliniques de patients atteints d'AI dont la prise en charge thérapeutique et le diagnostic du sens vertical squelettique et/ou dentaire étaient décrits.

Résultats : L'analyse diagnostic des articles a révélé une augmentation de la dimension verticale squelettique et/ou dentaire et/ou une diminution de la dimension verticale d'occlusion (DVO).

La prise en charge thérapeutique révèle que 100% des patients présentent une réhabilitation restauratrice complète. En amont, dépendamment du diagnostic et des besoins, les patients ont bénéficié de traitements en chirurgie orthognatique, orthodontie, parodontologie.

Conclusion : Les anomalies du sens vertical d'origine basale ayant pour origine la croissance osseuse de la face sont traitées par chirurgie orthognatique. L'orthodontie permet de gérer l'alignement dentaire et le traitement des malocclusions d'origine alvéolo-dentaires en minimisant les délabrements dentaires. La parodontologie permet d'aménager, par soustraction, l'espace prothétique nécessaire. La réhabilitation restauratrice permet d'augmenter la DVO, de protéger les substances dentaires et de satisfaire les doléances esthétiques. Les restaurations indirectes répondent avec succès à ces exigences. Les restaurations minimalement invasives sont de plus en plus considérées mais leur faisabilité dépendant du type, de l'anomalie et requièrent des résultats supplémentaires en terme de protocole clinique et de longévité. Un diagnostic approfondi orientant une prise en charge pluridisciplinaire et coordonnée entre les spécialistes permettra de répondre avec succès au traitement de ces patients adultes atteints d'Amélogénèse Imparfaite.

Termes meSH : Amelogenesis Imperfecta, Vertical dimension, Malocclusion.

Mots clés : Amelogenesis Imperfecta, Vertical dimension, Malocclusion, multidisciplinary treatment, Management, Literature review.

**Abstract**

Introduction : Amelogenesis Imperfecta (AI) is a genetic disorder that causes defective enamel development in both primary and permanent dentition and result in skeletal and dental disharmony affecting the patient's vertical

dimension. The objective of this work is to draw an analysis of Amelogenesis Imperfecta patients' treatment management of the dento-skeletal vertical dimension and provide recommendations for managing the care of these patients at the end of the growth.

**Methods :** The review was undertaken from the PubMed databases in June 2018. Research allows to identify from the sixteen case report selection the different treatment of these patients, according to their skeletal and dental vertical diagnosis.

**Results :** The exploration of case reports shows a skeletal and/ or dental vertical dimension was increased with an anterior open-bite, and/ or an occlusal vertical dimension (OVD) decrease.

Concerning the treatment approach, all the patients had a full-mouth restorative rehabilitation at the final stage of the treatment. Depending on the diagnosis and the needed, patients benefited from surgery, orthodontic, periodontology treatments before the rehabilitation.

**Conclusion :** With a multidisciplinary approach it is possible to treat the skeletal and dental anomalies beforehand, to restore the occlusal vertical dimension.

Orthognathic surgery is recommended if the abnormalities of vertical dimension derive from a skeletal component which could not be compensated for. Orthodontic therapy is used to align teeth, to treat dental malocclusions. To minimize tooth wear before entering the restorative phase, the patient's teeth should be in the ideal position consequent to orthodontics treatment. Periodontology with crown lengthening will manage the prosthetic space. Subsequently, a restorative reconstruction is indicated for all patients suffering from AI to avoid loss of OVD, to prevent further destruction of the teeth and to restore esthetics. Indirect prosthodontic have successfully met those requirements. Recently, adhesive treatments with minimally invasive techniques represent an interesting option for AI patients. However, for definitive restorations its long term survival depends on protocols and type of AI surface. An analysis of the cumulated evidence on outcomes of alternative restoration techniques is critically needed.

# 1 Introduction

Amelogenesis imperfecta (AI) is not a common dental condition, as shown by its prevalence which ranges from 1 in 700 up to 1 in 14,000 cases. (1-2) Amelogenesis imperfecta is a clinically and genetically heterogeneous group of hereditary disorders primarily affecting enamel formation. Depending on the extent of ameloblasts, different types of AI are described : hypoplastic, hypomaturation, hypocalcified or hypomaturation-hypoplastic. It can be noticed that these types sometimes coexist in the same patient and even on the same tooth.

According to the international classification proposed by Wiktop in 1988 (3), four major types were recognized based on phenotype. The different types are defined as follows :

- Hypoplastic: enamel is reduced in term of quantity and does not reach its normal thickness but is relatively well-mineralized.
- Hypomaturation : mineralization processes of the final stages are abnormal. Enamel thickness is normal but hardness is described as being decreased. Tooth shades range from a mottled opaque white to a yellow-brown or even a red-brown color, and tend to chip away from the underlying dentine.
- Hypocalcified : enamel is in relatively normal amounts but poorly mineralized. Enamel thickness on newly erupted teeth closely approaches that of normal teeth, but it is softer and friable and can easily be removed from the dentine.
- Hypomaturation–Hypoplastic : Enamel hypoplasia combined with hypomaturation. Taurodontism is the main feature.

All related fields to Amelogenesis Imperfecta have been extensively analyzed, such as etiology and clinical management.

Clinical problems associated with AI include poor aesthetics, dental hypersensitivity, loss of vertical dimension and poor occlusal function. Factors that adversely influence oral health and prosthetic treatment prognosis are poor oral hygiene and mouth breathing associated gingivitis and gingival hyperplasia. (4)

Amelogenesis Imperfecta, whatever its form, is most often associated with disorders of maxillofacial growth. More than 50% of patients with AI and occlusal abnormalities also suffer from vertical problems, such as hyperdivergency and/or anterior open bites. Other cases involve deep bites that can be caused by dental tissue breakdown. The causes of these growth abnormalities are still unknown; however, they may be related to local and / or genetic factors. (5)

Defects on the teeth are prone to heavy calculus formation that may eventually cover the teeth and cause gingival inflammation. These conditions make dental reconstructions delicate and unreliable, particularly for full-coverage restorations. Therefore, it is critical to achieve optimal gingival health before restorations. (6)

Previous studies demonstrated that AI is associated with discernable psychosocial effects. As these effects have a considerably negative impact on the patient's overall health, it is suggested that dental treatment for AI could be medically justified. (7)

Due to its complexity, AI may require an interdisciplinary approach for diagnosis as well as for clinical management, including orthodontic, periodontology and prosthodontics.

Only by this means could the results be optimal, in terms of esthetic, structural, and functional issues.

One of the biggest challenges with this clinical situation, aside from managing the AI itself, is addressing the anterior open bite and the significant posterior tooth wear.

To date, levels of evidence regarding the different therapies are very limited. (8) The majority of publications related to the clinical management of these cases are limited to simple case reports. (9-10)

The aim of this study is to analyze the management of dento-skeletal vertical dimension in AI patients through a selection of case reports from the current literature. Secondly, this study attempts to reach a consensus for the management of these patients.

## 2 Methods

A systematic review of the literature was performed on the Medline database in order to identify the case reports dealing with the diagnosis and treatment of amelogenesis imperfecta cases published from January 1995 to June 2018. The electronic research strategy was based on the association of the Medical Subject Heading (MeSH) terms: "Amelogenesis Imperfecta" [Mesh], "Malocclusion"[Mesh] and "Vertical Dimension" [Mesh]. [Table 1]

### 2.1 Selection criteria applied for the review, inclusion criteria

The inclusion criteria were :

- Case report articles
- Articles about treatment of patients with an isolated form of Amelogenesis Imperfecta
- Definitive treatment
- Patient over 14 years old
- Articles with a description of the patient's diagnosis
- Publication after 1994
- Publication in French or English

### 2.2 Exclusion criteria

Exclusion criteria were :

- Patient's age not mentioned or younger than 14 years old
- Articles which are not cases reports
- Cases without diagnosis and/or dental and/or skeletal pre-treatment analysis.
- Transitional rehabilitation case reports
- Amelogenesis Imperfecta syndromic cases
- Case reports about genetic analysis

### 2.3 Search strategy

Since the literature on a such broad subjects would be abundant, the review focused on selected combinations of the three search terms: "Amelogenesis Imperfecta" AND "Vertical Dimension" [Mesh] and "Amelogenesis Imperfecta" AND "Malocclusion "[Mesh].

## 2.4 Data extraction and management

The articles were extracted by two reviewers independently, using a pre-established checklist described below for data extraction.

We focused our research on patients with an isolated form of AI i.e. non-syndromic cases.

As our study deals with the management of AI with an anomaly of the vertical direction, it is necessary to retain only articles specifying the diagnosis of the case, both dental and skeletal. Case reports which were not specific enough on the diagnosis description were rejected.

Regarding the diagnosis, only the data from the article was retained. The lack of reproducibility of certain documents through studies (photographs, radiography) does not allow reinterpretation specific to each study.

Search terms	Citation	Case report
« Amelogenesis Imperfecta »[Mesh]	816	313
« Malocclusion »[Mesh]	31914	7059
« Vertical Dimension »[Mesh]	5270	899
« Amelogenesis Imperfecta »[Mesh] AND « Malocclusion »[Mesh]	65	43
« Amelogenesis Imperfecta »[Mesh] AND « Vertical Dimension »[Mesh]	22	17

*Table 1: Numbers of titles listed in Pubmed (June 2018) for various combinations of the research terms.*

## 3 Results

### 3.1 Inclusion of studies

Our electronic research identified 65 articles for the terms « Amelogenesis Imperfecta »[Mesh] AND « Malocclusion » [Mesh] and 22 articles for « Amelogenesis Imperfecta »[Mesh] AND « Vertical Dimension »[Mesh].

Initially, articles other than case reports were eliminated and we obtained, respectively, 43 and 17 case reports. [Table: 1].

Secondly, considering the exclusion criteria, case reports were selected according to the diagram of article selection below (Fig. 1).

Considering the association « Amelogenesis Imperfecta »[Mesh] AND « Malocclusion »[Mesh]: 6 case reports were excluded according to exclusion criteria: 5 papers because of the date of the publication (<1994) and 1 paper as it was written in Hungarian.

For the association « Amelogenesis Imperfecta »[Mesh] AND « Vertical Dimension »[Mesh]: 1 article written in Polish was excluded.

After elimination of duplicates, 48 articles were obtained.

After reading titles and abstracts, 32 articles were rejected for various reasons as mentioned in the exclusion criteria [Table 2]. First of all, 18 articles were excluded after title or abstract reading and secondly, after reading

critical articles : 14 case reports were eliminated because of a general disease association or an age less than 14 years old, or a non-specific diagnosis described, or because of the treatment plan (provisional restoration or no description).

Finally, 16 articles were selected for the literature review.

All the studies were case reports each describing one patient.

Articles	Cause of rejection			
	Age <14 years	Systemic syndrom associated	not specific description of the diagnosis or the treatment	treatment plan ( transitional treatment or no description )
Zimmermann M, 2016	treatment of an 8-year-old patient			
Saeidi, 2015			no diagnosis and analysis before the rehabilitation.	
Béchor N, 2014	12-Year-old girl			
Ashkenazi M, 2014		Nephrocalcinosis associated		
O'Connell S, 2014	7 year-old	associated dental follicular hamartomas		
Millet, Duprez, 2013	10 year-old			
Kala Vani SV, 2012		Enamel renal syndrome		
Nibali L, 2012		Hereditary gingival hyperplasia associated		
Finkelstein T, 2012	12 year old			
Oliveira et al. 2011		leukoderma syndrom association		
Arnetz GV, 2011	8-year-old boy			
Lee KE, 2011				no treatment plan, off-topic
Kinzer 2010	age not mentioned,		no diagnosis of the patient	
Lindemeyer RG, 2010				focus on genotype-phenotype correlations, off-topic
Al-Salehi SK, 2009				Treatment and rehabilitation at 22 years because of mandibular fracture
Assunção 2009		malnutrition and frequent antibiotics during childhood, systemic syndrome because of consanguinity marriage		
Sabatini, 2009				Transitional treatment, not completely skeletal growth.
Sadighpour et al., 2009		Thyroid hyperfunction		
Zarati S, 2009				transitional restauration in a young patient
Akin, 2007			the diagnosis and analysis of the patient are not described	
Siadat, 2007			the diagnosis of the patient is not described	
Suda N, 2006		cleft lip and palate and polycystic kidney disease		
Ozturk N, 2004			the diagnosis of the patient is not described	
Toksavul S, 2004			the diagnosis of the patient is not described	
Luzzi et al., 2003	9-year-old female			
yip HK, 2003			the diagnosis of the patient is not described	
N. de la Tranchade I, 2003		Systemic problem: Nephrocalcinosis		
Bouvier et al., 1999	7-year-old			
Hunter and Stone, 1997	9-year-old			
Bundzman ER, 1999		case of a family with hypomaturation X-linked AI discussion of the clinical and histopathological aspects of this disorder.		
Rosenblum SH, 1999	13-year-old			
Holroyd I, 1995				genetic analysis of a unique family record, off-topic

Table 2: Rejected articles and cause of rejection.

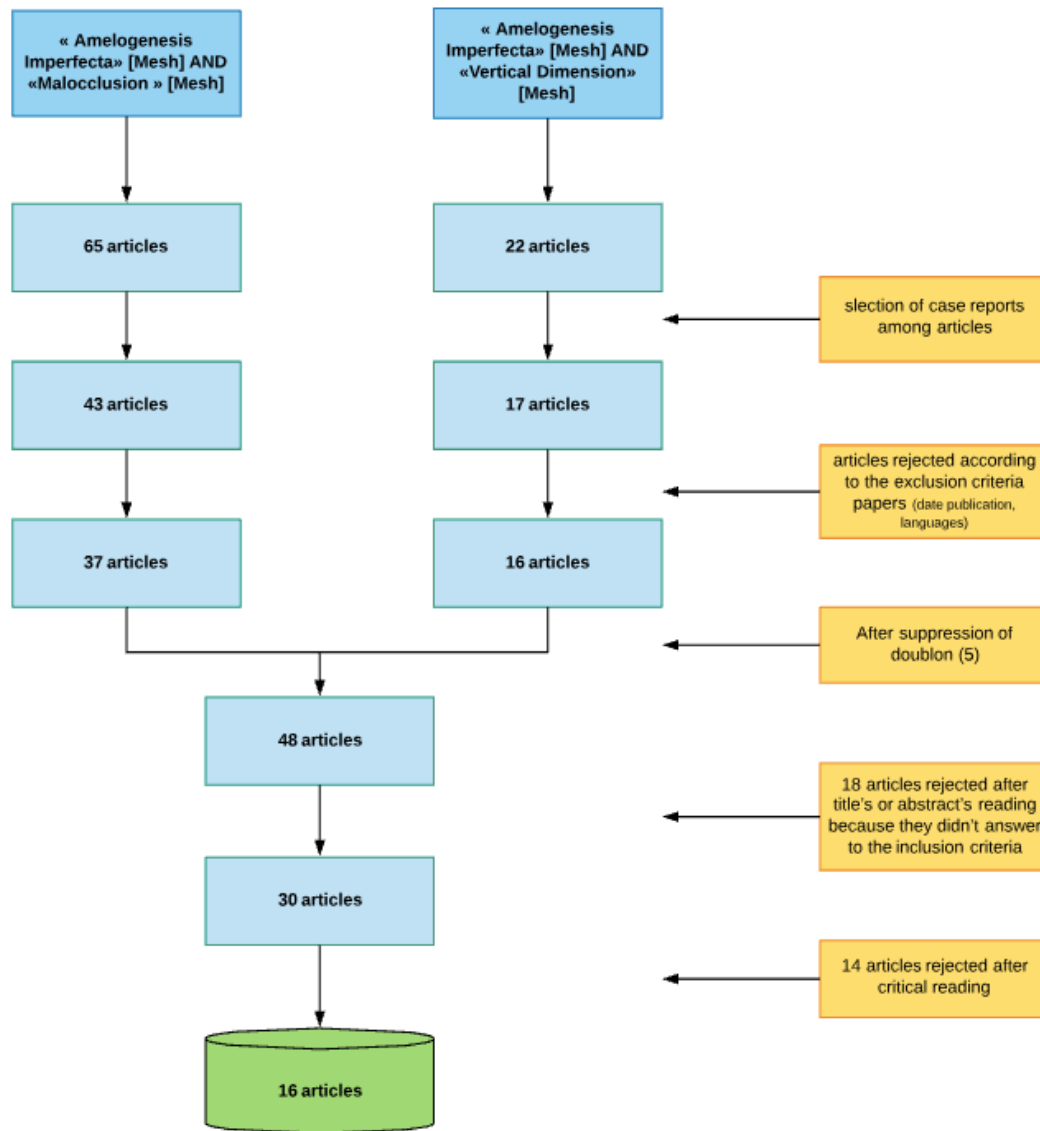


Figure 1 : Diagram of selection of the articles.

### 3.2 Patient's general characteristics [Table 7, cf Annex]

Sixteen patients aged from 14 to 45 were described, 6 males and 10 females. All patients were in the permanent dentition.

Regarding the type of Amelogenesis Imperfecta : 10 cases of hypoplastic type were described (63%), 2 hypocalcified and 2 hypomaturation. One paper presented an association of hypocalcified-hypoplastic types. Also, for one case the type of Amelogenesis Imperfecta was not specified.

Patients' oral characteristics included isolated dental sensitivity for 7 cases, periodontal diseases for 5 cases, and caries for 7 cases. Microdontia was described for 5 cases. Functional problems, such as difficulty chewing or sensitivity associated with loss of tooth structures, were present in 7 cases. There were 6 cases of non-erupted teeth due to impaction or agenesis. Ten patients benefited from dental treatment during childhood. Among these patients are described : amalgam restorations ; composite restorations ; steel crowns on molars. All the patients suffered from loss of tooth structure and discoloration problems. [Fig 2]



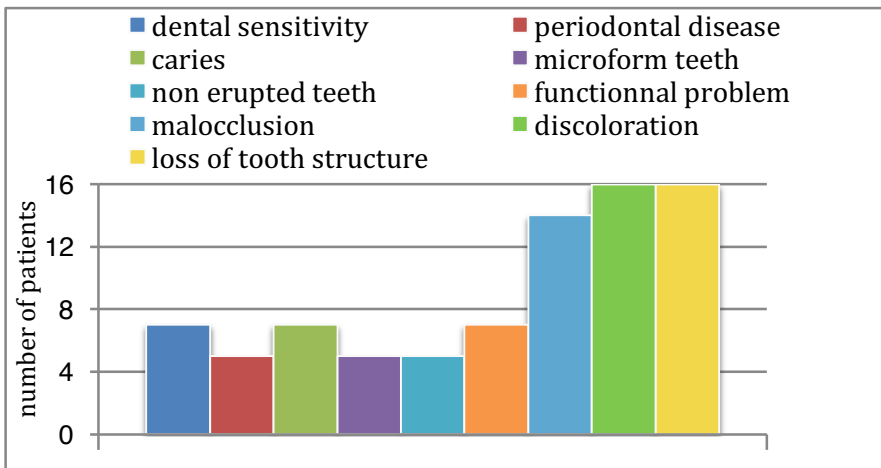


Figure 2 : General characteristics of patients included in the selected articles.

### 3.3 Malocclusion characteristics. [Table 8, see Annex]

#### 3.3.1 General consideration and evaluation methods

The diagnosis of the vertical dimension was specified either by cephalometric analysis (9 cases) or based on interocclusal space (6 cases). The interocclusal space was determined by phonetic test, or observed on a wax-up, or clinically with esthetic methods (measurement of the lower part of the face between the nasal point and the lower limit of the chin). Also, a single case report used both methods.

Fourteen patients had abnormalities of either the skeletal or dental vertical dimension. Two case reports described patients without issues i.e. dental and skeletal class 1 with no open-bite (11, 13).

#### 3.3.2 Vertical dimension analysis

Vertical dimension (VD) can be defined as the distance between any two points measured in the maxilla and the mandible when the teeth are in maximum intercuspation.

The etiology of vertical dimension problems is complex and multifactorial, and may be attributable to a combination of genetic and environmental factors.

While the association of dental/skeletal open bite malocclusions with AI have been described in several previous studies (4), the complex relationship between these features remains poorly defined and the mechanisms responsible for this association unknown. (34)

##### 3.3.2.1 Skeletal vertical dimension

Cases selected here show ten patients with an increase of skeletal vertical dimension, two with a decrease of the skeletal vertical dimension, and one presenting no abnormalities of the vertical skeletal characteristics. Three articles do not mention the skeletal diagnosis because of the absence of cephalometric evaluation (13, 20, 21). [Fig 3]

Skeletal characteristics associated with increase of the vertical dimension include increased anterior face height (long lower face), steep mandibular plane, maxillary constriction and high mandibular angle.

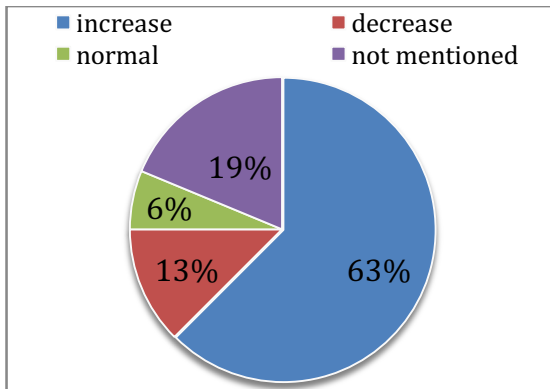


Figure 3: Skeletal vertical dimension.

### 3.3.2.2 Dental vertical dimension

With regard to dento-alveolar level, the cases treated in the selected articles show that 13 patients have an open-bite.

Dental open-bite was defined as open vertical dimension between the incisal edges of the maxillary and mandibular anterior teeth [36]. Anterior open-bite (AOB) is the open occlusal relationship of anterior teeth.

There are no patients among the case report selection who suffer from Amelogenesis Imperfecta and have a deepbite. [Fig 4]

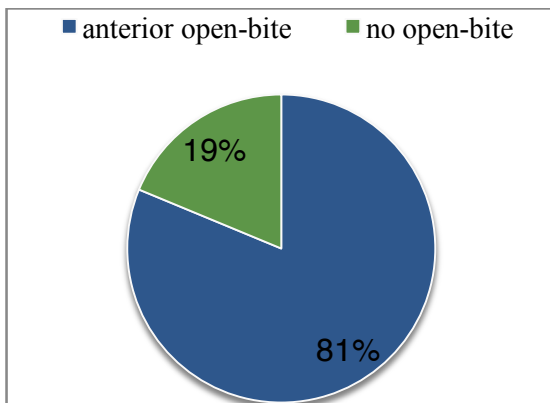


Figure 4: Patients with Amelogenesis Imperfecta and open-bite.

### 3.3.2.3 Occlusal vertical dimension (OVD)

A consequence of the loss/lack of enamel in Amelogenesis Imperfecta is the loss of the vertical dimension, and functional problems like decreased masticatory efficiency.

Attrition, reduction of the crown size, microform teeth, and significant tooth structure damage often result in occlusal disharmony affecting the patient's occlusal vertical dimension (OVD) but this data is independent of skeletal and dento-alveolar levels.

The OVD is defined as the distance between two selected anatomic points when the mandibular teeth are occluding with the maxillary teeth.

Amelogenesis imperfecta is often complicated by a reduced dental occlusal vertical dimension (OVD), diagnosed by an increased interocclusal space due to the loss of tooth structure.

12 patients present a loss of OVD.

### 3.3.3 Association with sagittal status.

#### 3.3.3.1 Skeletal relationship.

Among the ten patients with an increased skeletal vertical dimension, half of them were in skeletal class III.

According to the data reported in [Table 3] increase of vertical dimension can be found in all skeletal class malocclusions.

Among the patients with a decrease of vertical dimension, one had a skeletal class III and a retrognathic and edentulous maxilla, and an anterior open-bite (23), and one had a class I skeletal base (11). Only one of the cases reported that the skeletal vertical dimension was normal. (31)

	Increase skeletal VD	decrease skeletal VD	normal
Skeletal class 1	1	1	1
skeletal class 2	2	0	0
Skeletal class 3	5	1	0
not mentioned	2	0	0
	10	2	1

Table 3: Skeletal Characteristics and malocclusions.

#### 3.3.3.2 Dental relationship. [Table 4]

Among dental anterior open-bite patients, six patients were in dental class I, one presented a class II, and 2 patients were in dental class III. It should be noted that in four cases the dental classification of occlusion was unknown.

Three patients had no anterior open-bite. They were all in dental class 1 and they had a loss of OVD because of reduced height of the posterior crowns, loss of enamel and tooth structures.

Twelve patients presented a loss of OVD. Among them, 7 patients were in dental class I and one of them was in dental class III.

Only 4 patients had no abnormalities of the OVD.

	anterior open-bite	no anterior open-bite	decrease OVD	OVD maintain	anterior open-bite + decrease OVD
Dental class 1	6	3 (Sengun: edge to edge )	7	2	4
dental class 1 and class 2 (each different side)	1	0	1	0	1
Dental class 2	0	0	0	0	0
Dental class 3	2	0	1	1	1
not mentioned	4	0	3	1	3
	13	3	12	4	9

Table 4: Dental vertical anomalies and malocclusions.

### 3.3.4 Association between skeletal/dental vertical dimension with DVO

According to the data in [Table 5], there appear to be the two anomalies of the vertical dimension in Amelogenesis patients.

#### 3.3.4.1 Skeletal and dental vertical dimension relationships.

Among the 16 patients included in the case report selection, 9 patients presented a skeletal and a dental (i.e. AOB) increase of the vertical dimension.

Among the 10 patients with a skeletal vertical dimension increase, 9 of them had an increase of the dental anterior vertical dimension (AOB).

#### 3.3.4.2 Skeletal vertical dimension and OVD association.

We can observe that 6 patients with an increase skeletal vertical dimension had an OVD decrease.

The 2 patients with a decreased skeletal vertical dimension also had an OVD decrease.

#### 3.3.4.3 Dental vertical dimension and OVD association.

Nine patients (56%) presented both an anterior open-bite and a decrease of the OVD. [Table 4]

Four patients had an anterior open-bite and OVD maintained, and only one patient had no anterior open-bite but with a loss of OVD.

All the four patients with OVD maintained were treated with conservative treatment during childhood (rehabilitation of teeth during childhood consisted of restoration by composite resin ; metal crowns were placed to conserve dental tissues).

Finally, among the ten patients with a skeletal vertical dimension increase, nine of them had an increase of the dental anterior vertical dimension (AOB), with 55% of them an OVD decreased association.

		SKELETAL Vertical dimension		
		Increase	decrease	normal
DENTAL vertical dimension	Open-bite + OVD decrease	5	1	1
	Open-bite + normal OVD	4		
	No open-bite + OVD decrease	1	1	

Table 5 : Association between skeletal and dental vertical dimension with DVO.

### 3.4 Treatment options

#### 3.4.1 Management of the treatment and place of each therapeutic.

First, it is important to note that 100% of these cases had not received any treatment related to their malocclusion and vertical dimension anomalies during childhood and before the definitive treatment management but just restorations of tooth decay and loss of enamel with amalgam, composite or steel crowns.

Most of the cases were treated by definitive rehabilitation with a multidisciplinary treatment : only one patient among the 16 had prosthetic rehabilitation only. (13)

38% of patients had a combination of periodontology and prosthetic treatments.

It was observed that the periodontal surgery was often used in combination with prosthetic rehabilitation (without surgery and orthodontic treatment) to correct the OVD with a crown lengthening therapy.

Only one case was treated by surgery and prosthetic treatment only (because of an edentulous maxilla and rehabilitation by implants).

19% of patients were treated by orthodontic therapy before the prosthetic rehabilitation, and 38% of patients with orthognathic surgery. [Fig 5]

In some cases the possibility of orthodontic and/or surgical treatment was considered but excluded because of patient time constraints, disinterest, or financial difficulties. (20, 21, 33)

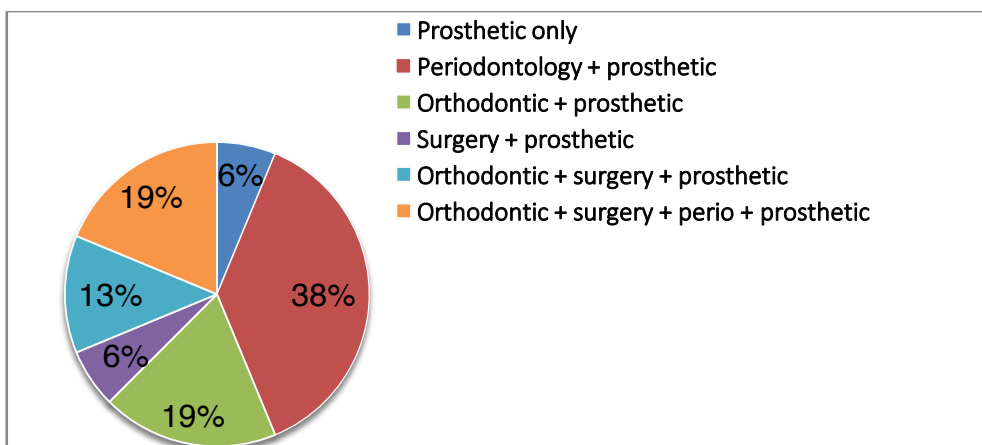


Figure 5: For the interdisciplinary treatment options, steps of treatment and type of each therapeutic intervention.

#### 3.4.2 Treatment options and vertical dimension considerations

##### 3.4.2.1 Treatment options and skeletal vertical dimension [Fig 6]

First, a prosthetic rehabilitation was always conducted for each patient treated in this case report selection. Among the ten patients with an increase of the skeletal vertical dimension, it was noted that 100% of them had a prosthetic rehabilitation. 57 % of the patients were treated before the prosthetic rehabilitation with orthognathic surgery or/and orthodontic therapy. 20% of patients had only orthodontic therapy before the prosthetic rehabilitation and 60% of the patients had periodontal treatment before the final prosthetic rehabilitation.

Regarding the 2 patients with a decrease of the skeletal vertical dimension, we can note that one of them (maxillary edentulous) was treated with surgery and prosthetic rehabilitation with implants (23), and the other was treated

by a prosthetic treatment after a periodontal prophylaxis (11) to restore the vertical dimension. For this patient, despite the decrease of skeletal vertical dimension, no surgery was proposed because this patient was a dental and skeletal class 1, and just presented with an OVD decrease impacting on the facial height.

One patient had no skeletal vertical dimension anomalies and their treatment was based on periodontology and prosthetic rehabilitation (31).

For the 3 patients with no diagnosis of the skeletal vertical dimension, the treatment plan was conducted by periodontology and prosthetic rehabilitation.

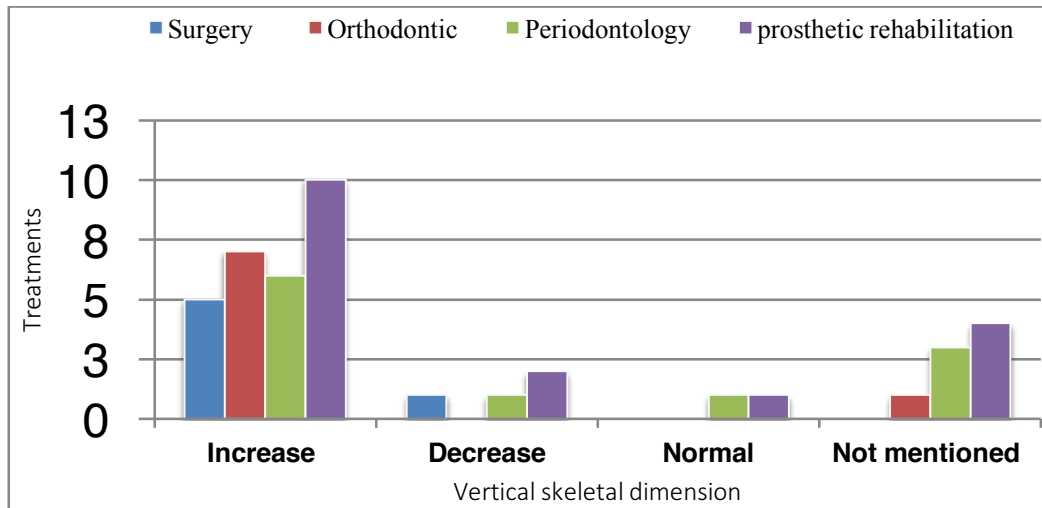


Figure 6: Treatment options and skeletal vertical dimension.

#### 3.4.2.2 Treatment options and dental vertical dimension. [Fig 7]

In [Figure 7] comparisons are drawn between patients with open-bite and an OVD decrease or increase.

##### 3.4.2.2.1 Open-bite and OVD decrease

In this study, nine patients had both an open-bite and an OVD decrease. Among them, for five patients the diagnosis mentioned an associated increase of skeletal vertical dimension. Only two of them were treated with surgery, orthodontic, periodontology and prosthetic rehabilitation, one with only orthodontic therapy before prosthetic rehabilitation to normalize the anterior and lateral open-bite (30), and for the 2 others the occlusal vertical dimension was treated with periodontal surgery (crown lengthening) and prosthetic rehabilitation.

##### 3.4.2.2.2 Open-bite and normal OVD

The four patients with an anterior open-bite and a normal OVD had a increased skeletal vertical dimension [Table 6]. Three of them had surgery and orthodontic therapy before the prosthetic rehabilitation to correct the skeletal and dental vertical anomaly, and the other one had orthodontic therapy with teeth extractions before the prosthetic rehabilitation (25).

Among the patients treated with orthognathic surgery, one of them presented a loss of OVD (27) which was corrected during the prosthetic rehabilitation.

##### 3.4.2.2.3 OVD decrease and no open-bite

Regarding the dental vertical dimension anomalies, we can note that patients with no dental open-bite are not treated with surgery (only 3 patients out of 16). These 3 patients without an open-bite had an OVD decrease. One

case among the 3 patients was treated with orthodontics before the prosthetic rehabilitation because the diagnosis indicated posterior cross bite and non-alignment of the teeth. Moreover the patient refused the surgical treatment and so the maxillary expansion was carried with a Hyrax screw appliance (28). The two other patients were treated only with prosthodontic rehabilitation (and periodontal therapy) to restore the OVD.

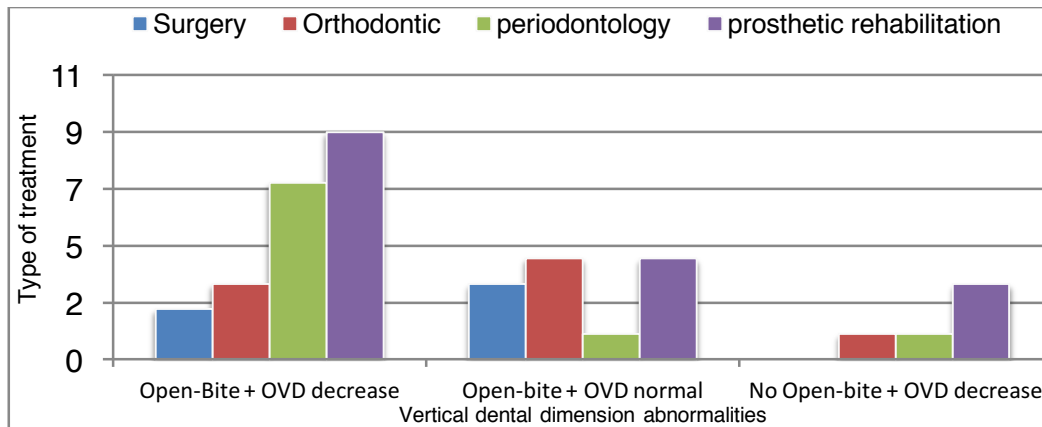


Figure 7: Treatment options and dental vertical dimension.

Regardless of the treatment modality, OVD is an important consideration for the treatment planning.

In this review, 13 cases were treated by modifying the vertical dimension value [Fig 10].

The increase of occlusal vertical dimension (OVD) was noted in 12 cases (11 cases with prosthetic rehabilitation and periodontology surgery and 1 case with orthodontics). [Table 6].

The decrease of skeletal vertical dimension was achieved by surgical treatment in 4 cases. One of the patients had both surgery to decrease the skeletal vertical dimension and a prosthetic rehabilitation to increase the OVD.

We can note that of the other 3 patients treated for hyperdivergence by surgery, all presented with an anterior open-bite but had no modification of their OVD in the prosthetic rehabilitation.

The value of the OVD variation was not mentioned in most cases. Yet it is important to specify this value and to distinguish the changes in the posterior and anterior levels. We note that this evaluation was neglected in most cases except one (31) in which the conditions and protocol of OVD increase were detailed.

	Surgery	Orthodontics	Periodontology	Prosthodontics
<b>Decrease of skeletal or dental vertical dimension</b>	4	1		
<b>Increase of skeletal or dental vertical dimension</b>	1			
<b>Increase of OVD</b>		1 (posterior)	5	11

Table 6 :Which treatments improve the vertical dimension and how.

### 3.4.3 Therapeutics used

#### 3.4.3.1 Orthodontics and Orthognathic Surgery [Fig 8].

In the cases treated in this review, the first therapeutic consideration was whether the correction should be at the dental level alone or extended to the skeletal level. A combined orthodontic-surgical approach was often ruled out from the beginning at the express wish of the patient, who was informed of both the skeletal/facial benefits and the special difficulties of orthognathic surgery in cases of AI. This approach would have corrected the vertical and sagittal skeletal relationships, but an orthodontic camouflage approach could be adopted if the patient refused surgery. In cases of dental level correction and minor vertical anomalies, orthodontic treatment alone was used to improve the occlusion before the prosthetic rehabilitation.

##### 3.4.3.1.1 Orthodontic therapy.

Four cases were treated with orthodontic treatment.

This treatment is often a compromise because some patients refuse surgical orthognathic treatment.

In the case of congenitally missing teeth, the treatment options are the same as for a hypodontia case and can largely be categorised into total space closure obviating the need for prosthetic replacement, or space opening and redistribution of space with subsequent restorations (30).

For mild open-bite or refused surgical treatment cases, anchorage and fixed appliances could also play a role, or could be a compromise in some cases (25).

In a specific case of skeletal III, dental class I, the orthodontic treatment plan involved the extraction of two maxillary and two mandibular premolars, which would allow alignment of the dental arches, retraction of the anterior teeth, and improvement of the inter-incisal angle while maintaining the Class I molar and canine relationships. Sectional spring was used to retract the first premolars and then the canines, using a palatal bar as anchorage, and a multibracket appliance were used to complete the treatment (30).

The role of fixed appliances can be a good option for cases with mild open-bite and non-alignment of the teeth (21).

Orthodontic treatment is often used to correct misalignment, reopening the space for the maxillary lateral incisors. Bonded and acrylic retainers are often used to maintain the space for the missing teeth after orthodontic treatment. [Table 10, annex]

Moreover, orthodontic treatment is necessary in cases undergoing orthognathic surgery.

##### 3.4.3.1.2 Orthodontic and surgery therapy.

Among the case selection, the multidisciplinary treatment with orthognathic surgery included four steps [Table 9, Annex] :

1- Orthodontic correction of tooth positions ; levelling and aligning with fixed appliances. The pre-surgical orthodontic treatment aimed to correct the transverse relation with rapid maxillary expansion (59, 64), or just with routine orthodontic fixed appliance mechanics (27). Alternatively, a three-piece Le Fort 1 osteotomy could be used during the surgery to correct a transverse skeletal discrepancy.

The presurgical period was completed in 14 months (24, 26); 16 months (29).



2- A one piece or three-piece osteotomy in the upper jaw combined with a genioplasty to adjust sagittal, vertical, and transverse dimensions (27), or bimaxillary surgery with posterior impaction and anterior advancement (three-piece osteotomy) and a mandibular set-back and counterclockwise rotation. (24, 26, 29)

3- Postsurgical orthodontic refinement ; 5 months (26, 27)

4- A prosthodontic rehabilitation to stabilize the achieved results, 6 months after treatment (26), or 12 months after treatment (29).

In most of cases, a non-solid interdigitation was achieved because of the flat occlusal relief, and tooth spacing remained to be corrected by prosthodontic procedures. Final stabilization of the occlusion and articulation with permanent fixed crowns in centric relation was performed after the surgery.

#### 3.4.3.1.3 Surgery only.

For one case of an edentulous patient, orthodontic therapy was not considered before the surgery. In this case, the quality and volume of bone represented additional management challenges. Since the patient would not accept any autogenic bone replacement or any further operations, it was exceedingly difficult to identify a proper and suitable location for a dental implant to support the prosthesis. The correction of the interalveolar relationship between the maxilla and the mandible was achieved with distraction osteogenesis through orthognathic surgery and insertion of dental implants (23).

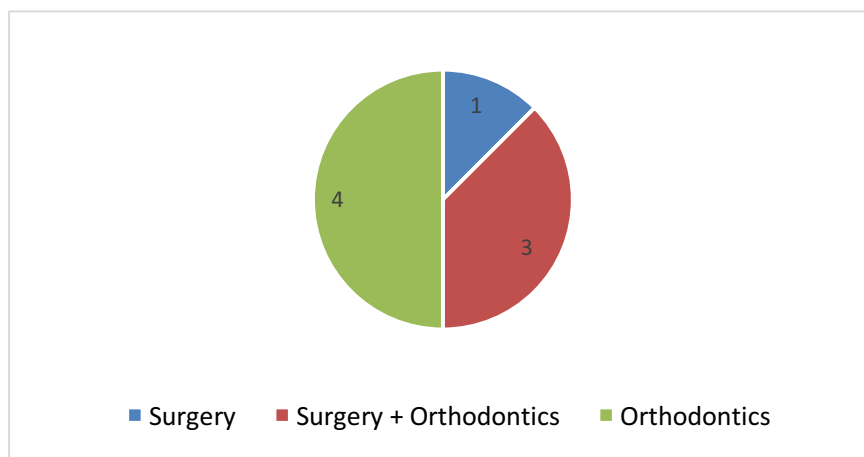


Figure 8: Representation of patients treated by orthodontic or surgery therapy before prosthetic rehabilitation.

#### 3.4.3.2 Periodontology treatment

In this present study, 60% of patients had a periodontology intervention (prophylaxis or surgery) before the prosthetic restoration.

Considering the patients without periodontal care, their periodontal conditions were always evaluated before the definitive rehabilitation. In most cases the gingival conditions were optimal before considering the final restoration. In one case the prophylaxis and prevention therapy were not done at the beginning of the treatment and, because the patient didn't brush well enough, the gingivae were slightly inflamed after the provisional restoration (13).

#### 3.4.3.2.1 Periodontology prophylaxis

In two cases the patients needed motivation to maintain oral health and a scaling to reduce the inflammation of the gingival tissues before prosthetic rehabilitation. [Fig 9]

For 50% of the patients treated by crown lengthening, the presurgical periodontal therapy consisted of oral hygiene instruction, scaling, and root planing. One patient benefited only from a prevention step before the surgery. The patient suffered from a mild localized gingivitis (32). This step was very important to provide healthy gums before the treatment and to maintain this condition. However, two patients benefitted from periodontal surgical treatment without preventive therapy. In the article the diagnosis mentioned that the plaque index was 10% at the first visit and the patient demonstrated a good knowledge of correct oral hygiene. The periodontium was examined and found to be healthy (27, 31).

#### 3.4.3.2.2 Periodontology surgery

Seven patients needed crown height lengthening. [Fig 9]

This was carried out in molar areas or in the full mouth to create a new more apically positioned biologic zone and to increase the crown vertical dimension for prosthodontic restorations. [Fig 10]. In the case of refusal of orthodontic and surgical treatments, periodontal surgical procedures with bone reduction on molars would have been needed for improving the occlusal plane and the anterior open bite.

In addition, periodontal surgery was necessary in one case after orthodontic treatment and during the restorative procedures to treat the gingival recession with a root coverage gingival graft (24).

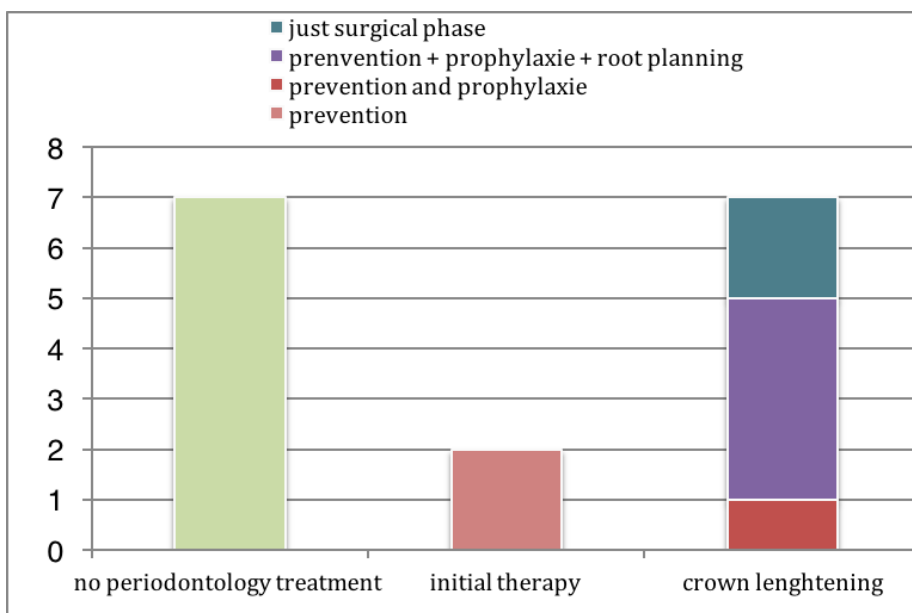


Figure 9: Periodontology treatments.

#### 3.4.3.3 Prosthodontic management

##### 3.4.3.3.1 Prosthodontic plan

In this study, sixteen cases (100%) had a prosthetic rehabilitation which resulted in improved occlusion, better oral health, improved esthetic appearance, preserved tooth structures and reduced tooth sensitivity.

Thirteen cases (80%) were treated with rehabilitation of a new vertical dimension of the occlusion [Fig 10] and among them, for eleven patients this rehabilitation was conducted with prosthodontic therapy. [Table 6]

A wax-up was always used to demonstrate the outcome of the treatment. In some cases, orthodontic and maxillofacial procedures were completed prior to the prosthodontic wax-up, so that a satisfactory occlusal relation could be established. Alternatively, in more complex occlusal conditions the wax-up may have been performed prior to orthognathic surgery (24).

The Periodontal treatment was completed before the provisional phase, based on the treatment needs (prophylaxis, crown lengthening).

As with the the wax-up, the provisional phase was always carried out before the definitive restoration in the case of a new vertical dimension.

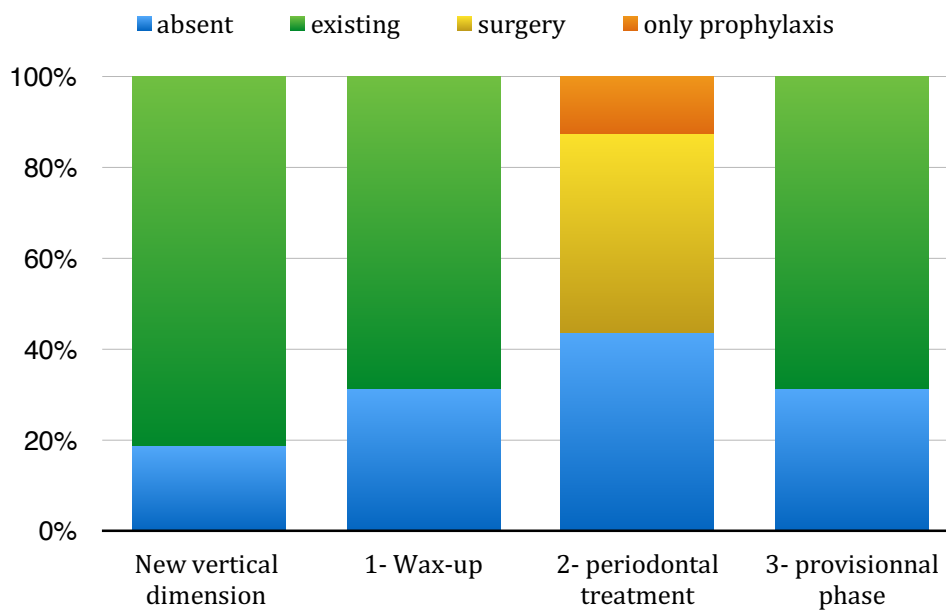


Figure 10: stages of pre-prosthetic preparation according to the new prosthetic vertical dimension.

#### 3.4.3.3.2 Restorations materials' [Fig 11]

Regarding the rehabilitation of AI patients, various treatment modalities have been studied thanks to the advance in techniques and to the increased availability of dental materials.

In the literature, the use of composite resin veneers, porcelain veneers, stainless steel crowns, ceramic and metal-ceramics crowns, and over dentures are described in order to restore function and esthetics.

In this review, six patients had a full-mouth restoration with the same materials (50% with metal-ceramic crowns and 50% with ceramic crowns). In the other cases, different techniques and materials were used for anterior and posterior teeth.

For anterior teeth, in one case, direct composite was applied. In 50% percent of cases, ceramic crowns for anterior restorations were chosen, and for 40% veneers were applied on anterior teeth.

With regard to the rehabilitation of posterior teeth, in one case the restoration was carried out with direct composite. 20% of patients were treated with onlays on posterior teeth only, 40% of cases by metal-ceramic crowns, and all-ceramic and all-metallic crowns were both used for one patient.

It was noted that for a missing tooth, an implant was used to restore the space.

For the edentulous patient, implants were used to rehabilitate the maxillary arch and because of the lack of bone it was decided to connect a removable prosthesis (23).

A removable prosthesis was also indicated to treat the patient with multiple impacted teeth in the mandibular arch (22). For this patient, the impacted teeth occupied maximum basal bone both in the maxilla and mandible. The removal of these teeth to allow for implant therapy was considered inappropriate because of the risk of weakening the jaw bone. Therefore, a complete denture was chosen as the most suitable option.

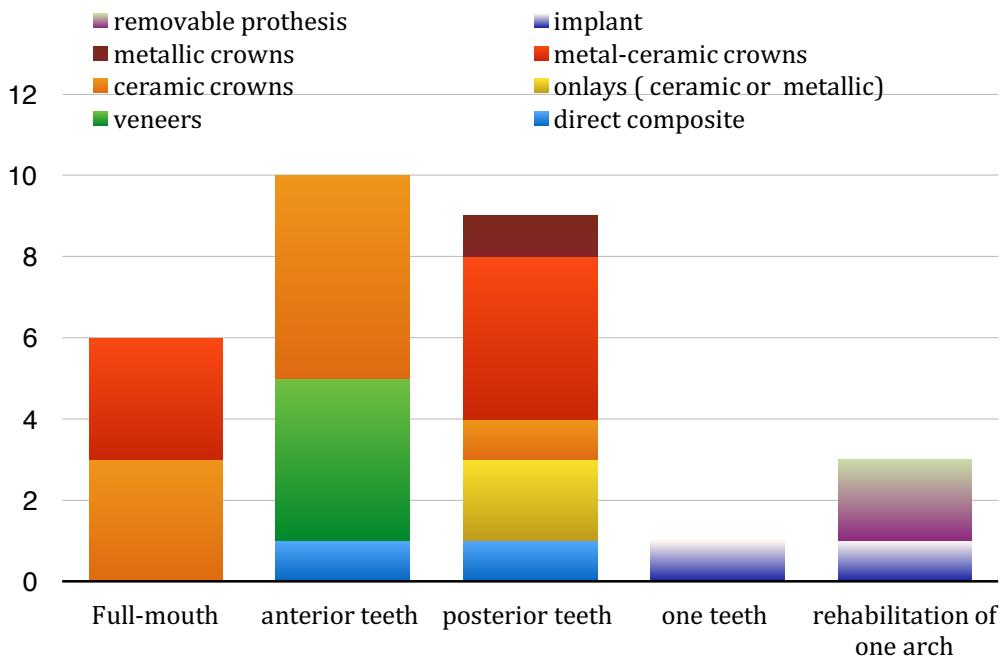


Figure 11:Representation of prosthetic materials used.

## 4 Discussion

### 4.1 Case report selection.

Until now, with regard to the published papers on Pubmed, no systematic review has addressed the problem of the treatment of AI in terms of vertical dimension management.

The exploration of Pubmed with Mesh terms identified 48 articles in this systematic review. Only 16 of these were selected after screening. This relatively low number of case reports could be related to the rarity of the disease, the complexity of treatments, the need for long-term follow-up and the the lack of a proper diagnosis by clinicians. Every selected article in this review was a case report. Although no interventional study was found in the literature, case reports are useful for an evidence-informed approach to the clinical management of rare diseases such as AI. Because our study is about adult treatment interventions, we decided to focus on reported cases for patients older than 14 years: the maxillofacial growth after puberty and the permanent dentition after 14 years of age allows long term treatment planning.

In the fourteen cases selected in this review, 63 % of them were classified as hypoplastic, the most common type of AI described in the literature (2). Hence it is likely to be the most accurately documented type.

Many authors have identified AI as part of a syndrome associated with several types of general diseases. These can affect the development of other organs. In our study, we decided to focus on patients with no general diseases associated with AI. In addition, our literature review is based on the management of AI patients according to their skeletal and dental diagnosis.

## 4.2 Patient's characteristics analysis

### 4.2.1 Clinical problems associated with Amelogenesis Imperfecta.

In this review, the patients' oral characteristics included dental sensitivity, periodontal diseases, dental caries and functional problems such as difficulties in chewing. These can be related to a rough enamel structure and poor oral hygiene caused by brushing sensitivity. In addition, cases of microform teeth and non-erupted (impacted or absent) teeth were also described. 94% of patients presented a malocclusion (skeletal or dental) and all patients suffered from a loss of tooth structure and discoloration problems [Fig 3]. In the case report selection all patients had functional and aesthetic justifications for the treatment. The psychological impact of their unsightly smile played an important in their social life. This demand for aesthetic treatments leads the majority of dentists to focus only on the restorative side of the treatment, without considering orthodontic and surgical management. 50% of patients benefited from at least one dental treatment during childhood (direct restoration, extracted teeth, roots treatment, etc). Unfortunately, the authors of these cases provided no details regarding the procedures employed but they only focus on dental restoration due to loss of enamel or tooth decay but not on the management of the skeletal or dental malocclusion .

The high rate of malocclusion in this case report selection leads us to consider getting a specific diagnosis of these patients to fully understand the possibilities of treatment management as a result.

### 4.2.2 Skeletal and dental diagnosis of the patients with Amelogenesis Imperfecta.

Among the 16 patients included in the case report selection, 9 patients presented with a skeletal and a dental (anterior open-bite) increase of the vertical dimension. [Fig 3]. 63% of patients had an increase of skeletal vertical dimension associated with a sagittal skeletal malocclusion [Table 3]. A Dental open-bite was found in 81% of the patients. [Fig 4]. Half of these were in dental class 1.

The important prevalence of these associated conditions suggests that sagittal and vertical skeletal have to be considered in the treatment plan.

Open bite malocclusions are defined by a lack of vertical overlap of the incisor teeth, failure of posterior teeth to occlude, and/or a craniofacial morphology characterized by an increase in the vertical dimensions of the anterior face.

The prevalence of open bite malocclusion in the general population is 3-7%. Persson and Sundell reported 40% of individuals with AI had an anterior dental open bite (36). In the United Kingdom, 44% of individuals with AI had "vertical dysgnathia" defined as a maxillary to mandibular plane angle greater than 34 based on cephalometric analysis. Of this "vertical dysgnathia" group, approximately half had an dental anterior open bite.

Indeed, through a clinical study, Ravassipour et al. stated that among 54 AI patients, 42% of the affected individuals and 12% of the unaffected family members had dental or skeletal open bite malocclusion when compared to a general Caucasian population (5%). (5)

The etiology of this association has not been clarified. In Hoppenreij's literature review, the authors suggested that the frequent association of AOB and AI is caused by a genetically determined anomaly of craniofacial development, rather than by local factors influencing alveolar growth. The mandibular occlusal plane angle in the AI group was steeper than in the non-AI group (37).

In our study, the results of the prevalence of skeletal and dental malocclusion are higher than in Rowley's (4) study which could be explained by a smaller sample size, the specific criteria for selection of case report and the method of analysis (56% by cephalometric analysis, 38% by interocclusal space and 6% by both techniques).

Clinicians traditionally do not define skeletal open bite using a limited set of clinical criteria but rather rely upon the gestalt of the craniofacial features evaluated clinically and radiographically to arrive at the diagnosis of skeletal open bite. (5)

According to the case selection diagnosis, skeletal characteristics associated with an increase of the vertical dimension include increased anterior face height (long lower face), steep mandibular plane, maxillary constriction and high mandibular angle. Increase of vertical dimension can be found in all different classes of skeletal and dental malocclusions.

#### 4.2.3 OVD diagnosis of patients with Amelogenesis Imperfecta.

Dental characteristics associated with an increase of anterior dento-alveolar vertical dimension included posterior bilateral cross bite, multiple impacted teeth, diastema, microform teeth, an increased overjet of the anterior teeth and a loss of tooth structure leading to a significant loss of the posterior occlusal vertical dimension (OVD).

In this study, 75% of patients presented a decrease of occlusal vertical dimension, usually determined by the evaluation of the freeway space between occlusal surfaces.

While the methods of OVD evaluation vary, some case reports have used several approaches such as the evaluation of interocclusal distance (clinically and/or phonetically) and an aesthetic evaluation, sometimes associated with the cephalometric evaluation. [Fig: 5]. To assess the OVD, none of the proposed techniques have proved to be scientifically superior to others. Therefore, a cephalometric analysis, despite its imperfections, is considered as a reliable method (38).

We suggested that there is no correlation between sagittal skeletal and dental malocclusion and the loss of occlusion vertical dimension, but this diagnostic data should be taken into account in the treatment plan to restore the optimal occlusion. [Table 4]

The study of these 16 articles highlights many effects on the vertical dimension for AI patients. Downward and backward skeletal growth impacted on the skeletal and dental vertical dimension of AI patients. Moreover, due to mechanical tooth abrasion because of the reduced thickness and hardness of the enamel, many patients suffered from OVD loss.

There seems to be no association between open-bite and a decrease in OVD, but each parameter is strongly linked with AI. Due to the skeletal and dental abnormalities in AI patients, it seems to be difficult to manage this specific condition with only a restorative treatment. It seems obvious that AI patients' management will require far greater attention.

Moreover, all 4 patients with an OVD maintained were treated with conservative treatment during childhood (rehabilitation of teeth during childhood: composite resin or metal crowns were placed to conserve dental tissues). There was perhaps no occlusal vertical dimension loss when a tooth protection intervention was carried out during childhood.

We have to consider that AI patients are more prone to accelerated toothwear. Systematically protecting the teeth in order to prevent this loss of dental structures would allow the maintenance of the OVD until the definitive rehabilitation.

### 4.3 Treatments concepts of patients with Amelogenesis Imperfecta.

#### 4.3.1 Therapeutics used to treat these patients.

Dahash et al. stated in 2013 that no randomized controlled studies to survey the outcome of dental treatment in patients with AI were available (8). Thus, the currently accessible evidence regarding the treatment approaches of patients with AI is very limited. In 2015 Lundgren et al. published a split mouth study on the long-term outcome of full-crown restoration in patients with AI using different crown materials (39). Besides this clinical trial, only very few studies comparing different treatment procedures and assessing treatment outcome in subjects with AI have been published, while several other studies only focused on the description of clinical findings or described genetic analyses. The majority of available publications are case reports.

The study of these 16 cases will attempt to show which treatment plans are appropriate to deal with vertical dimension disorders.

The principal treatment aims of improving function and facial/dental aesthetics could be divided into skeletal goals (correcting the class II and III pattern and vertical relationship) and dental goals (correcting the anterior open bite, achieve ideal overbite and over jet), while also considering the impact of Amelogenesis Imperfecta on dental structures in relation to OVD decrease.

Treatment planning for patients with AI is conditioned by many factors such as age, type and the severity of several disorders.

#### 4.3.2 Management of vertical dimension.

Among the ten patients with an increase of the skeletal vertical dimension, 100% of them had a prosthetic rehabilitation. This could be explained by the necessity to protect teeth surfaces from sensitivity, loss of enamel, maintaining masticatory function and restoring aesthetics. 57 % of the patients were treated before the prosthetic rehabilitation with orthognathic surgery or/and orthodontic therapy. 20% had only orthodontic therapy before the prosthetic rehabilitation and 60% of the patients had periodontal treatment before the final prosthetic rehabilitation. [Fig 5] In AI patients there was a need to provide sufficient interocclusal space and crown height for the definitive restorations. This could be achieved with orthognathic surgery in the case of skeletal vertical dimension anomalies which impacted facial height after skeletal growth was complete.

For one patient, despite the decrease of skeletal vertical dimension, no surgery was proposed because this patient was a dental and skeletal class I and presented only with an OVD decrease, impacting on the facial height. It was proposed that this solution be adopted to treat patients with a mild decrease of facial height and no other anomalies. In fact, the patient's occlusal vertical dimension was increased with the use of prosthodontics, as the crown height of the anterior teeth needed to be lengthened to enhance aesthetics.

Regardless of the treatment modality, OVD is an important consideration in the treatment planning. An increase of the occlusal vertical dimension (OVD) effected by the treatment was noted. [Table 6].

Patients with no dental open-bite have a decreased OVD and were not treated with surgery (only 3 patients out of 16). [Fig 7] One of them was treated with orthodontics before the prosthetic rehabilitation because the diagnosis indicated posterior cross bite and non-alignment of the teeth (28). The two other patients were treated only with a prosthodontic rehabilitation to restore the OVD. According to these results we could suggest that the best approach to manage the OVD when there is no hyperdivergence of dental open-bite is to increase the OVD with a

prosthetic rehabilitation. However, the limited number of cases does not allow to draw definitive conclusions and further study would be needed.

Subsequently, we can note that patients with both skeletal and dental increase of the vertical dimension, do not necessarily have occlusal vertical dimension problems. Because the increase of skeletal or dental vertical dimension could not be compensated for by an OVD decrease, they are the correct candidates for multidisciplinary treatment with surgery and orthodontic care before the prosthetic rehabilitation. [Table 6]

The other patients were treated for hyperdivergence with surgery; all presented with an anterior open-bite but with no modification of their OVD carried out in the prosthetic rehabilitation. [Table 6] In these cases, the surgeon should be informed with regard to the planned prosthetic rehabilitation. The vertical position of the maxilla should be determined, taking into consideration the crowns that might be planned in the future restorative phase of treatment. This would often require a larger than normal freeway space because of the reduced crown height in these patients (40).

In our study, nine patients had both an open-bite and an OVD decrease. In most cases, the diagnosis mentioned an associated increase of skeletal vertical dimension. Only two of them were treated with surgery, orthodontic, periodontology and prosthetic rehabilitation, and one with only orthodontic therapy before prosthetic rehabilitation to normalize the anterior and lateral open-bites (30). For the others, the occlusal vertical dimension was corrected by periodontal surgery (crown lengthening) and prosthetic rehabilitation, but management of the hyperdivergence anomaly and anterior open-bite was not mentioned in the treatment.

In this situation, periodontal surgery is the easiest way to increase the OVD using subtraction management of prosthetic space by crown lengthening. This treatment greatly improved the OVD space before prosthetic rehabilitation but the skeletal vertical dimension was not managed. We can suggest that management of the hyperdivergence and the open-bite was not considered. This situation can be attributed to the fact that in this case selection the majority of case reports are treated by general practitioners, who did not take into consideration the orthodontic diagnosis and did not adapt their treatment plan to the needs of the patients.

The majority of patients presented with an OVD decrease before the treatment and they were treated by modifying this condition with prosthetic rehabilitation, often associated with periodontal therapy. Cases with no OVD decrease were treated by surgery for hyperdivergence and open-bite. So, it seems that it is definitely possible to correct skeletal anomalies of the vertical dimension, and to correct the OVD (increased by prosthetic rehabilitation).

The value of the OVD variation was neglected in most cases except one (31) in which the conditions and protocol of OVD increase were detailed. Yet, it is important to specify this value and to distinguish the changes in the posterior and anterior levels according to Abduo's systematic review (41).

The therapeutic OVD should be validated through a temporary restoration (acrylic provisional restorations or full-mouth direct composite restorations (11)) or an occlusal splint. (21, 28, 31). It was used at an increased OVD to assess the patient's response before starting oral rehabilitation and to validate the wax-up.

#### 4.3.3 Surgical therapy

In this literature review, 38% of patients were treated with orthognathic surgery. [Fig: 5]

Clinical investigations have shown that an anomaly of the vertical jaw relationship in combination with increased lower anterior facial height has been observed in many AI patients. Vertical dysgnathia is the main reason why



AOB is so frequently observed in patients with AI. Vertical dysgnathia increases the anterior maxillo-mandibular distance, leading to AOB.

Orthodontic correction of AOB is considered to be very difficult, due to the high relapse rate observed in many cases (37). Inevitably, surgical treatment of patients with AOB combined with AI is one of the challenging alternative therapeutic modalities in orthognathic surgery. Treatment of such patients is a challenge for any clinician and a multidisciplinary approach by a team of orthodontist, maxillofacial surgeon, and prosthodontist is usually necessary.

Among the patients treated with orthognathic surgery, only one of them presented with a loss of OVD (27) which was corrected during the prosthetic rehabilitation. A wax-up was produced after the surgery with a 1mm vertical increase of the occlusion to create enough space for a restorative reconstruction. One could wonder why the management of the space for the prosthetic rehabilitation was not considered before the surgery and be provided beforehand.

However, the cases treated with surgery to decrease the vertical dimension further benefited from a wax-up for the prosthetic rehabilitation. In some cases the diagnostic wax-up suggested an increase in the OVD to create enough space for the ceramic crowns. It is highly important that the surgeon is informed about the prosthetic rehabilitation plan. The reduced height of crowns in these patients may require a larger than normal freeway space. It is suggested that the occlusal relationship should be evaluated before the surgery to allow enough space for the prosthetic rehabilitation. The surgeon should consider the final rehabilitation together with the prosthodontist to manage the vertical dimension. Moreover, as discussed below, crown lengthening surgery can be used in combination to increase OVD in the case of small clinical crown height (41).

In several cases the possibility of a combined orthodontic and orthognathic surgery approach are considered at the initial workup. However, in some cases due to the patient's fears this option was not chosen (20). We might suggest that the limited number of cases treated by surgical therapy in this literature review may be explained by the patient's time constraints, disinterest, or financial difficulties. We have to take into consideration that AI has a psychological impact in term of aesthetics, and because of the high number of appointments required due to dental problems from a young age. Moreover, in some cases the presence of multiple impacted teeth may have complicated the situation and made the orthognathic surgery option unsuitable (21).

To gain the confidence of the patient and reassure them, we could suggest that in the first stage of the treatment tooth sensitivity should be reduced, and patients should be informed about oral hygiene and all other measures of prophylaxis (27). Moreover, placement of a provisional restoration could reinforce the motivation of the patient. A recent review described a CAD Protocol for the simulation of dental treatment of AI. The interest of this approach is to perform the simulation of the wax-up to offer a coherent therapeutic proposal and to reinforce the patient's adherence with the visualization of the treatment objectives. (58)

In most patients treated with orthognathic surgery, treatment requires a Le Fort I intrusion osteotomy with tilting of the occlusal plane, with or without bilateral mandibular sagittal splitting advancement osteotomy or genioplasty. This treatment was performed in four steps [2.4.3.1.2. Orthodontic and surgery therapy, Table 9]. The evaluation of the schema describing the processing steps allows us to see that the only difference might be in the time between each step.

Despite the deterioration of the teeth due to Amelogenesis Imperfecta, the surgical and orthodontic treatment does not significantly differ from those treated without the anomaly. The surgical treatment of adult patients with

open bite and AI should produce an adequate intermaxillary relationship to facilitate occlusal prosthetic rehabilitation.

#### 4.3.4 Orthodontic therapy

19% of patients were treated by orthodontic therapy before the prosthetic rehabilitation in this literature review. The first therapeutic consideration was whether the correction should be at the dental level alone or extended to the skeletal level. A combined orthodontic-surgical approach is often ruled out at the beginning at the express wish of the patient, who was informed of both the skeletal/facial benefits and the difficulties of orthognathic surgery in cases of AI. This approach would have corrected the vertical and sagittal skeletal anomalies, but an orthodontic camouflage approach could be adopted.

We might suggest that orthodontic treatment without surgery could be a compromise for the patients with an increase of the vertical dimension and open-bite who refused the surgical therapy. Anchorage and fixed appliances devices could also play a role in mild anterior open bite (25). Achieving perfect occlusion is not always the treatment goal, as the main principle is often to place the teeth in a position that facilitates the placement of restorations and minimizing the loss of tooth substance.

In the case of congenitally missing teeth, the treatment options are the same as for hypodontia cases and can largely be categorised into total space closure, obviating the need for prosthetic replacement, or space opening and redistribution of space with subsequent restorations (30).

In cases where there is a discrepancy in the maxilla or mandible, an osteotomy may be required to correct this. Liaison between maxillofacial surgeons and orthodontist is the basis of the therapy. This is carried out in combination with fixed appliances to align and decompensated the arches. Temporary anchorage devices could also play a role in mild anterior open bites, managing the occlusal plan with the aid of an intra-osseous anchorage system and brackets (43, 45).

We have to take into consideration that alignment of the dental arches gives rise to special problems because of reduced hardness and thickness of the dental enamel (2). Bonding composite resin by the acid etch technique to enamel affected by AI is more difficult than bonding to normal enamel (42). The challenge of using fixed orthodontic appliances is to manage the defective enamel and determine whether the defective enamel can withstand the force that is applied during the treatment and when removing the appliances (43). In one case, the severe porosity and deformity of the right maxillary canine caused several failures in the adhesion to the bracket, and a temporary resin crown finally had to be placed over it. In another case, enamel fractures appeared after debonding brackets and adhesive. We can suggest that small fractures of enamel could be treated during the final prosthetic rehabilitation. Alternatively, the clinician could set up provisional restorations prior to the treatment, to both increase bracket adherence and to protect tooth surfaces (44). Several methods such as using plastic brackets, glass ionomer cement base adhesives, and traditional banded appliances have been described in the literature to improve adhesion, but the evidence is weak (43).

#### 4.3.5 Periodontal therapy

In this present study, 60% of patients had a periodontal treatment (prophylaxis or surgery) before the prosthetic restoration. Even in cases without periodontal care, the periodontal status was always evaluated before the definitive rehabilitation.

Defects on the teeth are prone to the heavy formation of calculus that can eventually cover the teeth and cause gingival inflammation (46). The association of gingivitis with AI patients may be accounted for by the persistence of bacterial plaque on the rough enamel surface, and tooth sensitivity that leads to poor oral hygiene.

Therefore, it is critical to achieve optimal gingival health before any treatment. When gingival inflammation has been noted, a prophylaxis initiation and a scaling are performed. In one case, 10 months after re-evaluation of the final restoration, the patient had slightly inflamed gingivae due to the absence of preventive therapy and insufficient brushing (13).

The prophylaxis initiation might be a full preventive regimen, including diet analysis and advice as well as oral hygiene instruction. Specific plaque removal instructions, along with professional interventions, have been shown to be safe and efficient in both reducing gingival inflammation and in enabling periodontal health to be maintained throughout the patient's life (47).

In the case of periodontitis, the initial cause-related therapy included full-mouth debridement and root planing of all pockets with attachment loss (20). The presence of gingivitis, gingival hyperplasia or periodontitis has to be analysed and treated before beginning a surgical therapy, an orthodontic treatment or a prosthetic rehabilitation of the patient. 75% of patients benefitted from a provisional step before the definitive restoration. During the provisional step, the rough enamel surface was protected and the gingivae was in a better environment to reduce inflammation. This allowed for proper remodelling and maturation of soft tissues and provided a perfect fit for the definitive restorations (48).

We could mention that the patients should be encouraged to attend regular recall appointments at intervals of at most 6 months, to keep the motivation for oral hygiene and keep the tooth surfaces clean and intact (49).

A periodontal surgical treatment might then be needed to increase by subtraction the OVD for prosthodontic restorations. [Fig 10]

In the case of a patient refusing orthodontic and surgical treatments, or patients with no skeletal or dental abnormalities despite a decrease of OVD, periodontal surgical procedures with bone reduction on molars would be needed in order to improve the occlusal plane. Indeed, patients with Amelogenesis Imperfecta often present with small crowns (microdontia, or due to gingival hyperplasia) and a decrease of the OVD due to loss of enamel. Clinical crown lengthening could be carried out to increase the crown height, creating a new more apically positioned biologic zone. It also allows increased crown retention, a better harmony in the gingivo-cervical region, and an increase and normalized roots/crown ratio (41).

Periodontal surgery can also be necessary after orthodontic treatment and during the restorative procedures to treat the gingival recession with a root coverage gingival graft (24).

The integration of periodontal considerations with orthodontics and restorative planning is now the standard of care. Direct and frequent communication between the periodontist, other specialist and general dentist is a prerequisite for predictable and satisfactory results.

#### 4.3.6 Restorative treatment

In this study, the 16 cases had a prosthetic rehabilitation which lead to an improved occlusion, a better oral health, aesthetic appearance, preservation of tooth structures and reduced sensibility. [Fig: 2]

The prosthetic rehabilitation is always the ultimate goal of the treatment but can play a more or less a significant role in case of a patient's refusal of surgery or orthodontic treatment.

The multidisciplinary treatment of adult patients with open-bite and AI should produce an adequate intermaxillary relationship to facilitate occlusal rehabilitation. As we mentioned above, this could be performed with surgery and/or orthodontics procedures before the prosthetic rehabilitation.

A reorganized approach was adopted in the prosthodontics treatment of an AI patient to increase the occlusal vertical dimension. The loss of tooth substance in AI patients caused the decrease of the OVD. The definitive restorations need to provide sufficient interocclusal space and crown height to correct tooth shape and to restore function with a good OVD. 80% of patient in this study were treated with a rehabilitation of the vertical dimension of occlusion and for 11 of them the increase of the OVD was managed by the prosthetic rehabilitation. [Fig :10]

The prosthetic treatment often begins with a wax-up, for diagnostic reason, and also to discuss with the patients the aesthetics. According to the case selection, the diagnostic wax-up is produce on the mounted study cast (always recording in the centric relation) and expected to realize provisional restorations. However, the existing vertical dimension without a reconstruction could already have been at its upper limit and could not have been increased arbitrarily. A mock-up could be the remedy and allows to validate aesthetic and functional parameters intra-orally (27). In one case, a specific approach was choosen to test the new vertical dimension (11). First, a diagnostic wax-up was produced to fabricate vacuum-formed transparent and full-mouth direct composite build-ups were performed. Secondly, when the best occlusion was validated, new study casts were made from the provisionally restored dentition.

It is always helpful to evaluate a patient's adaptability by provision of a diagnostic interocclusal splint for a trial period. However, many patients do not favour removable appliances and show poor compliance. In the present case, composite build-up's were used instead to address the problem. This assessed the patient's adaptability to the new occlusal scheme and acceptance of the anticipated appearance before making definitive preparations on the patient's teeth. Such an approach offers full control of the occlusion during the entire process and eliminates the potential for errors during the recording of the centric relation at the newly established vertical dimension. However, this technique is not appropriate to all cases. In case of surgical treatment, provisional crowns are usually necessary before to decrease the risk of damage to the pulp and to restore the anatomy of the crowns. Besides, the new vertical dimension is often validating after the surgery with another set of provisionnal cowns. Alternatively, in more complex occlusal conditions, the wax-up may be performed prior to surgery (24). This enables the placement of interim prostheses in the desired occlusal final relationship, thus guiding the surgeon for proper intra-operative jaw positioning.

In all these cases, patients showed good adaptability to the new occlusion and were satisfied with the aesthetic and functional outcome. Indeed, when there is a full mouth rehabilitation and/or an increase of the OVD, it is recommended to review the patient's adaptability to the new occlusion by the absence of temporo-mandibular joint muscle mastication abnormalities. After this step, we could finally rehabilitate the patient at the validated OVD (52).

Among the clinical case of this study, the use of composite resin veneers, porcelain veneers, stainless steel crowns, ceramic and metal-ceramics crowns and over dentures are described in order to restore function and aesthetics. More recently, it was suggested that less invasive treatment alternative with direct composite resin restorations, especially in cases of Amelogenesis Imperfecta without malocclusion, may also be employed (14).

While AI regularly affects both primary and secondary teeth, this study focus on cases treated for definitive restorations at adulthood. Direct restorations with resin-based composites are commonly preferred in young patients for avoiding extensive preparation of teeth during adolescence; however, the data strongly suggest that with a 5-year-survival rate of 50%, the longevity of direct restorations made from resin-based composite and glass ionomer cements is significantly lower in patients with AI than in matching healthy control groups (52). These clinical observations underline the clinical problems associated with adhesive bonding to enamel in patients with AI. A high failure rate associated with insufficient bonding between the composite resin restoration and enamel among variants of AI has been reported in the past (42). However, some recent clinical reports high-lighted that direct and adhesively bonded restorations can feature favorable long-term results (52) which might be due to the continuous improvement of bonding systems in recent years. Although bonding onto the hypoplastic enamel is feasible, sufficient enamel must be available for bonding. Direct restorative materials, such as amalgam restorations are usually unsuccessful in severely affected teeth with AI due to fractures in defective enamel margins (52).

Moreover, direct technique allows the preservation of dental structure since the preparation is limited to affected areas with unsupported enamel (14). The restorations can be placed with minimal tooth preparation or no tooth preparation to preserve tooth structure. This technique allows to obtain the anatomical form of posterior teeth with direct composite according to the Index Technique, a new and conservative approach published by Ammannato and al in 2015 (54).

Composite resin restorations were only used in few cases, probably because of the insufficient bonding between the adhesive product and the enamel in AI reported in the literature before the 2000s or the need to protect all the teeth surface due to the loss of enamel and manage the vertical dimension. But, due to this lack of consensus in the literature, there is still a necessity to evaluate the effectiveness of intraconoral restorations of teeth with AI.

Therefore, full coverage restorations may be a more effective method to provide maximal protection, esthetics, and function. According to Chiung-Fen Chen study, in case of hypomaturation AI, the defective enamel contains excessive organic matter that overtime becomes porous and stained; the defective enamel should be removed before placement of restorations (55). In contrast to direct restorations, data gathered in a high-quality prospective study by Pousette Lundgren and al (39) as well as retrospective data published by Lindunger and Smedberg indicated no significant difference in the longevity of indirect restorations in patients with various types of AI (56). Overall, results agree that indirect restorations are more commonly used in patients with AI feature (such as fixed full coverage prostheses and onlays). [Fig 11]

There are possibilities for the indirect prosthodontic rehabilitation of such teeth: conventional metal crowns, metal-ceramic crowns, full ceramic crowns and minimal invasive treatment with onlays or veneers. In this review, six patients have a full-mouth restoration with the same material (50% with metal-ceramic crowns and 50% with ceramic crowns). In the other cases, different techniques and materials were used for anterior and posterior teeth. For example, in two cases, ceramic veneers were used to restore the anterior teeth and onlays to restore the posterior teeth (13, 24, 29).

Ceramics crowns require significant tooth preparation but the possibility they offered with the CAD-CAM conception reveal new advantages for the preparation. They are also considered for anterior restorations because of its esthetics. Porcelain fused to metal (PFM) crowns for the anterior and posterior teeth were the restoration of choice for AI patients in the last few years and have been reported to be successful (18).

Removal of defective hypoplastic enamel revealed in some cases an unaffected dentinal layer existing. Then, the use of indirect minimally invasive restorations is enabled.

Casting onlays have also been suggested to protect the remaining tooth structure on the posterior teeth, and may be fabricated without tooth preparation (57). It may be a concern that the placement of supraoccluding restorations will result in an increase of the vertical dimension.

We can also observe that for a missing tooth, they choose to replace the space with an implant. There is no contraindication for the implant surgery on AI patient if the quantity of bone is evaluated before.

For the edentulous patient, implants were also used to rehabilitate the maxillary and because of the lack of bone they decided to connected a removable prosthesis (23). A removable prosthesis was also indicated to treat the patient with multi impacted teeth on the mandibular arch (22).

We could suggest that the evolution of techniques plays in the choice of materials in order to achieve optimal results, although using the most conservative approach. For example, with new ceramics and CAD-CAM design it is nowadays possible to limit the tooth preparation and to preserve the vitality of teeth and a maximum of dental tissues.

Indirect restorations with crowns were selected based on the desire to maximally protect and with veneers and onlays to keep the restoration conservative as much as possible. In few cases, direct composite restorations could be use to restore small lesion, when a more conservative approach is desire or when the increase of OVD is minor. Adequate tooth preparation and appropriate choice of restorative materials are essential to limit biological complications like loss of pulp vitality and to ensure long-term success with a correct adhesion.

The striking lack of evidence regarding the long-term outcomes of treatment methods and materials calls for caution in clinical decision-making. Notwithstanding these observations, clinicians have provided and continue to provide rehabilitative strategies for managing their patients' worn dentitions that range traditionally from extensive prosthodontics to an increasing reliance on adhesive techniques.

## 5 Conclusion

Amelogenesis imperfecta is a group of inherited disorders that pose diagnostic and restorative treatment challenges for dental care providers. This genetic disorder causes defective enamel development and modifying genes affecting both the dental and craniofacial developmental processes. Skeletal and dental increased of the vertical dimension malocclusions has been reported associated with AI (hyperdivergency and open-bite). Besides, abnormal enamel conducted in parallel to its mechanical wear and the loss of occlusion vertical dimension.

Although the number of well-designed clinical studies is limited, the authors attempt to derive some guidelines for treatment of patients with AI from the clinical studies that could be included into this review.

According to our study, the planning stage includes a detailed skeletal, dental and occlusal examination. An orthodontic diagnosis seems to be considering to explore skeletal and dental relationships systematically in AI for the treatment plan setting.

The treatment options should consider OVD in order to restore prosthetic space. Orthodontic and surgery treatment are often required due to hyperdivergence and anterior open bite, often associated to AI patients. Besides vertical dimension anomalies, other malocclusions like cross-bite, Class II or Class III occlusion, and constriction of the maxilla may require orthodontic or surgery treatment.

Orthognathic surgery is recommended if the abnormalities of vertical dimension derive from skeletal component which could not be compensate. Orthodontic therapy is use in combination with orthognathic surgery to align and decompensated the arches and to manage impacted teeth or delayed tooth eruption. To minimize tooth wear before entering the restorative phase, the patient's teeth should be in the ideal position thanks to orthodontics treatment. Periodontology with crown lengthening before the prosthetic rehabilitation achieve to harmonize the smile and to manage by subtraction the prosthetic space.

Then a restorative reconstruction is indicated for all patients suffering from AI to prevent further attrition and destruction of the teeth, to protect from sensibility, to restore esthetics and to avoid loss of the vertical dimension. To best manage this finally step it is recommended to choose the correct OVD. This can be performed by a full wax-up and simulation of the future definitive reconstruction using provisional crowns, direct composite fillings, splints, or more recently with the use of CAD visualization. It allows to review the patient's adaptability to the new occlusion to finally rehabilitate the patient at the validated OVD. Beyond testing functional aspect, provisional crowns would provide an environment conducive for maintenance of periodontal health.

Coordinated interdisciplinary procedures are critical for a successful outcome and patient satisfaction. Prosthodontic rehabilitation might be taken with full-crowns ceramic reconstruction for severe affected teeth. Generally, the data indicate that indirect restorations feature superior predictability and longevity than direct restorations, which is particularly due to the impaired adhesive bonding to AI-affected enamel. Recently, adhesive treatments represent an interesting option for AI patients. Minimally invasive technique with onlays on posterior teeth and veneers on anterior for limited affected teeth are commonly used. It represents a promising alternative, especially in the posterior area, to preserve dental structure and stabilize weakened tooth substance; however, longer observation periods and randomized controlled trials with a large number of treatments are necessary to assess the long-term success of such restorations.

Direct adhesive restorations have to be used as soon as possible in young patient to provide loss of enamel and maintain vertical dimension. However, for definitive restorations its long term survives depend of protocols technique and type of AI surface. The cumulated evidence on outcomes of alternative restorations for each type of AI is critically needed. In the case reports selection, we don't have enough information about the success reevaluation of the treatments.

Depending of the diagnosis, the severity of the enamel loss, the anomalies of the vertical dimension, there is currently no standard of care established for managing patient with AI.

Coordination is almost synonymous with interdisciplinary approach which is necessary to evaluate, diagnose and resolve the aesthetic and functional problems using a combination of surgery, orthodontic, periodontology and restorative treatment.

Nowadays, with virtually CAD-CAM diagnosis wax-up and conception for surgery, orthodontics and prosthetic treatment, we can more easily consider the final rehabilitation, using minimally invasive method, explain pedagogically the course of the treatment to our patient (58). The general practitioner plays a major role in directed the patient toward specialist and determine with them the global treatment plan with the help of a diagnosis wax-up.

## Bibliographic references

1. ROBINSON FG, HAUBENREICH JE. ORAL REHABILITATION OF A YOUNG ADULT WITH HYPOPLASTIC AMELOGENESIS IMPERFECTA: A CLINICAL REPORT. *J PROSTHET DENT*. 2006 JAN;95(1):10–3.
2. BÄCKMAN B, HOLM AK. AMELOGENESIS IMPERFECTA: PREVALENCE AND INCIDENCE IN A NORTHERN SWEDISH COUNTY. *COMMUNITY DENT ORAL EPIDEMIOL*. 1986 FEB;14(1):43–7.
3. WITKOP CJ. AMELOGENESIS IMPERFECTA, DENTINOGENESIS IMPERFECTA AND DENTIN DYSPLASIA REVISITED: PROBLEMS IN CLASSIFICATION. *J ORAL PATHOL*. 1988 NOV;17(9–10):547–53.
4. ROWLEY R, HILL FJ, WINTER GB. AN INVESTIGATION OF THE ASSOCIATION BETWEEN ANTERIOR OPEN-BITE AND AMELOGENESIS IMPERFECTA. *AM J ORTHOD*. 1982 MAR;81(3):229–35.
5. RAVASSIPOUR DB, POWELL CM, PHILLIPS CL, HART PS, HART TC, BOYD C, ET AL. VARIATION IN DENTAL AND SKELETAL OPEN BITE MALOCCLUSION IN HUMANS WITH AMELOGENESIS IMPERFECTA. *ARCHIVES OF ORAL BIOLOGY*. 2005 JUL 1;50(7):611–23.
6. POULSEN S, GJØRUP H, HAUBEK D, HAUKALI G, HINTZE H, LØVSCALL H, ET AL. AMELOGENESIS IMPERFECTA - A SYSTEMATIC LITERATURE REVIEW OF ASSOCIATED DENTAL AND ORO-FACIAL ABNORMALITIES AND THEIR IMPACT ON PATIENTS. *ACTA ODONTOL SCAND*. 2008 AUG;66(4):193–9.
7. PAREKH S, ALMEHATEB M, CUNNINGHAM SJ. HOW DO CHILDREN WITH AMELOGENESIS IMPERFECTA FEEL ABOUT THEIR TEETH? *INT J PAEDIATR DENT*. 2014 SEP;24(5):326–35.
8. DAHASH M, YEUNG CA, JAMOUS I, BLINKHORN A. INTERVENTIONS FOR THE RESTORATIVE CARE OF AMELOGENESIS IMPERFECTA IN CHILDREN AND ADOLESCENTS. IN: THE COCHRANE LIBRARY [INTERNET]. JOHN WILEY & SONS, LTD; 2013 [CITED 2018 MAR 28]. AVAILABLE FROM: [HTTP://COCHRANELIBRARY-WILEY.COM/DOI/10.1002/14651858.CD007157.PUB2/FULL](http://cochranelibrary-wiley.com/doi/10.1002/14651858.CD007157.PUB2/FULL)
9. SABANDAL MMI, SCHÄFER E. AMELOGENESIS IMPERFECTA: REVIEW OF DIAGNOSTIC FINDINGS AND TREATMENT CONCEPTS. *ODONTOLOGY*. 2016 SEP;104(3):245–56.
10. MILLET CATHERINE, DUPREZ JEAN-PIERRE, KHOURY CHRISTINE, MORGON LAURENT, RICHARD BÉATRICE. INTERDISCIPLINARY CARE FOR A PATIENT WITH AMELOGENESIS IMPERFECTA: A CLINICAL REPORT. *JOURNAL OF PROSTHODONTICS*. 2015 JUL 22;24(5):424–31.
11. CHAN KHC, HO EHT, BOTELHO MG, POW EHN. REHABILITATION OF AMELOGENESIS IMPERFECTA USING A REORGANIZED APPROACH: A CASE REPORT. *QUINTESSENCE INT*. 2011 MAY;42(5):385–91.
12. SADIGHPOUR L, GERAMIPANAH F, NIKZAD S. FIXED REHABILITATION OF AN ACP PDI CLASS III PATIENT WITH AMELOGENESIS IMPERFECTA. *J PROSTHODONT*. 2009 JAN;18(1):64–70.
13. SENGUN A, OZER F. RESTORING FUNCTION AND ESTHETICS IN A PATIENT WITH AMELOGENESIS IMPERFECTA: A CASE REPORT. *QUINTESSENCE INT*. 2002 MAR;33(3):199–204.
14. SABATINI C, GUZMÁN-ARMSTRONG S. A CONSERVATIVE TREATMENT FOR AMELOGENESIS IMPERFECTA WITH DIRECT RESIN COMPOSITE RESTORATIONS: A CASE REPORT. *J ESTHET RESTOR DENT*. 2009;21(3):161–9; DISCUSSION 170.
15. MILLET C, DUPREZ J-P. MULTIDISCIPLINARY MANAGEMENT OF A CHILD WITH SEVERE OPEN BITE AND AMELOGENESIS IMPERFECTA. *J CONTEMP DENT PRACT*. 2013 MAR 1;14(2):320–6.
16. OLIVEIRA IKCS, FONSECA J DE FB, DO AMARAL FLB, PECORARI VGA, BASTING RT, FRANÇA FMG. DIAGNOSIS AND ESTHETIC FUNCTIONAL REHABILITATION OF A PATIENT WITH AMELOGENESIS IMPERFECTA. *QUINTESSENCE INT*. 2011 JUN;42(6):463–9.
17. SADIGHPOUR L, GERAMIPANAH F, NIKZAD S. FIXED REHABILITATION OF AN ACP PDI CLASS III PATIENT WITH AMELOGENESIS IMPERFECTA. *J PROSTHODONT*. 2009 JAN;18(1):64–70.
18. YIP HK, SMALES RJ. ORAL REHABILITATION OF YOUNG ADULTS WITH AMELOGENESIS IMPERFECTA. *INT J PROSTHODONT*. 2003 AUG;16(4):345–9.



19. ASSUNÇÃO WG, BARÃO VAR, KANNO CM, SAITO CTMH, DELBEN JA. OVERDENTURE AS A RESTORATIVE OPTION FOR HYPOCALCIFIED-HYPOPLASTIC AMELOGENESIS IMPERFECTA: A CASE REPORT. J CONTEMP DENT PRACT. 2009 MAY 1;10(3):67–73.
20. HARRYPARSAD A, RAHMAN L, BUNN B. AMELOGENESIS IMPERFECTA: A DIAGNOSTIC AND PATHOLOGICAL REVIEW WITH CASE ILLUSTRATION. :5.
21. YILMAZ B, OZ U, YILMAZ HG. INTERDISCIPLINARY APPROACH TO ORAL REHABILITATION OF PATIENT WITH AMELOGENESIS IMPERFECTA. THE NEW YORK STATE DENTAL JOURNAL. 2014 MAR 1;80:31–5.
22. PATIL PG, PATIL SP. AMELOGENESIS IMPERFECTA WITH MULTIPLE IMPACTED TEETH AND SKELETAL CLASS III MALOCCLUSION: COMPLETE MOUTH REHABILITATION OF A YOUNG ADULT. THE JOURNAL OF PROSTHETIC DENTISTRY. 2014 JAN;111(1):11–5.
23. APAYDIN A, SERMET B, URETURK S, KUNDACKIOGLU A. CORRECTION OF MALOCCLUSION AND ORAL REHABILITATION IN A CASE OF AMELOGENESIS IMPERFECTA BY INSERTION OF DENTAL IMPLANTS FOLLOWED BY LE FORT I DISTRACTION OSTEOGENESIS OF THE EDENTULOUS ATROPHIC MAXILLA. BMC ORAL HEALTH. 2014 SEP 17;14:116.
24. RAMOS AL, PASCOTTO RC, FILHO LI, HAYACIBARA RM, BOSELLI G. INTERDISCIPLINARY TREATMENT FOR A PATIENT WITH OPEN-BITE MALOCCLUSION AND AMELOGENESIS IMPERFECTA. AMERICAN JOURNAL OF ORTHODONTICS AND DENTOFACIAL ORTHOPEDICS. 2011 APR;139(4):S145–53.
25. MORALES MV, PEREZ J-MB, GARCIA JJ, VARELA PG-C. INTERDISCIPLINARY TREATMENT OF A PATIENT WITH AMELOGENESIS IMPERFECTA. 2010;(9):7.
26. MARŞAN G, AKSU IS, KURT H, KUVAT SV, CURA N. INTERDISCIPLINARY TREATMENT OF A PATIENT WITH AMELOGENESIS IMPERFECTA, A SKELETAL CLASS III RELATIONSHIP, AND AN ANTERIOR OPEN BITE. WORLD J ORTHOD. 2010;11(3):284–90.
27. GISLER V, ENKLING N, ZIX J, KIM K, KELLERHOFF N-M, MERICSKE-STERN R. A MULTIDISCIPLINARY APPROACH TO THE FUNCTIONAL AND ESTHETIC REHABILITATION OF AMELOGENESIS IMPERFECTA AND OPEN BITE DEFORMITY: A CASE REPORT. JOURNAL OF ESTHETIC AND RESTORATIVE DENTISTRY. 2010 OCT 1;22(5):282–93.
28. KUMAR S. THE RESTORATION OF FUNCTION AND ESTHETICS OF A PATIENT WITH AMELOGENESIS IMPERFECTA USING A COMBINATION OF ORTHODONTIC AND PROSTHODONTIC TREATMENT: A CASE REPORT. THE JOURNAL OF CONTEMPORARY DENTAL PRACTICE. 2009;10(6):7.
29. KELES A, PAMUKCU B, IŞIK F, GEMALMAZ D, GÜZEL MZ. IMPROVING QUALITY OF LIFE WITH A TEAM APPROACH: A CASE REPORT. INT J ADULT ORTHODON ORTHOGNATH SURG. 2001;16(4):293–9.
30. ENCINAS, ROSA PULGAR, RODRIGUEZ JMN. AMELOGENESIS IMPERFECTA: DIAGNOSIS AND RESOLUTION OF A CASE WITH HYPOPIASIA AND HYPOCALCIFICATION OF ENAMEL, DENTAL AGENESIS, AND SKELETAL OPEN BITE. 2001;32(3):8.
31. WILLIAMS WP AND BECKER LH. AMELOGENESIS IMPERFECTA: FUNCTIONAL AND ESTHETIC RESTORATION OF A SEVERELY COMPROMISED DENTITION. -QUINTESSENCE INT. 2000 JUN;31(6):397-403.
32. THOMPSON GA, SCHWARTZ JM. ORAL REHABILITATION OF A PATIENT WITH AMELOGENESIS IMPERFECTA. JOURNAL OF PROSTHODONTICS. 1997 DEC 1;6(4):257–64.
33. NEL JC, PRETORIUS JA, WEBER A, MARAIS JT. RESTORING FUNCTION AND ESTHETICS IN A PATIENT WITH AMELOGENESIS IMPERFECTA. INT J PERIODONTICS RESTORATIVE DENT. 1997 OCT;17(5):478–83.
34. CARTWRIGHT AR, KULA K, WRIGHT TJ. CRANIOFACIAL FEATURES ASSOCIATED WITH AMELOGENESIS IMPERFECTA. J CRANIOFAC GENET DEV BIOL. 1999;19(3):148–56.
35. PAVLIČ A, BATTELINO T, TREBUŠAK PODKRAJŠEK K, OVSENIK M. CRANIOFACIAL CHARACTERISTICS AND GENOTYPES OF AMELOGENESIS IMPERFECTA PATIENTS. EUR J ORTHOD. 2011 JUN 1;33(3):325–31.
36. PERSSON M, SUNDELL S. FACIAL MORPHOLOGY AND OPEN BITE DEFORMITY IN AMELOGENESIS IMPERFECTA: A ROENTGENOCEPHALOMETRIC STUDY. ACTA ODONTOLOGICA SCANDINAVICA. 1982 JAN 1;40(3):135–44.
37. HOPPENREIJS TJ, VOORSMIT RA, FREIHOFFER HP. OPEN BITE DEFORMITY IN AMELOGENESIS IMPERFECTA. PART 1: AN ANALYSIS OF CONTRIBUTORY FACTORS AND IMPLICATIONS FOR TREATMENT. J CRANIOMAXILLOFAC SURG. 1998 AUG;26(4):260–6.
38. TAVANO KTA, SERAIDARIAN PI, DE OLIVEIRA DD, JANSEN WC. DETERMINATION OF VERTICAL DIMENSION OF OCCLUSION IN DENTATE PATIENTS BY CEPHALOMETRIC ANALYSIS--PILOT STUDY. GERODONTOLOGY. 2012 JUN;29(2):E297-305.

39. POUSETTE LUNDGREN G, WICKSTRÖM A, HASSELBLAD T, DAHLÖF G. AMELOGENESIS IMPERFECTA AND EARLY RESTORATIVE CROWN THERAPY: AN INTERVIEW STUDY WITH ADOLESCENTS AND YOUNG ADULTS ON THEIR EXPERIENCES. PLOS ONE [INTERNET]. 2016 JUN 30
40. ROETERS J, DE KLOET H. ESTHETISCHE TANDHEELKUNDE. NIJMEGEN: STI; 1988. p. 222-5.
41. ABDUO J. SAFETY OF INCREASING VERTICAL DIMENSION OF OCCLUSION: A SYSTEMATIC REVIEW. QUINTESSENCE INT. 2012 MAY;43(5):369–80.
42. SEOW WK. CLINICAL DIAGNOSIS AND MANAGEMENT STRATEGIES OF AMELOGENESIS IMPERFECTA VARIANTS. PEDIATR DENT. 1993 DEC;15(6):384–93.
43. ARKUTU N, GADHIA K, McDONALD S, MALIK K, CURRIE L. AMELOGENESIS IMPERFECTA: THE ORTHODONTIC PERSPECTIVE. BRITISH DENTAL JOURNAL [INTERNET]. 2012
44. BOUVIER D, DUPREZ JP, PIREL C, VINCENT B. AMELOGENESIS IMPERFECTA--A PROSTHETIC REHABILITATION: A CLINICAL REPORT. J PROSTHET DENT. 1999 AUG;82(2):130–1.
45. CORNELIUS C-P, EHRENFELD M. THE USE OF MMF SCREWS: SURGICAL TECHNIQUE, INDICATIONS, CONTRAINDICATIONS, AND COMMON PROBLEMS IN REVIEW OF THE LITERATURE. CRANIO MAXILLOFAC TRAUMA RECONSTR. 2010 JUN;3(2):55–80.
46. POULSEN S, MØLLER IJ. GINGIVITIS AND DENTAL PLAQUE IN RELATION TO DENTAL FLUOROSIS IN MAN IN MOROCCO. ARCHIVES OF ORAL BIOLOGY. 1974 OCT 1;19(10):951–4.
47. AXELSSON P, LINDHE J. EFFECT OF CONTROLLED ORAL HYGIENE PROCEDURES ON CARIES AND PERIODONTAL DISEASE IN ADULTS. JOURNAL OF CLINICAL PERIODONTOLOGY. 1978 JUN 1;5(2):133–51.
48. SOOD S, GUPTA S. PERIODONTAL-RESTORATIVE INTERACTIONS: A REVIEW. INDIAN JOURNAL OF MULTIDISCIPLINARY DENTISTRY. 2011 JAN 5;1(4):208.
49. SCOTTISH INTERCOLLEGIATE GUIDELINES NETWORK, SCOTLAND, HEALTHCARE IMPROVEMENT SCOTLAND. DENTAL INTERVENTIONS TO PREVENT CARIES IN CHILDREN: A NATIONAL CLINICAL GUIDELINE. 2014.
50. VALDERHAUG J. MARGIN OF RESTORATIONS - FROM THE VIEWPOINT OF CROWN AND BRIDGE MAKING. NOR TANNLAEGEFOREN TID 1972;82(7):386-90.
51. CARLSSON GE, INGERVALL B, KOCAC G. EFFECT OF INCREASING VERTICAL DIMENSION ON THE MASTICATORY SYSTEM IN SUBJECTS WITH NATURAL TEETH. J PROSTHET DENT. 1979 MAR;41(3):284–9.
52. STRAUCH S, HAHNEL S. RESTORATIVE TREATMENT IN PATIENTS WITH AMELOGENESIS IMPERFECTA: A REVIEW. JOURNAL OF PROSTHODONTICS. 2018 AUG 1;27(7):618–23.
53. GERDOLLE D, MORTIER E, RICHARD A, VAILATI F. FULL-MOUTH ADHESIVE REHABILITATION IN A CASE OF AMELOGENESIS IMPERFECTA: A 5-YEAR FOLLOW-UP CASE REPORT. THE INTERNATIONAL JOURNAL OF ESTHETIC DENTISTRY. 2015 JAN 27;10:12–31.
54. AMMANNATO R, FERRARIS F, MARCHESI G. THE “INDEX TECHNIQUE” IN WORN DENTITION: A NEW AND CONSERVATIVE APPROACH. CLINICAL RESEARCH. 2015;10(1):32.
55. CHEN C-F, HU JC, BRESCIANI E, PETERS MC, ESTRELLA MR. TREATMENT CONSIDERATIONS FOR PATIENT WITH AMELOGENESIS IMPERFECTA: A REVIEW. BRAZ DENT SCI. 2013;16(4):7–18.
56. LINDUNGER A, SMEDBERG JJ: A RETROSPECTIVE STUDY OF THE PROSTHODONTIC MANAGEMENT OF PATIENTS WITH AMELOGENESIS IMPERFECTA. INT J PROSTHODONT 2005;18:189-194
57. HARLEY KE, IBBETSON RJ. DENTAL ANOMALIES--ARE ADHESIVE CASTINGS THE SOLUTION? BR DENT J. 1993 JAN 9;174(1):15–22.
58. BREZULIER\* D, SOREL JL AND O. DESCRIPTION OF A CAD PROTOCOL FOR THE SIMULATION OF DENTAL TREATMENT OF AMELOGENESIS IMPERFECTA. BIOMEDICAL JOURNAL OF SCIENTIFIC & TECHNICAL RESEARCH. 2018 MAR 9;3(1):001–3.

## Table of illustrations

### TABLES

Table 1: Numbers of titles listed in Pubmed (June 2018) for various combinations of the research terms. ....	11
Table 2: Rejected articles and cause of rejection. ....	12
Table 3: Skeletal Characteristics and malocclusions. ....	16
Table 4: Dental vertical anomalies and malocclusions. ....	16
Table 5 : Association between skeletal and dental vertical dimension with DVO. ....	17
Table 6 :Which treatments improve the vertical dimension and how. ....	20
table 7 : General characteristics of patient's included in the selected articles. ....	41
table 8: Skeletal and dental diagnosis of patient included in the selected articles ....	42
Table 9: Steps of treatments in each cases treated by orthodontic and/or surgery therapy. ....	43

### PICTURE CARD

Figure 1 : Diagram of selection of the articles. ....	13
Figure 2 : General characteristics of patients included in the selected articles. ....	14
Figure 3: Skeletal vertical dimension. ....	15
Figure 4: Patients with Amelogenesis Imperfecta and open-bite. ....	15
Figure 5: For the interdisciplinary treatment options, steps of treatment and type of each therapeutic intervention. ....	18
Figure 6: Treatment options and skeletal vertical dimension. ....	19
Figure 7: Treatment options and dental vertical dimension. ....	20
Figure 8: Representation of patients treated by orthodontic or surgery therapy before prosthetic rehabilitation. .....	22
Figure 9: Periodontology treatments. ....	23
Figure 10: stages of pre-prosthetic preparation according to the new prosthetic vertical dimension. ....	24
Figure 11:Representation of prothetic materials used. ....	25

## Annex

Articles	N° patient	Gender	Age	Type of dentition	Type of AI	Associated oral characteristics	method's of vertical dimension evaluation and malocclusion	Treatment during childhood	Teeth extraction ( carious lesions, infection )
Apayadin A, 2014	1	F	17	Permanent dentition	Hypocalcified	<ul style="list-style-type: none"> <li>- Unerupted teeth, delayed eruption</li> <li>- Loss 5 teeth mandibular</li> <li>- Caries</li> <li>- Microform teeth and diastema</li> <li>- Gingival tissue enlarged</li> <li>- Decreased of vertical dimension because of teeth destruction.</li> </ul>	Cephalometric analysis	<ul style="list-style-type: none"> <li>- Deciduous teeth extracted</li> <li>- Retainers applied</li> <li>- Ill shaped teeth extracted</li> </ul>	- All maxillary teeth and 5 mandibular
Yilmaz B, 2014	1	F	22	Permanent dentition	Hypoplastic	<ul style="list-style-type: none"> <li>- Tooth sensitivity</li> <li>- Unesthetic appearance of her anterior teeth</li> <li>- Anterior open-bite</li> <li>- irregular distribution of diastema mandibular et maxillary caries</li> </ul>	Interocclusal space ( 4mm)	Not mentionned	16
Patil PG, 2014	1	M	23	Permanent dentition	Not mentioned	<ul style="list-style-type: none"> <li>- Impacted teeth</li> <li>- Open occlusal relation ship</li> <li>- Oligodontia in the maxillary and mandibular arches</li> <li>- Destruction of the anterior crowns</li> </ul>	Interocclusal space ( 9mm anterior )		Multiple deciduous teeth in both arches with compromised alveolar bone support were extracted.
Harrypar sad et al, 2013	1	F	45	Permanent dentition	Hypomaturati on	<ul style="list-style-type: none"> <li>- Periodontitis</li> <li>- Difficulty eating</li> <li>- Severe discoloration</li> <li>- Microdontia anterior teeth</li> <li>- Carious lesions</li> <li>- Missing teeth</li> <li>- Cross bite teeth</li> <li>- Deep overbite (6mm)</li> </ul>	Interocclusal space (freeway space of 4 mm.)	No history of previous restorative dental treatment	26, 36, 37, 12
Chan et al., 2011	1	F	40	Permanent dentition	Hypoplastic	<ul style="list-style-type: none"> <li>- Dental sensitivity</li> <li>- Damage enamel structure</li> <li>- Caries</li> <li>- Reduced facial height</li> </ul>	Esthetics and interocclusal space (freeway space of 5 mm.)	Amalgam 45 46 : endodontie treatment	36
Ramos, 2011	1	M	15	Permanent dentition	Hypoplastic	<ul style="list-style-type: none"> <li>- Discoloration of teeth</li> </ul>	Cephalometric analysis	Amalgam on molar	
Varela Moreles, 2010	1	M	14	Permanent dentition	Hypoplastic ( severe)	<ul style="list-style-type: none"> <li>- Dental sensitivity</li> <li>- Color of teeth</li> <li>- Blocked-out upper right canine</li> <li>- Mild open bite</li> <li>- Caries</li> </ul>	Cephalometric analysis	<ul style="list-style-type: none"> <li>- Treatment during primary and definitive dentition</li> <li>- Metallic crowns all first molar</li> <li>- Multiple composite</li> </ul>	
Gisler V, 2010	1	F	18 ( article 14 at the beginning)	Permanent dentition	Hypoplastic	<ul style="list-style-type: none"> <li>- Increase of vertical dimension</li> <li>- Tooth microform</li> <li>- Enamel aplasia</li> <li>- Diastemas</li> <li>- Overbite and open-bite</li> <li>- Dentin hypersensitivity</li> </ul>	Cephalometric analysis		Neither fillings nor caries existed at 14y: provisionnal treatment until 18y with direct resin composite.
Marçan G, 2010	1	F	18	Permanent dentition	Hypoplastic	<ul style="list-style-type: none"> <li>- Discoloration of teeth</li> </ul>	Cephalometric analysis	Composite restauration and amalgam	No
Kumar, 2009	1	F	20	Permanent dentition	Hypoplastic	<ul style="list-style-type: none"> <li>- Attrition of all of her teeth, decrease of vertical dimension.</li> <li>- Hypersensitive.</li> </ul>	Cephalometric analysis	No	No
Sengun and Ozer, 2002	1	M	14	Permanent dentition	Hypomaturati on	<ul style="list-style-type: none"> <li>- Dental Sensitivity</li> <li>- Gingivitis</li> <li>- Loss of vertical dimension</li> <li>- Attrition, severe loss of enamel.</li> <li>- Caries</li> </ul>	The interocclusal rest space	No	36
Keles, 2001	1	F	17	Permanent dentition	Hypoplastic	<ul style="list-style-type: none"> <li>- Malformation of enamel</li> <li>- Anterior open bite</li> <li>- Facial asymmetry,</li> <li>- Class III skeletal pattern,</li> <li>- Maxillary constriction</li> </ul>	Cephalometric analysis	No	No
Pulgar Encinas, 2001	1	F	15	Permanent dentition	Hypoplastic-hypocalcificati on	<ul style="list-style-type: none"> <li>- Hypersensitivity</li> <li>- Teeth 12, 22 absent</li> <li>- Small teeth friable, diastema</li> <li>- Class 3 occlusion</li> <li>- Gingivitis</li> </ul>	Cephalometric analysis	Composite restauration	No
Williams and Becker, 2000	1	F	16	Permanent dentition	Hypoplastic	<ul style="list-style-type: none"> <li>- Short clinical crowns,</li> <li>- Difficulty to chew</li> <li>- Overjet and open-bite</li> </ul>	The interocclusal distance was measured clinically and by cephalometric analysis	One amalgam restoration	No
Nel JC, 1997	1	M	20	Permanent dentition	Hypocalcified	<ul style="list-style-type: none"> <li>- Gingivitis and marginal periodontitis</li> <li>- Congenitally missing 12</li> <li>- Malocclusion</li> <li>- Discoloration and loss of dentin</li> <li>- Loss of chewing function</li> </ul>	Cephalometric analysis	Endodontic treatment	No
Thompson and Schwartz , 1997	1	M	23	Permanent dentition	Hypoplastic	<ul style="list-style-type: none"> <li>- Mild localized gingivitis</li> <li>- Caries</li> <li>- Destruction of tooth structure</li> <li>- Diastemas, short clinical crowns</li> <li>- Anterior and lateral skeletal open bite</li> <li>- Loss of chewing function</li> </ul>	The interocclusal distance was evaluated phonetically and on the diagnostic casts.	Provisional acrylic restorations covered the maxillary incisors, and stain- less-steel crowns placcd on all first molars.	15, 18

table 7 : General characteristics of patient's included in the selected articles.

Articles	Cutaneous	Skeletal			Dental Alveolar		
		Verticale	Transversale	Sagittal	Verticale	Transversale	Sagittal
Apayadin A, 2014	<ul style="list-style-type: none"> <li>- Concave profile</li> <li>- Pronounced chin and nose</li> <li>- No display upper gingival tissue when smiling</li> </ul>	<ul style="list-style-type: none"> <li>- Short lower face</li> <li>- Decrease of the vertical dimension</li> </ul>	Narrow Small Maxilla	<ul style="list-style-type: none"> <li>- Retrognathic maxilla</li> <li>- Skeletal Class III</li> </ul>	Openbite	Posterior bilateral cross bite	Class III
Yilmaz B, 2014					Openbite : 4Mm Inadequate Crown Lengths	Diastemas, Non-alignment of teeth	Overjet: 4Mm Class 1 Posterior Teeth
Patil Pg, 2014	Left hemifacial hypertrophy on the lower third of the face	Open Relationship		<ul style="list-style-type: none"> <li>- Maxillary Retrognathism,</li> <li>- Mandibular prognathism</li> <li>- Angle Class III skeletal malocclusion</li> </ul>	<ul style="list-style-type: none"> <li>- Multiple impacted teeth in both arches</li> <li>- Open occlusal relationship anterior teeth ( 9mm)</li> </ul>	<ul style="list-style-type: none"> <li>- Increased vertical overlap of the right posterior region</li> <li>- Open occlusal relationship of the left posterior region (11Mm)</li> </ul>	Anterior reverse articulation
Harryparsad Et Al, 2013					Overbite: 6Mm		Overjet: 1Mm
Chan Et Al., 2011	Symmetric	Facial height reduced		Class I Skeletal Base			Class I, Division 1 incisor relationship
Ramos, 2011	<ul style="list-style-type: none"> <li>- Profile: vertical excess</li> <li>- Large buccal corridors when smiling</li> </ul>	Hyperdivergent	Narrow Maxilla	Maxillary and mandibular retrusion	Anterior open bite	Posterior bilateral cross bite	Class 1 M
Varela Moreles, 2010	Convex profile	<ul style="list-style-type: none"> <li>- Hypoplastic Mandible,</li> <li>- High mandibular plane angle: hyper divergence.</li> </ul>		<ul style="list-style-type: none"> <li>- Mandibular anterior crowding,</li> <li>- Severe skeletal class II malocclusion,</li> </ul>	Mild Open Bite		<ul style="list-style-type: none"> <li>- Class 1 M</li> <li>- Dentoalveolar bimaxillary protrusion</li> </ul>
Gisler V, 2010	<ul style="list-style-type: none"> <li>- A Straight Profile With A Pronounced Chin And Jaw,</li> <li>- A Strong Gummy Smile Of 5 To 6 Mm</li> <li>- Increase Of The Dimension Of The Lower Face,</li> <li>- No Bite Collapse</li> </ul>	Hyperdivergent	Middle line in the lower jaw was displaced to the left by 2 mm.	Skeletal Class I	Openbite Of -5Mm	<ul style="list-style-type: none"> <li>- No Interdental Contact : Diastemas,</li> <li>- First and second molars were in an edge-to-edge bite</li> </ul>	<ul style="list-style-type: none"> <li>- Class 1 Right Side</li> <li>- Class 2 Left Side</li> </ul>

Marçan G, 2010	<ul style="list-style-type: none"> <li>- Asymmetry with her chin deviating to the right side</li> <li>- Concave Profile</li> <li>- 50% incisor display when smiling</li> </ul>	Long lower face height ~6.0-mm skeletal anterior open bite		Skeletal Class III relationship	Anterior Open Bite	Both dental midlines deviated 2.0 mm to the right in relation to the facial midline	4.0-mm overjet class III M
Kumar, 2009	<ul style="list-style-type: none"> <li>- A long face with severe facial asymmetry mandibular shift to the right side</li> <li>- An Asymmetric Smile</li> </ul>	Long lower face Hyperdivergent	<ul style="list-style-type: none"> <li>- Maxilla bilaterally constricted</li> <li>- Facial asymmetry to the right</li> </ul>	Skeletal Class III relationship	No Open-Bite	Posterior Crossbite	<ul style="list-style-type: none"> <li>- A Class I left molar malocclusion</li> <li>- A Class II, subdivision right molar relationship</li> </ul>
Sengun And Ozer, 2002		Hypodivergent			<ul style="list-style-type: none"> <li>- Loss of vertical dimension on posterior teeth,</li> <li>- No Open-Bite</li> </ul>		<ul style="list-style-type: none"> <li>- Molar Class 1 relationship anterior teeth edge to edge</li> </ul>
Keles, 2001	<ul style="list-style-type: none"> <li>- Straight Profile,</li> <li>- Long lower face height,</li> <li>- Facial Asymmetry,</li> <li>- Chin deviation on the left side</li> </ul>	Hyperdivergent	Constricted Maxilla	Skeletal Class III high angle skeletal pattern	8mm Anterior Open Bite	Posterior Cross Bite	Lower Incisor retroclined
Pulgar Encinas, 2001	Hyperdivergence Facial	<ul style="list-style-type: none"> <li>- Reduction of the posterior vertical skeletal dimension,</li> <li>- Hyperdivergent</li> </ul>		Skeletal Class III	<ul style="list-style-type: none"> <li>- Edge to edge anterior occlusion: slightly open-bite</li> <li>- Decreased of dental posterior vertical dimension.</li> </ul>	<ul style="list-style-type: none"> <li>- Posterior Cross Bite</li> <li>- Maxillary loss of space due to the missing teeth 12 and 22</li> </ul>	<ul style="list-style-type: none"> <li>- Class 1 Molar</li> <li>- Edge to edge anterior relationship</li> </ul>
Williams And Becker, 2000	Facial Asymmetry Gummy Smile			Skeletal Class I	Large Open Bite		<ul style="list-style-type: none"> <li>- Deep Overjet</li> <li>- Class 1</li> </ul>
Nel Jc, 1997	Prominent Pointed Chin	Hyperdivergence	Narrow Mandible And Maxilla	<ul style="list-style-type: none"> <li>- Skeletal Class II Division 1</li> <li>- Bimaxillary Protrusion</li> </ul>	Slightly Open-Bite		Class 1 Molar
Thompson And Schwartz, 1997		Hyperdivergence			Overbite : 4mm left	<ul style="list-style-type: none"> <li>- Dental midline discrepancy,</li> <li>- Reverse occlusal curve on the left side</li> </ul>	

table 8: Skeletal and dental diagnosis of patient included in the selected articles

Orthodontics treatments	Orthodontics and Surgery treatments	Surgery treatment only
<p>Pulgar Encinas, 2001</p> <p>1. reopening the space of the maxillary lateral incisors, correcting posterior cross bite, create posterior cross bite for prothetic rehabilitation, bracket and expansion with quad-helix and acrylic retainers for the missing teeth after orthodontic treatment.</p>	<p>Marçan G 2010:</p> <p>1- Orthodontic treatment: Levelling and aligning initially began with fixed appliances. The presurgery period was completed in 14 months.</p> <p>2- In the maxilla, the bimaxillary surgery comprised a 5.0-mm posterior impaction and a 5.0-mm anterior advancement; in the mandible, it involved a 5.0-mm set- back and counterclockwise rotation.</p> <p>3- Five months postsurgery, the orthodontic appliances were removed. Fixed retainers were bonded between the first premolars in the maxilla and mandible.</p>	<p>Apayadin A, 2014</p> <p>1.Le Fort I advancement osteotomy, intraoral distractors (that had been previously adapted to the patient's skull model) were placed at both sides of the maxilla, maxilla was distracted for 10 days</p> <p>2.consolidation period</p> <p>3.distractors were removed and implants inserted to the final sites. Implant sites with sufficient bone material had been previously selected using computed tomography data.</p> <p>4. Prosthetic phases</p>
<p>Kumar, 2009</p> <p>1. Orthodontic correction of the mandibular shift, unilateral posterior crossbite, and facial asymmetry. (. After two months of initial leveling, she was given a bonded hyrax for maxillary expansion because the patient refused surgical expansion of her maxilla, expansion: 12 days, consolidation: 3 months)</p>	<p>Gisler V, 2010:</p> <p>1- an orthodontic correction of tooth dislocations;</p> <p>2-a three-piece osteotomy in the upper jaw combined with a genioplasty to adjust sagittal, vertical, and transversal dimensions;</p> <p>3- a postsurgical orthodontic refinement;</p>	
<p>Varela Morels 2010:</p> <p>1.orthodontic treatment plan involved the extraction of two maxillary and two mandibular premolars, which would allow us to align the dental arches, retract the anterior teeth, and improve the interincisal angle while maintaining the Class I molar and canine relationships.</p> <p>2.sectional springs to retract the first premolars and then the canines, using a palatal bar as anchorage.</p> <p>3. Multibracket appliance</p>	<p>Ramos, 2011:</p> <p>1.Orthodontic preparation involved maxillary arch expansion (Hyrax expander followed by transpalatal bar) as well as alignment and leveling, in order to achieve better arch coordination prior to orthognathic surgery. ( 14 months)</p> <p>2. Orthognathic surgery was performed and the maxilla and mandible were moved forward. The mandible was rotated in a counterclockwise direction and a genioplasty was also performed.</p> <p>3. After 3 months : finishing phase of orthodontic treatment was accomplished.</p>	
<p>Yilmaz B, 2014:</p> <p>1. The orthodontic treatment was accomplished in seven months with the use of an edgewise fixed appliance with maxilla-mandibular anterior vertical elastics.</p>		

Table 9: Steps of treatments in each cases treated by orthodontic and/or surgery therapy.

## Serment d'Hippocrate modifié et actualisé pour les Médecins dentistes

Au moment d'être admis à exercer une profession médicale, je promets et je jure d'être fidèle aux lois de l'honneur et de la probité.

Mon premier souci sera de préserver, de promouvoir ou de rétablir la santé dans toutes ses dimensions, physique et mentale, personnelle et sociale.

Pour cela, je travaillerai en partenariat respectueux avec mes confrères et avec toutes les autres professions qui partagent les mêmes objectifs.

J'aiderai les autorités sanitaires dans leurs efforts pour préserver et améliorer la santé de la population.

Je ne permettrai pas que des considérations de religion, d'ethnie, de classe sociale ou de revenus viennent s'interposer entre mes patients et moi. Je donnerai mes soins à l'indigent et à quiconque me les demandera.

J'aurai comme objectif de prodiguer à mes patients les soins reconnus comme les plus efficaces par les sciences médicales du moment.

Je ne me laisserai pas influencer par la soif du gain.

Je préserverai l'indépendance nécessaire à l'accomplissement de ces missions.

Je n'entreprendrai rien qui dépasse mes compétences et je considérerai comme un devoir absolu de perfectionner sans cesse celles-ci.

Je respecterai toutes les personnes, et leur autonomie.

J'informerai les patients des décisions envisagées, de leurs raisons et de leurs conséquences.

Je tiendrai compte de leurs choix et de leurs préférences pour leur procurer la qualité de vie la meilleure.

Je ne ferai rien pour forcer leur conscience.

Je garderai à mes maîtres le respect et la reconnaissance qui leur sont dus.

J'apporterai mon aide à mes confrères ainsi qu'à leurs familles dans l'adversité.

Que les hommes et mes confrères m'accordent leur estime si je suis fidèle à mes promesses.

Que je sois couvert d'opprobre et méprisé si j'y manque.

HENRY Fanny – Prise en charge pluridisciplinaire du sens vertical squelettique et dentaire des patients atteints d'Amélogénèse Imparfaite isolée.

44 f., 11 ill., 9 tabl., 30 cm.- Thèse : Odontologie ; Rennes 1; 2018 ; N° 42.20.18.

Résumé français : L'Amélogénèse Imparfaite est une affection génétique héréditaire rare touchant la structure de l'émail en denture temporaire et permanente et est à l'origine d'anomalies squelettiques et dentaires ayant des conséquences notables sur la dimension verticale des patients atteints. L'objectif du travail est d'analyser les traitements proposés aux patients atteints d'Amélogénèse Imparfaite (AI) isolée, afin d'appréhender les possibilités de gestion du sens vertical de ces cas complexes, en fin de croissance. La revue a été entreprise à partir des bases de données PubMed en juin 2018. Les recherches ont permis de sélectionner seize cas cliniques de patients atteints d'AI dont la prise en charge thérapeutique et le diagnostic du sens vertical squelettique et/ou dentaire étaient décrits. L'analyse diagnostic des articles a révélé une augmentation de la dimension verticale squelettique et/ou dentaire et/ou une diminution de la dimension verticale d'occlusion (DVO). La prise en charge thérapeutique révèle que 100% des patients présentent une réhabilitation restauratrice complète. En amont, dépendamment du diagnostic et des besoins, les patients ont bénéficié de traitements en chirurgie orthognatique, orthodontie, parodontologie. Les anomalies du sens vertical d'origine basale ayant pour origine la croissance osseuse de la face sont traitées par chirurgie orthognatique. L'orthodontie permet de gérer l'alignement dentaire et le traitement des malocclusions d'origine alvéolo-dentaires en minimisant les délabrements dentaires. La parodontologie permet d'aménager, par soustraction, l'espace prothétique nécessaire. La réhabilitation restauratrice permet d'augmenter la DVO, de protéger les substances dentaires et de satisfaire les doléances esthétiques. Les restaurations indirectes répondent avec succès à ces exigences. Les restaurations minimalement invasives sont de plus en plus considérées mais leur faisabilité dépendant du type, de l'anomalie et requièrent des résultats supplémentaires en terme de protocole clinique et de longévité.

Rubrique de classement : Odontologie, Orthopédie Dento-Faciale, Odontologie Conservatrice, Prothèse.

Mots-clés : Amélogénèse Imparfaite ; Dimension verticale ; Traitement pluridisciplinaire ; Réhabilitation ; Revue de littérature.

Mots-clés anglais MeSH : Amelogenesis Imperfecta, Vertical dimension, Malocclusion.

Président : Monsieur le Professeur SOREL Olivier

JURY :

Assesseeurs : Monsieur le Docteur BREZULIER Damien [directeur de thèse]

Monsieur le Professeur SIXOU Jean-Louis

Madame le Docteur LE CLERC Justine

Monsieur le Docteur CARDONA Julien