



HAL
open science

The diagnostic workup in children with arthrogryposis multiplex congenita: description of practices through a monocentric cohort and suggestion of recommendations

Pauline Le Tanno

► To cite this version:

Pauline Le Tanno. The diagnostic workup in children with arthrogryposis multiplex congenita: description of practices through a monocentric cohort and suggestion of recommendations. Human health and pathology. 2020. dumas-02491483

HAL Id: dumas-02491483

<https://dumas.ccsd.cnrs.fr/dumas-02491483v1>

Submitted on 26 Feb 2020

HAL is a multi-disciplinary open access archive for the deposit and dissemination of scientific research documents, whether they are published or not. The documents may come from teaching and research institutions in France or abroad, or from public or private research centers.

L'archive ouverte pluridisciplinaire **HAL**, est destinée au dépôt et à la diffusion de documents scientifiques de niveau recherche, publiés ou non, émanant des établissements d'enseignement et de recherche français ou étrangers, des laboratoires publics ou privés.



AVERTISSEMENT

Ce document est le fruit d'un long travail approuvé par le jury de soutenance et mis à disposition de l'ensemble de la communauté universitaire élargie.

Il n'a pas été réévalué depuis la date de soutenance.

Il est soumis à la propriété intellectuelle de l'auteur. Ceci implique une obligation de citation et de référencement lors de l'utilisation de ce document.

D'autre part, toute contrefaçon, plagiat, reproduction illicite encourt une poursuite pénale.

Contact au SID de Grenoble :
bump-theses@univ-grenoble-alpes.fr

LIENS

Code de la Propriété Intellectuelle. articles L 122. 4
Code de la Propriété Intellectuelle. articles L 335.2- L 335.10

<http://www.cfcopies.com/juridique/droit-auteur>

Année : 2020

**THE DIAGNOSTIC WORKUP IN CHILDREN WITH ARTHROGRYPOSIS
MULTIPLEX CONGENITA : DESCRIPTION OF PRACTICES THROUGH A
MONOCENTRIC COHORT AND SUGGESTION OF RECOMMENDATIONS.**

THÈSE
PRÉSENTÉE POUR L'OBTENTION DU TITRE DE DOCTEUR EN MÉDECINE

DIPLÔME D'ÉTAT

Pauline LE TANNO

[Données à caractère personnel]

THÈSE SOUTENUE PUBLIQUEMENT À LA FACULTÉ DE MÉDECINE DE GRENOBLE

Le : 10 février 2020

DEVANT LE JURY COMPOSÉ DE

Président du jury :

Monsieur le Professeur Pierre-Simon JOUK

Membres :

Monsieur le Professeur Dominic PÉRENNOU

Madame le Docteur Véronique BOURG

Monsieur le Docteur Julien FAURÉ

Monsieur le Docteur Klaus DIETERICH, Directeur de thèse

L'UFR de Médecine de Grenoble n'entend donner aucune approbation ni improbation aux opinions émises dans les thèses ; ces opinions sont considérées comme propres à leurs auteurs.

Doyen de la Faculté : Pr. Patrice MORAND

Année 2019-2020

ENSEIGNANTS DE L'UFR DE MEDECINE

CORPS	NOM-PRENO	Discipline universitaire
PU-PH	ALBALADEJO Pierre	Anesthésiologie-réanimation et médecine péri-opératoire
PU-PH	APEL Florent	Ophthalmologie
PU-PH	ARVIEUX-BARTHELEMY Catherine	Chirurgie viscérale et digestive
PU-PH	BAILLET Athan	Rhumatologie
PU-PH	BARONE-ROCHETTE Gilles	Cardiologie
PU-PH	BAYAT Sam	Physiologie
MCF Ass.MG	BENDAMENE Farouk	Médecine Générale
PU-PH	BENHAMOU Pierre Yves	Endocrinologie, diabète et maladies métaboliques
PU-PH	BERGER François	Biologie cellulaire
MCU-PH	BIDART-COUTTON Marie	Biologie cellulaire
PU-PH	BLAISE Sophie	Chirurgie vasculaire ; médecine vasculaire
MCU-PH	BOISSET Sandrine	Bactériologie-virologie
PU-PH	BOLLA Michel	Cancérologie-Radiothérapie
PU-PH	BONAZ Bruno	Gastroentérologie, hépatologie, addictologie
PU-PH	BONNETERRE Vincent	Médecine et santé au travail
PU-PH	BOREL Anne-Laure	Nutrition
PU-PH	BOSSON Jean-Luc	Biostatistiques, informatique médicale et technologies de communication
MCU-PH	BOTTARI Serge	Biologie cellulaire
PR Ass.MG	BOUCHAUD Jacques	Médecine Générale
PU-PH	BOUGEROL Thierry	Psychiatrie d'adultes
PU-PH	BOUILLET Laurence	Médecine interne
MCU-PH	BOUSSAT Bastien	Epidémiologie, économie de la santé et prévention
PU-PH	BOUZAT Pierre	Anesthésiologie-réanimation et médecine péri-opératoire
PU-PH	BRAMBILLA Christian	Pneumologie
PU-PH	BRAMBILLA Elisabeth	Anatomie et cytologie pathologiques
MCU-PH	BRENIER-PINCHART Marie Pierre	Parasitologie et mycologie
PU-PH	BRICAULT Ivan	Radiologie et imagerie médicale
PU-PH	BRICHON Pierre-Yves	Chirurgie thoracique et cardiovasculaire
MCU-PH	BRIOT Raphaël	Thérapeutique-médecine de la douleur
MCU-PH	BROUILLET Sophie	Biologie et médecine du développement et de la reproduction
PU-PH	CAHN Jean-Yves	Hématologie
PU-PH	CARPENTIER Patrick	Chirurgie vasculaire, médecine vasculaire
PR Ass.MG	CARRILLO Yannick	Médecine Générale
PU-PH	CESBRON Jean-Yves	Immunologie
PU-PH	CHABARDES Stephan	Neurochirurgie
PU-PH	CHABRE Olivier	Endocrinologie, diabète et maladies métaboliques
PU-PH	CHAFFANJON Philippe	Anatomie

CORPS	NOM-PRENOM	Discipline universitaire
PU-PH	CHARLES Julie	Dermato-vénéréologie
MCF Ass.MG	CHAUVET Marion	Médecine Générale
PU-PH	CHAVANON Olivier	Chirurgie thoracique et cardio- vasculaire
PU-PH	CHIQUET Christophe	Ophthalmologie
PU-PH	CHIRICA Mircea	Chirurgie viscérale et digestive
PU-PH	CINQUIN Philippe	Biostatistiques, informatique médicale et technologies de communication
MCU-PH	CLAVARINO Giovanna	Immunologie
PU-PH	COHEN Olivier	Histologie, embryologie et cytogénétique
PU-PH	COURVOISIER Aurélien	Chirurgie infantile
PU-PH	COUTTON Charles	Génétique
PU-PH	COUTURIER Pascal	Gériatrie et biologie du vieillissement
PU-PH	CRACOWSKI Jean-Luc	Pharmacologie fondamentale, pharmacologie clinique
PU-PH	CURE Hervé	Cancérologie
PU-PH	DEBATY Guillaume	Médecine d'Urgence
PU-PH	DEBILLON Thierry	Pédiatrie
PU-PH	DECAENS Thomas	Gastro-entérologie, Hépatologie
PU-PH	DEMATTEIS Maurice	Addictologie
PU-PH	DEMONGEOT Jacques	Biostatistiques, informatique médicale et technologies de communication
MCU-PH	DERANSART Colin	Physiologie
PU-PH	DESCOTES Jean-Luc	Urologie
PU-PH	DETANTE Olivier	Neurologie
MCU-PH	DIETERICH Klaus	Génétique
MCU-PH	DOUTRELEAU Stéphane	Physiologie
MCU-PH	DUMESTRE-PERARD Chantal	Immunologie
PU-PH	EPAULARD Olivier	Maladies infectieuses ; Maladies tropicales
PU-PH	ESTEVE François	Biophysique et médecine nucléaire
MCU-PH	EYSSERIC Hélène	Médecine légale et droit de la santé
PU-PH	FAUCHERON Jean-Luc	Chirurgie viscérale et digestive
MCU-PH	FAURE Julien	Biochimie et biologie moléculaire
PU-PH	FERRETTI Gilbert	Radiologie et imagerie médicale
PU-PH	FEUERSTEIN Claude	Physiologie
PU-PH	FONTAINE Éric	Nutrition
PU-PH	FRANCOIS Patrice	Epidémiologie, économie de la santé et prévention
MCU-MG	GABOREAU Yoann	Médecine Générale
PU-PH	GARBAN Frédéric	Hématologie ; Transfusion
PU-PH	GAUDIN Philippe	Rhumatologie
PU-PH	GAVAZZI Gaétan	Gériatrie et biologie du vieillissement
PU-PH	GAY Emmanuel	Neurochirurgie
MCU-PH	GILLOIS Pierre	Biostatistiques, informatique médicale et technologies de communication
PU-PH	GIOT Jean-Philippe	Chirurgie plastique, reconstructrice et esthétique
MCU-PH	GRAND Sylvie	Radiologie et imagerie médicale
PU-PH	GRIFFET Jacques	Chirurgie infantile
MCU-PH	GUZUN Rita	Nutrition
PU-PH	HAINAUT Pierre	Biochimie et biologie moléculaire
PU-PH	HALIMI Serge	Nutrition
PU-PH	HENNEBICQ Sylviane	Biologie et médecine du développement et de la reproduction
PU-PH	HOFFMANN Pascale	Gynécologie-obstétrique

CORPS	NOM-PRENOM	Discipline universitaire
PU-PH	HOMMEL Marc	Neurologie
PU-MG	IMBERT Patrick	Médecine Générale
PU-PH	JOUK Pierre-Simon	Génétique
PU-PH	KAHANE Philippe	Physiologie
MCU-PH	KASTLER Adrian	Radiologie et imagerie médicale
PU-PH	KRAINIK Alexandre	Radiologie et imagerie médicale
PU-PH	LABARERE José	Epidémiologie, économie de la santé et prévention
MCU-PH	LABLANCHE Sandrine	Endocrinologie, diabète et maladies métaboliques
MCU-PH	LANDELLE Caroline	Bactériologie – virologie ; Hygiène hospitalière
PU-PH	LANTUEJOU Sylvie	Anatomie et cytologie pathologiques
MCU-PH	LARDY Bernard	Biochimie et biologie moléculaire
MCU - PH	LE GOUELLEC Audrey	Biochimie et biologie moléculaire
PU-PH	LECCIA Marie-Thérèse	Dermato-vénérologie
MCF Ass.MG	LEDOUX Jean-Nicolas	Médecine Générale
PU-PH	LEROY Vincent	Gastroentérologie ; hépatologie ; addictologie
PU-PH	LETOUBLON Christian	Chirurgie viscérale et digestive
PU-PH	LEVY Patrick	Physiologie
PU-PH	LONG Jean-Alexandre	Urologie
MCU-PH	LUPO Julien	Bactériologie-virologie
PU-PH	MAGNE Jean-Luc	Chirurgie vasculaire ; Médecine vasculaire
MCU-PH	MAIGNAN Maxime	Médecine d'urgence
PU-PH	MAITRE Anne	Médecine et santé au travail
MCU-PH	MALLARET Marie-Reine	Hygiène hospitalière
PU-PH	MALLION Jean-Michel	Cardiologie
MCU-PH	MARLU Raphaël	Hématologie ; Transfusion
MCU-PH	MAUBON Danièle	Parasitologie et mycologie
PU-PH	MAURIN Max	Bactériologie-virologie
MCU-PH	MC LEER Anne	Histologie, embryologie et cytogénétique
MCU-PH	MONDET Julie	Histologie, embryologie et cytogénétique
PU-PH	MORAND Patrice	Bactériologie-virologie
PU-PH	MOREAU-GAUDRY Alexandre	Biostatistiques, informatique médicale et technologies de communication
PU-PH	MORO Elena	Neurologie
PU-PH	MORO-SIBILOT Denis	Pneumologie
MCU-PH	MORTAMET Guillaume	Pédiatrie
PU-PH	MOUSSEAU Mireille	Cancérologie
PU-PH	MOUTET François	Chirurgie plastique, reconstructrice et esthétique ; brûlologie
MCF Ass.MG	ODDOU Christel	Médecine Générale
MCU-PH	PACLET Marie-Hélène	Biochimie et biologie moléculaire
PU-PH	PAILHE Régis	Chirurgie orthopédique et traumatologie
PU-PH	PALOMBI Olivier	Anatomie
PU-PH	PARK Sophie	Hématologie ; Transfusion
PU-PH	PASSAGGIA Jean-Guy	Anatomie
PR Ass.MG	PAUMIER-DESBRIERES Françoise	Médecine Générale
PU-PH	PAYEN DE LA GARANDERIE Jean-François	Anesthésiologie-réanimation et médecine péri-opératoire
MCU-PH	PAYSANT François	Médecine légale et droit de la santé
MCU-PH	PELLETIER Laurent	Biologie cellulaire
PU-PH	PELLOUX Hervé	Parasitologie et mycologie

CORPS	NOM-PRENOM	Discipline universitaire
PU-PH	PEPIN Jean-Louis	Physiologie
PU-PH	PERENNOU Dominique	Médecine physique et de réadaptation
PU-PH	PERNOD Gilles	Médecine vasculaire
PU-PH	PIOLAT Christian	Chirurgie infantile
PU-PH	PISON Christophe	Pneumologie
PU-PH	PLANTAZ Dominique	Pédiatrie
PU-PH	POIGNARD Pascal	Bactériologie-virologie
PU-PH	POLACK Benoît	Hématologie
PU-PH	POLOSAN Mircea	Psychiatrie d'adultes
PU-PH	RAMBEAUD Jean-Jacques	Urologie
PU-PH	RAY Pierre	Biologie et médecine du développement et de la reproduction
MCU-PH	RENDU John	Biochimie et biologie moléculaire
MCU-PH	RIALLE Vincent	Biostatistiques, informatique médicale et technologies de communication
PU-PH	RIETHMULLER Didier	Gynécologie-obstétrique ; gynécologie médicale
PU-PH	RIGHINI Christian	Oto-rhino-laryngologie
PU-PH	ROMANET Jean Paul	Ophthalmologie
PU-PH	ROSTAING Lionel	Néphrologie
MCU-PH	ROUSTIT Matthieu	Pharmacologie fondamentale ; pharmacologie clinique ; addictologie
MCU-PH	ROUX-BUISSON Nathalie	Biochimie et biologie moléculaire
MCF Ass.MG	ROYER DE VERICOURT Guillaume	Médecine Générale
MCU-PH	RUBIO Amandine	Pédiatrie
PU-PH	SARAGAGLIA Dominique	Chirurgie orthopédique et traumatologie
MCU-PH	SATRE Véronique	Génétique
PU-PH	SAUDOU Frédéric	Biologie cellulaire
PU-PH	SCHMERBER Sébastien	Oto-rhino-laryngologie
PU-PH	SCHWEBEL Carole	Médecine intensive-réanimation
PU-PH	SCOLAN Virginie	Médecine légale et droit de la santé
MCU-PH	SEIGNEURIN Arnaud	Epidémiologie, économie de la santé et prévention
PU-PH	STAHL Jean-Paul	Maladies infectieuses ; Maladies tropicales
PU-PH	STANKE Françoise	Pharmacologie fondamentale
MCU-PH	STASIA Marie-José	Biochimie et biologie moléculaire
PU-PH	STURM Nathalie	Anatomie et cytologie pathologiques
PU-PH	TAMISIER Renaud	Physiologie
PU-PH	TERZI Nicolas	Médecine intensive-réanimation
MCU-PH	TOFFART Anne-Claire	Pneumologie
PU-PH	TONETTI Jérôme	Chirurgie orthopédique et traumatologie
PU-PH	TOUSSAINT Bertrand	Biochimie et biologie moléculaire
PU-PH	VANZETTO Gérald	Cardiologie
PU-PH	VUILLEZ Jean-Philippe	Biophysique et médecine nucléaire
PU-PH	WEIL Georges	Epidémiologie, économie de la santé et prévention
PU-PH	ZAOUI Philippe	Néphrologie
PU-PH	ZARSKI Jean-Pierre	Gastroentérologie ; hépatologie ; addictologie

PU-PH : Professeur des Universités - Praticiens Hospitaliers
MCU-PH : Maître de Conférences des Universités - Praticiens Hospitaliers
PU-MG : Professeur des Universités de Médecine Générale
MCU-MG : Maître de Conférences des Universités de Médecine Générale
PR Ass.MG : Professeur des Universités Associé de Médecine Générale
MCF Ass.MG : Maître de Conférences Associé de Médecine Générale

TABLE DES MATIÈRES

REMERCIEMENTS.....	7
LISTE DES ABRÉVIATIONS.....	9
LISTE DES TABLEAUX ET FIGURES.....	11
RÉSUMÉ.....	12
ABSTRACT.....	13
INTRODUCTION.....	14
1. Definition and Epidemiology.....	14
2. Causes and classification.....	15
3. Context and purpose.....	19
MATERIALS AND METHODS.....	21
1. Protocol registration.....	21
2. Cohort building.....	22
3. Data collection.....	23
4. Patients' classification.....	23
5. Data analysis in the light of information provided by scientific literature.....	24
RESULTS.....	26
1. Cohort constitution.....	26
2. Etiologies of AMC.....	27
2.A/ Group 1 : Amyoplasia.....	27
3.B/ Group 2 : distal arthrogyriposis.....	27
3.C/ Group 3 : other patients.....	30
3. Paraclinical investigations performed and results.....	31
3.A/ Other genetic investigations.....	31
3.B/ Other biological investigations.....	32
3.C/ Neuromuscular investigations.....	34
3.D/ Central Nervous System investigations.....	37
3.E/ Associated organ impairment assessment.....	39
DISCUSSION.....	42
1. Comparison of our cohort with literature of AMC patients.....	42
2. AMC diagnostic assessment : delineating indications for each investigation.....	45
2.A/ Widely performed and non-invasive investigations.....	45
2.B/ CNS explorations (cMRI, tcUS, EEG) are indicated for group 3C only.....	47
2.C/ Neuromuscular explorations (MB, ENMG) are invasive and of poor interest.....	49
2.D/ Reflection about spinal cord explorations (scMRI, scUS).....	50
2.E/ More rarely performed investigation that require specific indications.....	52
3. AMC diagnostic assessment : synthesis of recommendations.....	57
4. Limits of this study.....	61
CONCLUSION.....	64
REFERENCES.....	67
SUPPLEMENTAL DATA.....	75
SERMENT D'HIPPOCRATE.....	84

REMERCIEMENTS

À Monsieur le Professeur Pierre-Simon JOUK. Je vous remercie de me faire l'honneur d'être le président de ce jury, afin de commenter ce travail centré sur une pathologie pour laquelle vous avez fait beaucoup. Je vous remercie également pour votre bienveillance et votre humanité qui ont accompagné le début de mon internat.

À Monsieur le Docteur Klaus DIETERICH. Merci de m'avoir proposé ce sujet, ambitieux mais essentiel. Merci pour ta patience, pour avoir répondu à mes nombreuses sollicitations y compris sur ton temps personnel.

À Monsieur le Professeur Julien FAURÉ. Merci d'accepter de relire ce travail. La qualité des interactions entre la génétique clinique et la biologie moléculaire, surtout dans le domaine de l'arthrogrypose, constitue une part essentielle de la prise en charge de nos patients.

À Madame le Docteur Véronique BOURG. Je te remercie également d'avoir accepté cette relecture. La MPR constitue en soi un pilier fondamental du bilan arthrogrypose, mais ton énergie et ton expérience le renforcent.

À Monsieur le Professeur Dominic PÉRENNOU. Merci d'accepter de relire ce travail. Merci également pour votre soutien dans la promotion des nombreux projets communs aux équipes de MPR et de génétique.

À mes parents, de m'avoir encouragée si tenacement, et de m'avoir hébergé pour mes longues heures de révisions qui ont émaillé mon cursus universitaire. Merci pour votre affection et votre fierté qui sont mes guides.

À ma sœur, mon frère : la petite dernière a enfin fini ses études !

À mes beaux-parents, pour m'accueillir avec autant de générosité et m'accepter comme leur fille.

À mes amis de médecine, le groupe grenoblois d'abord, David et Morgane et leur future mite, Flora et Olivier, Valérie et Grégoire, Floriane et Charlie, Claire, Pauline. Double merci à Floriane pour sa relecture !! Au groupe parisien aussi, qui m'a soutenue sur mes dernières semaines de travail intensif, Pauline, Alix et Reaksmei. Sans oublier les exilés bretons, Florie, ou bisontins, Océane et Clément. Je suis ravie d'avoir passé toutes ces années avec vous, un chemin semé d'épreuves (spéciale pensée au super groupe de conf) mais aussi de supers souvenirs (vive le MDB). Je suis super fière de voir les médecins et personnes que vous êtes devenus, vous assurez.

Il en va de même, bien sûr, pour mes amis anciens médecins, Armelle, éduc spé, Pinki, et pharmaciens, Momo et Natacha, dont l'amitié est d'une importance toute aussi capitale.

À mes plus vieux amis, qui suivez ça de loin, mention spéciale à Cécile et Nora.

À mon ancien co-interne Brice, toujours là pour répondre à mes (nombreuses) questions, et mon seul repère dans cette aventure grenobloise.

À mes co-internes de génétique à travers la France, Pauline, Marine, Julian, Simon et tant d'autres ; plus largement à la SIGF, qui m'a été d'un soutien indispensable.

À mes autres co-internes croisés dans des stages hors génétiques ou inter-CHU, merci notamment à mes co-internes de Necker, dont la bonne humeur m'a aidé à traverser ces quelques semaines difficiles.

À Charles, Françoise, Véronique et Julien d'avoir encadré mes travaux tout au long de mon externat puis de mon internat. À Florence, Radu, plus récemment Isabelle. Merci à tous pour votre accueil, votre enseignement. Traverser cet internat à vos côtés a été un plaisir.

À l'équipe de biologie moléculaire, qui m'a accueillie 6 mois, merci notamment à Nathalie pour sa pédagogie et sa gentillesse, à John et Xenia pour leur implication dans les arthrogyposes.

À tout le service de génétique, des secrétaires aux techniciens en passant par les ingénieurs, les conseillères en génétique, ARC et psychologue. À Gipsy, Marjolaine et Emmanuelle, indispensables au bon fonctionnement du Centre de référence Arthrogypose.

À tous les médecins de l'HCE, neuropédiatres et MPR aux premières loges. Aux rééducateurs de MPR, Claire et Véronique, équipe de choc.

À l'équipe du GETI, qui m'a accueillie pendant mon M2.

À tous les patients qui font l'objet de ce travail, et leur famille. À l'Association Alliance Arthrogypose, leur énergie et leur force. Les week-ends de l'association sont pour moi des souvenirs précieux.

Et surtout à mon Hadri, futur mari et relecteur attentif de toutes les thèses, merci pour ton aide si précieuse, ta patience infinie, et ton amour tout aussi infini je l'espère. J'ai une chance inouïe.

LISTE DES ABRÉVIATIONS

AAA	Association Alliance Arthrogrypose
AChR	Acetylcholine Receptor
AFM	Active Foetal Movements
AMC	Arthrogryposis Multiplex Congenita
AMC-NGS	Next Generation Sequencing of genes involved in AMC
C	Central nervous system involvement
CBD	Congenital Bone Disorders
CGH	Comparative Genomic Hybridization
CK	Creatine Kinase
cMRI	Cerebral Magnetic Resonance Imaging
CNS	Central Nervous System
CNV	Copy Number Variant
DA	Distal Arthrogryposis
EEG	Electroencephalogram
EKG	Electrocardiogram
ENMG	Electroneuromyography
FADS	Foetal Akinesia Deformation Sequence
ID	Intellectual Disability
IUFD	Intra Uterine Foetal Death
LRP4	Low-density lipoprotein Receptor-related Protein 4
M	Muscle
MB	Muscle biopsy
MCC	Multiple Congenital Contractures
MD1	Myotonic Dystrophy type 1
MG	Myasthenia Gravis
mMRI	Muscle Magnetic Resonance Imaging
MRC	Mitochondrial Respiratory Chain
MRI	Magnetic Resonance Imaging
MuSK	Muscle Specific Kinase
NGS	Next Generation Sequencing

NMD	Neuromuscular Diseases
NMD-NGS	Next Generation sequencing of genes involved in neuromuscular diseases
NMJ	Neuromuscular Junction
O	Other
PCH	Ponto-Cerebellar Hypoplasia
PN	Peripheral Nerve
PWS	Prader-Willi Syndrome
scMRI	Spinal cord Magnetic Resonance Imaging
scUS	Spinal cord Ultrasonography
SMA	Spinal Muscular Atrophy
SMALED	SMA with Lower Extremity predominance
TCS	Tethered Cord Syndrome
tcUS	Transcranial Ultrasonography
TNMG	Transient Neonatal Myasthenia Gravis
TOP	Termination of Pregnancy
U	Unknown
US	Ultrasonography
VUS	Variant of Unknown Significance
WES	Whole Exome Sequencing
WG	Weeks of Gestation
WGS	Whole Genome Sequencing

LISTE DES TABLEAUX ET FIGURES

Table 1	Typical Amyoplasia criteria.....	17
Table 2	Distal arthrogryposis classification.....	18
Table 3	Epidemiological information.....	26
Table 4	Paraclinical investigations performed for diagnostic purposes	33
Table 5	Anomalies observed on muscle biopsy examination.....	36
Table 6	Detailed anomalies observed on electroneuromyography.....	36
Table 7	Details on anomalies reported on cMRI and/or tcUS.....	38
Table 8	Details on anomalies observed on spinal cord imaging.....	39
Table 9	Details on anomalies reported in cardiological explorations.....	41
Table 10	Details on anomalies observed on abdominal ultrasonography.....	41
Figure 1	Simplified scheme of causes and consequences of decreased AFM.....	16
Figure 2	Main steps of present study protocol.....	21
Figure 3	Possible diagnosis in Group 3 with (C) or without (O) CNS involvement.....	25
Figure 4	Flowchart of the study and detailed molecular diagnoses obtained in group 2 and 3..	28
Figure 5	Pictures of AMC patients of our cohort.....	29
Figure 6	Proposition of recommendations in the aetiological assessment of AMC children.....	58
Figure S1	Study information note destined to patients.....	75
Table S1	Features that led to the diagnosis of atypical Amyoplasia.....	77
Table S2	List of the 121 NMD-related genes sequenced in CHU Grenoble-Alpes laboratory.....	78
Table S3	Indications that had motivated prenatal karyotypes.....	79
Table S4	Detailed karyotype and array-CGH results (postnatal).....	80
Table S5	Other Cytogenetic analyses performed in our cohort.....	80
Table S6	Other targeted analyses performed in our cohort.....	81
Table S7	Abnormal creatine kinase dosage results.....	81
Table S8	Details on metabolic investigations performed in our patients.....	82
Table S9	Details on anomalies observed on electroencephalogram.....	82
Table S10	Metabolic disorders associated with AMC.....	83

RÉSUMÉ

Titre : Le parcours diagnostique des enfants atteints d'Arthrogrypose Multiple Congénitale : description des pratiques actuelles à travers une cohorte monocentrique, et proposition de recommandations.

Introduction: L'Arthrogrypose Multiple Congénitale (AMC) correspond à des limitations articulaires touchant au moins deux niveaux. Sa prévalence est estimée entre 1/3000 et 1/12000. Le diagnostic étiologique est difficile car il en existe plus de 400 causes. L'objectif de ce travail est de décrire le parcours diagnostique des enfants atteints d'AMC et de proposer des recommandations afin d'optimiser les pratiques cliniques.

Matériel et méthodes: Nous avons mené une étude rétrospective observationnelle monocentrique, incluant les enfants évalués au Centre Hospitalier Universitaire de Grenoble de 2007 à 2019. Nous avons collecté les informations sur leur parcours diagnostique, puis avons mené une revue de la littérature pour chaque investigation paraclinique afin d'évaluer la pertinence à la lumière du diagnostic final des patients, des connaissances scientifiques, de leur bénéfices, risques et coûts.

Résultats: Nous avons inclus un total de 125 patients, dont 43% cas d'Amyoplasie, 26% d'arthrogrypose distale et 31% d'autres formes. Un diagnostic étiologique était posé dans 63% des cas. Nous proposons une procédure diagnostique en deux temps: d'abord des investigations non invasives permettant d'orienter les patients vers l'un des trois groupes principaux, puis des investigations plus spécifiques avec des indications précises, en fonction de leur rendement attendu et de leur caractère invasif.

Conclusion: L'approche diagnostique des enfants avec AMC doit résulter d'un travail pluridisciplinaire. L'utilisation croissante du séquençage de nouvelle génération facilitera cette démarche, mais le phénotypage restera essentiel pour guider leur interprétation.

Mots-clefs: Arthrogrypose Multiple Congénitale, démarche diagnostique, cohorte pédiatrique

ABSTRACT

Title: The diagnostic workup in children with Arthrogryposis Multiplex Congenita: description of practices through a monocentric cohort and suggestion of recommendations.

Introduction: Arthrogryposis multiplex congenita (AMC) defines congenital contractures involving two or more body areas. The prevalence is estimated between 1/3000 and 1/12000. More than 400 conditions may lead to AMC through foetal hypo/a-kinesia, making the aetiological diagnosis challenging. The objective of this work was to describe the aetiological management of children with AMC and to propose recommendations in order to optimize clinical practices.

Material and methods: We conducted a retrospective single centre observational study. Patients had been evaluated at least once at a paediatric age in Grenoble University Hospital from 2007 to 2019. After determining the diagnostic status of these patients, data on their diagnostic procedure were gathered. A literature review was performed for each paraclinical investigation to discuss their relevance in the light of patients' diagnoses, scientific knowledge, and benefit/risk or cost/benefit ratio.

Results: 125 patients were included, 43% had Amyoplasia, 26% had distal arthrogryposis, and 31% had other forms. A definitive aetiological diagnosis was available for 63% of cases. We propose a two-time diagnostic process : first, non-invasive investigations that aim at classifying patients into one of the three groups, and then specific investigations targeting a subset of patients according to the expected yield and invasiveness.

Conclusion: The diagnostic management of AMC patients has to result from a multidisciplinary approach. With the use of next generation sequencing, the aetiological assessment will be facilitated, but a relevant phenotyping will be paramount to guide their interpretation.

Keywords: Arthrogryposis Multiplex Congenita, diagnostic assessment, paediatric cohort.

INTRODUCTION

1. Definitions and epidemiology

Etymologically, the term “Arthrogryposis” results from the association of the Greek words “arthron” (joints), “gryp” (curved) and “osis” (condition) and points to joint contractures with limited range of motion. The Latin term “Arthrogryposis Multiplex Congenita” (AMC) used alternatively with the term “Multiple Congenital Contractures” (MCC), more specifically defines a congenital arthrogryposis, involving at least two body areas (1–3). Contractures are typically symmetric and although they do not progress to unaffected joints, they may change in amplitude under the influence of growth and treatment (2).

Although AMC has been first defined as a condition *per se*, it is now admitted as a descriptive term to define a symptom, common to a group of heterogeneous congenital conditions (4). Depending on the cause, contractures location and severity may vary, as well as the primary involvement of spine and jaw, or the existence of muscle weakness in the involved body area. AMC can be either isolated or associated to other body systems impairment such as central nervous system (CNS) as well as respiratory, gastrointestinal and genitourinary systems. Prognostic factors like response to treatment, importance of deficits, activity limitation, participation restriction but also neurodevelopment and even life expectancy may differ widely according to the aetiology (2).

As true prevalence estimation remains challenging, it is thought to stand around 1/3000-1/12000 (5–7). AMC is thus a rare affection, in contrast with isolated congenital contractures such as congenital clubfeet that affect 1/500 individuals (1).

2. Causes and classification

The common underlying cause of AMC is foetal hypokinesia or decreased active foetal movement (AFM) (4). AFM begin around 5 or 6 weeks of gestation (WG) and are essential for the further development of joints. Independently of the underlying cause, their absence may lead to connective tissue deposition around joints and stretching of tendons, increasing mobility reduction and resulting in contractures, whose severity depends on the earliness of hypokinesia (8,9). Foetal hypokinesia leads to a variety of other secondary deformations, that thus can be encountered in all forms of AMC: craniofacial changes, pulmonary hypoplasia, polyhydramnios, decreased gut mobility and shortened gut, short umbilical cord, growth restriction and skin changes (4) (**Fig. 1**). The whole set of symptoms constitute the most severe form of AMC called foetal akinesia deformation sequence (FADS) or Pena-Shokeir syndrome, usually perinatally lethal (10).

More than 400 conditions causing foetal hypokinesia and thus AMC have been described (4). They can involve any part of the anatomical structures implicated in movement and include all causes of lack or excess of muscle contraction as well as mechanical restriction. They can be divided into two categories (11) (**Fig. 1**) :

- Extrinsic causes : intrauterine foetal space restriction (severe oligohydramnios, tumoral process, multiple pregnancy, uterine malformation), intrauterine vascular compromise or environmental conditions (maternal illness including infections and myasthenia gravis, maternal exposure to toxics, treatment or trauma)
- Intrinsic causes (foetal dysfunction) : myopathic process (congenital myopathies, congenital muscular dystrophies, myositis...), neuropathic process (CNS impairment with or without structural anomalies, peripheral nerves impairment including anterior horn cells diseases, myelin anomalies...), neuromuscular end-plate process, connective joint tissue abnormalities (restrictive dermopathies or cartilage/bone tissue disturbances) and metabolic diseases.

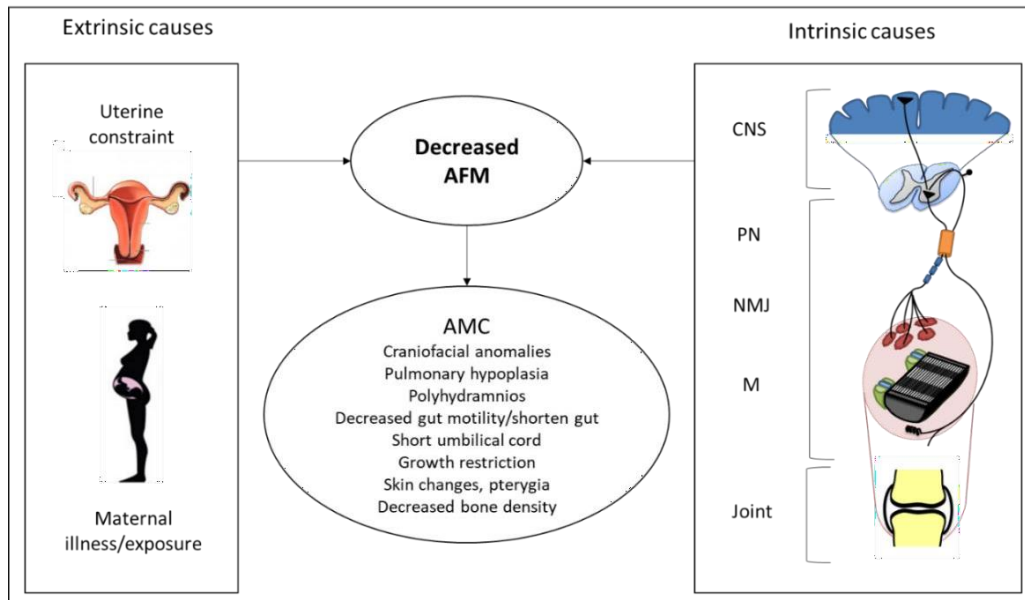


Figure 1. Simplified scheme of causes and consequences of decreased AFM.

Legends : AFM, Active foetal movements; AMC, Arthrogryposis Multiplex Congenita; CNS, central nervous system; M, muscle, NMJ, neuromuscular junction; PN, peripheral nerve.

Although a genetic origin is involved in most cases, the first cause of AMC, involved in 1/3 cases with an estimated prevalence of 1/10 000 individuals, is sporadic : Amyoplasia congenita (5,12) (**Table 1**). This entity, first described in 1840, is recognizable by the characteristic position of upper and lower limbs joints, absence of CNS involvement, absence of primary spinal and jaw involvement although spinal deformities can be present at birth as the consequence of foetal hypomobility and clinical muscle atrophy (3). Associated signs are common and include digestive anomalies, skin defects, loss of digits or limbs, and classic nevus flammeus of the midforehead (12). Muscular MRI (mMRI) typically evidences a reproducible pattern (manuscript submitted). A four limbs AMC arise in 60% of cases, while upper or lower limbs only account for 15% each (12). Orthopaedic outcome is very favourable especially in comparison with other anterior horn cell diseases (13). Indeed, on the basis of the observation of clinical similarities with Erb-Duchenne obstetrical palsy and electroneuromyographic studies, this disorder is thought to result from a neurogenic process, i.e. the impairment of the anterior horn cells of the spinal cord in early embryonic and foetal life, responsible for the underdevelopment of muscle tissue and further replacement by fatty or fibrous deposits. While the exact cause of this impairment is still unclear, the nature of the associated signs and discordance in monozygotic twins suggest an ischemic event, impacting the spinal cord at the level of upper and lower limbs expansion, i.e. motor roots C5-C6 and L2-L4 (12,14).

Clinical	Major criteria : <ul style="list-style-type: none"> - Sporadic - Symmetric (all 4 limbs or only UL/LL in a bilateral way) - Contractures distribution and joint positions : <ul style="list-style-type: none"> * UL : internal rotation of shoulders, extended elbows, pronation of the forearm, flexed wrist, adducted thumbs and camptodactyly * LL : severe equinovarus feet, no rocker bottom feet - Muscular atrophy (shoulder girdle muscles when UL involved) - Normal cognitive function, no sign of CNS involvement
	Minor criteria : <ul style="list-style-type: none"> - Shortness of affected limbs - Mild IUGR - Sparing the trunk - Dimples overlying involved joint - Lack of flexion creases on limbs, fingers, hands - Nevus flammeus over craniofacial midline - Gracile, osteoporotic long bones - Good response to physiotherapy
	Do not exclude the diagnosis : <ul style="list-style-type: none"> - Gastrointestinal impairment : abdominal wall defects, inguinal hernia, bowel atresia, gastroschisis - Skin defects - Loss of digits or limbs anomalies
Imaging	Absence or severe muscle atrophy of : <ul style="list-style-type: none"> - UL : biceps and brachialis muscles - LL : gracilis, sartorius and anterior tibialis muscles <p>Bone X-rays : Gracile, osteoporotic long bones</p>

Adapted from Hall et al., 2014 (12). *Legends* : CNS, central nervous system; IUGR, intra uterine growth retardation; LL, lower limbs; UL, upper limbs.

A group of affections called distal arthrogryposis (DA) represents another 1/5 to 1/3 of AMC individuals (15). First described in 1982, DA is a heterogeneous group of syndromes where AMC involve mainly hands (overriding fingers, camptodactyly or pseudocamptodactyly with hypoplasia of interphalangeal creases, ulnar deviation and/or wrist extension) and feet (talipes equinovarus, calcaneovalgus deformities, vertical talus, and/or metatarsus varus), with varying involvement of proximal joints. This arises in the absence of any primary neurological and/or muscle disease affecting limb function, with thus conserved muscle mass and cognitive function although muscle weakness and fatigability can occur. Familial cases are common, with classically a wide intrafamilial variability or even incomplete penetrance. Transmission is most often autosomal dominant. The DA group comprises ten different entities, among which many are clinically recognizable (16–18) (Table 2). Genes responsible for DA were the first described in link with AMC, as soon as 1995 for *FBN2* (19), and then for genes encoding sarcomeric muscle proteins like *TNNI2*, *TNNT3* and *TPM2*, also involved in congenital myopathies (20). Mechanisms of AMC in DA are various, either muscle weakness in sarcomeric and *ECEL1* forms, lack of relaxation in *PIEZO2* patients, or connective tissues dysfunction in *FBN2* (18,19,21,22).

Table 2. Distal arthrogryposis classification

Type	Name	Genes	Key distinguishing features	
DA1	Classic DA/digitotalar dysmorphism	<i>TNNI2</i> ¹ , <i>TNNT3</i> ¹ , <i>TPM2</i> ¹ , <i>MYH3</i> ² , <i>MYBPC1</i> ³	Extended wrists Flexed and overlapping fingers	No facial involvement
DA2A	Freeman-Sheldon syndrome	<i>MYH3</i> ²	Ulnar deviation Feet malposition (club feet/vertical talus)	Facial contractures, small pursed mouth, scoliosis
DA2B	Sheldon-Hall syndrome	<i>TNNI2</i> ¹ , <i>TNNT3</i> ¹ , <i>TPM2</i> ¹ , <i>MYH3</i> ²		Facial contractures less severe than in DA2A, MRI pattern (<i>TPM2</i>)
DA3	Gordon syndrome	<i>PIEZO2</i> ⁴	Cleft palate, blepharophimosis, ophthalmoplegia, painful muscle contractures, spine involvement with respiratory impairment, BMI<18/short stature, dimples	
DA4	DA with severe scoliosis	uk	Scoliosis	
DA5	DA with ophthalmoplegia, ptosis and retinal involvement	<i>PIEZO2</i> ⁴ , <i>ECEL1</i> ⁵	<i>ECEL1</i> : ptosis without ophthalmoplegia, groove tongue, extended knees, adducted thumbs, MRI pattern	
DA6	DA with sensorineural hearing loss and microcephaly	uk	Sensorineural hearing loss, microcephaly	
DA7	Trismus-pseudocamptodactyly syndrome/Hecht syndrome	<i>MYH8</i> ⁶	Trismus, facultative finger contractures	
DA8	AD Multiple pterygium syndrome	<i>MYH3</i> ⁷	Multiple pterygium	
DA9	CCA/Beals syndrome	<i>FBN2</i> ⁸	Arachnodactyly and camptodactyly, marfanoid habitus, ear deformity	
DA10	DA with congenital plantar flexion contractures	uk	Plantar flexion contractures	

From Bamshad et al., 2009 (16), Hall et al., 2017 (17) and Kimber et al., 2012 (18). Legends : AD, autosomal dominant; BMI, Body Mass index; CCA, congenital contractural arachnodactyly; DA, distal arthrogryposis; MRI, Magnetic Resonance Imaging; uk, unknown. ¹Sung et al., 2003 (20); ²Toydemir et al., 2006 (23), ³Gurnett et al., 2010 (24), ⁴Coste et al., 2013 (21), ⁵Dieterich et al., 2013 (22), ⁶Toydemir et al. 2006 (25), ⁷Chong et al., 2015 (26), ⁸Putnam et al., 1995 (19).

Apart from DA genes, more than 400 genes have been reported in association with AMC. Attempts to classify AMC forms according to genes function have been made, distributing these genes into 29 different groups standing for different pathways. However, as a single gene may be involved in more than one pathway, it may be classified in several groups. In addition, many genes may lead to distinct phenotypes with or without AMC, and conversely a single phenotype may be caused by different genes (27). Classification is thus arduous. Other classification systems are based on the aetiological process of foetal akinesia as previously cited. However, clinical classifications are most useful in daily practice. We can count two of them, both dividing AMC patients in 3 groups :

- the first one is the most used in the literature and distinguishes three categories of patients each accounting for 30% : primarily limb involvement (group I), musculoskeletal involvement associated with other system anomalies (group II), and musculoskeletal involvement associated with CNS dysfunction, intellectual disability (ID) or lethality (group III) (28).

- the other is much more rarely used but is of great interest for clinical practice and for family communication. It distinguishes two first groups accounting for more of the half of cases, Amyoplasia congenita and DA, plus another one where all other aetiologies are gathered (17).

No fully satisfying classification system exist, they all have their advantages and drawbacks. However, they may be a useful way to stratify the diagnostic strategy at first meet of a patient presenting with AMC.

3. Context and purpose

The identification of the aetiological diagnosis is of major importance in AMC, which arises either sporadically or may be inherited with all transmission mode possible (12). As most forms are severe, and as AMC is diagnosed at birth with parents in age of expanding their family, questions arise about reoccurrence risk for future pregnancies, and often for prenatal diagnosis. In addition, while exhaustive correlations are not established yet, elements of prognosis, treatment and follow-up optimisation can be provided according to the underlying cause. Last but not least, as for all rare conditions, patients and their families have often been through a long and thorough medical evaluation with a long diagnostic wavering, that may have had a significant psychological impact on individuals and structural consequences in families. Getting a diagnosis thus helps families to work through their thoughts and feelings, by providing an answer to their questions about the origin of their child's condition, by helping them to see more clearly their future, and by enabling them to get in touch with families who have a child affected with the same disease.

Considering that AMC remains rare and that causes are numerous and cover a wide spectrum of severity and clinical presentation, its aetiological diagnostic management is challenging. Together with the fact that clinicians in charge of AMC patients are from various medical specialties, their knowledge of diseases associated with AMC might be incomplete. Lastly, hitherto there is no uniform consensus guidelines regarding diagnostic check-up. All these elements may lead to heterogeneous medical practices and poor estimation of risk-benefit or cost-benefit balance of each diagnostic test, leading to a non-optimal diagnostic management of AMC patients.

Reference centres for rare diseases have been created to address this issue, common to all rare diseases. Grenoble University Hospital has been labelled in 2007 as one of the national reference centres for developmental anomalies and ID. In this context, our team has set up a dedicated consultation for AMC patients, first for children, then for adults. Paediatric dedicated workup comprises consultations with a clinical geneticist, a rehabilitation professional and an orthopaedic surgeon, full physical therapist and occupational therapist workup, psychological family evaluation and an imaging work-up when required. Thanks to the clinical experience acquired so far, the increasing recognition of this work by French clinicians, and due to the close relationship of our team with the national association of patient “Association Alliance Arthrogyrose” (AAA) created in 2005, this dedicated consultation attracts many patients across the country and abroad. As they first come to our centre with a medical diagnostic background, these patients nicely reflect diagnostic management of AMC in a national perspective. Adding to these patients those who have a local follow-up in Grenoble, we have now built a large cohort of AMC patients of various aetiologies.

Among authors that propose diagnostic management recommendations, only few drew their conclusions on the basis of a cohort description, a convenient way to adapt recommendations to existing practices. In addition, these publications are either too ancient, or their cohort present a selection bias, are of small size or include a large part of perinatally lethal cases (29,8,30,31).

The aim of this work was thus to describe our single centre cohort of AMC children patients gathered from 2007 to 2019, with the first objective of drawing a picture of the aetiologies found in our patients. In the light of this, the second goal was to redraw their genetic and paraclinical diagnostic work-up, in order to evaluate the relevance of each test with the help of information available in the literature, looking forward to proposing practices guidelines for clinicians to optimize AMC patients’ diagnostic management.

MATERIAL AND METHODS

We conducted a retrospective single centre observational study in a cohort of AMC paediatric patients, with the aim of redrawing their diagnostic process in order to evaluate each investigation in comparison with available information in the literature.

1/ Protocol registration

Standard protocol of the study (Fig. 2), was submitted and approved by the Grenoble-Alpes University hospital research section, who proceeded to an internal declaration of the study (No. 2205066v0). As it was a noninterventional retrospective study (MR-004), no CNIL (i.e. French data protection authority) declaration and no ethics committee approval were requested (JORF10/05/2017). There was no refusal to participate from any of the patients, and specific informed consent was obtained for photographs publication. The study information note destined for patients is provided in Supplemental data (Fig. S1).

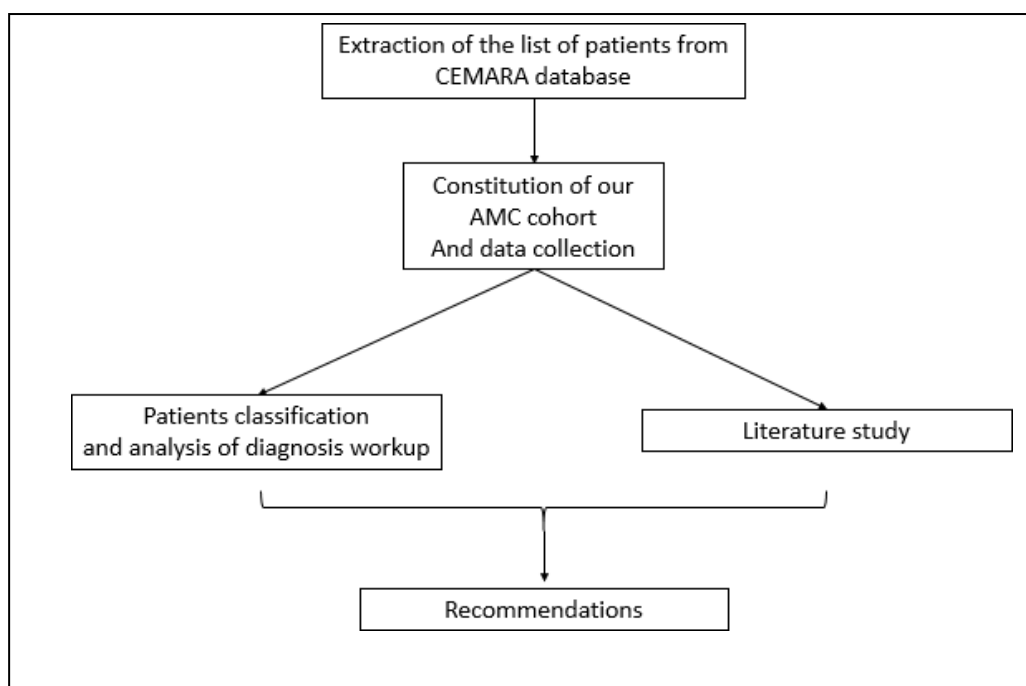


Figure 2. Main steps of present study protocol.

Legends : AMC, Arthrogyrosis Multiplex Congenita.

2/ Cohort building

As it was a retrospective observational study, no theoretical sample size was calculated. Cohort building was made using CEMARA, a national database designed for rare diseases instituted in 2004, whose completion is mandatory for all labelled rare disease reference or competence centre. Thus, every patient consulting in our reference centre for developmental anomalies and ID of the South-East, first labelled in 2007 and renewed every five years since then, has been registered in this application. The consultation purpose is one of the required information to fill in. Patients consulting for arthrogyrosis can thus be easily identified using the application search tool. Recruitment is either local or national, with patients addressed by healthcare professionals from other centres, or coming on their own, most often on the advice of the national association of patients “AAA”.

Hence, we requested from our local CEMARA database the list of all patients for whom the French term “arthrogryose” or “Amyoplasia” had been quoted as a consultation motive since 2007. We then selected patients meeting the following inclusion criteria :

- patients presenting with AMC, as previously defined, with or without associated signs
- born alive
- whose first evaluation had been performed at a paediatric age (i.e. ≤ 17 years old) in Grenoble University Hospital
- and who had been evaluated at least once in our reference centre since its labelling in 2007 and until February 2019. This evaluation had to comprise at least a consultation with a medical geneticist, or a medical opinion based on numerous and sufficient clinical and paraclinical data.

Patients presenting with arthrogyrosis at a late paediatric age evaluated by our adult team were excluded in order to homogenize gathered data and avoid a lack of information about the diagnostic work-up in infancy. Patients presenting with arthrogyrosis involving a single joint level (e.g. isolated equinovarus feet) were also excluded to stick to the definition of AMC. Finally, we did not include foetal diagnosis of arthrogyrosis leading to intra uterine death (IUFD), termination of pregnancy (TOP) for medical purposes or stillbirths since we wanted to focus on postnatal diagnostic management. To better reflect the recruitment of our reference centre for AMC patients, we chose not to select patients according to their home city or country.

3/ Data collection

Data were collected from patient's paper and informatic files reading. As most patients had been evaluated in other cities health centres, information had been collected by parental questioning or written documents transmitted by the parents during medical appointments. Data were anonymized and an identification number was randomly assigned to each patient.

Information collected were: family history and consanguinity, pregnancy history, birth, neonatal events and clinical presentation, joints spontaneous position and functional limitations assessed by the rehabilitation team, associated extra-articular signs, main treatments conducted and management, outcome of functional limitations, and age at first and each appointment with the clinical geneticist of the reference centre. More specifically, diagnostic investigations including biological, functional or imaging investigations performed pre or postnatally and their results were collected, as well as age at diagnosis when a molecular diagnosis was available.

4/ Patients' classification

In order to facilitate data analysis, patients were classified into 3 groups. To do so, we used the conclusions of the last clinical evaluation in genetic consultation which already classified patients into one of these categories and checked it or updated it using clinical and biological collected data since then. In accordance with our clinical habits in the diagnostic query of our patients during and following the first evaluation, we chose to use an adaptation of the second clinical classification previously described in the INTRODUCTION section, as following:

- Group 1: Amyoplasia congenita

Within this group we distinguished two subgroups :

- typical Amyoplasia (T) as defined in [Table 1](#) if evidences were sufficient to be fully confident to raise this diagnosis
- atypical Amyoplasia (aT) if the diagnosis was suggestive of Amyoplasia but that atypical elements were found, making this diagnosis uncertain.

- Group 2: Distal Arthrogyrosis (DA)

DA was defined as explained in the INTRODUCTION section and in [Table 2](#). To better reflect our ID process, we extended the definition of DA8 to include all other forms of multiple pterygia syndrome. Patients of group 2 were further subclassified as following:

- peripheral nerve involvement (PN) including patients bearing mutations in genes *PIEZO2* and *ECEL1*
- neuromuscular end-plate impairment (NMJ): mutations in *CHRNA3*
- muscle involvement (M): mutations in *TPM2*, *TNNT3*, *TNNI2*, *MYH3*, *MYH8* and *MYPBC1*
- other (O): other genes previously associated with DA (such as *FBN2*)
- unknown (U): when clinical and paraclinical features were suggestive of DA but that no molecular diagnosis was available to categorize them into one of the previously defined group with strong confidence.

- Group 3: other types of AMC

In this group we individualized patients presenting with CNS impairment (C) as defined by the presence of severe hypotonia, decreased alertness, psychomotor delay or ID, microcephaly, seizures, or other features suggestive often associated with CNS impairment such as dysmorphic features.

All other patients of group 3 (O) had various causes of AMC that could not be classified either as Amyoplasia, DA, or other types with central involvement. Possible diagnoses found in this group are gathered in [Fig. 3](#).

5/ Data analysis in the light of information provided by the scientific literature

Each investigation performed for diagnostic purposes was listed. We determined the percentage of patients that had been submitted to it, reported the proportion of positive results and how it helped to guide the diagnosis. Each groups and subgroups of patients were analysed separately.

Then we compared our data to medical information available in the literature. We performed a rapid review for each paramedical investigation, using the search engine PubMed® (NCBI). Articles were selected from abstract analysis, and only relevant publications

were further studied. Additional papers, identified through the study of bibliography of firstly selected publications, if pertinent, were also considered. Review was performed between April and August 2019. Details on article selection and conclusion may be shared on request. For some paraclinical investigations, literature review had been previously performed in Dieterich et al, 2019 (32). In parallel, we completed our analysis by studying publications describing AMC cohorts or providing diagnostic management recommendations.

Combining conclusions obtained from the analysis of our data and results of our literature searches, we aimed at establishing clinical recommendations for AMC patients' diagnostic management.

CNS involment (C)		Other forms (O)	
Chromosomal aberrations <ul style="list-style-type: none"> - Trisomy 18,13, 21 - Recurrent 9q and 8 translocation - 5q23 microdeletion - other rare microdeletions/duplications 	Neurogenic <ul style="list-style-type: none"> - Axonal or demyelination neuropathies (<i>CNTAP1, CNTN1, LGI4, GLDN</i>) - Other : <i>ZC4H2 mutations</i> 	Connective tissue disorders <ul style="list-style-type: none"> - Ehlers-Danlos syndromes (<i>CHST14, FKBP14</i>) - CBD : Brück, Campomelic dysplasia, Diastrophic dysplasia, Kniest dysplasia, Larsen, Multiple synostosis, Parastrematic dysplasia and metatropic dysplasia (<i>TRPV4</i>), Weil-Marchesani... - Ectodermal dysplasias, restrictive dermopathies 	
Primary structural brains anomalies <ul style="list-style-type: none"> - Cortical brain anomalies : polymicrogyria (<i>PI4KA, BICD2</i>), lissencephaly (<i>PAFAH1B1, RELN, DCX</i>), other causes of abnormal gyration - Nodular heterotopia (<i>KIF5C, DYNC1H1, TUBB2B, FLNA, NEDDL4</i>) - PCH type 1, 4, 9, 12 (<i>TSEN54, EXOSC3, RARS2, VRK1, AMPD2, COASY</i>) - Causes of brain or cerebellum atrophy 	Myogenic <ul style="list-style-type: none"> - MD type 1 (<i>DMPK</i>) - CMD : α dystroglycanopathies such as WWS and MEB (<i>POMT1, POMT2, FKTN, FKRK, LARGE, POMGNT1</i>), merosine deficient CMD (<i>LAMA2</i>) 	<ul style="list-style-type: none"> - CMD : retractile myopathies (<i>SEPN2, COLVI</i>) - Congenital myopathies (<i>NEM, ACTA1, RYR1, SYNE1...</i>), LGMD, congenital myasthenic syndromes (<i>RAPSN, DOK7, CHAT, CHRNA1, CHRNB1, CHRND, MUSK</i>) 	
	Syndromic forms <ul style="list-style-type: none"> - Monogenic disorders : Aicardi-Gouttieres, Alkuraya-Kucinkas, ARC, ATR-X, Bohring-Opitz, COFS, Crisponi, Marden-Walker/Ohdo spectrum, Miller-Dieker, Neu-Laxova, OPD, OFD, Schinzel-Giedion, SLO, Sotos.. - Metabolic disorders : Zellweger - PWS 	<ul style="list-style-type: none"> - Monogenic disorders without CNS involment : Aarskog, Holt-Oram, Nail-patella, Oculo-dento-digital, Oral-cranial-digital... - Metabolic disorders 	Maternal causes <ul style="list-style-type: none"> - Intrauterine vascular compromise - Maternal illness : MG, traumatic event - Maternal exposure : treatments (misoprostol, phenytoin, curare), toxics (alcohol)
Other <ul style="list-style-type: none"> - Genes controlling CNS development with/without brain anomalies (<i>TRIP4,ASCC1</i>) - Chanellopathies (<i>SLC6A9, NALCN</i>) - <i>MAGEL2</i> mutations - CBD : geleophysic dysplasia, Dyggve-Melchior-Clausen, rhizomelic CDP - infections : Zika, CMV, VZV, rubella virus 			Environmental causes <ul style="list-style-type: none"> Intra-uterine foetal space restriction: severe oligoamnios, tumoral process, multiple pregnancy, uterine malformation..

Figure 3. Possible diagnosis in Group 3 with (C) or without (O) CNS involvement.

From Dieterich et al., 2019 (32) and Hall et al., 2014 (4).

Legends : ARC, arthrogyrosis Renal dysfunction and Cholestasis; ATR-X, Alpha Thalassemia/mental Retardation syndrome; CBD, Congenital Bone Disorders; CDP, Chondrodysplasia; CMD, congenital muscular dystrophies; CMV, cytomegalovirus; CNS, central nervous system; COFS, Cerebro-Facio-Oculo-Skeletal syndrome; LGMD, Limb Girdle Muscular Dystrophies; MD, Myotonic Dystrophy; MEB, Muscle Eye Brain; MG, myasthenia gravis; OFD, oro-facio-digital syndrome; OPD, oto-palato-digital syndrome; PCH, ponto-cerebellar hypoplasia; PWS, Prader-Willi Syndrome; SLO, Smith-Lemli Opitz syndrome; SMA, Spinal Muscular Atrophy; SMALED, SMA Lower Extremities predominant, autosomal dominant; VZV, varicella zona virus; WWS, Walker Warburg Syndrome.

RESULTS

1/ Cohort constitution

We gathered 123 paediatric AMC patients over 12 years. Additionally, two patients that had been evaluated first before 2007 but had been followed up in the reference centre after its certification were included as well, reaching a total of 125 patients (Fig. 4A). The full clinical workup proposed to AMC children had been performed for 118 of them. Twenty-five (20%) had a regular local follow-up, 90 (72%) were followed-up in secondary or tertiary level care centres in other French cities and 10 (8%) from other countries, mostly from Northern Africa (n=6). Epidemiological, pregnancy and birth data are summarized in Table 3.

54 patients were classified in group 1 (43.2%), 32 in group 2 (25.6%) and 39 in group 3 (31.2%). In group 1, 41 cases had typical Amyoplasia (75.9%) and in group 3 most patients had signs of CNS involvement (n=27, 69.2%) (Fig. 4B).

Epidemiological data		Pregnancy data		Birth data	
Item	N° (%)	Item	N° (%)	Item	N° (%)
Females	64 (51.2)	Multiple pregnancies	4 ^{2,3} (3.2)	Preterm birth	17/104 (16.3)
Related parents	8 (6.3)	Twins	3 ⁴	Very premature ⁶	3
Familial cases	12 (9.5)	Triples	1	Post term birth	4/104 (3.8)
Parental	8	In vitro fertilization	3 (2.4)	Median birth weight (kg)	2.91 (1.03-4.49)/99
Siblings	4	Uterine malformations ⁵	6 (4.8)	Median birth height (cm)	47 (38-53)/62
Adoption	3 (2.4)	Pregnancy events	14/114 (12.3)	Median birth OFC (cm)	35 (28-39.5)/71
Past IUFD/miscarriage	8/89 (9)	Vaginal bleeding	4	C-section	38/122 (31.1)
Year of birth*	2010	First semester infection	4	Breech presentation	20
Age at first evaluation*	24mo	Toxaemia/HBP/oedema	3	Scarred uterus	5
Early death	4 (3.2) ¹	Vehicle accident	1	Foetal cause ⁷	8
		Premature delivery threat	1	Maternal cause ⁸	4
		Early membrane rupture	1	Term overtaking	1
				Long bone fracture	1 (0.8)
				Neonatal difficulties	15 ⁹ (12)

Legends : HBP, high blood pressure; IUFD, intra uterine foetal death; OFC, occipitofrontal circumference; mo, months old; N°, number of cases.
 *Median. ¹ group 3 only; ² and 2 additional early death of a twin; ³ 2 patients of group 1T, 2 of group 3O; ⁴ 1 monochorial, 1 dichorial, 1 unknown; ⁵ unicornuate, bicornuate or septate uterus; ⁶ before 32WG; ⁷ foetal cardiac rhythm anomaly (n=5), laparoschisis (n=2), twin-to-twin transfusion syndrome; ⁸ narrow pelvis, anticoagulation therapy for lupus, septate uterus, cervical cerclage. ⁹ 1 case of cardiorespiratory arrest.

2/ Aetiologies of AMC (Fig. 4B)

2.A/ Group 1: Amyoplasia congenita

Among patients with typical Amyoplasia, 66% had four limbs involvement (n=27), 22% only upper limbs (n=9) and 12% only lower limbs (n=5) (Fig. 5A). Thirteen cases were qualified as atypical Amyoplasia based on various clinical evidences (Table S1). Among these patients, nine had molecular investigations, negative in two and still ongoing in seven. For patient 98, clinical suspicion was strengthened by electroneuromyography (ENMG) results as we'll discuss later (Fig. 5B).

2.B/ Group 2 : Distal arthrogryposis

In this group, 66% of patients had a molecular diagnosis, all obtained by targeted Sanger or next-generation sequencing (NGS) focused on AMC or neuromuscular diseases (NMD) related genes (AMC-NGS and NMD-NGS, respectively, whose list of sequenced genes is provided in Table S2) (Fig. 4B). Mutations in genes encoding proteins of the muscle sarcomere were the most frequent aetiology, among which half were *MYH3* variants including two familial cases (Fig. 5C-D). Impairment of the peripheral nerve was nearly as frequent with a large majority of gain of function heterozygous *PIEZO2* variants among which two were identified by specific research of the familial variation previously identified in their affected sibling; and one familial case of a homozygous *ECEL1* variant (Fig. 5E-F). However, we had only one case of neuromuscular end-plate impairment due to a homozygous *CHRNA1* variant and one case of Beals syndrome due to *FBN2* mutation (Fig. 5G-H).

Among undiagnosed patients, eight NGS analyses were still ongoing. There was a clinical suspicion of DA2 in six patients including two cases with negative targeted Sanger sequencing and no further explorations ongoing. Multiple pterygium syndrome was suspected in three cases, with negative *CHRNA1* sequencing in one. An *ECEL1* mutation was negative in a case for which investigations were ongoing. Paraclinical examinations did not permit to get a formal diagnosis although it helped to better delineate the phenotype for two patients.

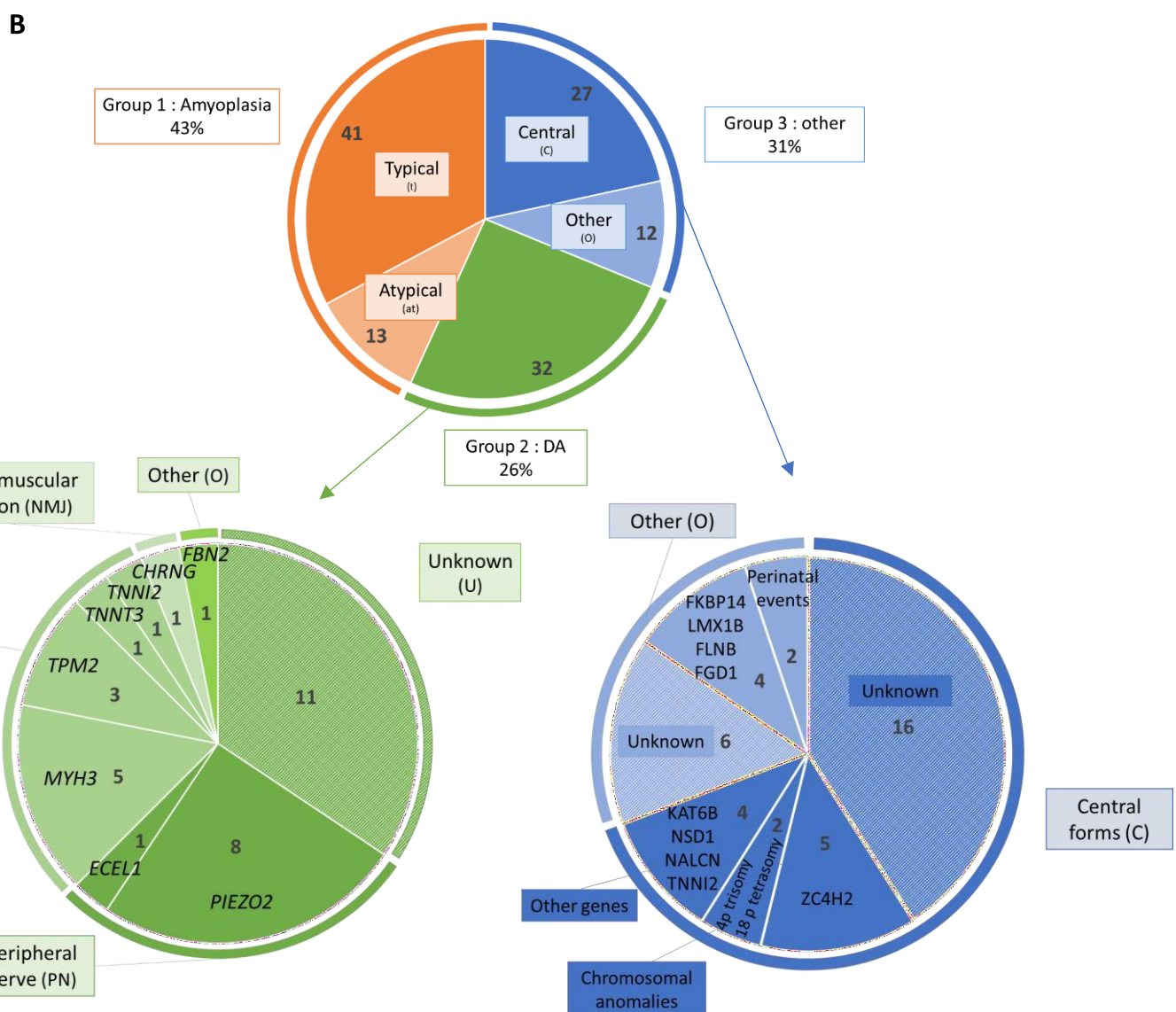
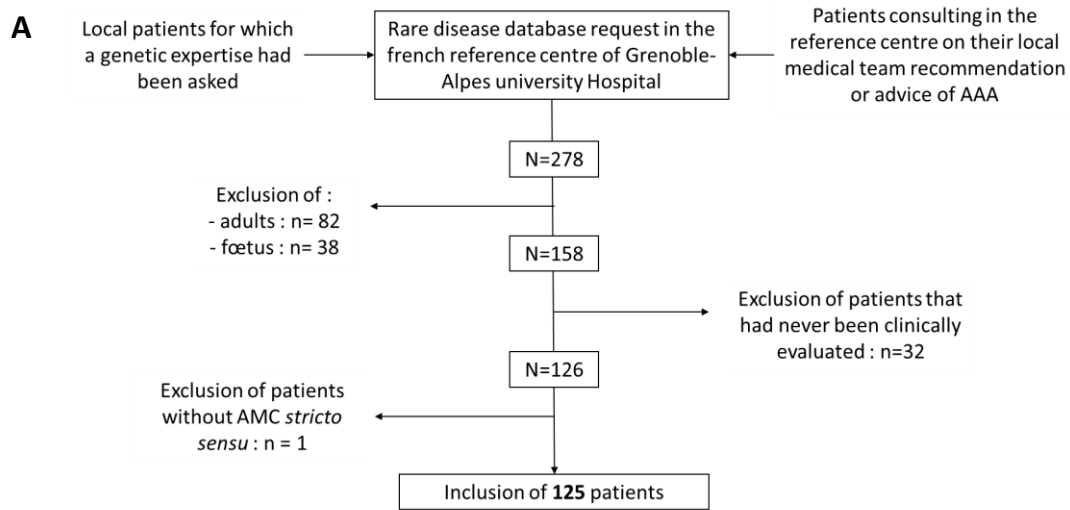


Figure 4. A. Flowchart of the study and **B.** Cohort distribution of the three groups, and detailed definitive diagnoses in group 2 (green disk) and 3 (blue disk).

Legends : AAA, Association Alliance Arthrogyrose; AMC, Arthrogyposis multiplex congenita; C, CNS involvement; DA, Distal Arthrogyposis; M, muscle, NMJ, neuromuscular junction; O, other; PN, peripheral nerve; U, unknown.

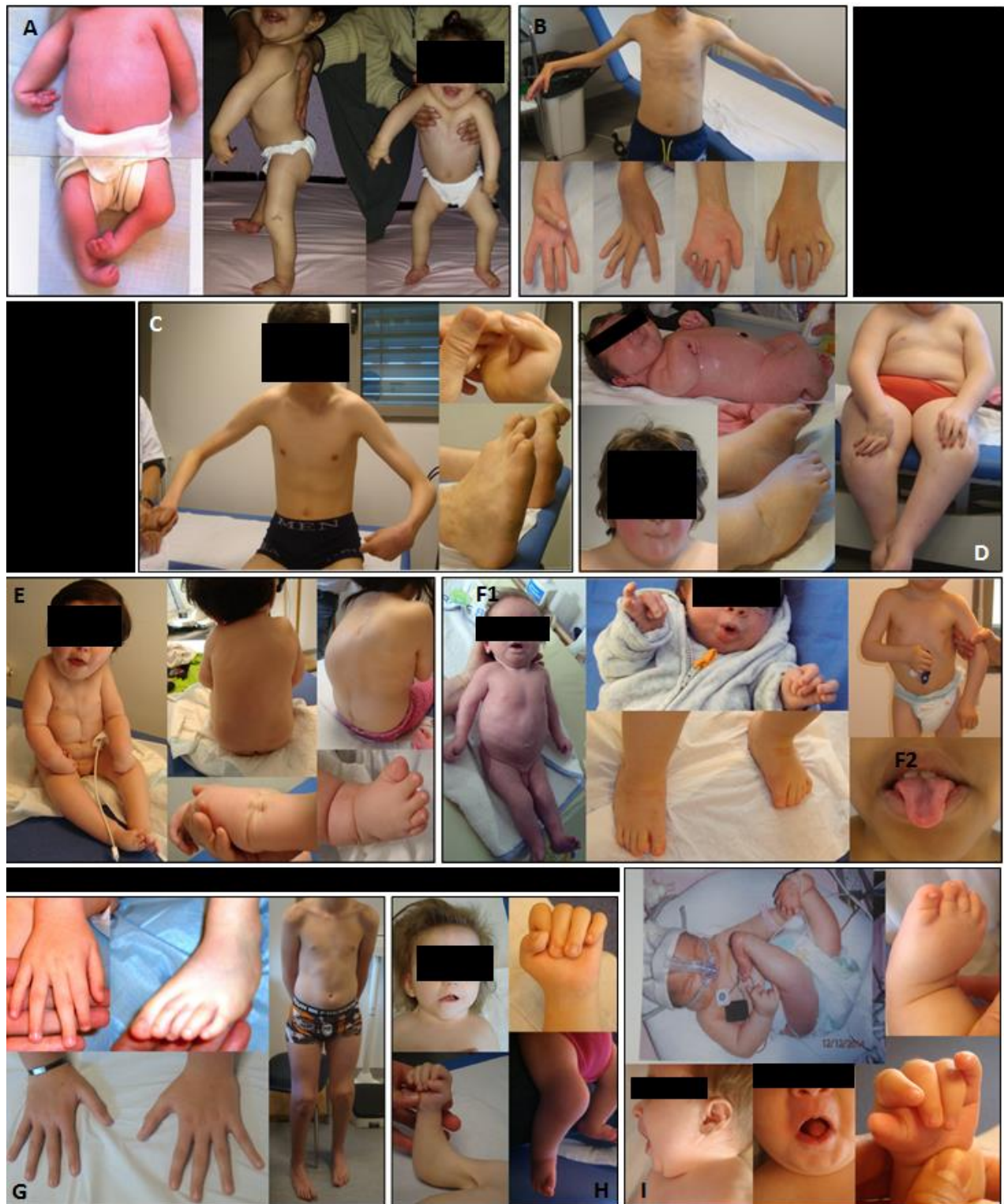

Figure 5. Pictures of AMC patients of our cohort. **A.** Typical Amyotonia congenita involving four limbs (subject 87). **B.** Atypical Amyotonia with asymmetric and caudal muscle impairment (subject 98). **C.** *TNNI2* mutation in a patient with Sheldon-Hall syndrome (subject 105). **D.** Freeman-Sheldon syndrome due to *MYH3* mutation (subject 108). **E.** Gain of function *PIEZO2* mutation with early and progressive trunk involvement (subject 23). **F1.** Confirmed *ECEL1* homozygous variant (subject 39) and **F2.** characteristic groove tongue of a patient with a strong clinical suspicion of *ECEL1* mutation (subject 125). **G.** Discrete AMC of favourable outcome in a patient with Beals syndrome (subject 3). **H.** *CHRNG* homozygous mutations (subject 63). **I.** Subject with a *ZC4H2* variant, with characteristic neck and extremities (subject 75).

2.C/ Group 3 : Other patients

In group 3, a definitive diagnosis was available for 41% and 50% of patients in group 3C and 3O, respectively (Fig. 4B).

In group 3C, *ZC4H2* appears to be a frequent cause of AMC with CNS involvement, with four point mutations identified by targeted sequencing (n=3) or Whole Exome Sequencing (WES) (n=1), and one deletion evidenced by comparative genomic hybridization array (array-CGH). One case was familial (Fig. 5I). Chromosomal analysis identified two additional cases in this group, both first identified on karyotype: a 18p tetrasomy with an isochromosome and a 4p duplication due to an unbalanced translocation der(4;22)(p10;q10), further characterized by array-CGH. AMC-NGS identified a point mutation in *TNNI2*, a gene responsible for DA type 2B, in an individual that was initially suspected with DA but had been classified in group 3 because of a cognitive impairment. Looking back to his personal history, we hypothesised that his cognitive dysfunction could have a distinct cause, i.e. a car accident with head impact in childhood. Also, NMD-NGS pointed out a heterozygous *NALCN* variant in a child with cognitive dysfunction compatible with the diagnosis of CLIFAHDD syndrome (“Congenital contractures of the Limbs and Face, Hypotonia and Developmental Delay”) (MIM#616266). Lastly, targeted sequencing of *KAT6B* and *NSD1* were asked for suggestive presentations of SBBYSSS variant of Ohdo syndrome (MIM#603736) and Sotos syndrome (MIM#115750), respectively. Among patients without molecular diagnosis, there was a clinical suspicion of Muscle Eye Brain disease unexplored to date, and a case of hyperreflexia with negative *GLRA1* sequencing.

Concerning patients of group 3O, WES and NMD-NGS identified variants in genes responsible for the kyphoscoliotic form of Ehlers-Danlos syndrome (MIM#614557) and for Larsen syndrome (MIM#150250), two conjunctive tissue disorders associated with AMC respectively due to *FKBP14* and *FLNB* variants. Two other patients had mutations in genes responsible for syndromic forms of AMC, i.e. nail patella syndrome due to *LMX1B* variants (MIM#161200), and Aarskog due to a *FGD1* mutation (MIM#305400). *FKBP14* and *FGD1* variants were identified in familial cases. Interestingly in this group we described two cases of environmental causes of AMC, one due to severe oligohydramnios secondary to a premature membrane rupture at 18WG and the other due to a complicated twin pregnancy (early cervical

cerclage, prolonged bleeding, premature rupture of membranes inducing extreme preterm birth).

More than half of these patients did not have any aetiological diagnosis. Among them, two were diagnosed with constitutional bone disorders (CBD) such as Diastrophic Dysplasia and Brück syndrome with so far negative analyses. Overall, NMD-NGS or WES analyses results were still pending in nine patients. As we'll see, in group 3, paraclinical investigations could be useful to guide the diagnosis, although it did not allow to conclude formally at time of the study.

Overall, a definitive aetiological diagnosis of AMC was established for 79 patients, i.e. 63.2% of the cohort, comprising 43 clinical and 36 molecular diagnoses. Median age of patients at time of molecular diagnosis results was four years old. For the 46 undiagnosed patients, nine never had any analyses, 13 had previous negative investigations (including two NMD-NGS and one WES) but no ongoing explorations and 24 had pending NMD-related genes or untargeted NGS results.

3/ Paraclinical investigations performed and results (Table 4)

3.A/ Other genetic investigations

A karyotype was performed in less than half of our cohort, 48% antenatally (n=26), 41% postnatally (n=22) and 11% (n=6) both antenatally and postnatally.

In the antenatal period, karyotype was performed in a quarter of the cohort (25.6%, n=32) in equal proportions in the three groups (27.8%, 25% and 23.1% respectively). Half were performed because of bilateral equinovarus feet, isolated or associated with articular or extra-articular anomalies. Antenatal array-CGH were rarely performed (4.8%, n=6, 3 from group 3) and all were normal. Detailed indications are summed up in **Table S3**. Postnatal karyotypes (22.4%, n=28) were performed mostly in group 3 (41% (n=16), in contrast with 16.7 and 9.4% in group 1 and 2, respectively), as was array-CGH. Together, they contributed to three diagnoses, resulting in a yield of 2.4% in the whole cohort and 11% in group 3C. It also unravelled incidental findings in six cases, polymorphic copy number variants (CNVs) or

Variant of Unknown Significance (VUS) (**Table S4**). Other type of cytogenetic examinations had been performed in a limited number of patients (**Table S5**).

Targeted sequencing on a subset of genes involved in AMC was performed in almost half of the patients. Among the 48 tested patient, Sanger sequencing of AMC-genes had been performed in 33 and AMC-NGS in 17, both with a high yield (42 and 33%, respectively). Both were mostly performed in group 2 for which yield was the best. Finally, 22 patients had a NMD-NGS, mostly group 3 patients, with a global yield so far of 18.2%, with still a significant number of pending analyses.

Targeted sequencing of other genes was performed in 12.7% (n=16) of the cohort (**Table S6**). It enabled a diagnosis for five patients. Finally, genome-wide investigations, i.e. WES or whole genome sequencing (WGS), were performed in 11.1% of the cohort, mostly in group 3, and led to two diagnoses, resulting in a hitherto yield of 15.4%, here again with a significant number of pending results.

DMPK analysis, Prader Willi 15q11.2q13 locus analysis and *SMN1* analysis were all performed in around 10% of patients. Some were performed prenatally (n=5, n=2 and n=4, respectively), mostly because of decreased foetal movements. *DMPK* triplet expansions were mostly investigated in group 3, *SMN1* deletions mainly in group 1 patients, whereas Prader-Willi was questioned as much in the three groups. Those analyses never turned out positive.

3.B/ Other biological investigations

Creatine Kinase (CK) levels were determined in approximately one out of five individuals. CK levels were slightly elevated or subnormal only for four patients, especially in two local patients with *ZC4H2* and *NSD1* variants for which dosages were performed in particular circumstances, not mentioned in medical reports and without available control dosages, suggesting that they had been judged uninterpretable (**Table S7**). Moreover, elevated CK are not reported in these disorders and at least one other *ZC4H2* mutated patients had normal values.

Table 4. Paraclinical investigations performed for aetiological purposes and their results

Investigations			Group 1			Group 2					Group 3			Total (%)
			tot (%)	t	at	tot (%)	PN	NMJ	M	O+U	tot (%)	C	O	
			54	41	13	32	9	1	10	12	39	27	12	
Genetic investigations*	Karyotype	tot	20 (37)	15	5	10 (31.3)	4	0	4	2	24 (61.5)	18	6	54 (43.2)
		+	0			0					2	2	0	2
	Array-CGH	tot	13 (24.1)	7	6	7 (21.9)	1	1	1	4	22 (56.4)	18	4	42 (33.6)
		+	0			0					1	1	0	1
	AMC sequencing**	tot	11 (20.4)	2	9	30 (93.8)	9	1	10	10	17 (43.6)	13	4	58 (46.4)
		+	0			21	9	1	10	1	3	3	0	24
		pend	6	0	6	6	0	0	0	6	4	2	2	16
	WES/WGS	tot	2 (3.7)	1	1	2 (6.3)	0	0	0	2	9 (23.1)	6	3	13 (10.4)
		+	0			0					2	1	1	2
		pend	2	1	1	1	0	0	0	1	6	4	2	9
	Other targeted seq. ¹	tot	1 (1.9)	1	0	2 (6.3)	1	1	0	0	13 (33.3)	8	5	16 (12.8)
		+	0			0					5	2	3	5
DMPK analysis	tot	7 (13)	6	1	3 (9.4)	1	0	1	1	6 (15.4)	5	1	16 (12.8)	
	+	0	0		0					0			0	
15q11.2q13 locus analysis	tot	3 (5.6)	3	0	2 (6.3)	1	0	0	1	3 (7.7)	2	1	8 (6.4)	
	+	0			0					0			0	
SMN1 analysis	tot	10 (18.5)	9	1	1 (3.1)	0	0	1	0	4 (10.3)	3	1	15 (12)	
	+	0			0					0			0	
Biological investigations	CK dosage	tot	13 (24.1)	9	4	2 (6.3)	0	0	0	2	8 (20.5)	6	2	23 (18.4)
		+	1	1	0	0					3	3	0	4
	AChR/MusK antibodies	tot	4 (7.4)	4	0	3 (9.4)	1	0	0	2	4 (10.3)	3	1	11 (8.8)
		+	0			0					0			0
Metabolic investigations	tot	1 (1.9)	0	1	1 (3.1)	0	0	0	1	13 (33.3)	10	3	15 (12)	
	+	0			0					1	0	1	1	
Neuro-muscular	MB	tot	13 (24.1)	9	4	6 (18.8)	2	1	0	3	6 (15.4)	5	1	25 (20)
		+	7	6	1	1	0	0	0	1	3	3	0	11
	ENMG	tot	12 (22.2)	8	4	9 (28.1)	1	0	3	5	6 (15.4)	5	1	27 (21.6)
		+	5	3	2	1	0	0	1	0	3	3	0	9
mMRI	tot	42 (77.8)	30	12	29 (91)	8	1	10	10	20 (51.3)	14	6	91 (72.8)	
	+	Ns	Ns	Ns	Ns	Ns	Ns	Ns	Ns	Ns	Ns	Ns	Ns	
Organ explorations	cMRI ²	tot	20 (37)	17	3	7 (21.9)	0	1	1	5	21 (53.8)	19	2	48 (38.4)
		+	1	1	0	2	0	0	0	2	12	12	0	15
	tcUS	tot	15 (27.8)	13	2	4 (12.5)	1	0	0	3	21 (53.8)	16	5	40 (32)
		+	3	2	1	0					2	2	0	5
	EEG	tot	2 (3.7)	2	0	1 (3.1)	0	0	0	1	13 (33.3)	12	1	16 (12.8)
		+	0			0					7	6	1	7
	scMRI	tot	20 (37)	14	6	6 (18.8)	2	0	2	3	10 (25.6)	5	5	36 (28.8)
		+	2	0	2	0					2	1	1	4
	scUS	tot	5 (9.3)	3	2	1 (3.1)	1	0	0	0	8 (20.5)	5	3	14 (11.2)
		+	2	0	2	0					1	1	0	3
	Ophthalmological evaluation	tot	6 (11.1)	6	0	5 (15.6)	0	0	1	4	13 (33.3)	10	3	24 (19.2)
		+	0			0					0			0
Abdominal US	tot	18 (33.3)	15	3	8 (25)	1	0	1	6	18 (46.2)	13	5	44 (35.2)	
	+	3	2	1	2	0	0	1	1	1	1	0	6	
Cardiological US	tot	17 (31.5)	16	1	13 (40.6)	2	0	3	8	27 (69.2)	21	6	57 (45.2)	
	+	3	3	0	3	1	0	0	2	9	8	1	15	

Legends: AChR, acetylcholine receptor; AMC, arthrogyrosis multiplex congenita; at, atypical; c, central nervous system involvement; CGH, comparative genomic hybridization; CK, Creatine Kinase; cMRI, cerebral MRI; EEG, electroencephalogram; ENMG, electroneuromyography; M, muscular; MB, muscle biopsy; mMRI, muscle magnetic resonance imaging; MusK, Muscle Specific Kinase; NMJ, neuromuscular junction; Ns, non-specified; O, other; pend, pending; PN, peripheral nerve; scMRI, spinal cord MRI; scUS, spinal cord ultrasonography; t, typical; tcUS, transcranial ultrasonography; tot, total; u, unknown; US, ultrasonography; WES, whole exome sequencing; WGS, whole genome sequencing.

* Investigations performed prenatally and postnatally are considered altogether

** Genes involved in AMC, includes Sanger sequencing of AMC genes, AMC-related genes and Neuromuscular disorders-related genes NGS (Table S2)

¹Chromosomal or molecular investigations

²Postnatal

Investigation of maternal myasthenia antibodies targeting either Acetylcholine Receptor (AChR) and/or Muscle specific Kinase (MuSK) was even more rarely performed without differences in the 3 groups and was never found positive. For two patients, detection was performed during pregnancy because of foetal limb malposition and reduced limb movements.

Apart from hepatic, phospho-calcic or thyroid metabolism assessment, metabolic investigations were performed in one patient out of ten, as expected mostly in group 3C. Most screened patients had a basic checkup looking mainly for organic aciduria, urea cycle deficits or other aminoacidopathies, energetics disorders of citric acid cycle and fatty acid beta oxidation dysfunction. Only one patient had slightly abnormal ammonia levels whose cause remains unknown. Other investigations were performed in two or single patients ([Table S8](#)).

3.C/ Neuromuscular investigations

Muscle biopsy (MB) and electroneuromyography (ENMG) were both performed in about one out of five patients, with a slightly higher proportion in group 1 and 2.

MB was planned or discussed for 11 additional patients but had not yet been performed to our knowledge. Two patients were biopsied twice. MB was often performed in parallel of a surgical intervention. Many were interpreted as normal (n=6) or non-contributory because of lack of muscle tissue (n=5), and rarely results were not available (n=3). Histopathological examination reports described abnormalities in 11 cases ([Table 5](#)). Surprisingly, six had a clinical diagnosis of typical Amyoplasia and showed various types of anomalies. A neurogenic involvement was reported in two cases of typical and atypical Amyoplasia, in accordance with the hypothetic pathogenesis of this disorder, bringing another evidence toward Amyoplasia for the atypical case. However, two were suggestive of myogenic involvement, based on the association of poorly specific features, but did not question the diagnosis which was typical. One patient with a clinical diagnosis of DA had normal microscopic evaluation but a suspicion of multiminicore myopathy. In this patient (subject 12) for whom first clinical suspicion was a Freeman-Sheldon syndrome with normal Sanger sequencing of six DA genes and no other current investigations, this result may certainly help in the interpretation of future molecular investigations.

In group 3C, it appears that MB was mainly conducted to rule out a mitochondrial dysfunction. Eventually, the five tested individuals had a severe presentation with premature death in three of them. In the absence of evidence of such disorder on histology, investigations were completed by an analysis of mitochondrial respiratory chain (MRC) in three patients unravelling complex I borderline deficiencies and led to targeted genetic analysis in two individuals that turned out to be negative. Other anomalies were reported on histological examination of some of these patients but could not help to clarify the diagnosis. One had discordant results. In group 3O, MB was only performed in the patient with kyphoscoliotic Ehlers-Danlos syndrome and was non-contributory.

One third of ENMG were considered as abnormal ([Table 6](#)). Among patient with Amyoplasia, only one patient with a typical presentation had a neurogenic pattern, while the others had either normal ENMG, or a discordant myogenic pattern probably secondary to muscle disuse or atrophy. Interestingly, ENMG was of great value in an atypical Amyoplasia patient with unusual contracture location since it evidenced a neurogenic pattern which involved C7-C8-T1 motor roots instead of C5-C6, in accordance with his clinical presentation. In this patient it raised the hypothesis of a common pathophysiological mechanism with what is supposed in Amyoplasia, i.e. vascular compromise, but occurring in this case at a more caudal metameric location. Furthermore, this presentation is quite similar to Klumpke's obstetrical palsy affecting motor roots C8-T1, a similarity that strengthened our hypothesis. This, together with the fact that this patient had unremarkable NMD-NGS results, lead to expect a low if ever null recurrence risk in this family, although it would be unwise to definitively and completely discard a genetic cause due to the lack of data about this presentation. Finally, ENMG completion helped to delineate the diagnosis of three patients of group 3 and one patient with DA (subject 20), adding for the latest new evidence toward the suspected diagnosis of Freeman-Sheldon though not confirmed on Sanger sequencing so far.

Whole-body T1-weighted mMRI was widely performed in this cohort and almost all patients with atypical Amyoplasia and DA had been investigated. It was planned in five additional patients, and failed in three others from group 3C. Eighteen individuals underwent several mMRI at different ages. Analysis of data delivered by this imaging is the purpose of other researches coordinated by our team and will not be detailed here. Overall, it mainly

Table 5. Anomalies observed on muscle biopsy examination

Ind.	Group	Sub group	Genetic diagnosis	Global conclusions	MRC study	Mitochondrial genes/ <i>POLG1</i> sequencing
22*	1	T	/	Probable CMD merosine positive	/	/
104	1	T	/	Unspecific anomalies only, no congenital myopathy	/	/
94	1	T	/	Ns (Slight predominance of type 1 fibres, few mitochondrial aggregates, slight increased lipid storage)	/	/
9	1	T	/	No myogenic involvement	/	/
26	1	T	/	Important myogenic involvement	/	/
8	1	T	/	Neurogenic involvement	/	/
52	1	aT	uk	Neurogenic involvement	/	/
12	2	U	uk	Probable multimimicore myopathy	/	/
34**	3	C	uk	No evidence for mitochondrial dysfunction	Impairment of complex I function?	Normal
17	3	C	uk	No evidence for mitochondrial dysfunction or myotubular myopathy. Discordant results between IHC suggestive of a sarcoglycanopathy and normal WB	Normal (incomplete study of complex IV)	/
4**	3	C	uk	No evidence for mitochondrial dysfunction	Normal but low complex I function	MELAS mutation with 7% heteroplasmy
19**	3	C	uk	Non contributory	Normal	/

Legends : aT, atypical; C, CNS involvement; CMD, congenital muscular dystrophy ; Ind. individual; IHC, Immuno Histo Chemistry; MRC, mitochondrial respiratory chain; ns, not specified; T, typical; U, unknown type; uk, unknown genetic diagnosis; WB, Western Blot.* MB performed twice. ** premature death.

Table 6. Detailed anomalies observed on electroneuromyography

Ind.	Group	Sub group	Genetic diagnosis	Conclusions
50	1	T	/	Possible neurogenic involvement suggestive of motor axonal neuropathy (microvoltage responses), with an atypical presentation. Anomalies could either be secondary to orthopaedic deformations
26	1	T	/	Myogenic pattern and decrease voluntary activity in distal muscles of lower limbs (anterior tibial muscle and internal gemellus muscle)
66	1	T	/	Atypic myogenic pattern with rather rich pattern in location where muscle are atrophic
98	1	aT	uk	Neurogenic pattern with C7 to T1 motor root impairment (micro volted pattern with slight decreased conduction velocity in the right median territory in motor conduction study, neurogenic contraction pattern in territory C7-C8-T1)
20	2	U	uk	First ENMG normal, second with neuromuscular junction or muscle impairment (normal conduction velocity, but contraction pattern not as rich as expected on upper limbs, suggesting that a slight myogenic involvement cannot be discarded, although it could be secondary to muscle underuse.
17	3	C	uk	Myogenic pattern (low potential amplitude in right median territory)
60	3	C	uk	Moderate motor axonal neuropathy suggestive of anterior horn involvement
19	3	C	uk	Myogenic pattern (no detail available)

Legends : aT, atypical; C, CNS involvement; ENMG, electroneuromyography; Ind. Individual; T, Typical; U, unknown type; uk, unknown genetic diagnosis.

helped in group 1 patient, where it helped to maintain the diagnosis of Amyoplasia in one, and led to a classification in the typical group for another patient for who clinical diagnosis was uncertain. In group 2, mMRI strengthened a suspicion of *ECEL1* mutation in one patient, still under investigation. In group 3, mMRI mostly evidenced normal muscle tissues or diffuse atrophy without specific pattern, among which several could be secondary to joint limitations.

3.D/ Central nervous system investigations

For more than half of our patients (51.2%, n=64), cerebral MRI (cMRI) and/or transcranial ultrasonography (tcUS) had been performed. Although it was mostly proposed to group 3C patients, subjects of the two other groups were also frequently investigated, including typical Amyoplasia where a subset (n=3) had been performed because of abnormal tcUS.

Anomalies had been observed in one out of three cMRI performed, mostly in group 3C (**Table 7**). In this group, five patients had specific lesions such as polymicrogyria or mesencephalic cleft that will certainly conduct to a molecular diagnosis in the future. Others had nonspecific features including three cases of group 1 and 2. Notably, one patient diagnosed as typical Amyoplasia had several associated nonspecific anomalies.

Twenty-two patients had both cMRI and tcUS. Rarely, tcUS reports pointed towards abnormal and unspecific findings, of which only two were confirmed on cMRI. Conversely, six patients showing structural brain anomalies on cMRI had unremarkable or only partially affected tcUS.

Antenatal cMRI were performed for seven patients with equal proportion in the 3 groups because of multiple joint anomalies associated with growth defects, abnormal amniotic fluid quantity or multi organ involvement. All were normal, and two had postnatal MRI, normal as well.

Electroencephalogram (EEG) was performed in a small subset of our patients with a clear predominance in group 3. Indications were abnormal movements (n=4), seizures (n=3), abnormal muscle tone (n=4, hypotonia in the two patients of group 1), malaises (n=2), abnormal alertness (n=1), or others (n=2, including the patient of group 2 in whom the indication remained unclear). Anomalies have been reported in six patients but were relevant

only for four of them, to assess or rule out the epileptic nature of seizures and abnormal movements or to characterize seizures (Table S9).

Spinal cord MRI (scMRI) and spinal cord ultrasonography (scUS) were performed in nearly 1/3 and 1/10 of our patients, respectively (Table 8). While scMRI was mostly done in group 1, group 3 had the highest proportion of scUS especially for patients without central signs, as part of a global organ assessment. Most often, scMRI was performed all at once with cMRI. For six patients for whom scUS was done, a scMRI was further proposed, and all findings on scUS were confirmed by scMRI. Conversely, among three cases of scMRI anomalies for which scUS had been realized, only one was unremarkable. Significant and causal anomalies were not reported but instead we identified features frequently observed in the general population such as tethered or low tethered cona medullaris and dilated central canal.

Table 7. Details on anomalies reported on cMRI and/or tcUS

Ind.	Group	Sub group	Genetic diagnosis	cMRI		tcUS
				Age	Observed anomalies	Observed anomalies
22	1	T	/	« early »	First MRI : white matter anomalies Second MRI : thin CC splenium, carrefour dilation	normal
104	1	T	/	6 mo	Normal	Sub arachnoid stage I haemorrhage
18	1	T	/	1 mo	Normal	Periventricular frontal and occipital right sided hyperechoic signal
93	1	aT	uk	/	/	Septum pellucidum cyst
3	2	O	FBN2	ns	Blake pouch cyst	
125	2	U	uk	8 mo	Benign enlargement of subarachnoid space	
11	3	C	NSD1	2.5 yo	Rarefaction of white matter, CC atrophy, patent septum pellucidum	Normal
45	3	C	ZC4H2	Nn	Delayed myelination	Normal
47	3	C	18p tetrasomy	1 yo	White matter thinning, periventricular hypersignal, lateral ventricles dilation	/
34	3	C	uk	1 mo	Unilateral ventricle dilation	Normal
102	3	C	uk	2 mo 4mo	Polymicrogyria, pachygyria , white matter rarefaction, delayed myelination , doubt on brainstem hypoplasia , passive ventricle dilation	Ventricle dilation
68	3	C	uk	2 yo	Polymicrogyria	Normal
17	3	C	uk	Ns	Abnormal myelination, CSC atrophy, mesencephalic cleft	Normal
60	3	C	uk	Nn	Very thin CC	Thin CC
19	3	C	uk	Ns	CSC atrophy	/
6	3	C	uk	2 yo	CSC atrophy, white matter thinning	/
4	3	C	uk	10 do 8 mo	White matter hypersignal, delayed myelination, thin vermis , thin CC	Normal
84	3	C	uk	Nn	Punctiform abnormal white matter signal, subarachnoid haemorrhage of the posterior fossa	Normal

Legends : aT, atypical; C, CNS involvement; CC, corpus callosum; cMRI, cerebral MRI; CSC, cortical-subcortical; do, days old; Ind. Individual; mo, months old; MRI, magnetic resonance imaging; nn, neonatal period; ns, not specified; O, other; T, typical; tcUS, transcranial ultrasonography; U, unknown type of distal arthrogyriposis; uk, unknown genetic diagnosis; yo, years old. Bold characters : specific anomalies.

Ind.	Group	Sub group	Molecular diagnosis	Abnormality on scMRI	Abnormality on scUS
77*	1	aT	uk	Low-lying and tethered conus medullaris	Low-lying and tethered conus medullaris, no spinal swelling at lumbar level
70	1	aT	uk	Central canal dilation (conus terminalis)	Central canal dilation
116	3	C	ZC4H2	/	Low-lying conus medullaris
19	3	C	uk	Tethered conus medullaris	/
51	3	O	uk	Central canal dilation at high thoracic level, L5 sacralisation	normal

Legends : aT, atypical; C, CNS involvement; Ind. individual; O, other; scMRI, spinal cord MRI ; tcUS, transcranial ultrasonography; uk, unknown genetic diagnosis.

**AMC involving lower limbs only, suspicion of TRPV4 mutation with pending molecular investigations.*

3.E/ Associated organ impairment assessment

Abdominal ultrasonography (US), cardiological and ophthalmological evaluations were all frequently performed, mostly in group 3.

Ophthalmological evaluation was the most rarely reported. Often, details about this examination were not mentioned on medical reports. When it was, most of the time an eye fundus and electrophysiological studies had been realized and all were unremarkable. However, detailed patient interview and clinical examination revealed pathological findings in 38 patients among who only four belonged to group 1. Most were refractive disorders (n=12) and strabismus (n=14), common findings in the general population and often associated with syndromic diseases. Otherwise, more specific features such as abnormal ocular movements were evidenced (n=17): impairment oculomotor abilities in all but one *PIEZO2* patients, and saccadic movements, nystagmus or oculomotor asynergy predominantly in patients of group 3. Ptosis (n=11) and blepharophimosis (n=4) were also frequent findings, especially in *PIEZO2* patients (n=2) and in the individual bearing a *KAT6B* variant. Of note, no data about ophthalmological examination were available for our *ECEL1* mutated patient.

A cardiological US was performed in nearly half of the cohort. One out of four examinations were reported as abnormal ([Table 9](#)), with mostly nonspecific and spontaneously favourable outcome without need for surgical procedure, including in patients with syndromic forms (*NSD1* and *KAT6B* variants), in line with their diagnosis. More specific anomalies were found in group 3C, such as a double aortic arch requiring neonatal surgery

and a septal hypertrophy. In addition, another patient of this group had an innominate artery compression syndrome that did not require surgery, but there was no information about how this anomaly had been assessed. Five patients had other cardiological explorations such as 12-lead electrocardiogram (EKG) or holter EKG. Only one was reported abnormal.

A third of individuals had an abdominal US, anomalies were found in six patients, mostly nonspecific and probably independent from AMC aetiology, except for our individual with a *KAT6B* variant that had bilateral renal hypoplasia and severe vesicoureteral reflux that are probably part of his syndrome, although hydronephrosis and kidney cysts are more common ([Table 10](#)). For two patients, renal anomalies had been suspected *in utero*.

Altogether, global morphological explorations comprising at least a cardiological examination, abdominal and transcranial US were performed in one patient out of five patients (21.6%, n=27), 36% of group 3, versus 9% or 18% of group 1 and 2, respectively. An anomaly was reported in a third of explored patients due to the high proportion of renal and heart defects. Specific and nonspecific anomalies might have guided - or at least will guide - the diagnosis in syndromic forms of group 3.

Table 9. Details on anomalies reported in cardiological explorations

Ind.	Group	Sub group	Genetic diagnosis	Echocardiography		EKG
				Observed anomalies	Outcome	
49	1	T	/	Minor PDA, PFO	Ns	/
27	1	T	/	ASD, large PDA	benign	/
104	1	T	/	PDA, PFO	Sp favorable	/
9	1	T	/	trabecular VSD	Ns	/
76	2	PN	PIEZO2	PDA, PFO	Ns	/
92	2	U	uk	normal		Incomplet right BBB
119	2	U	uk	ASD	Sp favorable	/
125	2	U	uk	PDA	Sp favorable	/
116	3	C	uk	Restrictive PDA Transient mild tricuspid failure	Sp favorable	Normal Holter EKG
11	3	C	<i>NSD1</i>	ASD ostium secundum	Ns	/
45	3	C	<i>ZC4H2</i>	perimembranous VSD	Ns	/
75	3	C	<i>ZC4H2</i>	PFO	Sp favorable	/
110	3	C	<i>KAT6B</i>	ASD, VSD	Ns	/
17	3	C	uk	Double aortic arch	Neonatal surgery	/
102	3	C	uk	Isolated PFO	Ns	/
112	3	C	uk	VSD, PDA	Sp favorable	/
113	3	C	uk	Innominate artery compression syndrome	Stable, no surgery	normal
79	3	C	uk	Asymetric septal hypertrophy	Ns	normal
89	3	O	uk	ASD, minor VSD, PFO	Sp favorable	/

Legends : ASD, Atrial Septal Defect; BBB, bundle branch block; ns, non-specified; EKG, electrocardiogram; Ind., Individual; OS, ostium secundum; PDA, patent ductus arteriosus; PFO, patent foramen ovale; PN, peripheral nerve; sp, spontaneously; T, typical; U, unknown form of distal arthrogyposis; uk, unknown genetic diagnosis; VSD, Ventricular Septal Defect.

Table 10. Details on anomalies observed on abdominal ultrasonography

Ind.	Group	Sub group	Genetic diagnosis	Abdominal US
104	1	T	/	Hepatic calcifications (normal blood hepatic workup)
65	1	T	/	Unilateral hydronephrosis
93	1	aT	uk	Transitory unilateral hydronephrosis
121	2	M	<i>MYH3</i>	Unilateral pyelectasis (bilateral in utero)
125	2	U	uk	Unilateral hydronephrosis (bilateral in utero)
110	3	C	<i>KAT6B</i>	Bilateral kidney hypoplasia, severe vesicoureteral reflux

Legends : aT, atypical; C, CNS involvement; Ind., individual; M, muscle impairment; T, typical; U, unknown form of distal arthrogyposis; uk, unknown genetic diagnosis; US, ultrasonography.

DISCUSSION

In this retrospective single centre observational study, we gathered 125 paediatric AMC patients and analysed their diagnostic pathway in the light of their final diagnosis. The goal was to establish recommendations about diagnostic strategy and to harmonise clinical practice.

1/ Comparison of our cohort with literature of AMC patients

Numerous cohorts were described so far worldwide, with various numbers of patients, enrolment criteria and aims. Our cohort was comparable to previous reports in terms of familial cases (6-30%) (7,8,29,33,34) and sex ratio (7), even if a smaller French cohort had an excess of boys (30). Nonetheless, we had less cases of consanguinity in comparison with previous works where it ranged from 15 to 46% (8,29,30,33), and patients were also mostly younger at first evaluation (29,34). By choosing to include all patients presenting to our reference centre with AMC as a consultation motif *per se*, we may have a wider spectrum of presentations compared to previous reports whose enrolment went through neuromuscular reference centres (29,30,35). However, with the aim to describe paediatric diagnostic assessment, we excluded TOP, IUFD and stillbirth cases, resulting in a lower proportion of severe cases (5,7,8,29,31). Lastly, as our patients had to be evaluated at least once by a geneticist of our team, this referral bias on severity was strengthened by the exclusion of the most severe neurological, neuromuscular and neurometabolic diseases for which paediatric neurologists or metabolicians are solicited first. In addition, AMC is often not the forefront symptom in these patients and thus might not have been quoted in the national rare disease database (CEMARA). Finally, severe syndromic forms might not be addressed for a specialized consultation in our centre.

Our global diagnostic rate was comparable with previous cohorts where it ranged from 54 to 93% (5,6,8,31,35). Our proportion of typical Amyoplasia (31%) and DA (26%) patients, grossly respects previous estimations for which each group accounts for 1/3 of all AMC cases (12,17).

In group 2, we underline genes encoding sarcomere proteins as the forefront aetiology of DA, involving half of molecularly confirmed cases, as previously described (33), *MYH3* being the most frequent. Peripheral nerve involvement arises as the second cause with eight *PIEZO2* cases. With the addition of the five patients of our recently published adult cohort (36), gain of function mutations of this gene represent 7.7% of all AMC patients evaluated in our centre. To our knowledge, this contribution of *PIEZO2* in AMC had never been reported. However, we had less homozygous *ECEL1* and *CHRNA3* mutations with only three and two cases in the whole cohort in contrast with up to 7% and 9.4% of AMC cases respectively in other publications, probably due to a much higher proportion of consanguineous families (30,33,37). In this group, we highlight the high yields of molecular investigations in comparison with the two others. Indeed, genes responsible for DA had been progressively unravelled since 1995 (19). As DA phenotypes are recognizable, these genes have long been studied by targeted Sanger sequencing before the introduction of NGS. In addition, first NGS technics set up in our laboratory focused on a small group of AMC-related genes among which many were responsible for DA.

In group 3C, *ZC4H2* appears as a frequent cause of AMC with CNS involvement with five cases in this study and an additional adult case, thus accounting for 3.6% of the whole cohort. Here, the great interest of array-CGH has to be underlined, since deletions involving at least the first exon of *ZC4H2* represent 29% of all *ZC4H2* pathogenic variants in females, with length ranging from 81kb to 826kb, while it is likely lethal in boys (38–41). As phenotypes associated with *ZC4H2* variants in females are highly variable and may overlap with clinical features of other patients of group 3C, array-CGH with special focus on *ZC4H2* locus may be preferred to *ZC4H2* microdeletion analysis alone. More globally, our rate of chromosomal aberrations of 2.4% in the cohort was in line with the 3-7% of the literature considering our referral bias on severity (6,7,31). Notably, chromosomal investigations had a high yield in this group, contributing to two diagnoses of syndromes for which congenital contractures, most often distal, had previously been described (42–44). Since the diagnostic value of chromosomal investigations was null in other groups, and as AMC is a clinical feature of many chromosomal disorders, most of the time involving cognitive function, we support previous recommendations suggesting restraining chromosome studies to patients with syndromic forms of AMC and/or CNS involvement (4,7,32). Selection of patients would also avoid array-

CGH incidental findings or complex interpretation of VUS as it happened for a significant number of patients here. Of note, our cases highlight the contribution of conventional karyotype. While array-CGH would have identified those defects, karyotype was essential to unravel causal mechanisms, which is of major importance for genetic counselling. Nevertheless, with the advent of CNV detection by WGS, karyotype as a first line investigation remains questionable.

Among patients from group 3O, as a consequence of our referral bias, we had no cases of molecularly confirmed neuromuscular disorders although it is described as a major cause of AMC in previous studies (6,33,45). However, we got four cases of congenital conjunctive or bone tissue disorders including two that had a molecular characterization, whereas this cause is rarely mentioned in other cohorts. Furthermore, there were two cases of environmental causes due to severe pregnancy complications, leading to a proportion of 1.6%, whereas previous reports had rates of 3.2-7.1% (29–31). These higher rates are due to the inclusion of uterine malformations as a cause of AMC. Here we reported uterine anomalies in six mothers, in line with the reported frequency of 2 to 4% in other series of AMC patients (34) but also with the frequency in the general women population (46). Previous reports suggested that these malformations are not a major cause of AMC but that it could instead increase the severity of previously existing and independent limitations. The diagnosis of environmental causes has major implications in terms of genetic counselling and osteoarticular prognosis and must not be held by excess (46).

Finally, among patients with atypical Amyoplasia, we identified a yet uncharacterized clinical presentation resulting from a neurogenic pattern which involving C7-C8-T1 motor roots and resembling Klumpke's obstetrical palsy. This may suggest a similar pathophysiological mechanism with what is supposed in Amyoplasia, but other patients need to be described to conclude formally.

In our cohort, nearly 40% of patients had no definitive diagnosis and this number reached 56% when excluding patients with a clinical diagnosis, mostly group 3 patients. For a part of them there was a strong clinical suspicion that had not been molecularly characterized yet. As wide or untargeted NGS methods became available only recently, few patients had been tested hitherto. For another subset of patients, results were still pending, mostly

because these technics require much time for their complex interpretation. As a consequence, it was difficult to estimate the yield of NGS in our cohort. In previous studies using WES in cohorts of AMC patients, diagnostic rate was estimated around 55% (52-58.3%) (33,37,45). We thus expect to increase soon our proportion of diagnosed patients by 10-20%, since this technology along with WGS will be of growing use in the future. Apart from solving previously undiagnosed cases, it will also enable to lower age at diagnosis, improving management and genetic counselling for parents in age of expanding their family. Finally, it will facilitate identification of new genes and expand our knowledge of pathophysiological pathways leading to AMC.

2/ AMC diagnostic assessment : delineating indications for each investigation

Based both on the observation of aetiological diagnostic management of AMC in our cohort and on a literature review, we attempted to determine the diagnostic value and relevance of each paraclinical investigation that could be conducted. We classified them into five main groups.

2.A/ Widely performed and non-invasive investigations

➤ CK dosage

CK levels are used as a diagnosis biomarker for neuromuscular diseases, more specifically for muscular dystrophies. Their dosage is thus mandatory in case of muscle weakness, doughy or decreased muscle mass and in case of a progressive course. It has to be performed with peculiar precaution to avoid false positive results. In this study, dosage was rarely reported, especially in group 2, probably because DA phenotypes are most often clearly distinguishable from muscular dystrophies and because of our referral bias. In our literature review, we determined that CK levels were highly elevated (i.e. more than ten times normal ranges) in patients with muscular dystrophies, anterior horn cell affections such as SMA Lower Extremity Dominant (SMALED) type 2 or musculo-contractural Ehlers-Danlos syndrome, while intermediate levels were detected in patients with *TRPV4* neuropathic AMC or AMC

associated with congenital myopathy due to *TTN* variants. Interestingly, DA2B patients bearing *TPM2* variants may also present with intermediate levels (32) but unfortunately, none of our two patients with *TPM2* variants had a CK level determination.

➤ *Associated organ impairment assessment*

A global morphological check-up was frequently performed in our cohort, with a striking enrichment in group 3, as expected.

Cardiac, genitourinary and gastro-intestinal malformations are found in many syndromes associated with AMC. Cardiac anomalies are also present in myopathies and muscular or myotonic dystrophies but have never been described neither in Amyoplasia nor in DA. Indeed, here, cardiac explorations unravelled mainly nonspecific features in these groups. While genitourinary and gastro-intestinal malformations are not common in DA, renal agenesis, dilated ureter or transient hydronephrosis have been mentioned in Amyoplasia (12). Indeed, the latest feature was found in two Amyoplasia patients of our cohort, but as it is quite frequent in the general population and as it was only rarely mentioned in Amyoplasia patients so far, it did not contribute to establish the diagnosis. Abdominal wall defects are more common in Amyoplasia, usually evident at birth or antenatally. In contrast, in group 3, described anomalies were globally less common, more specific or cumulative. For instance, the association of septal defect and kidney hypoplasia was a further evidence motivating *KAT6B* sequencing in subject 110.

While eye fundus and electrophysiological studies were unremarkable, specific ophthalmological features were found to be a clue to guide the diagnostic process of many patients. Indeed, ophthalmologic characteristics found in DA have been extensively described (47) and we now know that epicanthus, blepharophimosis or short palpebral fissures, ophthalmoplegia, keratoconus and retinopathies are common in *PIEZO2* mutated individuals (21), as we showed here, while patients with *ECEL1* mutations may exhibit ptosis, lagophthalmos, pseudo-exophthalmos and Duane syndrome (22). In addition, other ocular anomalies of various types have been reported in genetic or infectious disorders with AMC. As a result, a special attention to these features has to be paid at time of first clinical evaluation for all AMC cases to best guide the diagnosis. A more thorough evaluation

comprising an eye fundus and a slit-lamp examination should be undergone as part of the global assessment, especially in group 3.

In conclusion, CK dosage and associated organ impairment assessment comprising cardiological US, abdominal US and ophthalmological explorations are non-invasive, easily available, cost effective methods. Hence, although they have greatest interest in group 3, we suggest that they can be used in first line in AMC patient, especially in new-borns.

2.B/ CNS explorations (cMRI, tcUS, EEG) are indicated for group 3C only

Brain explorations were frequently performed in our cohort. We note that although it was mostly done in group 3C, a significant proportion of the other groups was investigated as well.

➤ Brain imaging

Causes of central forms of AMC are numerous, with miscellaneous pathophysiological mechanisms involved and genes implied and thus a wide variety of clinical presentation (4). They comprise syndromic forms of AMC (chromosomal abnormalities or other) as well as purely neurologic disorders or even neuromuscular disorders. Most often, AMC is not constant in a given syndrome, but is reported only in the most severe end of the spectrum of clinical presentations, making the diagnosis even more important for prognosis and genetic counselling (48). AMC with CNS involvement stands as one of the three groups of Hall classification, together with lethal forms (4). The proportion of these patients is usually around 30% (5,6,29) but ranges from 11.4 to 48% (7,30) depending on enrolment criteria. From another point of view, ID with or without structural brain anomalies, is reported in about 25% of AMC syndromes (1,6,13).

In neurogenic forms, brain anomalies are frequent (49). Specific features clearly guide the diagnosis. Here, polymicrogyria appears clearly as a frequent sign associated with AMC, as previously described (30). However, this cortical anomaly is not an aetiological diagnosis *per se* since it may result from miscellaneous genetic disorders. As foetal MRI cannot be performed before the third semester of pregnancy, determining the genetic cause is of major importance for genetic counselling and early diagnosis. Apart from specific findings,

nonspecific anomalies may as well help in the diagnostic procedure, providing additional evidences toward a diagnosis. For instance, we found enlarged ventricles in a female patient deleted for *ZC4H2*, a finding in accordance with recent reports indicating brain atrophy in 23% of females with *ZC4H2* variants (41). Interestingly, structural brain anomalies have been reported in Amyoplasia but are thought to occur as a consequence of vascular compromise and prematurity, or due to an independent affection (12,33,50). Brain imaging of patient 22, diagnosed as typical Amyoplasia and for who several unspecific anomalies were evidenced, need to be re-analysed to determine whether this hypothesis is plausible or not.

As a summary, we support the realization of a brain imaging for any abnormality at neurological evaluation, especially poor axial tone or alertness anomaly. If neurological involvement is clear, a cMRI should be performed straight away while in doubtful situations, tcUS may be performed to guide the decision and a neurological examination should be renewed at latter state. Indeed, although non radiant, cMRI is a costly investigation with restricted access, that may require anaesthesia depending on the age, whereas tcUS is non-invasive and easily available, although less sensitive for complex malformations or white mater lesions (51). If required, timing has to be questioned as far as possible. It is important to keep in mind that while CNS imaging is useful to provide developmental prognosis, it badly predicts contractures severity. Indeed, in AMC causes involving both central and peripheral nervous system such as *ZC4H2* mutations, contractures are likely to be rather linked to peripheral nervous system involvement and might progress independently from the central nervous impairment (48).

➤ *Electroencephalogram*

Many central forms of AMC are associated with epilepsy. Hence the usefulness of EEG in this group makes no doubt and was demonstrated here. Epilepsy has never been described in Amyoplasia nor in DA, except in a doubtful case report of DA2A syndrome without molecular confirmation (52). Therefore, in those two groups, with the exception of hypotonia, warning signs that indicate EEG and furthestmost positive results may lead to reconsider the diagnosis. However, as hypotonia is challenging to assess in AMC patients in the neonatal period, and as EEG is non-invasive, an overuse of this exploration has limited consequences.

2.C/ Neuromuscular explorations (MB, ENMG) are invasive and of poor interest

While MB and ENMG were more rarely performed in this study than in previous cohort with a neuromuscular referral (30), it had been proposed to a significant number of group 1 and group 2 patients.

➤ Muscle biopsy

MB is mostly used in paediatrics to investigate muscle weakness or gross motor delay with or without elevated CK. In these indications pathological yield reaches 60-80% with mainly diagnosis of congenital myopathies or muscular dystrophies (53,54). Our literature review showed that in DA and Amyoplasia, MB were either negative or nonspecific. In other types of AMC, specific lesions might help to better delineate the diagnosis of congenital myopathies, peripheral neuropathies and motoneuron disorders (32). In our cohort, MB was of poor interest if ever contradictory. It slightly narrowed the spectrum of aetiological hypothesis in two patients, one with atypical Amyoplasia and the other with DA, for whom no molecular diagnosis was available. In group 3 it contributed to discard mitochondrial disorders that could be investigated by other means.

MB is an expensive and invasive procedure requiring in children anaesthesia or sedation and leads to aesthetic sequelae. The choice of muscle is crucial to avoid uncontributed histology examination because of lack of muscle or a too severely damaged one, which happened in a significant number of our patients. Given these elements and the little impact on aetiological diagnosis, we suggest that MB should be performed as an ultimate diagnostic tool only in patients for whom there is clinical suspicion of an underlying congenital myopathy, neuropathy, motor neuron disease and in atypical Amyoplasia or DA cases, or in case of suspicion of mitochondrial dysfunction, when the diagnosis cannot be established using other less invasive methods. Ultimately, it can sometimes be essential in the interpretation of VUS identified by NGS. If MB is indicated, a muscle MRI or at least a muscle echography has to be performed to select the optimal location for biopsy, and it should be performed at time of surgery, which is frequent in AMC patients.

➤ Electroneuromyography

ENMG allows to sort out and diagnose anterior horn cell diseases or neuropathies and may as well point out toward myopathies. In the literature, ENMG is mostly useful in neurogenic forms of AMC, with an electrophysiological diagnostic yield of 100% that drops to 34-56% in myopathic forms (32,55,56). Concerning Amyoplasia, while a neurogenic pattern suggestive of segmental motor neuropathy is expected, a large subset of Amyoplasia patients have normal ENMG (14,29,55), a heterogeneity probably explained by variable choice of studied muscles between patients, and illustrated in our cohort.

ENMG is an operator dependant, invasive and painful procedure. Its full completion requires cooperation of the patient and its interpretation is therefore particularly challenging in young children, explaining low diagnostic values in this age group (55,57). It might be even more arduous in patients presenting with severely atrophic or absent muscles, and studied muscle have to be carefully selected. Nevertheless, we show that ENMG could be of major interest to corroborate clinical feeling of atypical Amyoplasia, and that it may provide additional elements to guide the diagnosis. Altogether, we suggest that ENMG should be performed only in second line in patients with peripheral presentation when the clinical distinction between a neurogenic and myopathic involvement is doubtful. Atypical Amyoplasia with suggestive impairment of distal motor roots C7 to D1 is an appropriate indication. When needed, ENMG should be optimally performed in a child old enough to cooperate, and by a neurologist used to work with children, in order to optimise diagnostic yields.

2.D/ Reflection about spinal cord explorations (scMRI, scUS)

Literature suggests that AMC involving spinal cord represents around 23% of cases, among which anterior horn impairment leading to Amyoplasia is a major cause (6) followed by infantile or X-linked SMA and pontocerebellar hypoplasia (PCH) type 1 (30). While many authors published their data on spinal cord autopsy, data on spinal cord imaging in AMC patients are rare, especially in Amyoplasia. In SMA, scMRI is either found normal (58,59) or shows localized narrowing (60) while in type 1 PCH, scMRI appears unremarkable (61). More

globally, abnormal medullar findings have been described for various, uncharacterized neurogenic forms of AMC with or without cerebral structural defects, with mainly diffuse or focal atrophy linked with dysgenesis of the anterior horns (49). Interestingly, whole spinal cord thinning was reported in cases of Zika virus infection associated with AMC (62). Apart from purely neurogenic forms, abnormal spinal cord termination level has been reported in cases of caudal regression syndrome, that may be associated with contractures (63).

In our cohort, spinal cord imaging was mostly performed in group 1, probably due to their presentation suggestive of anterior horn impairment. It provided findings that did not explain AMC and that are frequently seen in the general population. Low-lying or tethered conus medullaris are at risk for tethered cord syndrome (TCS) which causes progressive neurological symptoms such as back pain, scoliosis, bowel or bladder dysfunctions and neurological motor or sensitive deficits of the lower extremities that can delay motor milestones or induce foot deformity (64). The discovery of asymptomatic low-lying or tethered conus medullaris requires to set up a regular medical follow-up, looking for signs of TCS and, in case of symptoms, to question surgical management in order to prevent neurologic deterioration (65). To our knowledge, only one publication reported arthrogyrosis as a possible cause of TCS (66). However, more data are needed and whether AMC is a contributing factor, or a co-occurring finding remains to be determined.

Localized or generalized dilation of the central canal is a feature that can be transient in healthy new-borns and that can persist with time without any symptoms in the absence of other malformations such as Chiari malformation (67). However, a full medullar imaging followed by regular scMRI associated to a clinical follow up appear to be essential to insure stability of the lesion and absence of neurological signs (68).

No neural tube defects were observed in our patients, although their association with congenital contractures of lower limbs have been extensively described, since they lead to limitation of AFM (4,69,70). In addition, these defects can be part of more global syndromic forms of AMC such as trisomy 18. Most of them are diagnosed antenatally or at birth in case of lumbosacral lesion or cutaneous stigmata and might thus skip genetic consultations.

Overall, our data suggest that there is little benefit to perform scMRI in AMC patients in for diagnostic purposes in the absence of specific suspicion of spinal cord lesions,

considering its complexity and high cost. However, if a cMRI is required and before any spine surgery, a scMRI should be done to look for associated spinal lesions. Otherwise, scUS appears to be a convenient non-invasive method to propose in the first three months of life of children, looking either for common spinal lesions that could worsen patients' prognosis, or for neural tube defects if contractures are limited to lower limbs, in addition to usual warningsigns.

2.E/ More rarely performed investigation that require specific indications

➤ DMPK, 15q11.2q13 locus and SMN1 analyses

These analyses investigate quite frequent genetic disorders and require specific laboratory methods, often easily available in secondary unit cares. Hence, they are often performed straight away in neonatal care units for hypotonic children in spite of a low expected diagnostic yield, as illustrated here.

Myotonic dystrophy type 1 (MD1), or Steinert's disease, is a frequent cause of foetal hypo or akinesia, with a prevalence of 1/8000. It results from a CTG expansion in the *DMPK* gene, undetectable by NGS methods. Up to 20% of these patients have been reported with AMC (71). Conversely in AMC cohorts, MD1 is found in 3-7.4% of cases (6,31). Contractures typically involve the feet but may be present at multiple joint levels even without distal limb contractures (71,72). *DMPK* triplet expansion was mostly sought in group 3 where severe hypotonia is most frequent. Severe generalized hypotonia is a relevant motive to consider this analysis in AMC patients, especially if other suggesting signs of Steinert's disease exist, i.e. respiratory insufficiency, facial diplegia and diminished deep tendon reflexes without fasciculations. Prenatal history of polyhydramnios, family history and clinical signs in the mother (facial paresis, myotonia, neuropsychological signs) are also strong arguments for this clinical hypothesis that should be looked for.

In our study, Prader Willi Syndrome (PWS) was questioned independently of patients' final diagnosis, certainly because of the cognitive prognostic and the interest of an early diagnosis to institute a growth hormone therapy within the first year of life. The occurrence of AMC seems to be a very rare event in this syndrome and has *per se* only been described in two

patients (73,74). Single level distal contractures such as adducted thumbs or mispositioned toes have more frequently been described (75,76). Of note, one patient exhibiting PWS was excluded from the cohort because revision of her medical file indicated that she did not *stricto sensu* presented with AMC, since she only had a unilateral talus foot with overlapping toes that did respond well to physical therapy within a few weeks. While 15q11.2q13 paternal allele deletions, the major mechanism leading to PWS, would be detected using array-CGH, methylation anomalies require specific investigations. This should be thus only considered in severely hypotonic patients of group 3C when contractures are mild and distal, especially if they are associated to other classical signs of PWS i.e. lethargy, feeding difficulties with poor sucking and failure to thrive, genital hypoplasia or cryptorchidism in males, or characteristic facial features.

Deletion analysis of *SMN1* was mostly performed in group 1 probably because these patients present with features suggestive of anterior horn impairment with notably areflexia. Homozygous deletion of *SMN1* leads to typical or 5q Spinal Muscular Atrophy (SMA), the second most frequent recessive genetic disorder (1/6000 – 10 000 live births, all types included (77)) with a high prevalence of heterozygous deletion carriers. In SMA, cases for whom arthrogryposis had been reported in the literature are relatively rare and all presented with the most severe type 0 SMA (78–80). This type is much rarer (1/300 000 (78)) and presents at birth with severe hypotonia with respiratory and facial involvement and areflexia. We therefore suggest limiting *SMN1/SMN2* analyses at least to severe neonatal hypotonia, and furthermore if the other signs of type 0 are present. In case of clinical suspicion, *SMN1* needs to be specifically studied since its analysis with NGS is challenging. However, non 5q SMA due to *TRPV4*, *BICD2* or *DYNC1H1* mutations, that can be distinguished from *SMN1* proximal SMA on several features (81), are often described in association with arthrogryposis (81–84). As clinical variability is wide and as some patients may as well have severe neonatal presentations (84), NGS with specific focus on those genes need to be performed if *SMN1* analysis is normal, especially if MRI unravels perisylvian polymicrogyria, a possible feature of *BICD2* and *DYNC1H1* cases (85).

➤ Other cytogenetic investigations

In respectively three and two patients, 22q11.2 microdeletion and Fragile-X syndromes were investigated. These are two frequent genetic disorders; one is the most common interstitial chromosomal microdeletion in humans and the other stands as the first molecular cause of mental retardation in boys. They have been extensively described in the literature and joint contractures are not known as a classic feature (86,87). While we did not find association of AMC with Fragile-X syndrome resulting from a CGG expansion, we found few occurrences of 22q11.2 locus anomalies. However, all cases were either atypical in terms of clinical presentation or breakpoints, or there was low evidence to assess AMC. Therefore, targeted 22q11.2 locus and X-fragile analysis shouldn't be performed in first line to investigate AMC patients. Given their frequency, the diagnosis of one of these syndromes in AMC children has to raise the hypothesis of co-existing disorders, and other investigations need to be performed to explain AMC.

Of note, only one of our patients had a skin biopsy for karyotyping and 12p tetrasomy research. Somatic mosaicism has been reported as a frequent feature in arthrogryposis patients, for chromosomal anomalies as well as monogenic syndromes (4,37,88). As suggested by some authors, fibroblasts cultures might be useful for patients with central involvement when no diagnosis is obtained despite thorough genetic investigations (4).

➤ Acetylcholine receptor (AChR) and muscle specific kinase (MuSK) antibodies

Maternal myasthenia gravis (MG) is due to the development of auto antibodies targeting mainly AChR and more rarely MuSK or low-density lipoprotein receptor-related protein 4 (LRP4) (89,90). Incidence is of 5-10 per million per year, women being more prone to develop the disease in early adulthood (91). Transplacental transmission of maternal antibodies may cause, in about 10-15% of cases, a condition called transient neonatal myasthenia gravis (TNMG), and even more rarely a persistent myopathy called « foetal AChR inactivation syndrome » (92–94). In addition, antibodies that target specifically the foetal γ subunit of AChR, that switches at around 30WG for a ϵ subunit in the adult form (95), can be associated with cases of foetal arthrogryposis, ranging from mild contractures to perinatal death (96). The rate of children with skeletal anomalies born from mothers with MG has been

recently estimated to be around 3.9% in a cohort of 127 births (94), whereas no case of MCC were reported in other large cohorts (97). Most authors report a high lethality in the foetal or neonatal period (92,94,98,99) although mild contractures or favourable skeletal outcomes are also described (92,93,100,101). Conversely, in large cohorts of FADS or AMC patients, maternal AChR antibodies are identified in 1.3 to 7.1% of cases (102–104), but may be absent (7,30) as in our cohort. Concerning MuSK antibodies, arthrogryposis cases have been described only in three siblings (105) but never in large cohorts (103). Finally, no data was found about an association between LRP4 antibodies and children with arthrogryposis.

When antibodies are evidenced in a mother, risk for following pregnancies appears to be very high (92,97) and siblings of an affected child either with TNMG or AMC have an increased risk to develop either one or the other, independently of MG mother's clinical state (98). Potential treatment, such as mother thymectomy and immunoglobulins injections during pregnancy, might prevent recurrences (97,106,107). Despite the extreme rarity of this condition, it is thus important not to miss the diagnosis. As clinical presentation is wide, we suggest considering this diagnosis when no other evident one appears, especially in severe neonatal presentations or history of previously affected fetuses or children. MG signs in mother are a supplemental evidence but shouldn't be considered as an exclusion criterion since asymptomatic or only mildly affected mother are common (96). Hitherto, data are insufficient concerning MuSK and LRP4 antibodies, we thus recommend starting with AChR antibodies, and conserve mothers' serum for further antibodies explorations in case of strong clinical suspicion and negative AChR. When performed, AChR antibodies detection should be done in the mother as early as possible to be able to establish a clear correlation with newborn's symptoms.

➤ *Metabolic investigations*

Only a small part of our cohort was investigated for metabolic diseases. This proportion was much higher in other cohorts of patients enrolled by neuromuscular reference centers (30). This reflects our selection bias, further illustrated by normal results in all patients. A lower rate of consanguinity than previous reports may participate.

Metabolic disorders that first manifest in utero may lead to fetal hypo or akinesia and thus to AMC. Through a literature review, we aimed at determining for each type of metabolic disease, whether AMC cases have been described or not ([Table S10](#)).

Intoxication disorders are usually asymptomatic immediately at birth but rather start suddenly in the neonatal period after a symptom-free stage. Neurological symptoms are predominant for most of those severe disorders, and hyperammonia is the key warning sign. While urea cycle disorders seem to have never been associated to AMC, we found few cases of organic aciduria or aminoacidopathies.

Concerning energy disorders, fatty acid beta oxidation disorders have not been associated with arthrogryposis, whereas few citric acid cycle's related disorders have, all in perinatally lethal cases. In contrast, many mitochondrial disorders may affect intra uterine development and thus lead to AMC, notably Leigh syndrome for which clinical skeletal presentation may suggest Amyoplasia congenita before the onset of neurological symptoms (108). In a retrospective study of 300 patients with proven respiratory chain enzyme deficiency, congenital contractures have been reported in two patients and AMC in only one (109). Here AMC is mostly distal but may also present as generalized severe arthrogryposis (110).

Hydrops fetalis may *per se* lead to arthrogryposis. Non-immune forms may be explained by lysosomal disorders. In Gaucher disease with hydrops fetalis, arthrogryposis was reported to occur in around 19.5% of cases and often results in perinatal death (111).

As a global conclusion, metabolic disorders are rare diseases for which investigations are expensive and time-consuming. Mitochondrial disorders, citric acid cycle deficiency, and specific subtypes of other metabolic diseases have been associated with AMC. Most were reported in severe cases with neurologic involvement and most often perinatal death. We thus recommend considering global metabolic checkup for group 3 patients with severe neurological presentations, but to question targeted investigations only in strongly suggestive presentations, on the advice of a paediatrician specialized in metabolic disorders. The global check-up should comprise blood and urine amino acid analysis, organic acid test, lactate and pyruvate dosage; and ammonia has to be interpreted with caution if performed. In cases of muscular or CNS impairment associated with two other organ failures, a MRC dysfunction has to be investigated using serum and/or cerebrospinal fluid lactate and pyruvate dosage,

completed by cMRI with spectroscopy, and as a last resort with skin or muscle biopsy comprising a study of the MRC.

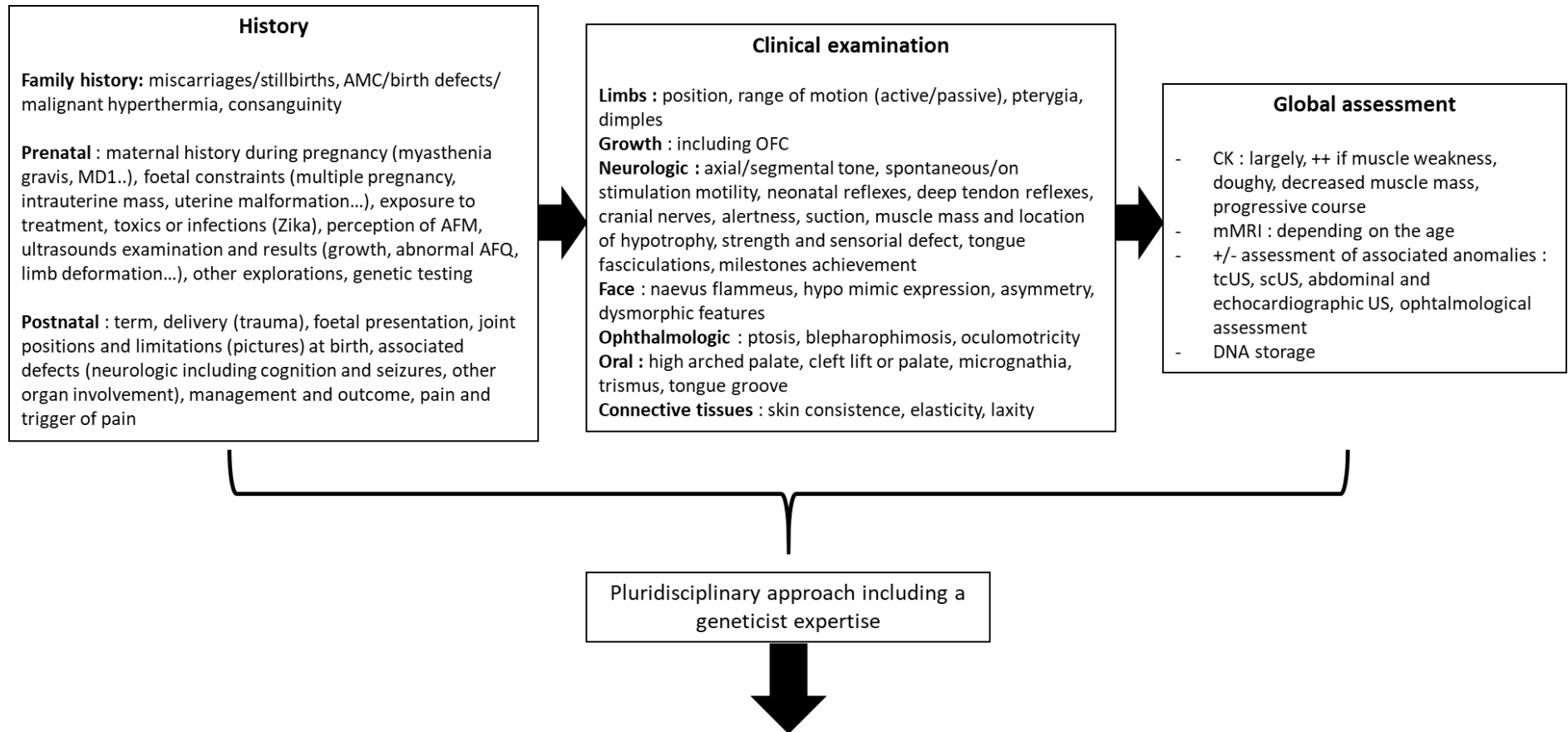
3/ AMC diagnostic assessment: synthesis of recommendations

Based on those considerations, we propose recommendations for the diagnostic management intended to all paediatrician and geneticists in charge of AMC patients (Fig. 6).

In this process, we highlight the importance of distinguishing, as soon as possible in patients' lives, Amyoplasia and DA patients from the other forms. Indeed, they are most often recognizable and together account for more than half cases of AMC. But most of all, patients presenting with these forms do not need further explorations, and indeed we showed here that many patients of group 1 and 2 had a thorough medical assessment that rarely led to relevant findings. This reflects both a poor knowledge of AMC condition, common to all rare diseases, but also the challenging clinical evaluation of AMC new-borns in the early neonatal period. Indeed, phenotypic presentations of the various forms often overlap, since they all result from reduced foetal movement. In many forms, there may be neonatal decreased limb movements, muscle mass or strength and deep tendon reflexes, making difficult to clearly categorise the patient in one group or the other. In addition, phenotypes may overlap between the three groups, especially in case of atypical presentation. It is thus tempting to perform a thorough aetiological assessment, even if most investigations are expected to turn out normal. In addition, parental reassurance is a motivation *per se* for a complete check-up. Here we thus try to provide clues at the time of familial or personal history assessment and clinical evaluation, but also suggest a set of paraclinical investigations that can be used in first line because of their harmlessness and cost-effectiveness, as opposed to those that has to be performed in specific cases, because of their invasiveness, high cost and/or low yields.

Distinguishing group 1 and group 2 straight away has two other advantages. First of all, it enables to bring a fast answer for genetic counselling: sporadic occurrence for Amyoplasia, and usually *de novo* or autosomal dominant transmission for DA with the possibility to reach a genetic diagnosis quickly thanks to the high yield of genetic investigations in this group.

A



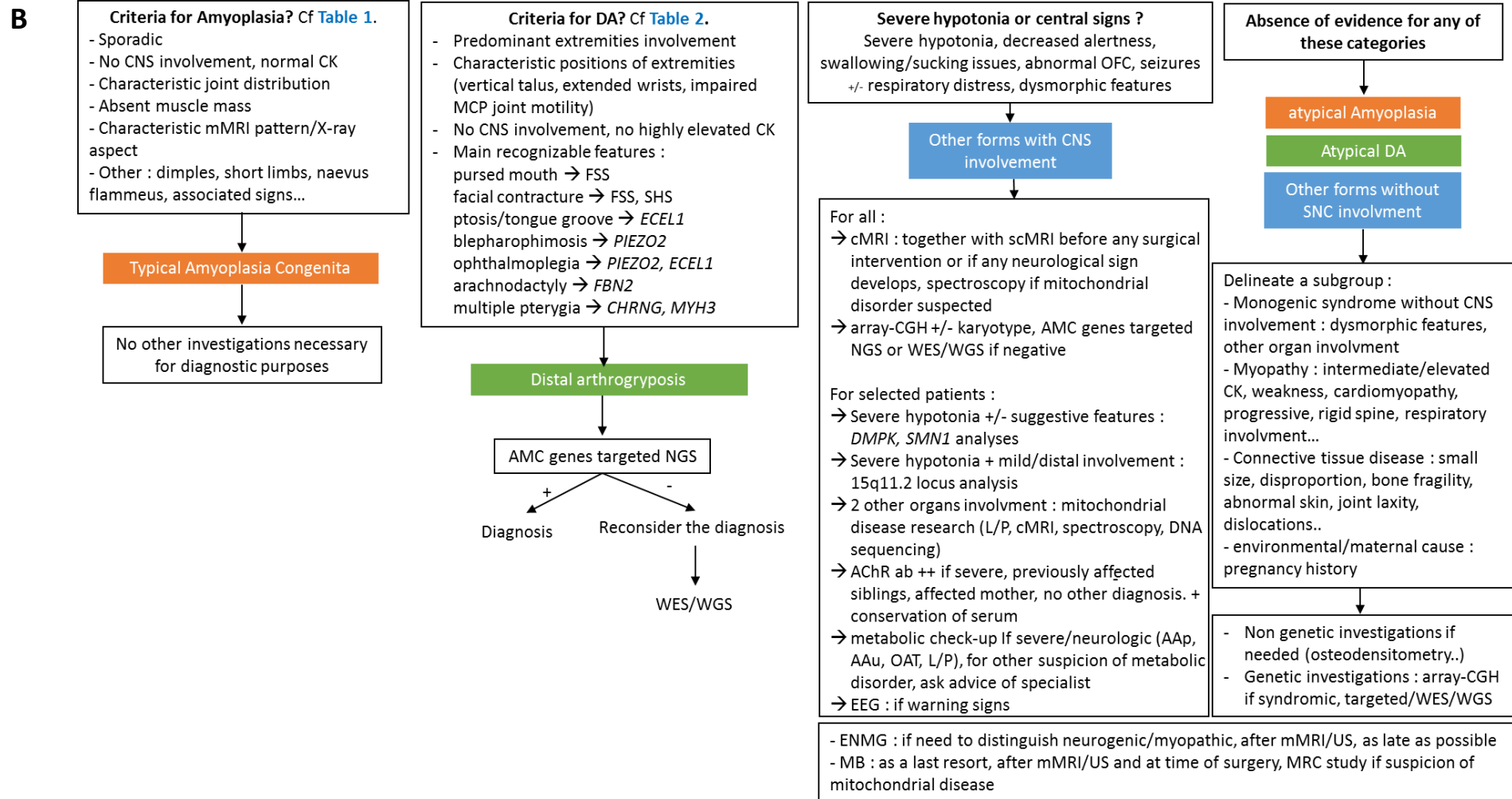


Figure 6. Proposition of recommendations in the aetiological assessment of AMC children. **A.** General recommendations for assessment of all patients. **B.** Recommendations according to the conclusions of the global assessment. Legends : AAp, AminoAcidogram in plasma; AAu, Aminoacidogram in urine; AChR ab, antibodies targeting Acetylcholine receptor; AFM, Active Foetal Movements; AFQ, Amniotic Fluid Quantity; AMC, arthrogyriposis multiplex congenita; CGH, comparative genomic hybridization; CK, creatine Kinase; cMRI, cerebral MRI; CNS, Central Nervous System; DNA, deoxyribonucleic acid; EEG, electroencephalogram; ENMG, electroneuromyogram; FSS, Freeman-Sheldon Syndrome; L/P, lactate pyruvate ratio; MB, muscle biopsy; MCP : metacarpophalangeal; MD1 : Myotonic Dystrophy type 1; mMRI, muscle MRI; MRC, mitochondrial chain respiratory study; NGS, next generation sequencing; OAT, organic acid test; OFC, occipitofrontal circumference; scMRI, spinal cord MRI; scUS, spinal cord ultrasounds, SHS, Sheldon-Hall Syndrome; tcUS, transcranial ultrasounds; US, ultrasonography; WES, whole exome sequencing; WGS, whole genome sequencing.

Secondly, it provides favourable prognosis elements: absence of intellectual impairment for both, but also favourable orthopaedic outcome in Amyoplasia. This distinction is often facilitated by the expertise of a clinical geneticist, as part of the multidisciplinary team. Meeting the genetic team is also essential in guiding and coordinating genetic investigations, as well as helping in the interpretation of NGS data.

In our centre, a mMRI is systematically proposed at each dedicated consultation for AMC patients. This method is of increasing use in the diagnostic strategy. Indeed, studies of muscle mass and infiltration identified reproducible patterns of muscle impairment distribution, first in various inherited muscular disorders such as muscular dystrophies or myopathies (112), and more recently in AMC for *ECEL1* and *CHRNG* (22,113) and more strikingly in Amyoplasia congenita (manuscript submitted). While the usefulness of this tool will soon be demonstrated in oncoming publications, our team already actively use it as an additional evidence in favour of a diagnosis especially in Amyoplasia (impairment of biceps brachii and brachialis at the upper limb, and gracilis, sartorius and tibialis anterior at the lower limbs) and *ECEL1* (long head of biceps femoris and sartorius impairment with rectus femoris conservation). In addition, it appears as a helpful tool to guide rehabilitation by discriminating completely absent muscle from thin but residual ones, although it doesn't seem that there are any correlations between muscle impairment on imaging and global function. In the future, a further benefit of mMRI will be to follow the evolution of muscle impairment through time by repeated evaluations in order to better delineate the prognosis for a given aetiology. Lastly, mMRI is a helpful to select muscle to biopsy or to study on ENMG in order to improve their yield. Altogether we recommend it in first instance, but, as it is not validated as a diagnostic tool yet, it should be only be done when the age of the patient doesn't require general anaesthesia. In addition, the expertise of a trained radiologist is mandatory, and age as well as motor milestones achievement has to be taken in account in the interpretation.

In this work, we focused on postnatal aetiological diagnostic management of AMC. Actually, this process may even start *in utero* if AMC is detected. In the absence of family history of AMC, this antenatal assessment is even more challenging, in contrast with a high need of genetic counselling at this time. Indeed, hitherto, no clear correlation has been

established between antenatal anomalies and specific causes of AMC, and investigations mostly focus on providing prognostic elements. However, information about course of pregnancy in AMC children need to be gathered to be able, as soon as the number of patients will be sufficient, to identify aetiological markers and improve the accuracy of information delivered to soon-to-be parents.

It is difficult to give precise guidelines in AMC since aetiologies are numerous and every case has its own issues. The target audience is large, and although we tried to consider all points of view, especially neonatal clinicians' one, the reality in practice is often different from theoretical considerations. The take-home message is to avoid as much as possible invasive low yield investigations made obsolete by NGS methods and that considerably increase the negative experience of the patient in this long diagnostic process. In any case, and in the absence of immediate new parental project, it may be useful to re-evaluate the child at distance in order to get sufficient hindsight on his neurodevelopment but also on the evolution of contractures and response to rehabilitation treatment. This will bring further elements that will facilitate the complex interpretation of NGS data. While an early diagnosis is useful for young parents, we have to keep in mind that a too early identification of a disease with poor cognitive prognosis might be deleterious for the establishment of the attachment relationship between the child and his parents.

4/ Limits of this study

Here, we chose a classification system rarely used by other authors, but that we daily apply during dedicated AMC patients' consultations. It nicely reflects our intellectual process and it is very convenient for communication with families (17). However, it has its own limits.

First, borders that distinguish the different groups of the classification is often difficult to delineate and categorization may be clinician dependant. Indeed, consensus criteria for Amyoplasia and DA have been established long ago but remain broad and elusive. Concerning Amyoplasia, although typical forms are easily recognizable, no criterion is constant. In addition, as there are no biochemical or molecular diagnostic marker for Amyoplasia, definition of atypical Amyoplasia is tricky, and this concept has never been clearly defined so

far. This is true also for Amyoplasia involving lower limbs only, for which confusing with neurogenic forms due to *TRPV4* mutation is possible.

Concerning DA, definition has much widened now that entities have been better delineated over the last few years, and we now know that in many presentations, contractures are not exclusively distal. Indeed, while medium calibre joints or proximal joints involvement is common in *PIEZO2*, *ECEL1* related AMC or multiple pterygia syndrome, it is also observed in CCA or even in sarcomeric forms (18). Thus, while typical presentations are easily recognizable, classification in group 2 is much more arduous for atypical cases without molecular characterization.

In addition, some symptoms may bring confusion. Clinicians have to be aware of signs previously described as specific of a given syndrome that may actually arise in many forms, such as pterygia. Also, as ID or developmental delay is inconstant in some syndromes, they may lead to classify patients in group 2 or 3O instead of 3C, as it happened in one of our patients with Aarskog syndrome and in previous studies (5,6). As well, although structural brain anomalies and ID described in Amyoplasia patients might be due to independent events (12,50), there may be misclassifications between group 1 and 3C. This may also happen with DA patients as in our study.

No classification system is fully satisfying, and as genetic basis begin to be uncovered, classification will probably have to be reconsidered following pathophysiological pathways or using multi-layered approaches (11,27). This will ultimately facilitate patients comparison between studies.

Another limit of our study is the fact that most patients were not evaluated at birth, but after they had received a more or less extensive diagnostic assessment. Thus, diagnosis was established in the light of results available so far and hence it does not reflect the situation of a neonatologist first to face the patient. In addition, the retrospective nature of data collection and the fact that most patients were followed up in other medical care centres than ours impaired exhaustivity and accuracy of data collection. For non-local patients, we were dependant on the number, nature and precision of medical sheets provided. One can suppose that this could be counterbalanced by the fact that patients were mostly coming to our centre on their own and that they were thus willing to provide the maximum of information.

However, despite parental willingness, some common paraclinical investigations that turned out to be normal, such as CK dosage, might not have been mentioned on these documents. Lastly, for non-local patients, we had no information about the explorations conducted after the clinical evaluation in our centre.

To finish, in our cohort French practices representation is questioned by the fact that 8% of our cases were children coming from other countries. We chose not to exclude them to better reflect our own practises and recruitment. This actually mainly impacted accuracy of information concerning pregnancy management, whereas information about diagnosis and therapeutic postnatal management was often as complete as for French residents. Indeed, for most of them management was co-coordinated by our team or was conducted in another medical care centre of France.

CONCLUSION

In a retrospective single centre observational study, we gathered clinical and paraclinical diagnostic data from 125 patients with AMC evaluated at a paediatric age between 2007 and 2019 in Grenoble University Hospital reference centre for developmental anomalies. Taking advantage of this data and of our clinical experience, we aimed at proposing medical practical recommendations for the diagnostic procedure of patients with AMC that could benefit all clinicians in charge of these patients. The nationwide recruitment of our patients, coming from secondary or tertiary level care centres, associated with the high number of patients gathered, enabled us to diminish referral biases and to highlight the diversity of the current medical diagnostic practices. This notably enabled us to unravel the previously undescribed importance of *PIEZO2* mutations in patients with distal arthrogryposis and of *ZC4H2* in patients with central nervous system involvement.

We propose a new classification system that prod into distinguishing straight away, as soon as possible in patient's life, the two main causes of AMC, i.e. Amyoplasia congenita and distal arthrogryposis. We discuss the relevance of all investigations that could be performed in patients and propose first that despite a poor diagnostic yield with mostly nonspecific anomalies, non-invasive and cost-effective investigations such as ultrasonography or CK dosage should be largely proposed, since they may bring further elements to guide the diagnosis. We also illustrate that invasive investigations, such as muscle biopsy or electromyoneurography, should be considered only in last intention in specific cases, and that their realization should be framed by several considerations to increase their yield. We further question the diagnostic value of other widely performed investigations such as *DMPK*, *SMN1* and 15q11-q13 locus analyses as well as metabolic investigations, whereas we emphasize the importance of chromosomal investigations, spinal cord and muscle MRI.

In this diagnostic procedure, a multidisciplinary approach is of major importance. In the next years, the increasing use of next generation sequencing technologies will increase diagnostic rates by uncovering new genes and revolutionizing our understanding of AMC physiopathology. However, a relevant phenotyping will remain paramount to facilitate wide genomic data interpretation.

THÈSE SOUTENUE PAR : Pauline LE TANNO

TITRE : “The diagnostic workup in children with Arthrogryposis Multiplex Congenita : description of practices through a monocentric cohort and suggestion of recommendations.”

CONCLUSION :

Dans cette étude rétrospective, nous avons inclus 125 patients atteints d'Arthrogrypose Multiple Congénitale (AMC), évalués à un âge pédiatrique au Centre de Référence des Anomalies du Développement du Centre Hospitalo-Universitaire Grenoble-Alpes entre 2007 et 2019. Nous avons mis en parallèle les données disponibles sur l'ensemble des examens paracliniques effectués chez ces patients tout au long de leur parcours diagnostique, notre expérience clinique, ainsi que les connaissances scientifiques rapportées dans la littérature. L'objectif était de proposer des recommandations médicales pour guider la démarche diagnostique chez ces patients, à destination de tout médecin susceptible de les prendre en charge. Le nombre significatif d'individus réunis ainsi que la variété de leurs origines, beaucoup ayant été adressés par des centres de soins secondaires ou tertiaires de toute la France, nous ont permis de réduire certains biais de recrutement et de refléter au mieux les pratiques médicales actuelles sur notre territoire. Ceci a également permis d'illustrer la part importante des mutations des gènes *PIEZO2* dans les arthrogryposes distales et *ZC4H2* chez les patients présentant une atteinte du système nerveux central, ce qui n'avait pas été relevé à ce jour.

Dans ce travail, nous proposons une nouvelle classification clinique qui pousse à distinguer au plus tôt les deux principales causes d'AMC, l'Amyoplasie congénitale et les arthrogryposes distales, des autres formes. Nous discutons de la pertinence de toutes les investigations paracliniques qui ont pu être proposées chez ces patients, et suggérons que les investigations non invasives et peu coûteuses, telles que l'échographie ou les dosages de créatine kinase, soient proposées de façon large en première intention, puisqu'elles sont susceptibles d'apporter des éléments permettant de réduire le spectre des hypothèses diagnostiques évoquées. Nous montrons également que certaines investigations, telles que la biopsie musculaire ou l'électroneuromyographie, sont de faible contribution au regard de leur

caractère invasif. Nous proposons qu'elles ne soient réalisées qu'en dernière intention dans des indications sélectionnées et qu'elles soient encadrées de certaines précautions permettant d'optimiser leur rendement. Nous précisons les indications d'autres analyses fréquemment pratiquées telles que l'étude des gènes *DMPK*, *SMN1* et du locus 15q11-q13, ainsi que celles des investigations métaboliques. Enfin nous attirons l'attention sur la valeur des investigations chromosomiques et de l'IRM musculaire, et discutons de l'impact d'analyses plus rarement pratiquées telles que la recherche d'anticorps anti-récepteurs de l'acétylcholine et de l'IRM médullaire.

Le parcours diagnostique des patients atteints d'AMC est complexe et requiert une approche pluridisciplinaire. Il sera facilité dans les prochaines années par l'utilisation croissante des techniques de séquençage de nouvelle génération, qui permettront d'augmenter les rendements, d'identifier de nouveaux gènes et d'améliorer notre compréhension des mécanismes physiopathologiques de l'AMC. Un phénotypage pertinent des patients restera cependant essentiel dans l'interprétation des données de séquençage.

VU ET PERMIS D'IMPRIMER

Grenoble, le 15 Janvier 2020:

LE DOYEN



Pr. Patrice MORAND

LE PRÉSIDENT DE LA THÈSE



Pr. Pierre-Simon JOUK

REFERENCES

1. Hall JG. Arthrogryposis multiplex congenita: etiology, genetics, classification, diagnostic approach, and general aspects. *J Pediatr Orthop B*. 1997;6(3):159- 66.
2. Cachecho S, Elfassy C, Hamdy R, Rosenbaum P, Dahan-Oliel N. Arthrogryposis multiplex congenita definition: Update using an international consensus-based approach. *Am J Med Genet C Semin Med Genet*. 2019; DOI: 10.1002/ajmg.c.31739
3. Dahan-Oliel N, Cachecho S, Barnes D, Bedard T, Davison AM, Dieterich K, et al. International multidisciplinary collaboration toward an annotated definition of arthrogryposis multiplex congenita. *Am J Med Genet C Semin Med Genet*. 2019;181(3):288- 99. DOI: 10.1002/ajmg.c.31721
4. Hall JG. Arthrogryposis (multiple congenital contractures): diagnostic approach to etiology, classification, genetics, and general principles. *Eur J Med Genet*. 2014;57(8):464- 72. DOI: 10.1016/j.ejmg.2014.03.008
5. Lowry RB, Sibbald B, Bedard T, Hall JG. Prevalence of multiple congenital contractures including arthrogryposis multiplex congenita in Alberta, Canada, and a strategy for classification and coding. *Birth Defects Res Part A Clin Mol Teratol*. 2010;88(12):1057- 61. DOI: 10.1002/bdra.20738
6. Darin N, Kimber E, Kroksmark A-K, Tulinius M. Multiple congenital contractures: birth prevalence, etiology, and outcome. *J Pediatr*. 2002;140(1):61- 7. DOI: 10.1067/mpd.2002.121148
7. Hoff JM, Loane M, Gilhus NE, Rasmussen S, Daltveit AK. Arthrogryposis multiplexa congenita: an epidemiologic study of nearly 9 million births in 24 EUROCAT registers. *Eur J Obstet Gynecol Reprod Biol*. 2011;159(2):347- 50. DOI: 10.1016/j.ejogrb.2011.09.027
8. Navti OB, Kinning E, Vasudevan P, Barrow M, Porter H, Howarth E, et al. Review of perinatal management of arthrogryposis at a large UK teaching hospital serving a multiethnic population. *Prenat Diagn*. 2010;30(1):49- 56. DOI: 10.1002/pd.2411
9. Skaria P, Dahl A, Ahmed A. Arthrogryposis multiplex congenita in utero: radiologic and pathologic findings. *J Matern Fetal Neonatal Med*. 2019;32(3):502- 11. DOI: 10.1080/14767058.2017.1381683
10. Hall JG. Pena-Shokeir phenotype (fetal akinesia deformation sequence) revisited. *Birth Defects Res Part A Clin Mol Teratol*. 2009;85(8):677- 94. DOI: 10.1002/bdra.20611
11. Hall JG, Kimber E, Dieterich K. Classification of arthrogryposis. *Am J Med Genet C Semin Med Genet*. 2019;181(3):300- 3. DOI: 10.1002/ajmg.c.31716
12. Hall JG, Aldinger KA, Tanaka KI. Amyoplasia revisited. *Am J Med Genet A*. 2014;164A(3):700- 30. DOI: 10.1002/ajmg.a.36395
13. Reed SD, Hall JG, Riccardi VM, Aylsworth A, Timmons C. Chromosomal abnormalities associated with congenital contractures (arthrogryposis). *Clin Genet*. 1985;27(4):353- 72. DOI: 10.1111/j.1399-0004.1985.tb02278.x
14. Gaitanis JN, McMillan HJ, Wu A, Darras BT. Electrophysiologic Evidence for Anterior Horn Cell Disease in Amyoplasia. *Pediatric Neurology*. 2010;43(2):142- 7. DOI: 10.1016/j.pediatrneurol.2010.03.018

15. Kimber E. Arthrogryposis. Causes, Consequences and Clinical Course in Amyoplasia and Distal Arthrogryposis [dissertation]. Göteborg : University of Gothenburg; 2009. 64 p.
16. Bamshad M, Van Heest AE, Pleasure D. Arthrogryposis: a review and update. *J Bone Joint Surg Am.* 2009;91 Suppl 4:40- 6. DOI: 10.2106/JBJS.I.00281
17. Hall JG, Kimber E, van Bosse HJP. Genetics and Classifications. *J Pediatr Orthop.* 2017;37 Suppl 1:S4- 8. DOI: 10.1097/BPO.0000000000000997
18. Kimber E, Tajsharghi H, Kroksmark A-K, Oldfors A, Tulinius M. Distal arthrogryposis: clinical and genetic findings. *Acta Paediatr.* 2012;101(8):877- 87. DOI: 10.1111/j.1651-2227.2012.02708.x
19. Putnam EA, Zhang H, Ramirez F, Milewicz DM. Fibrillin-2 (FBN2) mutations result in the Marfan-like disorder, congenital contractural arachnodactyly. *Nat Genet.* 1995;11(4):456- 8. DOI: 10.1038/ng1295-456
20. Sung SS, Brassington A-ME, Grannatt K, Rutherford A, Whitby FG, Krakowiak PA, et al. Mutations in genes encoding fast-twitch contractile proteins cause distal arthrogryposis syndromes. *Am J Hum Genet.* 2003;72(3):681- 90. DOI: 10.1086/368294
21. Coste B, Houge G, Murray MF, Stitzel N, Bandell M, Giovanni MA, et al. Gain-of-function mutations in the mechanically activated ion channel PIEZO2 cause a subtype of Distal Arthrogryposis. *Proc Natl Acad Sci USA.* 2013;110(12):4667- 72. DOI: 10.1073/pnas.1221400110
22. Dieterich K, Quijano-Roy S, Monnier N, Zhou J, Fauré J, Smirnow DA, et al. The neuronal endopeptidase ECEL1 is associated with a distinct form of recessive distal arthrogryposis. *Hum Mol Genet.* 2013;22(8):1483- 92. DOI: 10.1093/hmg/dd514
23. Toydemir RM, Rutherford A, Whitby FG, Jorde LB, Carey JC, Bamshad MJ. Mutations in embryonic myosin heavy chain (MYH3) cause Freeman-Sheldon syndrome and Sheldon-Hall syndrome. *Nat Genet.* 2006;38(5):561- 5. DOI: 10.1038/ng1775
24. Gurnett CA, Desruisseau DM, McCall K, Choi R, Meyer ZI, Talerico M, et al. Myosin binding protein C1: a novel gene for autosomal dominant distal arthrogryposis type 1. *Hum Mol Genet.* 2010;19(7):1165- 73. DOI: 10.1093/hmg/ddp587
25. Toydemir RM, Chen H, Proud VK, Martin R, van Bokhoven H, Hamel BCJ, et al. Trismus-pseudocamptodactyly syndrome is caused by recurrent mutation of MYH8. *Am J Med Genet A.* 2006;140(22):2387- 93. DOI: 10.1002/ajmg.a.31495
26. Chong JX, Burrage LC, Beck AE, Marvin CT, McMillin MJ, Shively KM, et al. Autosomal-Dominant Multiple Pterygium Syndrome Is Caused by Mutations in MYH3. *Am J Hum Genet.* 2015;96(5):841- 9. DOI: 10.1016/j.ajhg.2015.04.004
27. Kiefer J, Hall JG. Gene ontology analysis of arthrogryposis (multiple congenital contractures). *Am J Med Genet C Semin Med Genet.* 2019; DOI: 10.1002/ajmg.c.31733
28. Hall JG. An approach to congenital contractures (arthrogryposis). *Pediatr Ann.* 1981;10(7):15- 26.
29. Hageman G, Ippel EPF, Beemer FA, Pater JM de, Lindhout D, Willemse J. The diagnostic management of newborns with congenital contractures: A nosologic study of 75 cases. *American Journal of Medical Genetics.* 1988;30(4):883- 904. DOI: 10.1002/ajmg.1320300404

30. Wallach E, Walther-Louvier U, Espil-Taris C, Rivier F, Baudou E, Cances C. Arthrogryposis in children: Etiological assessments and preparation of a protocol for etiological investigations. *Arch Pediatr*. 2018; DOI: 10.1016/j.arcped.2018.05.004
31. Solotareff Fagué L. Arthrogryposes congénitales : étude descriptive de 31 cas au CHRU de Lille, entre 2005 et 2012 [dissertation]. Lille: Université du droit et de la santé 2; 2013. 57 p.
32. Dieterich K, Le Tanno P, Kimber E, Jouk P-S, Hall J, Giampietro P. The diagnostic workup in a patient with AMC: Overview of the clinical evaluation and paraclinical analyses with review of the literature. *Am J Med Genet C Semin Med Genet*. 2019;181(3):337- 44. DOI: 10.1002/ajmg.c.31730
33. Bayram Y, Karaca E, Coban Akdemir Z, Yilmaz EO, Tayfun GA, Aydin H, et al. Molecular etiology of arthrogryposis in multiple families of mostly Turkish origin. *J Clin Invest*. 2016;126(2):762- 78. DOI: 10.1172/JCI84457
34. Valdés-Flores M, Casas-Avila L, Hernández-Zamora E, Kofman S, Hidalgo-Bravo A. Characterization of a group unrelated patients with arthrogryposis multiplex congenita. *Jornal de Pediatria*. 2016;92(1):58- 64. DOI: 10.1016/j.jpmed.2015.04.008
35. Ambegaonkar G, Manzur AY, Robb SA, Kinali M, Muntoni F. The multiple phenotypes of Arthrogryposis multiplex congenita with reference to the neurogenic variant. *European Journal of Paediatric Neurology*. 2011;15(4):316- 9. DOI: 10.1016/j.ejpn.2011.01.007
36. Dai S, Dieterich K, Jaeger M, Wuyam B, Jouk P-S, Pérennou D. Disability in adults with arthrogryposis is severe, partly invisible, and varies by genotype. *Neurology*. 2018;90(18):e1596- 604. DOI: 10.1212/WNL.0000000000005418
37. Pehlivan D, Bayram Y, Gunes N, Coban Akdemir Z, Shukla A, Bierhals T, et al. The Genomics of Arthrogryposis, a Complex Trait: Candidate Genes and Further Evidence for Oligogenic Inheritance. *The American Journal of Human Genetics*. 2019;105(1):132- 50. DOI: 10.1016/j.ajhg.2019.05.015
38. Hirata H, Nanda I, van Riesen A, McMichael G, Hu H, Hambrock M, et al. ZC4H2 mutations are associated with arthrogryposis multiplex congenita and intellectual disability through impairment of central and peripheral synaptic plasticity. *Am J Hum Genet*. 2013;92(5):681- 95. DOI: 10.1016/j.ajhg.2013.03.021
39. Zanzottera C, Milani D, Alfei E, Rizzo A, D'Arrigo S, Esposito S, et al. ZC4H2 deletions can cause severe phenotype in female carriers. *American Journal of Medical Genetics Part A*. 2017;173(5):1358- 63. DOI: 10.1002/ajmg.a.38155
40. Okubo Y, Endo W, Inui T, Suzuki-Muromoto S, Miyabayashi T, Togashi N, et al. A severe female case of arthrogryposis multiplex congenita with brain atrophy, spastic quadriplegia and intellectual disability caused by ZC4H2 mutation. *Brain and Development*. 2018;40(4):334- 8. DOI: 10.1016/j.braindev.2017.11.011
41. Frints SGM, Hennig F, Colombo R, Jacquemont S, Terhal P, Zimmerman HH, et al. Deleterious de novo variants of X-linked ZC4H2 in females cause a variable phenotype with neurogenic arthrogryposis multiplex congenita. *Human Mutation*. Dec 2019;40(12):2270-2285.
42. Gonzalez CH, Sommer A, Meisner LF, Elejalde BR, Opitz JM. The trisomy 4p syndrome: case report and review. *Am J Med Genet*. 1977;1(2):137- 56. DOI: 10.1002/ajmg.1320010202

43. Sebold C, Roeder E, Zimmerman M, Soileau B, Heard P, Carter E, et al. Tetrasomy 18p: Report of the molecular and clinical findings of 43 individuals. *American Journal of Medical Genetics Part A*. 2010;152A(9):2164- 72. DOI: 10.1002/ajmg.a.33597
44. Karimzad Hagh J, Liehr T, Ghaedi H, Mossalaeie MM, Alimohammadi S, Inanloo Hajiloo F, et al. Prenatal Diagnosis of Mosaic Tetrasomy 18p in a Case without Sonographic Abnormalities. *Int J Mol Cell Med*. 2017;6(1):61- 5.
45. Laquériere A, Maluenda J, Camus A, Fontenas L, Dieterich K, Nolent F, et al. Mutations in CNTNAP1 and ADCY6 are responsible for severe arthrogryposis multiplex congenita with axoglial defects. *Hum Mol Genet*. 2014;23(9):2279- 89. DOI: 10.1093/hmg/ddt618
46. Hall JG. Uterine structural anomalies and arthrogryposis-death of an urban legend. *Am J Med Genet A*. 2013;161A(1):82- 8. DOI: 10.1002/ajmg.a.35683
47. Pallotta R, Ehresmann T, Fusilli P. Ocular findings in distal arthrogryposis. *Ophthalmic Genet*. 2001;22(2):125- 30. DOI: 10.1076/opge.22.2.125.2232
48. Dieterich K, Kimber E, Hall JG. Central nervous system involvement in arthrogryposis multiplex congenita: Overview of causes, diagnosis, and care. *Am J Med Genet C Semin Med Genet*. 2019;181(3):345- 53. DOI: 10.1002/ajmg.c.31732
49. Fedrizzi E, Botteon G, Inverno M, Ciceri E, D'Incerti L, Dworzak F. Neurogenic arthrogryposis multiplex congenita: clinical and MRI findings. *Pediatr Neurol*. 1993;9(5):343- 8. DOI: 10.1016/0887-8994(93)90102-i
50. Kamien B, Zankl A, Gabbett M. Septo-optic dysplasia and associations with amyoplasia and gastroschisis. *Birth Defects Res Part A Clin Mol Teratol*. 2010;88(6):497- 501. DOI: 10.1002/bdra.20663
51. Llorens-Salvador R, Moreno-Flores A. The ABCs of transfontanellar ultrasound and more. *Radiologia*. 2016;58 Suppl 2:129- 41. DOI: 10.1016/j.rx.2016.02.007
52. Sackey A, Coulter B, Fryer A, Van Velzen D. Epilepsy in the Freeman Sheldon Syndrome. *J Child Neurol*. 1995;10(4):335- 7. DOI: 10.1177/088307389501000421
53. Gibreel WO, Selcen D, Zeidan MM, Ishitani MB, Moir CR, Zarroug AE. Safety and yield of muscle biopsy in pediatric patients in the modern era. *J Pediatr Surg*. 2014;49(9):1429- 32. DOI: 10.1016/j.jpedsurg.2014.02.079
54. Thavorntanaburt S, Tanboon J, Likasitwattanakul S, Sangruchi T, Nishino I, Ngercham M, et al. Impact of muscle biopsy on diagnosis and management of children with neuromuscular diseases: A 10-year retrospective critical review. *J Pediatr Surg*. 2018;53(3):489- 92. DOI: 10.1016/j.jpedsurg.2017.06.006
55. Kang PB, Lidov HGW, David WS, Torres A, Anthony DC, Jones HR, et al. Diagnostic value of electromyography and muscle biopsy in arthrogryposis multiplex congenita. *Ann Neurol*. 2003;54(6):790- 5. DOI: 10.1002/ana.10769
56. Rabie M, Jossiphov J, Nevo Y. Electromyography (EMG) accuracy compared to muscle biopsy in childhood. *J Child Neurol*. 2007;22(7):803- 8. DOI: 10.1177/0883073807304204
57. Dubowitz V. *Muscle disorders in childhood*. 2nd edition. London: WB Saunders; 1995. 460 p.

58. Rossor AM, Oates EC, Salter HK, Liu Y, Murphy SM, Schule R, et al. Phenotypic and molecular insights into spinal muscular atrophy due to mutations in BICD2. *Brain*. 2015;138(Pt 2):293- 310. DOI: 10.1093/brain/awu356
59. Mercuri E, Messina S, Kinali M, Cini C, Longman C, Battini R, et al. Congenital form of spinal muscular atrophy predominantly affecting the lower limbs: a clinical and muscle MRI study. *Neuromuscul Disord*. 2004;14(2):125- 9. DOI: 10.1016/j.nmd.2003.09.005
60. Russell EJ. Cervical disk disease. *Radiology*. 1990;177(2):313- 25. DOI: 10.1148/radiology.177.2.2217760
61. Görden-Pauly U, Sperner J, Reiss I, Gehl HB, Reusche E. Familial pontocerebellar hypoplasia type I with anterior horn cell disease. *Eur J Paediatr Neurol*. 1999;3(1):33- 8. DOI: 10.1053/ejpn.1999.0177
62. de Souza AS, de Oliveira-Szjenfeld PS, de Oliveira Melo AS, de Souza LAM, Batista AGM, Tovar-Moll F. Imaging findings in congenital Zika virus infection syndrome: an update. *Childs Nerv Syst*. 2018;34(1):85- 93. DOI: 10.1007/s00381-017-3637-1
63. Bicakci I, Turgut ST, Turgut B, Icgasioglu A, Egilmez Z, Yumusakhuylu Y. A case of caudal regression syndrome: walking or sitting? *Pan Afr Med J*. 2014;18:92. DOI: 10.11604/pamj.2014.18.92.3683
64. Sanchez T, John RM. Early identification of tethered cord syndrome: a clinical challenge. *J Pediatr Health Care*. 2014;28(3):e23-33. DOI: 10.1016/j.pedhc.2013.06.007
65. Solmaz I, Izci Y, Albayrak B, Cetinalp E, Kural C, Sengul G, et al. Tethered cord syndrome in childhood: special emphasis on the surgical technique and review of the literature with our experience. *Turk Neurosurg*. 2011;21(4):516- 21. DOI: 10.5137/1019-5149.JTN.4394-11.1
66. McGirt MJ, Mehta V, Garces-Ambrossi G, Gottfried O, Solakoglu C, Gokaslan ZL, et al. Pediatric tethered cord syndrome: response of scoliosis to untethering procedures. *Clinical article. J Neurosurg Pediatr*. 2009;4(3):270- 4. DOI: 10.3171/2009.4.PEDS08463
67. Jinkins JR, Sener RN. Idiopathic localized hydromyelia: dilatation of the central canal of the spinal cord of probable congenital origin. *J Comput Assist Tomogr*. 1999;23(3):351- 3. DOI: 10.1097/00004728-199905000-00004
68. Jones BV. Cord Cystic Cavities: Syringomyelia and Prominent Central Canal. *Semin Ultrasound CT MR*. 2017;38(2):98- 104. DOI: 10.1053/j.sult.2016.07.008
69. Kowalczyk B, Feluś J. Arthrogryposis: an update on clinical aspects, etiology, and treatment strategies. *Arch Med Sci*. 2016;12(1):10- 24. DOI: 10.5114/aoms.2016.57578
70. Westcott MA, Dynes MC, Remer EM, Donaldson JS, Dias LS. Congenital and acquired orthopedic abnormalities in patients with myelomeningocele. *Radiographics*. 1992;12(6):1155- 73. DOI: 10.1148/radiographics.12.6.1439018
71. Schilling L, Forst R, Forst J, Fajak A. Orthopaedic Disorders in Myotonic Dystrophy Type 1: descriptive clinical study of 21 patients. *BMC Musculoskelet Disord*. 2013;14:338. DOI: 10.1186/1471-2474-14-338
72. Martinello F, Piazza A, Pastorello E, Angelini C, Trevisan CP. Clinical and neuroimaging study of central nervous system in congenital myotonic dystrophy. *J Neurol*. 1999;246(3):186- 92. DOI: 10.1007/s004150050332

73. Denizot S, Boscher C, Le Vaillant C, Rozé JC, Gras Le Guen C. Distal arthrogryposis and neonatal hypotonia: an unusual presentation of Prader-Willi syndrome (PWS). *J Perinatol.* 2004;24(11):733- 4. DOI: 10.1038/sj.jp.7211185
74. Bigi N, Faure J-M, Coubes C, Puechberty J, Lefort G, Sarda P, et al. Prader-Willi syndrome: is there a recognizable fetal phenotype? *Prenat Diagn.* 2008;28(9):796- 9. DOI: 10.1002/pd.1973
75. Klinge L, Scott RC, de Sousa C. Neonatal subdural and extradural haemorrhage in Prader-Willi syndrome. *Neuropediatrics.* 2001;32(4):221- 2. DOI: 10.1055/s-2001-17379
76. Oiglane-Shlik E, Zordania R, Varendi H, Antson A, Mägi M-L, Tasa G, et al. The neonatal phenotype of Prader-Willi syndrome. *Am J Med Genet A.* 2006;140(11):1241- 4. DOI: 10.1002/ajmg.a.31223
77. Prior TW, Snyder PJ, Rink BD, Pearl DK, Pyatt RE, Mihal DC, et al. Newborn and carrier screening for spinal muscular atrophy. *Am J Med Genet A.* 2010;152A(7):1608- 16. DOI: 10.1002/ajmg.a.33474
78. Grotto S, Cuisset J-M, Marret S, Drunat S, Faure P, Audebert-Bellanger S, et al. Type 0 Spinal Muscular Atrophy: Further Delineation of Prenatal and Postnatal Features in 16 Patients. *J Neuromuscul Dis.* 2016;3(4):487- 95. DOI: 10.3233/JND-160177
79. Bürglen L, Amiel J, Viollet L, Lefebvre S, Burlet P, Clermont O, et al. Survival motor neuron gene deletion in the arthrogryposis multiplex congenita-spinal muscular atrophy association. *J Clin Invest.* 1996;98(5):1130- 2. DOI: 10.1172/JCI118895
80. Falsaperla R, Romeo G, Di Giorgio A, Pavone P, Parano E, Connolly AM. Long-term survival in a child with arthrogryposis multiplex congenita and spinal muscular atrophy. *J Child Neurol.* 2001;16(12):934- 6. DOI: 10.1177/088307380101601213
81. Guillot N, Cuisset J-M, Cuvellier J-C, Hurtevent J-F, Joriot S, Vallee L. Unusual clinical features in infantile Spinal Muscular Atrophies. *Brain Dev.* 2008;30(3):169- 78. DOI: 10.1016/j.braindev.2007.07.008
82. McEntagart M. TRPV4 axonal neuropathy spectrum disorder. *Journal of Clinical Neuroscience.* 2012;19(7):927- 33. DOI: 10.1016/j.jocn.2011.12.003
83. Scoto M, Rossor AM, Harms MB, Cirak S, Calissano M, Robb S, et al. Novel mutations expand the clinical spectrum of DYNC1H1-associated spinal muscular atrophy. *Neurology.* 2015;84(7):668- 79. DOI: 10.1212/WNL.0000000000001269
84. Storbeck M, Horsberg Eriksen B, Unger A, Hölker I, Aukrust I, Martínez-Carrera LA, et al. Phenotypic extremes of BICD2-opathies: from lethal, congenital muscular atrophy with arthrogryposis to asymptomatic with subclinical features. *Eur J Hum Genet.* 2017;25(9):1040- 8. DOI: 10.1038/ejhg.2017.98
85. Ravenscroft G, Di Donato N, Hahn G, Davis MR, Craven PD, Poke G, et al. Recurrent de novo BICD2 mutation associated with arthrogryposis multiplex congenita and bilateral perisylvian polymicrogyria. *Neuromuscul Disord.* 2016;26(11):744- 8. DOI: 10.1016/j.nmd.2016.09.009
86. de la Chapelle A, Herva R, Koivisto M, Aula P. A deletion in chromosome 22 can cause DiGeorge syndrome. *Hum Genet.* 1981;57(3):253- 6. DOI: 10.1007/bf00278938
87. Hunter JE, Berry-Kravis E, Hipp H, Todd PK. FMR1 Disorders. Dans: Adam MP, Ardinger HH, Pagon RA, Wallace SE, Bean LJ, Stephens K, et al., directeurs. *GeneReviews*®. [En ligne]. Seattle

(WA): University of Washington, Seattle; 1993-2020. Disponible:
<http://www.ncbi.nlm.nih.gov/books/NBK1384/>

88. Li X, Jiang M, Han W, Zhao N, Liu W, Sui Y, et al. A novel TNNI2 mutation causes Freeman-Sheldon syndrome in a Chinese family with an affected adult with only facial contractures. *Gene*. 2013;527(2):630-5. DOI: 10.1016/j.gene.2013.06.082
89. Eymard B. [Antibodies in myasthenia gravis]. *Rev Neurol (Paris)*. 2009;165(2):137-43. DOI: 10.1016/j.neurol.2008.11.020
90. Zisimopoulou P, Evangelakou P, Tzartos J, Lazaridis K, Zouvelou V, Mantegazza R, et al. A comprehensive analysis of the epidemiology and clinical characteristics of anti-LRP4 in myasthenia gravis. *Journal of Autoimmunity*. 2014;52:139-45. DOI: 10.1016/j.jaut.2013.12.004
91. Andersen JB, Heldal AT, Engeland A, Gilhus NE. Myasthenia gravis epidemiology in a national cohort; combining multiple disease registries. *Acta Neurol Scand, Suppl*. 2014;(198):26-31. DOI: 10.1111/ane.12233
92. Polizzi A, Huson SM, Vincent A. Teratogen update: maternal myasthenia gravis as a cause of congenital arthrogyrosis. *Teratology*. 2000;62(5):332-41. DOI: 10.1002/1096-9926(200011)62:5<332::AID-TERA7>3.0.CO;2-E
93. Hacohen Y, Jacobson LW, Byrne S, Norwood F, Lall A, Robb S, et al. Fetal acetylcholine receptor inactivation syndrome. *Neurol Neuroimmunol Neuroinflamm*. 2014;2(1). DOI: 10.1212/NXI.0000000000000057
94. Gilhus NE, Hong Y. Maternal myasthenia gravis represents a risk for the child through autoantibody transfer, immunosuppressive therapy and genetic influence. *European Journal of Neurology*. 2018;25(12):1402-9. DOI: 10.1111/ene.13788
95. Hesselmann LF, Jennekens FG, Van den Oord CJ, Veldman H, Vincent A. Development of innervation of skeletal muscle fibers in man: relation to acetylcholine receptors. *Anat Rec*. 1993;236(3):553-62. DOI: 10.1002/ar.1092360315
96. Vincent A, McConville J, Farrugia ME, Bowen J, Plested P, Tang T, et al. Antibodies in myasthenia gravis and related disorders. *Ann N Y Acad Sci*. 2003;998:324-35. DOI: 10.1196/annals.1254.036
97. Hoff JM, Daltveit AK, Gilhus NE. Myasthenia gravis in pregnancy and birth: identifying risk factors, optimising care. *Eur J Neurol*. 2007;14(1):38-43. DOI: 10.1111/j.1468-1331.2006.01538.x
98. Hoff JM, Daltveit AK, Gilhus NE. Arthrogyrosis multiplex congenita -- a rare fetal condition caused by maternal myasthenia gravis. *Acta Neurol Scand, Suppl*. 2006;183:26-7. DOI: 10.1111/j.1600-0404.2006.00610.x
99. Mikou F, Kaouti N, Ghazli M, El Kerroumi M, Sefrioui O, Morsad F, et al. [Severe neonatal myasthenia with arthrogyrosis]. *J Gynecol Obstet Biol Reprod (Paris)*. 2003;32(7):660-2.
100. Cantagrel S, Maury L, Yamamoto A-M, Maheut J, Toutain A, Castelnau P. Akinesia, arthrogyrosis, craniosynostosis: a presentation of neonatal myasthenia with fetal onset. *Am J Perinatol*. 2002;19(6):297-301. DOI: 10.1055/s-2002-34468

101. Morel E, Bach JF, Briard ML, Aubry JP. Neonatal myasthenia gravis. Anti-acetylcholine receptor antibodies in the amniotic fluid. *J Neuroimmunol.* 1984;6(5):313- 7. DOI: 10.1016/0165-5728(84)90020-1
102. Hellmund A, Berg C, Geipel A, Müller A, Gembruch U. Prenatal diagnosis of fetal akinesia deformation sequence (FADS): a study of 79 consecutive cases. *Arch Gynecol Obstet.* 2016;294(4):697- 707. DOI: 10.1007/s00404-016-4017-x
103. Dalton P, Clover L, Wallerstein R, Stewart H, Genzel-Boroviczeny O, Dean A, et al. Fetal arthrogryposis and maternal serum antibodies. *Neuromuscul Disord.* 2006;16(8):481- 91. DOI: 10.1016/j.nmd.2006.05.015
104. Eymard B, Morel E, Dulac O, Moutard-Codou ML, Jeannot E, Harpey JP, et al. [Myasthenia and pregnancy: a clinical and immunologic study of 42 cases (21 neonatal myasthenia cases)]. *Rev Neurol (Paris).* 1989;145(10):696- 701.
105. Vincent A, Waters P, Leite MI, Jacobson L, Konecny I, Cossins J, et al. Antibodies identified by cell-based assays in myasthenia gravis and associated diseases. *Ann N Y Acad Sci.* 2012;1274:92- 8. DOI: 10.1111/j.1749-6632.2012.06789.x
106. Hamel J, Ciafaloni E. An Update: Myasthenia Gravis and Pregnancy. *Neurol Clin.* 2018;36(2):355- 65. DOI: 10.1016/j.ncl.2018.01.005
107. Midelfart Hoff J, Midelfart A. Maternal myasthenia gravis: a cause for arthrogryposis multiplex congenita. *J Child Orthop.* 2015;9(6):433- 5. DOI: 10.1007/s11832-015-0690-8
108. Wilnai Y, Seaver LH, Enns GM. Atypical amyoplasia congenita in an infant with Leigh syndrome: A mitochondrial cause of severe contractures? *American Journal of Medical Genetics Part A.* 2012;158A(9):2353- 7. DOI: 10.1002/ajmg.a.35533
109. von Kleist-Retzow J-C, Cormier-Daire V, Viot G, Goldenberg A, Mardach B, Amiel J, et al. Antenatal manifestations of mitochondrial respiratory chain deficiency. *J Pediatr.* 2003;143(2):208- 12. DOI: 10.1067/S0022-3476(03)00130-6
110. Laubscher B, Janzer RC, Krähenbühl S, Hirt L, Deonna T. Ragged-red fibers and complex I deficiency in a neonate with arthrogryposis congenita. *Pediatr Neurol.* 1997;17(3):249- 51. DOI: 10.1016/s0887-8994(97)00082-9
111. Mignot C, Gelot A, Bessières B, Daffos F, Voyer M, Menez F, et al. Perinatal-lethal Gaucher disease. *Am J Med Genet A.* 2003;120A(3):338- 44. DOI: 10.1002/ajmg.a.20117
112. Quijano-Roy S, Avila-Smirnow D, Carlier RY, WB-MRI muscle study group. Whole body muscle MRI protocol: pattern recognition in early onset NM disorders. *Neuromuscul Disord.* 2012;22 Suppl 2:S68-84. DOI: 10.1016/j.nmd.2012.08.003
113. Carrera-García L, Natera-de Benito D, Dieterich K, de la Banda MGG, Felter A, Inarejos E, et al. CHRNG-related nonlethal multiple pterygium syndrome: Muscle imaging pattern and clinical, histopathological, and molecular genetic findings. *Am J Med Genet A.* 2019;179(6):915- 26. DOI: 10.1002/ajmg.a.61122

Figure S1 : Study information note destined for patients



NOTICE D'INFORMATION SUR UN PROJET DE RECHERCHE
PRRARDiag
Pediatric Retrospective Registry for patients with ARthrogryposis multiplex congenita: description of the Diagnosis process and building of recommendations
Registre rétrospectif pédiatrique de patients atteints d'Arthrogrypose multiple congénitale : description du parcours diagnostique et établissement de recommandations.

Madame, Monsieur,

Cette fiche vous informe d'un projet de recherche, planifié ou en cours, organisé par le service de Génétique, génomique et procréation du C.H.U. Grenoble Alpes. **Nous vous remercions d'avance d'en prendre connaissance.**

DESCRIPTIF DE L'ETUDE

Cette recherche consiste à retracer le parcours diagnostique des patients atteint d'Arthrogrypose Multiple Congénitale ayant consulté au Centre de Référence « Anomalies du Développement et syndromes malformatifs de l'inter-région Est » depuis sa création, à un âge pédiatrique. L'objectif est d'interroger la pertinence de chaque examen complémentaire, dans le but d'établir des recommandations de prise en charge diagnostique à l'échelle nationale.

Le recueil de données sera uniquement rétrospectif et se fera sur la lecture des dossiers médicaux papiers

BENEFICES, CONTRAINTES ET RISQUES

Ce projet utilisera les données du dossier médical de patients pris en charge dans ce service, pour faire progresser les connaissances et les pratiques médicales. Seules des données normalement acquises dans le cadre d'une prise en charge seront utilisées.

La prise en charge d'un patient n'est aucunement modifiée par l'utilisation de ses données médicales ou par son opposition à cette recherche.

CONFIDENTIALITE DES DONNEES

Dans le cadre de cette recherche, un traitement de données personnelles va être mis en œuvre.

Les données que nous prévoyons de collecter sont les suivantes :

- Données épidémiologiques : année de naissance, sexe, place dans la fratrie, lien de parentés entre les parents, âge de la première consultation dans le centre, site de prise en charge habituel
- Cause de l'Arthrogrypose Multiple Congénitale retenue : diagnostic clinique, diagnostic moléculaire, forme familiale ou sporadique
- Investigations génétiques et paracliniques : examens biologiques, moléculaires, histologiques, électrophysiologiques et d'imagerie
- Données cliniques anténatales : anomalies détectées à l'échographie et terme, événements particuliers lors de la grossesse (pathologie maternelle...)
- Données cliniques néonatales : terme de naissance, biométries de naissance, adaptation à la vie extra-utérine, position articulaire spontanée
- Données cliniques au cours des différents examens médicaux de l'enfant : bilan articulaire, neurologique, développement psychomoteur, signes cliniques spécifiques
- Données de prise en charge (orthopédique et chirurgicale), d'autonomie et d'évolution

VOS DROITS

Vous disposez de droits d'accès et de rectification, d'opposition et d'un droit de réclamation à une autorité de contrôle (CNIL).



QUE DEVEZ-VOUS FAIRE ?

- Si vous ne vous opposez pas à l'utilisation des données de votre dossier médical, vous n'avez rien à faire.
- Si vous souhaitez vous opposer à l'utilisation de vos données pour ce projet, vous pouvez :
 - En parler directement au personnel du service que vous rencontrez aujourd'hui.
 - Contacter le responsable de l'étude ou le délégué à la protection des données (voir ci-dessous).

VOS CONTACTS

Pour exercer vos droits, ou pour toute question à ce sujet :

- Vous pouvez contacter le délégué à la protection des données du CHU Grenoble Alpes par mail (protection-donnees@chu-grenoble.fr) ou par téléphone au 04.76.76.82.02
- Une demande peut aussi être envoyée par courrier à CHU Grenoble Alpes, Délégué à la Protection des Données, CS 10217, 38043 GRENOBLE Cedex 09.
- Vous pouvez demander un formulaire d'opposition à l'accueil du service de Génétique, génomique et procréation.

Si vous avez des questions sur l'étude, vous pouvez contacter le responsable ci-dessous :

Investigateur responsable de l'étude : Dr DIETERICH Klaus	Organisme responsable du traitement des données : CHU Grenoble Alpes
Coordonnées : CHU Grenoble Alpes Service de génétique, génomique et procréation Hôpital Couple Enfant – Rez-de-chaussée CS10217 CHU, 38043 GRENOBLE Cedex 09 Tel : 04 76 76 72 85	Coordonnées : CHU Grenoble Alpes - DRCI Pavillon Dauphiné – Rez-de-chaussée CS 10217 38043 GRENOBLE Cedex 9 Tel : 04 76 76 59 57

Table S1. Features that led to the diagnosis of atypical Amyoplasia			
Ind.	UL/LL/4L	Atypical characteristic	Genetic Analysis
5	4L	Global loss of muscle function with hypomobility and hypotonia	NMD-NGS : negative
16	4L	Classic impairment of LL but only distal impairment of UL	none
38	LL	Atypical LL only presentation	NMD-NGS: ongoing
40	4L	Global loss of muscle function with hypomobility and hypotonia	none
52	LL	Cramps and pains	NMD-NGS: ongoing
70	UL	Cramps and pains	NMD-NGS: ongoing
73	LL	Abnormally weak response to physiotherapy	NMD-NGS: negative WES : ongoing
77	LL	Atypical LL only presentation	NMD-NGS: ongoing
82	4L	Atypical muscle masses and/or mild involvement of trunk	NMD-NGS: ongoing
93	LL	Complete loss of deep tendon reflexes despite only mild or moderate muscle atrophy	NMD-NGS: ongoing
98	UL	Atypical elbow pattern, asymmetry	NMD-NGS: negative
114	LL	Atypical LL only presentation	none
123	4L	Reduction abnormality of limbs	none

Legends : 4L, four limbs; Ind., individual; LL, lower limbs; NMD NGS, Neuromuscular Disorders-related genes next generation sequencing; UL, upper limbs; WES, Whole Exome Sequencing.

Table S2. List of the 121 NMD-related genes sequenced in CHU Grenoble-Alpes laboratory (NMD-NGS)

Gene	Disease	Inh.	Gene	Disease	Inh.	Gene	Disease	Inh.
ACTA1	CM	AD/AR	DNM2	FADS/CM/other myo	AR/AD	MYO18B	CM	AD
ADAMST2	EDS	AR	DOK7	FADS/CMS	AR	MYOD1	FADS	AR
ADCY6	FADS	AR	DPAGT1	CMS	AR	MYOT	Other Myo	AD
ADGRG6	FADS	AR	DYNC1H1	SMALED	AD	NALCN	AMC+CNS	AD
AGRN	CMS	AR	ECEL1	DA	AR	NEB	CM/other myo	AR
ALG2	CMS	AR	EMD	Other dys	XL	ORAI1	Other myo	AD
ALG14	CMS	AR	ERBB3	FADS	AR	PIEZO2	DA	AD
ANO5	Other myo	AR	FBN2	DA	AD	PIP5K1C	FADS	AR
ATP2A1	Myotonia	AR	FBLN5	Other conn	AD	PLEC	CMS	AR
BAG3	Other myo, DCM	AD	FHL1	Other myo	XL	PLOD1	EDS	AR
BICD2	SMALED	AD	FKBP14	EDS	AR	PNPLA2	Other myo	AR
BIN1	CM	AD/AR	FLNC	Other myo	AD	PRPL	CMS	AR
CACNA1S	CM/PP	AR	GFPT1	CMS	AR	PTPLA	CM	AR
CASQ1	CM	AR	GLE1	FADS	AR	RAPSN	FADS/CMS	AR
CAV3	LGMD/ Other myo	AD	GNE	Other myo	AR	RYR1	CM/other myo/MH	AR
CCDC78	CM	AR	HSPG2	Other conn	AR	SCN4A	FADS/CMS/PP/myotonia	AR/AD
CFL2	CM	AR	ITGA7	Other myo	AR	SEPN1	CM/other myo/dys	AR
CHAT	CMS	AR	KBTBD13	CM	AD	SLC25A1	Other mya	AR
CHRNA1	MPS/CMS	AR/AD	KCNA1	Myotonia	AD	SLC5A7	CMS/neuropathy	AD/AR
CHRN1	FADS/CMS	AR /AD	KCNJ2	PP	AD	SNAP25	CMS	?
CHRND	MPS/CMS	AR /AD	KCNQ2	Other	AD	SOSTM1	Other myo	AD
CHRNE	CMS	AD/AR	KLHL40	CM	AR	SPEG	CM	AR
CHRNA1	MPS/CMS	AR	KLHL41	CM	AR	STAC3	CM	AR
CLCN1	Myotonia	AD/AR	LAMA2	Other dys	AR	STIM1	other myo	AD
CNTN1	CM	AR	LAMB2	CMS	AR	SYT2	CMS, other mya	AD
CNTNAP1	FADS	AR	LDB3	Other myo	AD	TCAP	LGMD	AR
COL1A1	EDS	AD	LMOD3	CM	AR	TIA1	Other myo	AD
COL1A2	EDS	AD/AR	LMNA	LGMD/other myo/dys	AD/AR	TNNI2	DA	AD
COL3A1	EDS	AD/AR	LRP4	CMS	AR	TNNT1	CM	AR
COL5A1	EDS	AD	MAGEL2	Foetal AMC	AD	TNNT3	DA	AD
COL5A3	EDS	AD?	MATR3	Other myo	AD	TNXB	EDS	AR
COL6A1	Other myo/dys	AD/AR	MEGF10	CM	AR	TPM2	DA/CM/CM	AD
COL6A2	Other myo/dys	AD/AR	MTM1	CM	XL	TPM3	CM	AD
COL6A3	Other myo/dys	AD/AR	MUSK	FADS/CMS	AR	TRIM32	CM	AR
COL6A6	Other myo	?	MYBPC1	FADS	AR	TRPV4	SMAD	AD
COL12A1	Other myo/dys	AD/AR	MYBPC3	CM	AR	TTN	CM/other myo	AD/AR
COL14A1	CMS	AR	MYH2	DA/CM	AD/AR	VCP	Other myo	AD
COLQ	CMS	AR	MYH3	MPS/DA	AD	ZBTB42	FADS	AR
CRYAB	Other myo	AR/AD	MYH7	CM/ other Myo	AD	ZC4H2	AMC+CNS	XL
DES	Other myo	AR	MYH8	DA	AD			
DNAJB6	LGMD	AD	MYO9A	CMS	AR			

List of sequenced genes in 2017, other genes might have been added since then.

Legends : AD, autosomal dominant; AMC, Arthrogyriposis Multiplex Congenita; AR, autosomal recessive; CM, congenital myopathies; CMS, congenital Myasthenic Syndrome; CNS, Central Nervous System; Conn, connective tissue disorder; DA, Distal Arthrogyriposis; DCM, dilated cardiomyopathy; Dys, dystrophy; EDS, Ehlers Danlos Syndrome; FADS, Foetal Akinesia Deformation Sequence; LGMD, Limb Girdle Muscular Dystrophy; MH, Malignant Hyperthermia; MPS, Multiple Pterygia Syndrome; Mya, myasthenia; Myo, myopathy; NMD, neuromuscular diseases; PP, periodic palsy; SMAD, Spinal Muscular Atrophy, distal; SMALED, Spinal Muscular Atrophy, Lower-Etremity predominant. Bold character : AMC-related genes list, including foetal or lethal forms. Red character : List of the 11 AMC-related genes previously sequenced in the laboratory (AMC-NGS).

Table S3. Indications that had motivated prenatal karyotypes

Ind.	Group	Sub Group	Genetic diagnosis	Indication	Details
54	1	T	/	Isolated BEV	/
50	1	T	/		
38	1	aT	uk		
22	1	T	/	BEV + other articular anomalies	UL and LL
85	1	T	/	BEV + other articular anomalies	UL and LL
118	3	O	uk		
89	3	O	uk		
106	1	T	/	BEV + other articular and extra articular anomalies	UL and LL, decreased AFM, umbilical cyst
64	1	T	/	BEV + other articular and extra articular	UL and LL, decreased AFQ, growth delay
23	2	PN	PIEZO2		UL and LL, decreased AFM, abnormal cardiac hyperechogenicity
74	2	M	MYH3		UL and LL, increased AFQ, retrognathism
60	3	C	uk		UL and LL, increased AFQ, decreased AFM, abnormal extremities
73	1	aT	uk		BEV + other extra articular anomalies
52	1	aT	uk	Mesenteric cyst	
30	2	PN	PIEZO2	Growth delay	
76	2	PN	PIEZO2	Abnormal abdominal image	
69	1	T	/	History of pregnancy with Down syndrome	
14	1	T	/	Increased nuchal translucency	Short long bones, decreased AFQ
58	2	M	MYH3		Growth delay, spine anomalies
11	3	C	NSD1	Increased first semester dosage	
61	3	O	LMX1B		and unilateral EV
66	1	T	/	Other articular anomalies	Bilateral club hand
98	1	aT	uk		Clenched fists, UL muscle amyotrophy
123	1	aT	uk	Other articular anomalies + other signs	Unilateral EV and decreased AFM
116	3	C	ZC4H2	Other articular anomalies + other signs	Clenched fists, growth delay, increased AFQ
45	3	C	ZC4H2	Other articular anomalies + other signs	Excess of AFQ
65	1	T	/	Other	Laparoschisis
55	2	PN	PIEZO2		Decreased AFQ and AFM
121	2	M	MYH3	Other	Increased AFQ, increased OFC, frontal excess of skin
58	2	M	TPM2	Other	Decreased AFQ and AFM, growth delay
6	3	C	uk		Increased AFQ, short long bones, growth delay

Legends : AFM, active foetal movements; AFQ, amniotic fluid quantity; aT, atypical; C, BEV, bilateral Equinovarus feet; CNS involvement; EV, equinovarus foot; Ind., individual; LL, lower limbs, M, muscle; O, other; OFC, occipitofrontal circumference; PN, peripheral nerve; T, typical; uk, unknown; UL, upper limbs. Lines coloured in grey indicate patients for which a prenatal array-CGH was also performed.

Table S4. Detailed Karyotype and array-CGH results (postnatal)

Ind.	Group	Sub group	Genetic diagnosis	Investigation	Results
Positive results					
45	3	C	uk	Array-CGH	329kb Xq11.2 deletion involving ZC4H2 (chrX:64,196,201-64,525,424)
124	3	C	uk	Karyotype	4p trisomy resulting from unbalanced de novo translocation der(4;22)(p10;q10)
				Array-CGH	Characterisation of translocation : 4p trisomy
47	3	C	uk	Karyotype	18p tetrasomy resulting from an isochromosome 18p
Incidental findings/class 1-2-3 CNVs*					
49	1	T	/	Array-CGH	2 inherited deletions
63	2	NMJ	<i>CHRNA2</i>	Array-CGH	10p13 duplication inherited from the mother, polymorphism
119	2	O	uk	Karyotype	47,XXY
12	2	O	uk	Array-CGH	16q23.1 <i>de novo</i> duplication, VUS
116	3	C	<i>ZC4H2</i>	Array-CGH	2p25.2 <i>de novo</i> deletion, VUS
19	3	C	uk	Array-CGH	16q21 duplication inherited from the father, polymorphism
<i>Legends : C, CNS involvement; CGH, Comparative Genomic Hybridization; CNVs, Copy Number Variants; Ind., individual; NMJ, neuromuscular junction; O, other; T, typical; uk, unknown; VUS, Variant of Unknown Significance.</i> <i>* According to ACMG classification, i.e. benign, likely benign or VUS</i>					

Table S5. Other cytogenetic analyses performed in our cohort

Ind.	Group	Sub group	Genetic diagnosis	Chromosomal investigations
69	1	T	/	MLPA for subtelomeric loci study
76	2	PN	<i>PIEZO2</i>	MLPA targeting main microdeletions syndromes
11	3	C	<i>NSD1</i>	MLPA for subtelomeric loci study*
75	3	C	<i>ZC4H2</i>	Fragile X
110	3	C	<i>KAT6B</i>	MLPA for subtelomeric loci study, 22q11.2 deletion search
17	3	C	uk	22q11.2 deletion search, 12p tetrasomy**
60	3	C	uk	MLPA targeting main microdeletions syndromes
6	3	C	uk	Fragile-X
4	3	C	uk	22q11.2 microdeletion search, 4p duplication
51	3	O	uk	Wolff-Hirschhorn syndrome
<i>Legends : C, CNS involvement; Ind., individual; MLPA, multiplex Ligation-dependant Probe Amplification; O, other; PN, peripheral nerve; st, subtelomeric; T, typical; uk, unknown; μdel, microdeletions. * polymorphic SHANK3 duplication. ** performed on fibroblasts</i>				

Table S6. Other targeted analyses performed in our cohort					
Ind.	Group	Sub group	Genetic diagnosis	Investigations	Result
50	1	T	/	<i>HSPB1, HSPB3, HSPB8</i>	-
55	2	PN	<i>PIEZO2</i>	Congenital myasthenia genes	-
63	2	NMJ	<i>CHRNA3</i>	<i>ASXL1</i> Sg	-
11	3	C	<i>NSD1</i>	<i>FBN1</i>	-
				<i>TGFBR2</i>	-
				<i>NSD1</i> MLPA then Sg	+ (Sg)
110	3	C	<i>KAT6B</i>	<i>KAT6B</i> Sg	+
34	3	C	uk	Mt-DNA mutation screening	-
				<i>POLG1</i> Sg	-
17	3	C	uk	ARC syndrome genes	-
7	3	C	uk	<i>GLRA1</i> Sg	-
60	3	C	uk	NM genes*	P
				<i>SLC12A6</i> Sg	-
4	3	C	uk	Mt-DNA mutation screening	⁻¹
				<i>POLG1</i> Sg	-
79	3	C	uk	<i>CRLF1</i> Sg	-
61	3	O	<i>LMX1B</i>	<i>LMX1B</i> Sg	+
109	3	O	<i>FLNB</i>	<i>FLNB</i> Sg	+
35	3	O	<i>FGD1</i>	<i>FGD1</i> Sg	+
2	3	O	uk	<i>DTDST</i> Sg	-
32	3	O	uk	Brück syndrome genes	-

Legends : + positive ; -, negative; ARC, arthrogyrosis Renal dysfunction and Cholestasis; C, CNS involvement; Ind., individual; MLPA, multiplex ligation-dependant probe amplification; mtDNA, mitochondrial DNA; NM, Neuromuscular; NMJ, neuromuscular junction; O, other; P, polymorphism; PN, peripheral nerve; Sg, Sanger sequencing; T, typical; uk, unknown; VUS, Variant of Unknown Significance.

* other analysis than NMD-NGS performed in our laboratory

¹ MELAS mutation with 7% of heteroplasmy, absent in several maternal tissues

Table S7. Abnormal creatine kinase dosage results				
Ind.	Group	Sub group	Genetic diagnosis	CK dosage value
33	1	T	/	Subnormal (ns)
116	3	C	<i>ZC4H2</i>	Light elevation* (463UI/L), post-surgery
11	3	C	<i>NSD1</i>	Mild elevation* (1422UI/L) in the neonatal period, context of hypoglycaemia
60	3	C	uk	Subnormal (263UI/L)

Legends : CK, creatine Kinase; C, CNS involvement; Ind., individual; ns, not specified; T, typical; uk, unknown.

* not mentioned in medical reports, no control dosage available


Table S8. Details on metabolic investigations performed in our patients		
Metabolic investigation	Number of patients investigated	Results
Amino acids analysis in blood	7	Negative
Amino acids analysis in urine	5	Negative
Organic acids test in urine	8	Negative
Ammonia in blood	6	Hyperammonia (140µmol/L) without hyperlactatemia in patient 17 (group 3C)
Lactate and pyruvate in blood	7	Negative
Acyl carnitine profile in blood	3	Negative
Very long chain fatty acids	2	Negative
Cerebrospinal Fluid investigations :	2	Negative
Amino acid analysis	1	
Neurotransmitters	1	
Not specified	1	
Not specified	3	Negative
Other : - Gaucher disease - Urinary glycosaminoglycans and oligosaccharids, acid hydrolases, sialic acid - Adenylosuccinase deficiency - CDG syndrome - Vacuolated lymphocytes, acid maltase - Urinary pyridinoline and deoxypyridinoline - G6PD deficiency - Copper dosage	1 for each	Negative

Legends : CDG, congenital disorders of glycosylation; G6PD, glucose-6-phosphate deshydrogenase.

Table S9. Details on anomalies observed on electroencephalogram				
Ind.	Group	Sub group	Indications	Conclusions
47	3	C*	Seizures (myoclonic, absence)	Inter ictal anomalies on the right hemisphere
34	3	C	Abnormal movements (myoclonia, tremor)	Transitory anomalies on the left anterior region, conclusion of an epileptic origin for abnormal myoclonic movements
102	3	C	Seizures (West syndrome)	Slow polyspike wave complexes
7	3	C	Hypertonia crisis on stimulation (hyperplexia)	Registering of one clinical crisis without EEG anomalies, normal inter ictal EEG
60	3	C	Sucking and deglutition issues, central apnea	Acute wave pattern predominant on the right hemisphere
4	3	C	Seizures, epileptic encephalopathy	No physiologic pattern, multifocal spikes mostly on central left region
89	3	C	Hypotonia	Few bilateral temporal spikes

*Legends : C, CNS involvement; EEG, Electroencephalogram; Ind., individual. * 12p tetrasomy*

Table S10. Metabolic disorders associated with AMC		
Type of disorder	Genes	Reference PMID
Intoxication disorders		
<i>Organic aciduria :</i>		
3-methylmalonique aciduria	TMEM70	21147908
Lethal restrictive dermopathy		19102058
<i>Aminoacidopathies :</i>		
GLYT1 encephalopathy	SLC6A9	27773429
Serine biosynthesis defects	PSAT	26960553
<i>Urea cycle deficiencies (none)</i>		
Energetic disorders		
<i>Fatty acid beta oxidation disorders (none)</i>		
<i>Citric acid cycle's related disorders :</i>		
Pyruvate deshydrogenase deficiency	PDHA1	28495245
<i>Mitochondrial disorders :</i>		
Leigh syndrome	GMF2	26016410
	SURF1	22887355
	IBA57	23462291
Other genes with mitochondrial function	ATAD1	29390050
	NALCN	27473021
	ATPAF2, EFG1, MRPS16	21596636
	EIF2S3	25790323
MELAS	Mitochondrial	16353243
Complex I deficiency	Uc	17162196, 16143021, 12420122, 10669207, 9390702
Complex III deficiency	Uc	12970634
Complex V deficiency	Uc	14757859, 12970634
Multiple complex deficiencies	Uc	10401692
Complexe molecules disorders		
<i>Peroxisomal disorders</i>		
Rhizomelic chondrodysplasia punctate	PEX7, GNPAT, AGPS	987909, 20301447
D-bi functional protein deficiency	HSD17B4	11743515
Zellweger (CDP)	PEX1, PEX6, PEX12*	24704792, 31369690, 20301621
<i>Lysosomal disorders</i>		
Gaucher	GBA1	12838552, 26327947, 24704792
<i>Mucopolysaccharidoses (none)</i>		
<i>Glycogen storage disease</i>		
Type IV	GBE1	27546458, 26752647, 23218673
Type VII	PFKM	26108272
Type IXb	PHKB	8051930
<i>Purine/pyrimidine biosynthesis defects</i>		
Adenylsuccinate lyase deficiency	ADSL	24704792, 17188615
<i>Glycosylation defects</i>		
CDG type Ia, b, d	PMM2, MPI, ALG3	24704792, 31369690
CDG Type Ij	DPAGT1	26033833
CDG type In	RFT1	19267216
ALG14-CDG	ALG14	28733338
<i>Other</i>		
ARC Syndrome	VPSS33B, VIPAS39	15052268, 20190753
Hyaline systemic fibromatosis	ANTXR2	20140429
<i>Legends : AMC, Arthrogryposis Multiplex Congenita; ARC, arthrogryposis, renal dysfunction and cholestasis; CDG, Congenital Disorders of Glycosylation; MT, mitochondrial genes; Uc, absence of molecular characterization. * among other PEX family genes</i>		



SERMENT D'HIPPOCRATE

En présence des Maîtres de cette Faculté, de mes chers condisciples et devant l'effigie d'HIPPOCRATE,

Je promets et je jure d'être fidèle aux lois de l'honneur et de la probité dans l'exercice de la Médecine.

Je donnerai mes soins gratuitement à l'indigent et n'exigerai jamais un salaire au dessus de mon travail. Je ne participerai à aucun partage clandestin d'honoraires.

Admis dans l'intimité des maisons, mes yeux n'y verront pas ce qui s'y passe ; ma langue taira les secrets qui me seront confiés et mon état ne servira pas à corrompre les mœurs, ni à favoriser le crime.

Je ne permettrai pas que des considérations de religion, de nation, de race, de parti ou de classe sociale viennent s'interposer entre mon devoir et mon patient.

Je garderai le respect absolu de la vie humaine.

Même sous la menace, je n'admettrai pas de faire usage de mes connaissances médicales contre les lois de l'humanité.

Respectueux et reconnaissant envers mes Maîtres, je rendrai à leurs enfants l'instruction que j'ai reçue de leurs pères.

Que les hommes m'accordent leur estime si je suis fidèle à mes promesses.

Que je sois couvert d'opprobre et méprisé de mes confrères si j'y manque.