



**HAL**  
open science

# Diagnostic sérologique de *Toxoplasma gondii*: analyse des IgG faux positifs et implications

Loïc Simon

► **To cite this version:**

Loïc Simon. Diagnostic sérologique de *Toxoplasma gondii*: analyse des IgG faux positifs et implications. Médecine humaine et pathologie. 2020. dumas-02969431

**HAL Id: dumas-02969431**

**<https://dumas.ccsd.cnrs.fr/dumas-02969431>**

Submitted on 16 Oct 2020

**HAL** is a multi-disciplinary open access archive for the deposit and dissemination of scientific research documents, whether they are published or not. The documents may come from teaching and research institutions in France or abroad, or from public or private research centers.

L'archive ouverte pluridisciplinaire **HAL**, est destinée au dépôt et à la diffusion de documents scientifiques de niveau recherche, publiés ou non, émanant des établissements d'enseignement et de recherche français ou étrangers, des laboratoires publics ou privés.

Université Côte d'Azur  
Faculté de Médecine de Nice

THÈSE D'EXERCICE DE MÉDECINE

**Serological diagnosis of *Toxoplasma gondii*:  
analysis of false-positive IgG results and implications**



Présentée et soutenue publiquement le 11 mars 2020 à la Faculté de Médecine de Nice

Par **Loïc SIMON**, né le 15 septembre 1988 à Tours

En vue d'obtenir le Diplôme d'État de Docteur en Médecine

*Spécialité : Biologie Médicale*



Devant le Jury composé de :

Monsieur le Professeur Pierre MARTY

**Président du Jury**

Monsieur le Professeur Jérôme DELOTTE

**Assesseur**

Madame le Professeur Valérie GIORDANENGO

**Assesseur**

Madame le Docteur Christelle POMARES

**Directrice de Thèse**

## SERMENT D'HIPPOCRATE

---

Au moment d'être admis à exercer la médecine, je promets et je jure d'être fidèle aux lois de l'honneur et de la probité.

Mon premier souci sera de rétablir, de préserver ou de promouvoir la santé dans tous ses éléments, physiques et mentaux, individuels et sociaux.

Je respecterai toutes les personnes, leur autonomie et leur volonté, sans aucune discrimination selon leur état ou leurs convictions. J'interviendrai pour les protéger si elles sont affaiblies, vulnérables ou menacées dans leur intégrité ou leur dignité. Même sous la contrainte, je ne ferai pas usage de mes connaissances contre les lois de l'humanité.

J'informerai les patients des décisions envisagées, de leurs raisons et de leurs conséquences. Je ne tromperai jamais leur confiance et n'exploiterai pas le pouvoir hérité des circonstances pour forcer les consciences.

Je donnerai mes soins à l'indigent et à quiconque me les demandera. Je ne me laisserai pas influencer par la soif du gain ou la recherche de la gloire.

Admis dans l'intimité des personnes, je tairai les secrets qui me seront confiés. Reçu à l'intérieur des maisons, je respecterai les secrets des foyers et ma conduite ne servira pas à corrompre les mœurs.

Je ferai tout pour soulager les souffrances. Je ne prolongerai pas abusivement les agonies. Je ne provoquerai jamais la mort délibérément.

Je préserverai l'indépendance nécessaire à l'accomplissement de ma mission. Je n'entreprendrai rien qui dépasse mes compétences. Je les entretiendrai et les perfectionnerai pour assurer au mieux les services qui me seront demandés.

J'apporterai mon aide à mes confrères ainsi qu'à leurs familles dans l'adversité. Que les hommes et mes confrères m'accordent leur estime si je suis fidèle à mes promesses ; que je sois déshonoré et méprisé si j'y manque.

**Liste des enseignants au 1er septembre 2019 à la Faculté de Médecine de Nice**

**Doyen**

**Pr. BAQUÉ Patrick**

**Vice-doyens**

**Pédagogie  
Recherche  
Etudiants**

**Pr. ALUNNI Véronique  
Pr. DELLAMONICA Jean  
M. JOUAN Robin**

**Chargé de mission projet Campus**

**Pr. PAQUIS Philippe**

Conservateur de la bibliothèque

Mme AMSELLE Danièle

Directrice administrative des services

Mme CALLEA Isabelle

Doyens Honoraires

M. RAMPAL Patrick  
M. BENCHIMOL Daniel

Liste des enseignants au 1er septembre 2019 à la Faculté de Médecine de Nice

PROFESSEURS CLASSE EXCEPTIONNELLE

M.	BAQUÉ Patrick	Anatomie - Chirurgie Générale (42.01)
M.	BERNARDIN Gilles	Réanimation Médicale (48.02)
Mme	BLANC-PEDEUTOUR Florence	Cancérologie – Génétique (47.02)
M.	BOILEAU Pascal	Chirurgie Orthopédique et Traumatologique (50.02)
M.	DARCOURT Jacques	Biophysique et Médecine Nucléaire (43.01)
M.	DRICI Milou-Daniel	Pharmacologie Clinique (48.03)
M.	ESNAULT Vincent	Néphrologie (52.03)
M.	FUZIBET Jean-Gabriel	Médecine Interne (53.01)
M.	GILSON Éric	Biologie Cellulaire (44.03)
M.	GUGENHEIM Jean	Chirurgie Digestive (52.02)
M.	HASSEN KHODJA Reda	Chirurgie Vasculaire (51.04)
M.	HÉBUTERNE Xavier	Nutrition (44.04)
M.	HOFMAN Paul	Anatomie et Cytologie Pathologiques (42.03)
Mme	ICHAÏ Carole	Anesthésiologie et Réanimation Chirurgicale (48.01)
M.	LACOUR Jean-Philippe	Dermato-Vénérologie (50.03)
M.	LEFTHERIOTIS Georges	Chirurgie vasculaire ; médecine vasculaire (51.04)
M.	MARQUETTE Charles-Hugo	Pneumologie (51.01)
M.	MARTY Pierre	Parasitologie et Mycologie (45.02)
M.	MICHIELS Jean-François	Anatomie et Cytologie Pathologiques (42.03)
M.	MOUROUX Jérôme	Chirurgie Thoracique et Cardiovasculaire (51.03)
Mme	PAQUIS Véronique	Génétique (47.04)
M.	PAQUIS Philippe	Neurochirurgie (49.02)
M.	PRADIER Christian	Épidémiologie, Économie de la Santé et Prévention (46.01)
M.	QUATREHOMME Gérald	Médecine Légale et Droit de la Santé (46.03)
M.	RAUCOULES-AIMÉ Marc	Anesthésie et Réanimation Chirurgicale (48.01)
M.	ROBERT Philippe	Psychiatrie d'Adultes (49.03)
M.	SCHNEIDER Stéphane	Nutrition (44.04)
M.	THYSS Antoine	Cancérologie, Radiothérapie (47.02)
M.	TRAN Albert	Hépto Gastro-entérologie (52.01)

Liste des enseignants au 1er septembre 2019 à la Faculté de Médecine de Nice

PROFESSEURS PREMIERE CLASSE

Mme	ASKENAZY-GITTARD Florence	Pédopsychiatrie (49.04)
M.	BARRANGER Emmanuel	Gynécologie Obstétrique (54.03)
M.	BÉRARD Étienne	Pédiatrie (54.01)
M.	BONGAIN André	Gynécologie-Obstétrique (54.03)
Mme	BREUIL Véronique	Rhumatologie (50.01)
M.	CASTILLO Laurent	O.R.L. (55.01)
M.	CHEVALLIER Patrick	Radiologie et Imagerie Médicale (43.02)
M.	DE PERETTI Fernand	Anatomie-Chirurgie Orthopédique (42.01)
M.	FERRARI Émile	Cardiologie (51.02)
M.	FERRERO Jean-Marc	Cancérologie ; Radiothérapie (47.02)
M.	FONTAINE Denys	Neurochirurgie (49.02)
M.	GIBELIN Pierre	Cardiologie (51.02)
M.	HANNOUN-LEVI Jean-Michel	Cancérologie ; Radiothérapie (47.02)
M.	LEVRAUT Jacques	Médecine d'urgence (48.05)
M.	LONJON Michel	Neurochirurgie (49.02)
M.	MOUNIER Nicolas	Cancérologie, Radiothérapie (47.02)
M.	PADOVANI Bernard	Radiologie et Imagerie Médicale (43.02)
M.	PASSERON Thierry	Dermato-Vénérologie (50.03)
M.	PICHE Thierry	Gastro-entérologie (52.01)
Mme	RAYNAUD Dominique	Hématologie (47.01)
M.	ROSENTHAL Éric	Médecine Interne (53.01)
M.	STACCINI Pascal	Biostatistiques et Informatique Médicale (46.04)
M.	THOMAS Pierre	Neurologie (49.01)
M.	TROJANI Christophe	Chirurgie Orthopédique et Traumatologique (50.02)

Liste des enseignants au 1er septembre 2019 à la Faculté de Médecine de Nice

PROFESSEURS DEUXIEME CLASSE

Mme	ALUNNI Véronique	Médecine Légale et Droit de la Santé (46.03)
M.	ANTY Rodolphe	Gastro-entérologie (52.01)
M.	BAHADORAN Philippe	Cytologie et Histologie (42.02)
Mme	BAILLIF Stéphanie	Ophtalmologie (55.02)
Mme	BANNWARTH Sylvie	Génétique (47.04)
M.	BENIZRI Emmanuel	Chirurgie Générale (53.02)
M.	BENOIT Michel	Psychiatrie (49.03)
M.	BERTHET Jean-Philippe	Chirurgie Thoracique (51.03)
M.	BOZEC Alexandre	ORL- Cancérologie (47.02)
M.	BREAUD Jean	Chirurgie Infantile (54.02)
Mme	BUREL-VANDENBOS Fanny	Anatomie et Cytologie pathologiques (42.03)
M.	CHEVALIER Nicolas	Endocrinologie, Diabète et Maladies Métaboliques (54.04)
Mme	CHINETTI Giulia	Biochimie-Biologie Moléculaire (44.01)
M.	CLUZEAU Thomas	Hématologie (47.01)
M.	DELLAMONICA Jean	Réanimation médicale (48.02)
M.	DELOTTE Jérôme	Gynécologie-obstétrique (54.03)
M.	FAVRE Guillaume	Néphrologie (44.02)
M.	FOURNIER Jean-Paul	Thérapeutique (48.04)
Mme	GIORDANENGO Valérie	Bactériologie-Virologie (45.01)
Mme	GIOVANNINI-CHAMI Lisa	Pédiatrie (54.01)
M.	GUÉRIN Olivier	Méd. In ; Gériatrie (53.01)
M.	IANNELLI Antonio	Chirurgie Digestive (52.02)
M.	ILIE Marius	Anatomie et Cytologie pathologiques (42.03)
M.	JEAN BAPTISTE Elixène	Chirurgie vasculaire (51.04)
M.	ROHRLICH Pierre	Pédiatrie (54.01)
M.	ROUX Christian	Rhumatologie (50.01)
M.	RUIMY Raymond	Bactériologie-virologie (45.01)
Mme	SACCONI Sabrina	Neurologie (49.01)
M.	SADOUL Jean-Louis	Endocrinologie, Diabète et Maladies Métaboliques (54.04)
M.	VANBIERVLIET Geoffroy	Gastro-entérologie (52.01)

**Liste des enseignants au 1er septembre 2019 à la Faculté de Médecine de Nice**

**MAITRES DE CONFÉRENCES DES UNIVERSITÉS - PRATICIENS HOSPITALIERS**

M.	AMBROSETTI Damien	Cytologie et Histologie (42.02)
Mme	BERNARD-POMIER Ghislaine	Immunologie (47.03)
M.	BRONSARD Nicolas	Anatomie Chirurgie Orthopédique et Traumatologique (42.01)
M.	CAMUZARD Olivier	Chirurgie Plastique (50.04)
Mme	CONTENTI-LIPRANDI Julie	Médecine d'urgence (48.04)
M.	DOGLIO Alain	Bactériologie-Virologie (45.01)
M.	DOYEN Jérôme	Radiothérapie (47.02)
M.	FOSSE Thierry	Bactériologie-Virologie-Hygiène (45.01)
M.	GARRAFFO Rodolphe	Pharmacologie Fondamentale (48.03)
Mme	HINAULT Charlotte	Biochimie et biologie moléculaire (44.01)
M.	HUMBERT Olivier	Biophysique et Médecine Nucléaire (43.01)
Mme	LAMY Brigitte	Bactériologie-Virologie (45.01)
Mme	LONG-MIRA Elodie	Cytologie et Histologie (42.02)
Mme	MAGNIÉ Marie-Noëlle	Physiologie (44.02)
M.	MASSALOU Damien	Chirurgie Viscérale (52.02)
Mme	MOCERI Pamela	Cardiologie (51.02)
M.	MONTAUDIE Henri	Dermatologie (50.03)
Mme	MUSSO-LASSALLE Sandra	Anatomie et Cytologie pathologiques (42.03)
M.	NAÏMI Mourad	Biochimie et Biologie moléculaire (44.01)
Mme	POMARES Christelle	Parasitologie et mycologie (45.02)
M.	SAVOLDELLI Charles	Chirurgie maxillo-faciale et stomatologie (55.03)
Mme	SEITZ-POLSKI Barbara	Immunologie (47.03)
M.	SQUARA Fabien	Cardiologie (51.02)
M.	TESTA Jean	Épidémiologie Économie de la Santé et Prévention (46.01)
Mme	THUMMLER Susanne	Pédopsychiatrie (49.04)
M.	TOULON Pierre	Hématologie et Transfusion (47.01)



## Liste des enseignants au 1er septembre 2019 à la Faculté de Médecine de Nice

### MAITRE DE CONFÉRENCES DES UNIVERSITÉS

M. DARMON David Médecine Générale (53.03)  
Mme GROS Auriane Orthophonie (69)

### PROFESSEURS AGRÉGÉS

Mme LANDI Rebecca Anglais

### PRATICIEN HOSPITALIER UNIVERSITAIRE

M. DURAND Matthieu Urologie (52.04)  
M. SICARD Antoine Néphrologie (52.03)

### PROFESSEURS ASSOCIÉS

M. GARDON Gilles Médecine Générale (53.03)  
Mme MONNIER Brigitte Médecine Générale (53.03)

### MAITRES DE CONFÉRENCES ASSOCIÉS

Mme CASTA Céline Médecine Générale (53.03)  
M. GASPERINI Fabrice Médecine Générale (53.03)  
M. HOGU Nicolas Médecine Générale (53.03)

**Liste des enseignants au 1er septembre 2019 à la Faculté de Médecine de Nice**

**Constitution du jury en qualité de 4ème membre**

**Professeurs Honoraires**

M. AMIEL Jean	M. GASTAUD Pierre
M. ALBERTINI Marc	M. GÉRARD Jean-Pierre
M. BALAS Daniel	M. GILLET Jean-Yves
M. BATT Michel	M. GRELLIER Patrick
M. BLAIVE Bruno	M. GRIMAUD Dominique
M. BOQUET Patrice	M. HOFLIGER Philippe
M. BOURGEON André	M. JOURDAN Jacques
M. BOUTTÉ Patrick	M. LAMBERT Jean-Claude
M. BRUNETON Jean-Noël	M. LAZDUNSKI Michel
Mme BUSSIERE Françoise	M. LEFEBVRE Jean-Claude
M. CAMOUS Jean-Pierre	M. LE FICHOUX Yves
M. CANIVET Bertrand	Mme LEBRETON Elisabeth
M. CASSUTO Jill-Patrice	M. MARIANI Roger
M. CHATEL Marcel	M. MASSEYEFF René
M. COUSSEMENT Alain	M. MATTEI Mathieu
Mme CRENESSE Dominique	M. MOUIEL Jean
M. DAR COURT Guy	Mme MYQUEL Martine
M. DELLAMONICA Pierre	M. ORTONNE Jean-Paul
M. DELMONT Jean	M. PRINGUEY Dominique
M. DEMARD François	M. SANTINI Joseph
M. DESNUELLE Claude	M. SAUTRON Jean Baptiste
M. DOLISI Claude	M. SCHNEIDER Maurice
Mme EULLER-ZIEGLER Liana	M. TOUBOL Jacques
M. FENICHEL Patrick	M. TRAN Dinh Khiem
M. FRANCO Alain	M. VAN OBERGHEN Emmanuel
M. FREYCHET Pierre	M. ZIEGLER Gérard

**M.C.U. Honoraires**

M. ARNOLD Jacques	M. GIUDICELLI Jean
M. BASTERIS Bernard	M. MAGNÉ Jacques
M. BENOLIEL José	Mme MEMRAN Nadine
Mlle CHICHMANIAN Rose-Marie	M. MENGUAL Raymond
Mme DONZEAU Michèle	M. PHILIP Patrick
M. EMILIOZZI Roméo	M. POIRÉE Jean-Claude
M. FRANKEN Philippe	Mme ROURE Marie-Claire
M. GASTAUD Marcel	

## REMERCIEMENTS

---

Aux membres du jury :

Au **Professeur Pierre Marty**, vous me faites l'honneur de présider ce jury. Je tiens à vous remercier pour vos enseignements toujours passionnants. Cela fait bientôt cinq ans que vous partagez un peu de votre grande expérience avec moi, vous m'avez fait découvrir et aimer la Parasitologie dès mon premier stage d'interne. Merci pour votre sympathie, votre humour, vos conseils et votre soutien tout au long de ces années. Soyez assuré de mon profond respect.

Au **Docteur Christelle Pomares**, tu m'as fait l'honneur de diriger cette thèse. Merci pour ta disponibilité, tes conseils et ton aide tout au long de ce travail. Merci pour ta bienveillance et ton soutien depuis que je te connais ainsi que pour ton enseignement. Je suis heureux que nous ayons déjà d'autres projets en perspective, c'est un vrai plaisir de travailler avec toi.

Au **Professeur Valérie Giordanengo**, merci d'avoir accepté de juger ce travail, c'est un honneur de vous compter parmi les membres de mon jury. Merci pour votre gentillesse, vos conseils et l'aide que vous avez pu m'apporter durant mon internat. Merci de m'avoir accueilli à bras ouverts dans votre service ce semestre.

Au **Professeur Jérôme Delotte**, vous me faites l'honneur de faire partie de mon jury et d'évaluer ce travail. Soyez assuré de ma profonde gratitude.

À ceux avec qui j'ai travaillé et appris :

*(en Parasitologie...)*

**Pascal**, merci pour tes cours toujours passionnés et passionnants, je te dois ma toute première publication ! Merci pour ta sympathie au quotidien.

**Lilia**, merci pour ta gentillesse et ta bienveillance, pour ce que tu m'as appris et va encore m'apprendre en Mycologie.

**Martine GT**, merci de m'avoir initié à la Mycologie lors de mes premiers mois d'interne, merci pour ta sincérité et tes conseils.

**Anne L**, merci pour ta compagnie toujours agréable et souriante dans le bureau. C'est un plaisir de te faire face chaque jour.

**Stéphane M**, merci pour ton expérience partagée en Parasitologie et sur de nombreux autres sujets, c'est toujours enrichissant de discuter avec toi. Tu es un ami, un grand frère, un exemple pour moi.

**Caroline D**, merci pour ta gentillesse, pour le temps passé à m'apprendre la microscopie et plein d'autres choses. Merci pour les rigolades, la musique, le sirtaki, tes conseils.

**Élodie**, merci pour ta gentillesse, pour le partage de ton expérience en Mycologie. Merci pour les rires, merci d'avoir entendu Mastercuisse ! Et merci pour ton intérêt certain à ma vie sentimentale... :)

**Karine**, un grand merci d'abord pour ton aide précieuse dans ce travail. Merci pour ton sourire, tu rayannes au quotidien dans le laboratoire.

**Krystel**, merci de ton amabilité, merci d'avoir enlevé ta veste devant l'externe. C'est un plaisir de travailler avec toi.

**Nicole**, merci pour vos conseils, merci de me faire partager votre expérience.

**Greg**, tu as une place bien à toi dans ces remerciements, à part du C3M (obligé...je crois qu'on n'a pas fini de travailler ensemble...). Merci de partager ta riche expérience avec moi, merci pour ta sympathie, ton humour. Et merci pour Cuichette.

(...et ailleurs)

Les biologistes côtoyés au cours de mes stages : **Nicolas, Alice, le Professeur Raymond Ruimy, Didier, Isabelle, Florence F, Corinne, Anny, Danièle, Pierre, Patricia, François B, Pascale, Thibaud, les Professeurs Martine Wallon et François Peyron, Jean, Florence P, Damien, Méja, Anne DM, Isabelle, Laurence** : merci pour votre accueil et votre gentillesse, pour ce que vous m'avez apporté durant ma formation. Et plus spécialement merci à **Caroline B** de ne jamais capter une seule de mes références cinéματο-musicales ; et à **Géraldine**, la vie est un combat... et ce soir, j'lui mets un bon coup d'boule dans les valseuses !

**Maria**, tu m'as bien sûr appris beaucoup de choses mais tu méritais une place particulière. Merci pour tout ce que tu m'as apporté, dans les bons moments et dans les moments plus difficiles. Merci pour tes conseils, ton écoute bienveillante, ta sagesse. Merci pour ton exceptionnelle bonne humeur et ta joie de vivre. Tu es un amour.

À mes co-internes : **Lamine**, pour les rigolades, ta bonne humeur et tes siestes au 4<sup>ème</sup> ; **Stéphane S**, pote de promo *ad vitam* même si on n'a jamais été en stage ensemble ; **Célia**, c'est grâce à toi que je suis venu à Nice et tu resteras la meilleure maman référente même si ok Stéphane se débrouille pas mal :) ; **Aubin**, pour les fous rires, les « toc-toc », les boulettes et ton amitié ; **Lam Thuy**, pour ta gentillesse et ton courage ; **Rémi** aka « le valideur fou », pour ton phlegme en toute circonstance ; et tous les autres de Nice et de Lyon.

Plus généralement à tous les techniciens et techniciennes, les ingénieurs, les cadres et secrétaires des labos de Parasito-Myco, Bactério, Viro, Hémato et Bioch, merci pour votre accueil, ces années ont été ponctuées de beaucoup de belles rencontres. Merci pour le temps passé à m'apprendre.

À toute l'**équipe du C3M**, merci pour votre accueil et votre gentillesse : **Anne D, Patrick M, Orane, Céline, Juan, Anne-So, Johan, Chaïma, Pauline, Salma, Alex** ; avec une attention particulière à **Cédric et Océane**, tous les deux vous personnalisez la notion de contraste et c'est un spectacle très divertissant à regarder ; à **Alissa**, merci pour les danses ; et à **Laurent**, tu y auras droit au pâté de ragondin.

À mes amis de toujours :

**Kux, Bol, Munch, Ratinte, Mion, François, Saillmone, Pablo, Martine** : on en est presque à 30 ans d'amitié pour certains, juste un peu moins pour les autres, un nombre incalculable de souvenirs et de fous rires durant tout ce temps, vous avez entendu un paquet d'histoires de médecine, vous m'avez soutenu toutes ces années, ça fait 10 ans que vous vous demandez quand est-ce que je finis mes études !!! Et bin ça y est les gars, aujourd'hui je deviens officiellement Docteur Pitch ! Sourire sur mon visage, étoiles dans mon cœur, **j'vous kiff**.

À ma famille :

À mes parents, **Nadine** et **Patrick**, je vous remercie pour votre soutien dans tous mes choix de vie, pour votre aide tout au long de mon parcours, je n'aurais pas pu réussir sans vous. Merci pour tout ce que vous m'avez transmis.

À ma sœur, **Emmanuelle**, merci pour ton soutien et ta présence, pour les souvenirs d'enfance, PS : les vaccins c'est super :).

À mes grands-parents, **Mamie-Rose**, **Mamie Annick** et **Papy Michel**, merci pour votre soutien et votre gentillesse, pour tous ces souvenirs.

*« Ceux qui croient au progrès s'exposent au regret d'être nés trop tôt. »*

*Oscar Louis Forel*

*Et pour les amateurs de langues mortes,*

*« None sed non nova » : la manière est nouvelle, mais non la matière.*

*Citation que j'ai jamais pu replacer correctement dans une conversation...*

# SOMMAIRE

---

Résumé ..... 13

Article de recherche publié dans le journal “Parasite”

**Serological diagnosis of *Toxoplasma gondii*: analysis of false-positive  
IgG results and implications.**

Authors and abstract..... 14

**Introduction ..... 15**

**Materials and Methods ..... 15**

- Sample collection..... 15
- Study design..... 15
- Study population ..... 16
- *RecomLine*<sup>®</sup> immunoblot..... 16
- LDBio<sup>®</sup> immunoblot..... 16
- Protein BLAST analysis (Basic Local Alignment Search Tool) ..... 16

**Results ..... 16**

- Serological tests results..... 16
- *RecomLine*<sup>®</sup> immunoblot results ..... 16
- LDBio<sup>®</sup> immunoblot results ..... 17
- Analysis of the combined immunoblots results..... 17
- Protein BLAST analysis ..... 17

**Discussion ..... 18**

**References ..... 20**



Director’s cut..... 22

Credits ..... 31

## RÉSUMÉ

---

**Introduction :** La toxoplasmose est une maladie parasitaire due à *Toxoplasma gondii*, un protozoaire intracellulaire obligatoire de distribution mondiale. Asymptomatique chez les personnes en bonne santé, la primo-infection à *T. gondii* chez la femme enceinte peut être dangereuse pour le fœtus, allant jusqu'à la mort fœtale *in utero*. Une sérologie IgG faussement positive pendant la grossesse peut mener à un diagnostic erroné d'infection ancienne et à stopper les mesures préventives. Dans cette étude, nous avons cherché une explication aux IgG anti-*T. gondii* suspectés faux positifs.

**Matériels et Méthodes :** De juillet 2009 à avril 2018, nous avons collecté 189 sérums présentant un résultat Architect<sup>®</sup> Toxo IgG (Abbott Laboratories) positif ainsi qu'un résultat IgG négatif par au moins deux autres tests sérologiques. Nous avons utilisé l'immunoblot *recomLine* Toxoplasma IgG<sup>®</sup> (Mikrogen Diagnostik), contenant sept antigènes recombinants, pour élaborer un profil de réactivité immunitaire pour chaque sérum. L'immunoblot LDBio Toxo II IgG<sup>®</sup> (LDBio Diagnostics) a servi de test de confirmation pour conclure sur la vraie ou fausse positivité des IgG retrouvés en Architect<sup>®</sup>.

**Résultats :** En immunoblot *recomLine*<sup>®</sup>, les bandes GRA8 et/ou GRA7 étaient positives pour 148 échantillons (78,3%). GRA8 était la bande la plus fréquente, apparaissant dans 133 profils (70,4%) alors que GRA7 était présente pour 49 échantillons (25,9%). Sur les 81 échantillons testés en LDBio<sup>®</sup>, 23 se sont avérés positifs (28,4%). Sur les 58 LDBio<sup>®</sup> négatifs (71,6%) (réels faux positifs IgG Architect<sup>®</sup>), 23 échantillons n'ont montré ni bande GRA8 ni bande p30 en *recomLine*<sup>®</sup> (39,6%) et leur fausse positivité reste donc inexplicée (Abbott utilisant ces deux antigènes recombinants dans leur test).

**Conclusion :** La fausse positivité IgG Architect<sup>®</sup> pour *T. gondii* semble être due à une réactivité envers la protéine GRA8 pour la majorité des sérums et envers GRA7 dans une moindre mesure. L'hypothèse d'un contact passé avec des parasites génétiquement proches de *T. gondii* comme *Hammondia hammondi* ou *Neospora caninum* semble intéressante et devrait être approfondie.



## Serological diagnosis of *Toxoplasma gondii*: analysis of false-positive IgG results and implications

Loïc Simon<sup>1,2,\*</sup>, Judith Fillaux<sup>3,4</sup>, Aurélie Guigon<sup>5</sup>, Rose-Anne Lavergne<sup>6,7</sup>, Odile Villard<sup>8</sup>, Isabelle Villena<sup>9</sup>, Pierre Marty<sup>1,2</sup>, Christelle Pomares<sup>1,2</sup>, *Toxoplasma* p35 Study Group<sup>a</sup>

<sup>1</sup> Service de Parasitologie-Mycologie, CHU de Nice, Université Côte d'Azur, 06202 Nice, France

<sup>2</sup> Inserm U1065, C3M, 06204 Nice, France

<sup>3</sup> Service de Parasitologie-Mycologie, CHU de Toulouse, 31300 Toulouse, France

<sup>4</sup> PharmaDev, IRD UMR 152, Université de Toulouse, 31062 Toulouse, France

<sup>5</sup> Service de Microbiologie, Hôpital La Source, CHR d'Orléans, 45100 Orléans, France

<sup>6</sup> Parasitologie-Mycologie, CHU de Nantes, 44093 Nantes, France

<sup>7</sup> Université de Nantes, Nantes Atlantique Universités, EA1155-IICiMed, Institut de Recherche en Santé 2, 44200 Nantes, France

<sup>8</sup> Institut de Parasitologie et de Pathologie Tropicale, EA 7292, Fédération de Médecine Translationnelle, Université de Strasbourg, 67000 Strasbourg, France

<sup>9</sup> EA7510, ESCAPE, Laboratoire de Parasitologie-Mycologie, Université de Reims Champagne-Ardenne, SFR Cap Santé FED 4231, 51096 Reims, France

Received 3 December 2019, Accepted 29 January 2020, Published online 7 February 2020

**Abstract – Background:** Primary infection by *Toxoplasma gondii* in pregnant women can result in serious outcomes for the foetus. A false-positive IgG result during pregnancy can lead to a misdiagnosis of past infection and to stopping preventive measures. We collected 189 sera with positive Architect<sup>®</sup> Toxo IgG assay (Abbott Laboratories) and negative IgG results with at least two other serological tests, in order to find an explanation for the suspected false-positive IgG results. We used the *recomLine Toxoplasma IgG*<sup>®</sup> immunoblot (Mikrogen Diagnostik) to search for specific antigenic reactivities of the sera, and the LDBio Toxo II IgG<sup>®</sup> immunoblot (LDBio Diagnostics) as a confirmatory test. **Results:** The bands GRA8 and/or GRA7 were positive for 148 samples (78.3%). GRA8 was the most frequent band, appearing in 133 patterns (70.4%), whereas GRA7 was present for 49 samples (25.9%). Of the 81 samples tested with LDBio<sup>®</sup>, 23 (28.4%) turned out to be positive. Of the 58 negative LDBio<sup>®</sup> tests (71.6%) (real false-positive Architect<sup>®</sup> IgG), 23 samples (39.6%) did not show either a GRA8 or p30 band by *recomLine*<sup>®</sup>. Their false positivity with Architect<sup>®</sup> remains unexplained since Abbott uses these two recombinant antigens for their assay. **Conclusions:** The Architect<sup>®</sup> IgG false positivity for *T. gondii* seems to be due to reactivity against GRA8 for the majority of the sera and GRA7 to a lesser extent. The hypothesis of past contact with parasites genetically close to *T. gondii* such as *Hammondia hammondi* or *Neospora caninum* seems promising and should be assessed further.

**Key words:** *Toxoplasma gondii*, IgG, False-positive, Serology, Architect, Toxoplasmosis.

**Résumé – Diagnostic sérologique de *Toxoplasma gondii* : analyse des IgG faux positifs et implications.**

**Contexte :** La primo-infection à *Toxoplasma gondii* chez la femme enceinte peut avoir de graves conséquences pour le fœtus. Un résultat IgG faussement positif pendant la grossesse peut mener à un diagnostic erroné d'infection ancienne et à stopper les mesures préventives. Nous avons collecté 189 sérums présentant un résultat Architect<sup>®</sup> Toxo IgG (Abbott Laboratories) positif ainsi qu'un résultat IgG négatif par au moins deux autres tests sérologiques, dans le but de trouver une explication aux résultats IgG suspectés faux positifs. Nous avons utilisé l'immunoblot *recomLine Toxoplasma IgG*<sup>®</sup> (Mikrogen Diagnostik) pour chercher certaines réactivités antigéniques spécifiques des sérums et l'immunoblot LDBio Toxo II IgG<sup>®</sup> (LDBio Diagnostics) comme test de confirmation. **Résultats :** Les bandes GRA8 et/ou GRA7 étaient positives pour 148 (78,3 %) échantillons. GRA8 était la bande la plus fréquente, apparaissant dans 133 (70,4 %) profils alors que GRA7 était présente pour 49 (25,9 %) échantillons. Sur les 81 échantillons testés en LDBio<sup>®</sup>, 23 (28,4 %) se sont révélés positifs. Sur les 58 (71,6 %) tests LDBio<sup>®</sup> négatifs (réels faux positifs IgG Architect<sup>®</sup>), 23 (39,6 %) échantillons n'ont montré ni bande GRA8 ni bande p30 en *recomLine*<sup>®</sup> et leur fausse

\*Corresponding author: [simon.l@chu-nice.fr](mailto:simon.l@chu-nice.fr)

<sup>a</sup>*Toxoplasma* p35 Study Group: Jean-François Carod, Bernard Cimon, Rita Donsimoni, Valérie Ernault, Héléne Fricker-Hidalgo, Juliette Gillon, Nadine Godineau, Géraldine Gonfrier, Marie Hautecoeur, Stéphane Liguori, Marie-Noëlle Noulard, Hervé Pelloux, Cécile Poggi.

positivité reste donc inexplicée puisque Abbott utilise ces deux antigènes recombinants dans son test. *Conclusions* : La fausse positivité IgG Architect<sup>®</sup> pour *T. gondii* semble être due à une réactivité envers la protéine GRA8 pour la majorité des sérums et envers GRA7 dans une moindre mesure. L'hypothèse d'un contact passé avec des parasites génétiquement proches de *T. gondii* comme *Hammondia hammondi* ou *Neospora caninum* semble prometteuse et devrait être approfondie.

## Introduction

Toxoplasmosis is a parasitic disease due to *Toxoplasma gondii*, an obligate intracellular protozoan with a worldwide distribution. The life cycle of the parasite involves sexual reproduction in definitive hosts from the Felidae family, and a broad range of intermediate hosts including mammals and birds [18, 26, 30, 41, 46, 47]. Human infection occurs mainly by ingestion of *T. gondii* oocysts present on raw and unwashed vegetables, and through consumption of raw or undercooked meat containing cysts of the parasite [6, 22, 48]. Although *T. gondii* primary infection is usually asymptomatic in the healthy population, it can be life-threatening for others, like immunocompromised patients. In these hosts, acute infection or reactivation of a past infection can lead to severe and possibly lethal diseases (cerebral, pulmonary, or disseminated toxoplasmosis) [25, 27, 40]. In particular, primary infection in pregnant women and reactivation in immunocompromised pregnant women can be the cause of congenital toxoplasmosis with the risk of serious outcomes for the foetus, mainly retinitis pigmentosa, hydrocephaly, or even death *in utero* [4, 24, 44].

In some countries, the health authorities have set up a prenatal screening program for *T. gondii* [33, 34, 43]. In France, pregnant women are tested in the early weeks of pregnancy for the presence of specific IgG and IgM against *T. gondii*. The presence of *T. gondii* IgG at a stable level without IgM is in favour of a past infection. These women are considered to be immunised against *T. gondii* and follow-up is no longer performed. In seronegative pregnant women, monthly screening will be performed to allow early diagnosis and treatment of an acute infection in order to prevent transplacental transmission of the parasite to the foetus [43]. This highlights the importance of an accurate and reliable test for the detection of specific IgG, given that a false-positive result can lead to a misdiagnosis of past infection, and to stopping surveillance and preventive measures in a pregnant woman.

Currently, many serological tests are available for IgG detection with different sensitivities and specificities. Studies on the Architect<sup>®</sup> Toxo IgG assay (Abbott Laboratories, North Chicago, IL, USA) show specificities and sensitivities ranging from 99.1% to 99.8% and 92.1% to 99.7%, respectively [17, 29, 32, 37, 42]. This assay is based on the principle of chemiluminescent microparticle immunoassay (CMIA). According to the manufacturer, Architect<sup>®</sup> uses two *T. gondii* recombinant antigens for the immunoassay: a membrane protein of 30 kDa (= p30) called SAG1 (surface antigen 1), only found in the tachyzoite stage of the parasite; and a cytoplasmic protein of 35 kDa (= p35) called GRA8 (dense granule), found in the tachyzoite and bradyzoite stages of the parasite. Similarly, studies on other commonly used automated or semi-automated immunoassays (Advia Centaur<sup>®</sup>, AxSym<sup>®</sup>, Elecsys<sup>®</sup>, Enzygnost<sup>®</sup>, Liaison<sup>®</sup>, Platelia<sup>®</sup>, Vidas<sup>®</sup>, and Vidia<sup>®</sup>)

show various specificities from 99.3% to 100%, while sensitivities range from 93.8% to 100% [32, 42]. Since the specificity is not 100% for some of these assays, pregnant women are exposed to the risk of being misdiagnosed as immunised, whereas they are not. In our article, we will focus on Architect<sup>®</sup> in order to find a rational explanation for the suspected false-positive Architect<sup>®</sup> Toxo IgG results. To our knowledge, this is the first study that tries to provide an explanation for discordant *T. gondii* IgG test results.

## Materials and methods

### Sample collection

The laboratory of Parasitology-Mycolology at the University Hospital of Nice, France (Nice laboratory) is a member of the National Reference Centre for toxoplasmosis (Reims, France). This laboratory regularly receives human serum samples from other laboratories throughout France, in order to provide expertise for serological diagnosis of toxoplasmosis. From July 2009 to April 2018, sera from other laboratories with discordant *T. gondii* IgG results between different serological assays were sent to the Nice laboratory. The samples included in this study came from 21 cities in mainland France (Angers, Antibes, Arras, Embrun, Fréjus, Grenoble, Lisieux, Miramas, Nantes, Nice, Orléans, Reims, Saint-Denis, Saint-Etienne-du-Rouvray, Saint-Laurent-du-Var, Salon-de-Provence, Strasbourg, Toulon, and Toulouse), from the island of Corsica (Ajaccio), and French Guiana in South America (Saint-Laurent-du-Maroni); in addition to the samples from the Nice laboratory (Table 1).

### Study design

Sera with positive Architect<sup>®</sup> Toxo IgG test result and negative test result found by at least one other IgG assay were selected for further analyses. According to the manufacturer's instructions, the Architect<sup>®</sup> Toxo IgG assay is considered positive when the titre is  $\geq 3$  IU/mL. The other serological test results came from the following assays: Platelia<sup>®</sup> Toxo IgG (Bio-Rad, Hercules, CA, USA), AxSym<sup>®</sup> Toxo IgG (Abbott Laboratories), Toxolater Fumouze<sup>®</sup> (Biosynex, Eckbolsheim, France), Pastorex<sup>™</sup> Toxo (Bio-Rad), Modified Agglutination Test (MAT), Toxo-Spot IF<sup>®</sup> (bioMérieux, Marcy-l'Étoile, France), and Vidas<sup>®</sup> Toxo IgG II (bioMérieux). In case only one of these assays was performed, the Nice laboratory performed a Vidas<sup>®</sup> Toxo IgG II analysis. When a Vidas<sup>®</sup> test result was the only one available, a Toxo-Screen DA<sup>®</sup> (bioMérieux) was performed. For sera from the Nice laboratory, the Vidas<sup>®</sup> and Toxo-Screen DA<sup>®</sup> assays were always performed as part of the routine procedure of the laboratory. We grouped all these eight assays under the name

**Table 1.** Origin of the samples.

City	Number of sera
Private laboratories	
Embrun	2
Lisieux	2
Miramas	1
Saint-Etienne-du-Rouvray	2
Saint-Laurent-du-Var	1
Salon-de-Provence	1
Hospital laboratories	
Ajaccio (Corsica)	3
Angers	4
Antibes	1
Arras	4
Fréjus	4
Grenoble	3
Nantes	30
Nice	60
Orléans	10
Reims	4
Saint-Denis	3
Saint-Laurent-du-Maroni (French Guiana)	3
Strasbourg	5
Toulon	1
Toulouse	45
<b>Total</b>	<b>189</b>

“alternative tests”. Thus, each serum was positive by Architect<sup>®</sup> Toxo IgG and negative by at least two assays among the alternative tests. Additionally, Architect<sup>®</sup> Toxo IgM (Abbott Laboratories) was performed for all the sera in the study, and test results were all negative (index <0.6 according to the manufacturer’s instructions), except for one individual (Architect<sup>®</sup> IgM index = 1.8) whose positive IgM were later confirmed on another sample as non-specific IgM.

To increase the power of the study, grey-zone IgG results by Architect<sup>®</sup> were considered negative and were not included. Concerning the other three quantitative tests performed (Vidas<sup>®</sup>, Platelia<sup>®</sup>, and AxSym<sup>®</sup>), all IgG results obtained were below the grey-zone.

## Study population

In total, 189 samples collected from 176 individuals presenting positive IgG Architect<sup>®</sup> ( $\geq 3$  IU/mL) and negative IgG with at least two other serological tests were included in the study over a period of 9 years. The study population included 155 females (88.1%) and 21 males (11.9%). The mean age was 31.5 years, ranging from 1 to 87 years (including six children under 17 years).

## RecomLine<sup>®</sup> immunoblot

The *recomLine* Toxoplasma IgG<sup>®</sup> immunoblot (Mikrogen Diagnostik, Neuried, Germany) was performed on the 189 sera. This immunoblot is able to discriminate antibodies against the recombinant proteins of *T. gondii* ROP1c (= p66), GRA1 (= p24), GRA7 (= p29), GRA8 (= p35), SAG1 (= p30),

MAG1 (= p65, p68), and MIC3. An additional antigen called rSAG1 (= p30, low concentration) is loaded to the strip as a marker of past infection. We hijacked the initial purpose of this diagnostic test and used it solely to elaborate a pattern of antibody reactivity, by noting the positive bands among the eight recombinant antigens coated, for each serum tested.

## LDBio<sup>®</sup> immunoblot

Whenever possible, the LDBio Toxo II IgG<sup>®</sup> immunoblot (LDBio Diagnostics, Lyon, France) was performed on the samples. We used this assay as a confirmatory test of the absence or presence of specific anti-*T. gondii* IgG [14]. According to the manufacturer, a positive LDBio<sup>®</sup> immunoblot is defined by three apparent bands including p30 among the five *T. gondii* natural antigens coated, of molecular weights 30 kDa (= p30), 31 kDa, 33 kDa, 40 kDa, and 45 kDa. This assay was used to conclude whether the positive Architect<sup>®</sup> Toxo IgG test results were true- or false-positives.

## Protein BLAST analysis (Basic Local Alignment Search Tool)

Protein sequences were blasted with NCBI’s online alignment tool using substitution matrix BLOSUM62. Similarity scores are expressed in bits, and Expect values (*E*-values)  $\leq 10e-10$  demonstrate significant homologies.

## Results

### Serological tests results

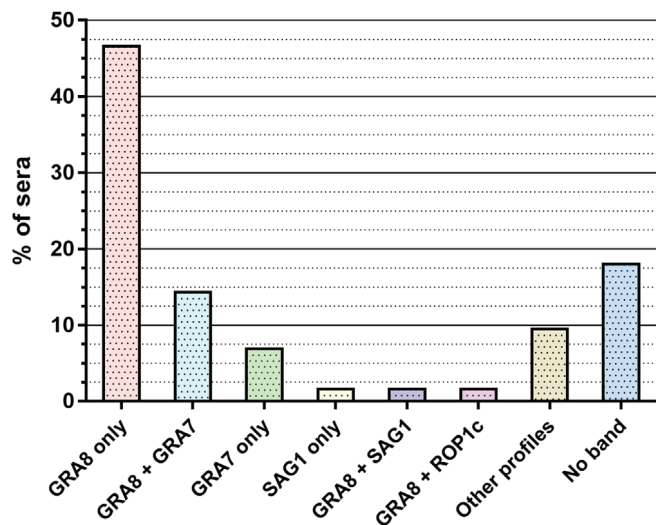
Across the 189 Architect<sup>®</sup> Toxo IgG performed, the IgG values ranged from 3.0 to 235.1 IU/mL; the median was 5.6 IU/mL with an interquartile range of 6.5 IU/mL. Among the alternative tests, 157 (83.1%) Toxo-screen<sup>®</sup> and 134 (70.9%) Vidas<sup>®</sup> were performed. All the other alternative tests performed are detailed in Table 2.

### RecomLine<sup>®</sup> immunoblot results

We carried out 189 *recomLine*<sup>®</sup> tests in total and analysed the pattern of positive bands among the eight recombinant antigens for each serum (Fig. 1). In our full sample set, we found 20 different profiles in which zero to maximum three bands per immunoblot were found. The majority of the samples were only positive for the GRA8 band (46.6%) but other frequent patterns were found, especially GRA8 + GRA7 (14.3%) and GRA7 only (6.9%). The remaining patterns included: SAG1 only (1.6%), GRA8 + SAG1 (1.6%), GRA8 + ROP1c (1.6%), ROP1c only (1.1%), GRA8 + SAG1 + ROP1c (1.1%), GRA8 + GRA7 + GRA1 (1.1%), GRA8 + GRA7 + ROP1c (1.1%), GRA8 + GRA7 + SAG1 (1.1%), MIC3 only (0.5%), GRA1 only (0.5%), GRA8 + GRA1 (0.5%), GRA8 + MAG1 (0.5%), GRA8 + MIC3 (0.5%), GRA7 + GRA1 (0.5%), GRA8 + GRA7 + MAG1 (0.5%), and GRA7 + GRA1 + ROP1c (0.4%). In 18% of the samples, the immunoblots did not show any positive band.

**Table 2.** Diagnostic tests performed.

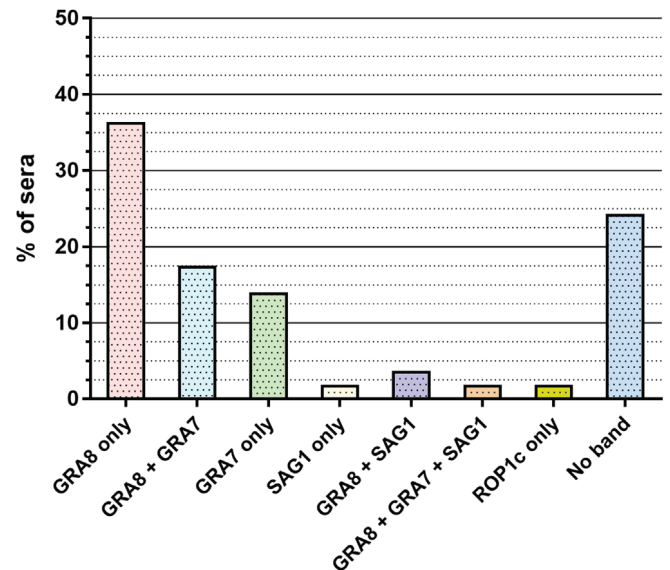
Analysis	Number of sera	Negative (%)	Positive (%)
Architect® Toxo IgG	189	0 (0)	189 (100)
Toxo-Screen DA®	157	157 (100)	0 (0)
Vidas® Toxo IgG	134	134 (100)	0 (0)
Platelia® Toxo IgG	63	63 (100)	0 (0)
AxSYM® Toxo IgG	21	21 (100)	0 (0)
Toxolates Fumouze®	10	10 (100)	0 (0)
Toxo-Spot IF®	8	8 (100)	0 (0)
Pastorex™ Toxo	7	7 (100)	0 (0)
Modified Agglutination Test	4	4 (100)	0 (0)
LDBio-Toxo II IgG®	81	58 (71.6)	23 (28.4)

**Figure 1.** Description of the *recomLine*® immunoblot profiles performed on the 189 suspected false-positive sera with Architect®.

Taking into account all the patterns, we found GRA8 and/or GRA7 bands for 148 samples (78.3%). GRA8 was the most frequent band, appearing in total in 133 patterns (70.4%), whereas GRA7 was present for 49 samples (25.9%). We did not observe any specific pattern according to age or gender categories.

### LDBio® immunoblot results

We were able to perform 81 LDBio® tests on the leftover serum. Of these 81 samples tested, 23 (28.4%) turned out to be positive despite their 2–4 negative alternative tests (Table 2 and Supplementary Table 1). Most of the positive samples had similar profiles with LD Bio®: 21 of them presented apparent bands at 30 kDa, 31 kDa, and 40 kDa. The remaining two samples presented apparent bands at 30 kDa, 31 kDa, 33 kDa, and 40 kDa. The Architect® Toxo IgG values for these sera ranged from 3.2 to 30.4 IU/mL, the median was 6.6 IU/mL with an interquartile range of 10.1 IU/mL. Moreover, 58 samples (71.6%) presented a negative LDBio® test and were considered true false-positive Architect® IgG results. As for the results of the *recomLine*® immunoblots, there was no specific result according to age or gender.

**Figure 2.** Description of the *recomLine*® immunoblot profiles (for the 58 negative LDBio® tests considered true false-positive sera with Architect®).

### Analysis of the combined immunoblots results

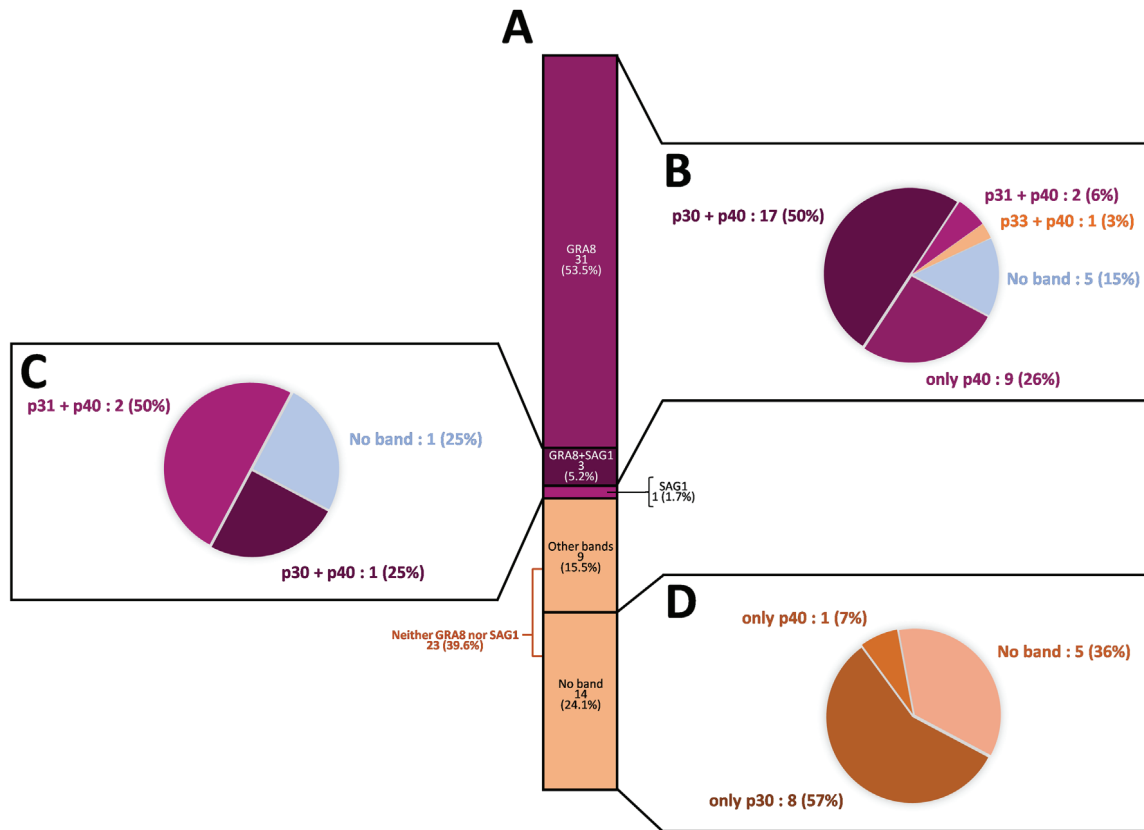
The negative LDBio® profiles are further detailed in Figures 2 and 3. Concerning these samples, *recomLine*® immunoblots show that GRA8 (p35) and/or SAG1 (p30) appeared in 35 samples (60.4%) (including 31 profiles (53.5%) with GRA8, 1 (1.7%) with SAG1 and 3 (5.2%) with GRA8 + SAG1) (Figs. 2 and 3A). This may explain the false positivity with Architect®, which uses the recombinant antigens GRA8 and p30. On the other hand, 23 samples (39.6%) did not show either a GRA8 or p30 band and yet were positive with Architect® (Figs. 2 and 3A). In detail, for these samples, *recomLine*® patterns showed no band for 14 samples (24.1%), only GRA7 for 8 samples (13.8%), and only ROP1c for 1 sample (1.7%). For the samples containing the GRA8 band by *recomLine*®, the majority (50%) presented a p30 + p40 LDBio® profile and 5 samples (15%) did not present any band by LDBio® (Fig. 3B). Of the 4 samples containing the SAG1 band by *recomLine*®, 1 presented a p30 band by LDBio® (Fig. 3C). Concerning the samples without any *recomLine*® band, 36% also did not present any band by LDBio®, and 57% presented a p30 band (Fig. 3D).

For the 23 positive LDBio® tests, all the samples presented the GRA8 band by *recomLine*®. Although all the positive LDBio® tests had a p30 band by definition, 1 out of 23 presented the SAG1 band by *recomLine*®.

Among the 81 LDBio® tests performed, 33 showed only the GRA8 band by *recomLine*®, of which 12 samples (36.4%) were positive and 21 (63.6%) were negative by LDBio®.

### Protein BLAST analysis

To assess the possibility of other cross-reactivities, we blasted protein sequences of *T. gondii* GRA8, GRA7, and SAG1 (p30) (Table 3). First, the *T. gondii* GRA8 protein



**Figure 3.** Description of the immunoblot profiles of the 58 negative LDBio® tests (true false-positives with Architect®). (A) Proportion of recomLine® profiles positive for GRA8, SAG1, GRA8+SAG1, other bands or no band, among the 58 negative LDBio® tests. (B) LDBio® profiles of the GRA8-positive recomLine® profiles. (C) LDBio® profiles of the SAG1-positive recomLine® profiles. (D) LDBio® profiles of the “no band” recomLine® profiles.

**Table 3.** Protein BLAST analysis.

Blasted proteins	Bitscore	E-value	Query cover (%)	Identities (%)	Positives (%)	Gaps (%)
<i>T. gondii</i> GRA8 vs. <i>H. hammondi</i> GRA8	275.0	2e−89	100	75	82	1
<i>T. gondii</i> GRA7 vs. <i>H. hammondi</i> GRA7	260.0	4e−84	99	60	70	2
<i>T. gondii</i> GRA8 vs. <i>T. gondii</i> GRA7	12.7	9.1	4	50	58	41
<i>T. gondii</i> GRA7 vs. <i>N. caninum</i> 021640	68.6	3e−10	91	36	47	21
<i>T. gondii</i> p30 vs. <i>N. caninum</i> P36	317.0	5e−104	94	52	66	1

showed high similarity to the *Hammondia hammondi* GRA8 protein (dense granule) in the Protein BLAST analysis. In the same way, the *T. gondii* GRA7 protein showed strong similarity with the *H. hammondi* GRA7 protein. Moreover, it also seems to have sequence homology with the uncharacterised protein NCLIV\_021640 from the parasite *Neospora caninum*. On the other hand, there is no significant homology between *T. gondii* GRA7 and GRA8 proteins. Concerning *T. gondii* p30, its sequence homology with *N. caninum* surface protein P36 is substantial.

### Discussion

All serological methods can provide false-positive results, irrespective of the infectious disease tested. The Architect®

Toxo IgG assay is currently one of the most commonly used for *T. gondii* serological diagnosis in France. In this study, we collected all suspected false-positive Architect® IgG test results, regardless of the gender. Despite proven high specificity, the few false-positive test results are still a serious issue, particularly for pregnant women. In immunocompromised patients, reactivation of a past infection can be fatal, mainly from brain damage. In this specific population, a false-positive IgG test result can be misleading and appear to indicate cerebral toxoplasmosis, thus neglecting other differential diagnoses (e.g., cryptococcal meningitis or primary central nervous system lymphoma). In pregnant women, acute infection or reactivation of *T. gondii* can lead to a fatal outcome for the foetus. Importantly, a false-positive IgG test result in a pregnant woman can lead to stopping preventive measures, leading to the risk of an acute infection during pregnancy. In addition,

false-positive IgG test results will make it difficult to diagnose an acute infection as it will be more difficult to differentiate the false-positive IgG from the neosynthesized ones of the acute infection. In such a situation, testing IgM, IgA, and avidity will be of utmost importance for the diagnosis. On the basis of our results, it seems that Architect<sup>®</sup> IgG false positivity may be due to reactivity against GRA8 for the majority of the sera and GRA7 to a lesser extent. We also noted that a significant part of our samples did not present reactivity against any of the seven different recombinant proteins loaded on the *recomLine*<sup>®</sup> immunoblot.

Previous studies on *T. gondii* cross-reactivity and the BLAST analyses performed in this work have led us to take an interest in the protozoan *H. hammondi*. *Hammondia hammondi* is another obligate intracellular parasite that infects cats. It is closely relative to *T. gondii* in terms of morphology, biology and genetics [19, 35]; however, this parasite is not known to be infective in humans [45]. Its range of intermediate hosts seems to be more restrictive and includes mainly rodents [16]. *Hammondia hammondi* also produces a GRA8 protein (dense granule) so the hypothesis of cross-reactivity with some of its antigens should be assessed.

Given the BLAST analysis results, it would be interesting to test our samples for *N. caninum* too. This parasite, like *H. hammondi*, is not known to be infective in humans and is found in dogs and other mammals. As remarkably reviewed by Gondim et al., several studies in the past forty years have shown serological cross-reactivities and cross-immunity between *T. gondii*, *H. hammondi*, and *N. caninum* [19]. *In vivo*, rodents infected with *H. hammondi* developed immunity and were protected against *T. gondii* lethal dose infection [15]. It is interesting to note that the immunogenic potential seems to depend on the strains used for experiments [3]. Immunisation with *H. hammondi* protects goats from abortion induced by *T. gondii* [31]. Serological cross-reactivities have also been found between these two parasites in mice, rabbits, dogs, and pigs using immunofluorescence, haemagglutination, dye-test or ELISA [19]. In another study reviewed by Gondim et al., five *T. gondii* antigens of molecular weight 30, 32, 35, 66, and 90 kDa were recognised using polyclonal anti-*H. hammondi* serum [35].

Concerning *N. caninum*, Gondim et al. reviewed studies showing that cross-immunity and protection of mice against *T. gondii*, after immunisation by *N. caninum*, are dependent on strains and doses used for experimental infections [19]. Serological cross-reactivities with *T. gondii* have also been a problem for the production of monoclonal antibodies against *N. caninum* [28, 39]. These findings highlight the fact that the strains of pathogens such as *H. hammondi*, *T. gondii*, and *N. caninum* are important in terms of cross-reactivity issues.

Moreover, the number of *recomLine*<sup>®</sup> immunoblots without any positive bands raises additional questions. Despite the fact that none of them had a positive LDBio<sup>®</sup> test (defined by three bands including p30), some nonetheless showed a p30 band not found by *recomLine*<sup>®</sup>. This inconsistency from one assay to another could be due to a difference of sensitivity between these two immunoblots. The LDBio<sup>®</sup> strips are indeed coated with natural *T. gondii* antigens, whereas *recomLine*<sup>®</sup> uses recombinant proteins.

Our results show that several negative serological tests do not guarantee true IgG negativity of the sera, given the positivity of 28.4% of the tested samples with the LDBio Toxo II IgG<sup>®</sup> confirmatory test. The main assumption that could explain this result is that individual variations in the quantity of circulating IgG are high after *T. gondii* infection. Very low titres could point out the lack of sensitivity of the automated assays compared to the LDBio<sup>®</sup> test facing such antibody titres.

As a reminder, the Architect<sup>®</sup> automated assay is based on the immune reactivity of the sera against the proteins p30 and GRA8. The discrepancies we found between the positivity with Architect<sup>®</sup> and yet the absence of GRA8 or p30 bands in immunoblots make us wonder whether the antigens chosen for automated assays are the most suitable ones. Most manufacturers do not in fact indicate what antigens are used in their test, and this can also be entire *T. gondii* antigenic extracts. A comparison between the different assays is then difficult to perform. We might wonder why the GRA8 antigen was initially added to the Architect<sup>®</sup> IgG assay. Was the aim to increase sensitivity in the detection of past *T. gondii* infection or to allow earlier diagnosis of recent infection? Some previous studies seem to show that the recombinant GRA8 antigen allows for better diagnosis of acute toxoplasmosis rather than chronic infection [11, 21]. Moreover, we can question whether the antibodies directed only against GRA8, as we highlighted in our study in 46.6% of samples, are sufficient to consider the patient immunised against *T. gondii*? In this regard, among the *recomLine*<sup>®</sup> tests only positive for GRA8 and tested by LDBio<sup>®</sup>, we found 36.4% positive and 63.6% negative confirmatory tests. Thus, in our sample set, some antibodies directed only against GRA8 could be considered true positive. The research is ongoing to find new efficient antigens. Innovative tools like bioinformatic analyses or epitope mapping have been developed and recent studies used chimeric antigens and multiepitope peptides for the diagnosis of acute and chronic infections [8, 10, 36]. Promising results in terms of sensitivity and specificity are available with these antigens, but more tests are needed to implement them in routine diagnostic practice [7, 20].

Since the selection of antigens for immunoassays remains an issue, the question becomes whether serological methods could be supplemented by other tests for the diagnosis of *Toxoplasma* infection. Humoral response of the host to the infection increases levels of circulating anti-*Toxoplasma* immunoglobulins. The different isotypes IgG, IgM, IgA, and IgE are currently used for diagnosis and estimation of the date of infection in serological tests [8, 38]. However, immune response to *T. gondii* is processed for a significant part by cell-mediated immunity [9, 12]. The first mechanism involved is a T-cell-independent response. *T. gondii* activates microbicidal functions of macrophages and synthesis of gamma interferon (IFN- $\gamma$ ) by natural killer cells [9]. The second mechanism involves interleukin-12 release by the macrophages, in response to the infection, to allow synthesis of IFN- $\gamma$  by *Toxoplasma*-specific CD4<sup>+</sup> and CD8<sup>+</sup> T-cells through a Th1 immune response [9, 12]. IFN- $\gamma$  is thus important to control parasite replication during the acute and chronic phases of the infection.

New tools based on cell-mediated immunity should be developed in order to be used in routine laboratories for the

diagnosis of *T. gondii* infection. First, fluorescence-activated cell sorting (FACS) methods have been developed to detect patient-specific T-cell activation in blood after *in vitro* incubation with *T. gondii* antigens [13, 23]. More recently, the *in vitro* IFN- $\gamma$  production of patient T lymphocytes after contact with *Toxoplasma* antigens has been assessed in a new test based on the principle of the IFN- $\gamma$  assay, well described for the diagnosis of tuberculosis [1, 2, 5]. These tests were first designed to improve the diagnosis of congenital toxoplasmosis in infants born to mothers who seroconverted during pregnancy. Serological diagnosis of such patients is difficult since maternal *Toxoplasma*-specific IgG can cross the placenta, whereas the *Toxoplasma* IFN- $\gamma$  assay allows for direct assessment of newborn cell-mediated immunity. In addition, this test also showed very good performances on adult patients [1].

Altogether, our work shows that the GRA8 and GRA7 proteins seem to be an avenue worth exploring to explain serological cross-reactivities. It highlights the importance of always confirming IgG positivity with at least another assay. False-positive samples cannot yet be avoided, even though they remain rare, and particular attention must be given to pregnant women with no proven past *T. gondii* infection. Serological tests have perhaps reached their limits and innovative tools such as cell-mediated immunity-based assays could become a valuable aid for toxoplasmosis diagnosis in the near future.

## Conflict of interest

The authors declare that Abbott Laboratories provided the *recomLine*<sup>®</sup> kits used to perform part of the analyses.

## Supplementary materials

Supplementary material is available at <https://www.parasite-journal.org/10.1051/parasite/2020006/olm>

*Supplementary Table 1.* Detailed results of all tests performed.

**Acknowledgements.** We would like to thank the private laboratories of Embrun, Lisieux, Miramas, Saint-Etienne-du-Rouvray, Saint-Laurent-du-Var, and Salon-de-Provence for sending us samples of interest for our study.

## References

- Chapey E, Wallon M, Debize G, Rabilloud M, Peyron F. 2010. Diagnosis of congenital toxoplasmosis by using a whole-blood gamma interferon release assay. *Journal of Clinical Microbiology*, 48, 41–45.
- Chapey E, Wallon M, L'Ollivier C, Piarroux R, Peyron F. 2015. Place of interferon- $\gamma$  assay for diagnosis of congenital toxoplasmosis. *Pediatric Infectious Disease Journal*, 34, 1407–1409.
- Christie E, Dubey JP. 1977. Cross-immunity between *Hammondia* and *Toxoplasma* infections in mice and hamsters. *Infection and Immunity*, 18, 412–415.
- Chuang Y-C, Chen J-Y, Ji D-D, Su P-H. 2012. Congenital toxoplasmosis in a neonate with significant neurologic manifestations. *Journal of the Formosan Medical Association*, 111, 232–233.
- Ciardelli L, Meroni V, Avanzini MA, Bollani L, Tinelli C, Garofoli F, Gasparoni A, Stronati M. 2008. Early and accurate diagnosis of congenital toxoplasmosis. *Pediatric Infectious Disease Journal*, 27, 125–129.
- Cook AJC, Gilbert RE, Buffolano W, Zufferey J, Petersen E, Jenun PA, Foulon W, Semprini AE, Dunn DT. 2000. Sources of *Toxoplasma* infection in pregnant women: European multicentre case-control study. *British Medical Journal*, 321, 142–147.
- Dai J, Jiang M, Wang Y, Qu L, Gong R, Si J. 2012. Evaluation of a recombinant multiepitope peptide for serodiagnosis of *Toxoplasma gondii* Infection. *Clinical and Vaccine Immunology: CVI*, 19, 338–342.
- Dard C, Fricker-Hidalgo H, Brenier-Pinchart M-P, Pelloux H. 2016. Relevance of and new developments in serology for Toxoplasmosis. *Trends in Parasitology*, 32, 492–506.
- Denkers EY, Gazzinelli RT. 1998. Regulation and function of T-cell-mediated immunity during *Toxoplasma gondii* infection. *Clinical Microbiology Reviews*, 11, 569–588.
- Döşkaya M, Liang L, Jain A, Can H, Gülçe İz S, Felgner PL, Değirmenci Döşkaya A, Davies DH, Gütüz AY. 2018. Discovery of new *Toxoplasma gondii* antigenic proteins using a high throughput protein microarray approach screening sera of murine model infected orally with oocysts and tissue cysts. *Parasites & Vectors*, 11, 393.
- Drapała D, Holec-Gaśior L, Kur J. 2015. New recombinant chimeric antigens, P35-MAG1, MIC1-ROPI1, and MAG1-ROPI1, for the serodiagnosis of human toxoplasmosis. *Diagnostic Microbiology and Infectious Disease*, 82, 34–39.
- Dupont CD, Christian DA, Selleck EM, Pepper M, Leney-Greene M, Harms Pritchard G, Koshy AA, Wagage S, Reuter MA, Sibley LD, Betts MR, Hunter CA. 2014. Parasite fate and involvement of infected cells in the induction of CD4+ and CD8+ T cell responses to *Toxoplasma gondii*. *PLoS Pathogens*, 10, e1004047.
- Fatoohi AF, Cozon GJN, Gonzalo P, Mayencon M, Greenland T, Picot S, Peyron F. 2004. Heterogeneity in cellular and humoral immune responses against *Toxoplasma gondii* antigen in humans. *Clinical and Experimental Immunology*, 136, 535–541.
- Franck J, Garin YJ-F, Dumon H. 2008. LDBio-Toxo II immunoglobulin G Western Blot confirmatory test for anti-*Toxoplasma* antibody detection. *Journal of Clinical Microbiology*, 46, 2334–2338.
- Frenkel JK, Dubey JP. 1975. *Hammondia hammondi* gen. nov., sp. nov., from domestic cats, a new coccidian related to *Toxoplasma* and *Sarcocystis*. *Zeitschrift für Parasitenkunde*, 46, 3–12.
- Frenkel JK, Dubey JP. 2000. The taxonomic importance of obligate heteroxeny: distinction of *Hammondia hammondi* from *Toxoplasma gondii* – another opinion. *Parasitology Research*, 86, 783–786.
- Gay-Andrieu F, Fricker-Hidalgo H, Sickinger E, Espern A, Brenier-Pinchart M-P, Braun H-B, Pelloux H. 2009. Comparative evaluation of the ARCHITECT Toxo IgG, IgM, and IgG Avidity assays for anti-*Toxoplasma* antibodies detection in pregnant women sera. *Diagnostic Microbiology and Infectious Disease*, 65, 279–287.
- Gazzonis AL, Zanzani SA, Santoro A, Veronesi F, Olivieri E, Villa L, Lubian E, Lovati S, Bottura F, Epis S, Manfredi MT. 2018. *Toxoplasma gondii* infection in raptors from Italy: seroepidemiology and risk factors analysis. *Comparative Immunology, Microbiology and Infectious Diseases*, 60, 42–45.
- Gondim LFP, Mineo JR, Schares G. 2017. Importance of serological cross-reactivity among *Toxoplasma gondii*, *Hammondia* spp., *Neospora* spp., *Sarcocystis* spp. and *Besnoitia besnoiti*. *Parasitology*, 144, 851–868.

20. Hajissa K, Zakaria R, Suppian R, Mohamed Z. 2017. An evaluation of a recombinant multiepitope based antigen for detection of *Toxoplasma gondii* specific antibodies. BMC Infectious Diseases, 17, 807.
21. Hiszczyńska-Sawicka E, Kur J, Pietkiewicz H, Holec-Gasior L, Gasior A, Myjak P. 2005. Efficient production of the *Toxoplasma gondii* GRA6, p35 and SAG2 recombinant antigens and their applications in the serodiagnosis of toxoplasmosis. Acta Parasitologica, 50, 249–254.
22. Jones JL, Dubey JP. 2012. Foodborne toxoplasmosis. Clinical Infectious Diseases, 55, 845–851.
23. Kahi S, Cozon GJ, Peyron F. 1999. Early detection of cellular immunity in congenitally *Toxoplasma gondii*-infected children. Pediatric Infectious Disease Journal, 18, 846–847.
24. Khan K, Khan W. 2018. Congenital toxoplasmosis: an overview of the neurological and ocular manifestations. Parasitology International, 67, 715–721.
25. Khurana S, Batra N. 2016. Toxoplasmosis in organ transplant recipients: evaluation, implication, and prevention. Tropical Parasitology, 6, 123–128.
26. Laforet CK, Deksne G, Petersen HH, Jokelainen P, Johansen MV, Lassen B. 2019. *Toxoplasma gondii* seroprevalence in extensively farmed wild boars (*Sus scrofa*) in Denmark. Acta Veterinaria Scandinavica, 61, 4.
27. Lee S-B, Lee T-G. 2017. Toxoplasmic encephalitis in patient with acquired immunodeficiency syndrome. Brain Tumor Research and Treatment, 5, 34–36.
28. Liao M, Xuan X, Huang X, Shirafuji H, Fukumoto S, Hirata H, Suzuki H, Fujisaki K. 2005. Identification and characterization of cross-reactive antigens from *Neospora caninum* and *Toxoplasma gondii*. Parasitology, 130, 481–488.
29. Mahinc C, Flori P, Delaunay E, Guillerme C, Charaoui S, Raberin H, Hafid J, L'Ollivier C. 2017. Evaluation of a new immunochromatography technology test (LDBio diagnostics) to detect *Toxoplasma* IgG and IgM: comparison with the routine architect technique. Journal of Clinical Microbiology, 55, 3395–3404.
30. Meng Q-F, Li D, Yao G-Z, Zou Y, Cong W, Shan X-F. 2018. Seroprevalence of *Toxoplasma gondii* infection and variables associated with seropositivity in donkeys in eastern China. Parasite, 25, 66.
31. Munday BL, Dubey JP. 1988. Prevention of *Toxoplasma gondii* abortion in goats by vaccination with oocysts of *Hammondia hammondi*. Australian Veterinary Journal, 65, 150–153.
32. Murat J-B, Dard C, Fricker Hidalgo H, Dardé M-L, Brenier-Pinchart M-P, Pelloux H. 2013. Comparison of the Vidas system and two recent fully automated assays for diagnosis and follow-up of toxoplasmosis in pregnant women and newborns. Clinical and Vaccine Immunology, 20, 1203–1212.
33. Pomares C, Montoya JG. 2016. Laboratory diagnosis of congenital toxoplasmosis. Journal of Clinical Microbiology, 54, 2448–2454.
34. Prusa A-R, Kasper DC, Sawers L, Walter E, Hayde M, Stillwaggon E. 2017. Congenital toxoplasmosis in Austria: prenatal screening for prevention is cost-saving. PLoS Neglected Tropical Diseases, 11, e0005648.
35. Riahi H, Bouteille B, Darde ML. 1998. Antigenic similarity between *Hammondia hammondi* and *Toxoplasma gondii* tachyzoites. Journal of Parasitology, 84, 651–653.
36. Rostami A, Karanis P, Fallahi S. 2018. Advances in serological, imaging techniques and molecular diagnosis of *Toxoplasma gondii* infection. Infection, 46, 303–315.
37. Sickinger E, Gay-Andrieu F, Jonas G, Schultess J, Stieler M, Smith D, Hausmann M, Stricker R, Stricker R, Dhein J, Braun H-B. 2008. Performance characteristics of the new ARCHITECT Toxo IgG and Toxo IgG Avidity assays. Diagnostic Microbiology and Infectious Disease, 62, 235–244.
38. Smets A, Fauchier T, Michel G, Marty P, Pomares C. 2016. Comparison of *Toxoplasma gondii* IgG avidity Architect and Vidas assays with the estimated date of infection in pregnant women. Parasite, 23, 45.
39. Sohn CS, Cheng TT, Drummond ML, Peng ED, Vermont SJ, Xia D, Cheng SJ, Wastling JM, Bradley PJ. 2011. Identification of novel proteins in *Neospora caninum* using an organelle purification and monoclonal antibody approach. PloS One, 6, e18383.
40. Sonnevile R, Magalhaes E, Meyfroidt G. 2017. Central nervous system infections in immunocompromised patients. Current Opinion in Critical Care, 23, 128–133.
41. Villagra-Blanco R, Barrantes-Granados O, Montero-Caballero D, Romero-Zúñiga JJ, Dolz G. 2019. Seroprevalence of *Toxoplasma gondii* and *Neospora caninum* infections and associated factors in sheep from Costa Rica. Parasite Epidemiology and Control, 4, e00085.
42. Villard O, Cimon B, L'Ollivier C, Fricker-Hidalgo H, Godineau N, Houze S, Paris L, Pelloux H, Villena I, Candolfi E. 2016. Help in the choice of automated or semiautomated immunoassays for serological diagnosis of toxoplasmosis: evaluation of nine immunoassays by the french national reference center for toxoplasmosis. Journal of Clinical Microbiology, 54, 3034–3042.
43. Wallon M, Peyron F, Cornu C, Vinault S, Abrahamowicz M, Kopp CB, Binquet C. 2013. Congenital *Toxoplasma infection*: monthly prenatal screening decreases transmission rate and improves clinical outcome at age 3 years. Clinical Infectious Diseases, 56, 1223–1231.
44. Wallon M, Garweg JG, Abrahamowicz M, Cornu C, Vinault S, Quantin C, Bonithon-Kopp C, Picot S, Peyron F, Binquet C. 2014. Ophthalmic outcomes of congenital toxoplasmosis followed until adolescence. Pediatrics, 133, e601–608.
45. Walzer KA, Adomako-Ankomah Y, Dam RA, Herrmann DC, Schares G, Dubey JP, Boyle JP. 2013. *Hammondia hammondi*, an avirulent relative of *Toxoplasma gondii*, has functional orthologs of known *T. gondii* virulence genes. Proceedings of the National Academy of Sciences of the United States of America, 110, 7446–7451.
46. Wang X, Qin S-Y, Liu Z-L, Zhang X-T, Cui D-Y, Li J-H, Liu Y, Zhao Q, Ni H-B. 2019. Seroprevalence and risk factors of *Toxoplasma gondii* infection in domestic raccoon dogs in four provinces in northern China. Microbial Pathogenesis, 128, 136–138.
47. Zhang X-X, Qin S-Y, Li X, Ren W-X, Hou G, Zhao Q, Ni H-B. 2018. Seroprevalence and related factors of *Toxoplasma gondii* in pigeons intended for human consumption in Northern China. Vector Borne and Zoonotic Diseases, 19, 302–305.
48. Zhou Q, Wang Q, Shen H, Zhang Y, Zhang S, Li X, Acharya G. 2018. Seroepidemiological map of *Toxoplasma gondii* infection and associated risk factors in preconception period in China: a nationwide cross-sectional study. Journal of Obstetrics and Gynaecology Research, 44, 1134–1139.



Director's cut

**D**ans l'attente de nouvelles méthodes de diagnostic immunologique, la sérologie reste actuellement le principal outil nous permettant de connaître le statut immunitaire d'une femme enceinte vis-à-vis de la toxoplasmose.

Les dangers d'une infection acquise en cours de grossesse sont aujourd'hui bien connus, mais l'on connaît moins les risques encourus lorsque l'infection maternelle a lieu dans les mois qui précèdent la conception. En complément de l'étude réalisée sur les IgG faux positifs, le cas clinique rapporté ci-après, en cours de soumission pour publication, nous montre qu'une primo-infection à *T. gondii* plusieurs mois avant la grossesse peut être responsable d'une mort fœtale *in utero*. Cet évènement, survenu chez une personne immunocompétente, met en lumière les possibilités d'amélioration de prise en charge des cas similaires et l'attention particulière qui devrait leur être accordée.



**Congenital toxoplasmosis: the maternal infection may occur  
several months before conception.**

Loïc Simon<sup>1,2</sup>, Cynthia Trastour<sup>3</sup>, Albert Soler<sup>4</sup>, Fabienne Jeannet<sup>5</sup>, Pierre Marty<sup>1,2</sup>, Christelle Pomares<sup>1,2</sup>.

1- Service de Parasitologie-Mycoologie, CHU de Nice, Université Côte d'Azur, Nice, France

2- Inserm U1065, C3M, Nice, France

3- Service de Gynécologie-Obstétrique, CHU de Nice, Nice, France

4- Polyclinique Saint-Jean, Cagnes-sur-Mer, France

5- Médecine générale, Saint-Laurent-Du-Var, France

Corresponding author:

Loïc Simon (email: [simon.l@chu-nice.fr](mailto:simon.l@chu-nice.fr), tel: +33 (0)4 92 03 62 54)

Service de Parasitologie-Mycoologie, CHU de Nice - Hôpital l'Archet, 151 route Saint-Antoine de Ginestière, CS 23079, 06202 Nice cedex 3, France.

Short title: Maternal toxoplasmosis before conception

Presentation at meetings:

Poster - European Congress of Clinical Microbiology and Infectious Diseases 2019, Amsterdam, Netherlands.

Poster - Congress of the French Society of Parasitology 2019, Tours, France.

Oral communication - International Congress On Congenital Toxoplasmosis 2019, Matera, Italy.

Keywords: *Toxoplasma gondii*, congenital toxoplasmosis, preconception, miscarriage, fetal death.

## Abstract

**Background:** We report a case of fatal congenital toxoplasmosis with maternal infection dated four months before pregnancy in the absence of any specific immunosuppressive condition.

**Case:** Ms. D. experienced submaxillary lymphadenitis in February 2018. The medical workup performed revealed an acute *T. gondii* infection. She became pregnant in June 2018 while she still had adenopathy. The second obstetrical ultrasound, performed at 16 weeks of pregnancy, revealed a fetal death. The research for *T. gondii* by PCR was positive in the products of curettage.

**Conclusion:** Diagnosis of toxoplasmosis should be discussed in case of miscarriage with lymphadenitis. As lymph nodes in *T. gondii* infection could be responsible for iterative release of parasites and fetal death, symptomatic toxoplasmosis should be treated in women of childbearing age.

## Introduction

The intracellular parasite *Toxoplasma gondii* is responsible for benign toxoplasmosis in immunocompetent population. In about 80% of cases, *T. gondii* primary infection is asymptomatic in healthy people. Sometimes, mild symptoms can nonetheless appear like asthenia, cervical lymphadenitis, moderate fever and biological mononucleosis syndrome. Children are at risk of congenital toxoplasmosis when the infection occurs during pregnancy. The tachyzoite form of the parasite can then be transmitted to the fetus by random breaks from placental foci. The risk of transmission is considered low when the maternal infection occurs at the beginning of pregnancy but it increases up to 70% at the end of pregnancy<sup>1</sup>. Conversely, severity of congenital infection is higher at the beginning compared to the end of pregnancy. Few congenital infections were described when women were infected before the date of conception. In the majority of cases, these infections can be explained by reactivation of a past infection during pregnancy in immunocompromised mothers<sup>2</sup>. Here, we report a case of fatal congenital toxoplasmosis with maternal infection dated four months before pregnancy in the absence of any specific immunosuppressive condition.

## Case

Ms. D., a 28-year-old woman in good health and without any known immunosuppression, experienced mid-February 2018 submaxillary lymphadenitis associated with asthenia, without any other symptom. She consulted general physicians and ENT specialists during the following weeks as the lymphadenitis was still present. Her medical history was without particularity and there was no history of travel abroad. She has one child in good health from a first pregnancy, born from vaginal delivery in October 2017. Cervical ultrasound exam and blood tests were performed. Submaxillary lymphadenitis was confirmed by ultrasound and the biological workup did not show any sign of immunosuppression. The cytomegalovirus, Epstein-Barr Virus, Hepatitis B and C Virus, and HIV serological tests results were negative and rubella serology showed an immunization profile. The *T. gondii* serology performed the 4<sup>th</sup> of April was in favor of an acute infection dated beginning of February with presence of specific IgG, IgM and IgA, associated with low IgG avidity (**Table 1**). The last known negative *T. gondii* serology dated November 29, 2017. An ophthalmologic exam did not reveal any abnormality and no treatment was prescribed at that time.

Few months later, Ms. D. became pregnant. The first fetal ultrasound performed on August 17 during the first trimester (12 weeks of pregnancy) was normal and the estimated date of conception was June 05, 2018. The ultrasound measurements were then: crown-rump length=63.8 mm, biparietal diameter=21.6 mm, head circumference=77 mm, abdominal circumference=64 mm, femur length=7.7 mm, nuchal translucency=2.2 mm. On September 12, at 16 weeks of pregnancy, a second obstetrical ultrasound highlighted fetal death that probably occurred few days after the first ultrasound according to the obstetrical measurements. Uterine curettage was performed the next day at the teaching hospital of Nice, France. Analysis of the products of curettage by the laboratory of Parasitology-Mycology revealed a positive *T. gondii* PCR. Genotyping performed on the PCR products by the National Reference Center for Toxoplasmosis, based in Limoges, found a Type II *T. gondii* strain. Type II strains represent 95% of the circulating strains in France. *Toxoplasma gondii* PCR performed on the peripheral blood of Ms. D. was negative. The **Figure 1** summarizes the timeline of the events.

After a quick investigation, we learned that the submaxillary lymphadenitis was still present when Ms. D. became pregnant and during the pregnancy. To date, Ms. D. is doing well. She became pregnant again on April 2019 and gave birth to a healthy baby boy on December 31.

## Discussion

In some countries like France, pregnant women are tested in the early weeks of gestation for the presence of specific IgG and IgM against *T. gondii*. When the first serology is negative, a monthly prenatal screening is performed. This approach allows prompt initiation of treatment of the mothers who seroconvert and of infected fetuses along with being cost-effective<sup>1</sup>. In our case, *T. gondii* infection, proven by the association of symptomatology and specific serology, occurred four months before conception and there should have been no consequences on the pregnancy. *Toxoplasma gondii* was transmitted to the fetus long after the estimated date of infection. Similar cases are rare in the literature and to our knowledge, this is the first description of proven fetus infection with such a long period of time between mother infection and conception<sup>2-8</sup>. The presence of enlarged cervical lymph nodes seems to be the common feature in similar situations of pregnant women without immunosuppressive pathology<sup>2,3,6-8</sup>. We might wonder if an iterative release of parasites from the lymph nodes may have been responsible, in our case and the others, for fetus infection. Moreover, when primary infection is symptomatic, there could be a prolonged parasitemia, promoting transmission to the fetus.

Our patient was not treated at the time of diagnostic but treatment with spiramycin before conception have been performed in other cases and failed to prevent infection of the fetus<sup>2-4,7</sup>. Currently, there are no official recommendations about the preconceptional toxoplasmosis care.

We agree with Villena *et al.* on advocating a pregnancy-free interval of at least six months after proven toxoplasmosis infection<sup>3</sup>. In addition, specific monitoring, by regular ultrasound and prenatal diagnosis, in pregnant immune women with adenopathy should be recommended.

Effective treatment of symptomatic toxoplasmosis in women with a desire for pregnancy could be advisable too. Treatment strategy with trimethoprim-sulfamethoxazole (already used for *T. gondii* infection in immunocompromised patients) could be a good alternative to spiramycin. A double-blind, randomized clinical trial by Alavi *et al.* showed the benefits of a treatment by trimethoprim-sulfamethoxazole (= cotrimoxazole) at 48 mg/kg/day for 1 month on the healing of lymphadenitis and the decrease of anti-*T. gondii* IgM level<sup>9</sup>. Moreover, it is also important to encourage practitioners to examine women with miscarriage for the presence of enlarged lymph nodes. In case of lymphadenitis, the diagnosis of toxoplasmosis should be discussed.

The role of *T. gondii* in unexplained miscarriages has been rarely assessed and is probably underestimated. According to the review by Giakoumelou *et al.*, the link between miscarriages

and congenital toxoplasmosis was poorly studied<sup>10</sup>. In this review, the study populations ranged from 100 to 326 women with a history of miscarriage. The analyses performed were often limited to serological tests or *T. gondii* PCR in mothers' blood and these assays are not those which make it possible to diagnose a congenital toxoplasmosis. Prevalence of toxoplasmosis ranges from 20% to 70% worldwide and more powerful studies about the potential role of *T. gondii* in miscarriages are needed to better prevent fetus infection.

This case report highlights the fact that a symptomatic acute infection by *T. gondii* should be considered differently than an asymptomatic one. A period of six months should be considered between the symptomatic infection and the pregnancy, in order to prevent miscarriage due to *T. gondii*.

### Teaching points

- Symptomatic toxoplasmosis in women of childbearing age should be treated.
- *T. gondii* primary infection should be sought in women with miscarriage and lymphadenitis.
- Pregnancy should be delayed in case of proven acute toxoplasmosis in the past six months.

## Table

**Table 1.** Biological results

Assay performed	04/04/2018	08/18/2018	09/07/2018	09/13/2018	09/24/2018	11/14/2018
IgG (IU/mL)	194,9	732,3	1362,3	n/a	1350,9	1096,2
IgG avidity	5,04%	38,10%	n/a	n/a	n/a	n/a
IgM (index)	15,38	4,74	3,04	n/a	3,87	5,01
IgA (index)	4,2	3	n/a	n/a	n/a	n/a
PCR (curettage products)	n/a	n/a	n/a	Positive	n/a	n/a
PCR (Ms. D's blood)	n/a	n/a	n/a	n/a	Negative	n/a

**IgG** (Architect®, Abbott Laboratories): negative < 1.6 ; equivocal 1.6 - 2.9 ; positive ≥ 3

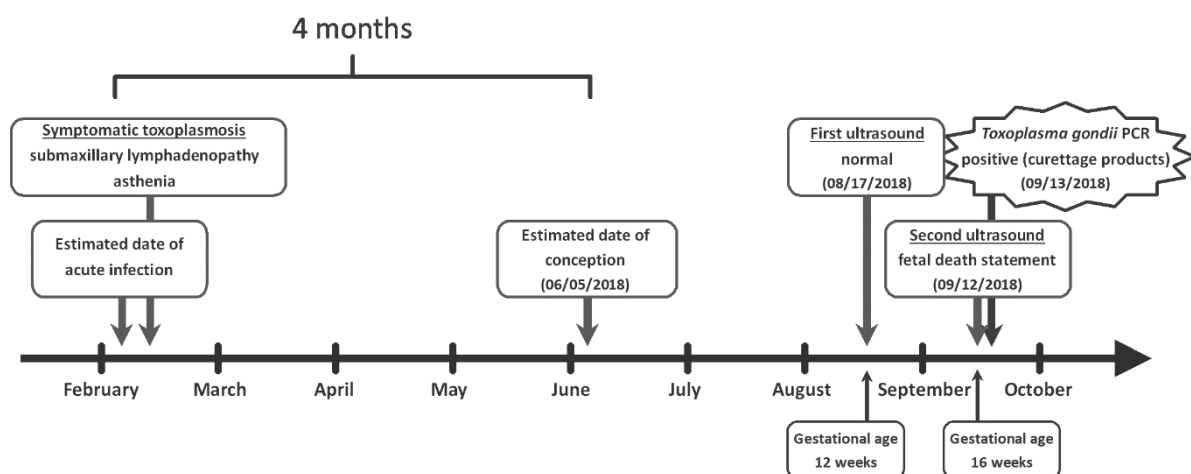
**IgG avidity** (Architect®, Abbott Laboratories): ≥ 60% → past infection > 4 months ago

**IgM** (Architect®, Abbott Laboratories): negative < 0.50 ; equivocal 0.50 - 0.59 ; positive ≥ 0.60

**IgA** (Platelia™, Bio-Rad): negative < 0.8 ; equivocal 0.8 - 1 ; positive ≥ 1

**n/a**: not available

## Figure



**Figure 1:** Timeline of the events



## References

1. Wallon M, Peyron F, Cornu C, Vinault S, Abrahamowicz M, Kopp CB, et al. Congenital *Toxoplasma* Infection: Monthly Prenatal Screening Decreases Transmission Rate and Improves Clinical Outcome at Age 3 Years. *Clin Infect Dis*. 2013;56(9):1223-1231. doi:10.1093/cid/cit032.
2. Marty P, Bongain A, Rahal A, Thulliez P, Wasfi D, Lambert JC, et al. Prenatal diagnosis of severe fetal toxoplasmosis as a result of toxoplasmic reactivation in an HIV-1 seropositive woman. *Prenat Diagn*. 1994;14(5):414-415. doi:10.1002/pd.1970140514.
3. Villena I, Chemla C, Quereux C, Dupouy D, Leroux B, Foudrinier F, et al. Prenatal diagnosis of congenital toxoplasmosis transmitted by an immunocompetent woman infected before conception. Reims Toxoplasmosis Group. *Prenatal diagnosis*. 1998;18:1079-1081. doi:10.1002/(SICI)1097-0223(1998100)18:103.3.CO;2-5.
4. Dollfus H, Dureau P, Hennequin C, Uteza Y, Bron A, Dufier JL. Congenital *toxoplasma* chorioretinitis transmitted by preconceptionally immune women. *Br J Ophthalmol*. 1998;82(12):1444-1445. doi:10.1136/bjo.82.12.1444.
5. Pons JC, Sigrand C, Grangeot-Keros L, Frydman R, Thulliez P. [Congenital toxoplasmosis: transmission to the fetus of a pre-pregnancy maternal infection]. *Presse Med*. 1995;24(3):179-182.
6. Desmonts G, Couvreur J, Thulliez P. [Congenital toxoplasmosis. 5 cases of mother-to-child transmission of pre-pregnancy infection]. *Presse Med*. 1990;19(31):1445-1449.
7. Boumahni B, Randrianivo H, Flodrops H, Kauffmann E, Sauve F, Chauvet O, et al. [Maternal toxoplasmosis before conception and chorioretinitis in twin sisters]. *J Gynecol Obstet Biol Reprod (Paris)*. 2004;33(3):248-250. doi:10.1016/s0368-2315(04)96447-2.
8. Vogel N, Kirisits M, Michael E, Bach H, Hostetter M, Boyer K, et al. Congenital toxoplasmosis transmitted from an immunologically competent mother infected before conception. *Clin Infect Dis*. 1996;23(5):1055-1060. doi:10.1093/clinids/23.5.1055.
9. Alavi SM, Alavi L. Treatment of toxoplasmic lymphadenitis with co-trimoxazole: double-blind, randomized clinical trial. *Int J Infect Dis*. 2010;14 Suppl 3:e67-69. doi:10.1016/j.ijid.2009.11.015.
10. Giakoumelou S, Wheelhouse N, Cuschieri K, Entrican G, Howie SEM, Horne AW. The role of infection in miscarriage. *Hum Reprod Update*. 2016;22(1):116-133. doi:10.1093/humupd/dmv041.

# Credits

# SEROLOGICAL DIAGNOSIS OF *TOXOPLASMA GONDII*: ANALYSIS OF FALSE-POSITIVE IGG RESULTS AND IMPLICATIONS

## DIRECTED BY

Christelle Pomares

## CAST

### in order of appearance

Serum #1 Ms. T.  
Serum #2 Ms. H.  
Serum #3 Ms. E.<sub>1</sub>  
... ..  
Serum #188 Ms. E.<sub>2</sub>  
Serum #189 Ms. N.  
Guest Ms. D.

*Executive Producers* Loïc Simon  
Christelle Pomares  
Pierre Marty

*Script writers* Loïc Simon  
Christelle Pomares

*Graphics* Loïc Simon

*Editor* Loïc Simon

*Associate Producers* Judith Fillaux  
Aurélie Guigon  
Rose-Anne Lavergne  
Odile Villard  
Isabelle Villena  
*Toxoplasma* p35 Study Group  
Cynthia Trastour  
Albert Soler  
Fabienne Jeannet

Based upon the book “Thesis Charter”  
by The Nice school of Medicine