



HAL
open science

Six months results on efficacy, safety, and optical coherence tomography monitoring of the bleb, following Preserflo MicroShunt™ implantation

Kévin Allaix

► **To cite this version:**

Kévin Allaix. Six months results on efficacy, safety, and optical coherence tomography monitoring of the bleb, following Preserflo MicroShunt™ implantation. Human health and pathology. 2020. dumas-03369847

HAL Id: dumas-03369847

<https://dumas.ccsd.cnrs.fr/dumas-03369847>

Submitted on 7 Oct 2021

HAL is a multi-disciplinary open access archive for the deposit and dissemination of scientific research documents, whether they are published or not. The documents may come from teaching and research institutions in France or abroad, or from public or private research centers.

L'archive ouverte pluridisciplinaire **HAL**, est destinée au dépôt et à la diffusion de documents scientifiques de niveau recherche, publiés ou non, émanant des établissements d'enseignement et de recherche français ou étrangers, des laboratoires publics ou privés.

AVERTISSEMENT

Ce document est le fruit d'un long travail approuvé par le jury de soutenance.

La propriété intellectuelle du document reste entièrement celle du ou des auteurs. Les utilisateurs doivent respecter le droit d'auteur selon la législation en vigueur, et sont soumis aux règles habituelles du bon usage, comme pour les publications sur papier : respect des travaux originaux, citation, interdiction du pillage intellectuel, etc.

Il est mis à disposition de toute personne intéressée par l'intermédiaire de [l'archive ouverte DUMAS](#) (Dépôt Universitaire de Mémoires Après Soutenance).

Si vous désirez contacter son ou ses auteurs, nous vous invitons à consulter la page de DUMAS présentant le document. Si l'auteur l'a autorisé, son adresse mail apparaîtra lorsque vous cliquerez sur le bouton « Détails » (à droite du nom).

Dans le cas contraire, vous pouvez consulter en ligne les annuaires de l'ordre des médecins, des pharmaciens et des sages-femmes.

Contact à la Bibliothèque universitaire de Médecine
Pharmacie de Grenoble :
bump-theses@univ-grenoble-alpes.fr

Année : 2020

**SIX MONTHS RESULTS ON EFFICACY, SAFETY, AND OPTICAL COHERENCE
TOMOGRAPHY MONITORING OF THE BLEB, FOLLOWING
PRESERFLO MICROSHUNT™ IMPLANTATION**

THÈSE
PRÉSENTÉE POUR L'OBTENTION DU TITRE DE DOCTEUR EN MÉDECINE
DIPLÔME D'ÉTAT

M. ALLAIX Kévin

[Données à caractère personnel]

THÈSE SOUTENUE PUBLIQUEMENT À LA FACULTÉ DE MÉDECINE DE
GRENOBLE

Le 02/10/2020

DEVANT LE JURY COMPOSÉ DE

Président du jury :

M. le Professeur Christophe CHIQUET

Membres :

M. le Professeur Florent APTEL (directeur de thèse)

M. le Professeur Philippe GAIN

L'UFR de Médecine de Grenoble n'entend donner aucune approbation ni improbation aux opinions émises dans les thèses ; ces opinions sont considérées comme propres à leurs auteurs.

Doyen de la Faculté : Pr. Patrice MORAND

Année 2020-2021

ENSEIGNANTS DE L'UFR DE MEDECINE

CORPS	NOM-PRENOM	Discipline universitaire
PU-PH	ALBALADEJO Pierre	Anesthésiologie-réanimation et médecine péri-opératoire
PU-PH	APTEL Florent	Ophthalmologie
PU-PH	ARVIEUX-BARTHELEMY Catherine	Chirurgie viscérale et digestive
PU-PH	BAILLET Athan	Rhumatologie
PU-PH	BARONE-ROCHETTE Gilles	Cardiologie
PU-PH	BAYAT Sam	Physiologie
MCF Ass.MG	BENDAMENE Farouk	Médecine Générale
PU-PH	BENHAMOU Pierre-Yves	Endocrinologie, diabète et maladies métaboliques
PU-PH	BERGER François	Biologie cellulaire
MCU-PH	BIDART-COUTTON Marie	Biologie cellulaire
PU-PH	BLAISE Sophie	Chirurgie vasculaire ; médecine vasculaire
PR Ass. Méd.	BOILLOT Bernard	
MCU-PH	BOISSET Sandrine	Bactériologie-virologie ; Hygiène hospitalière
PU-PH	BONAZ Bruno	Gastroentérologie ; hépatologie ; addictologie
PU-PH	BONNETERRE Vincent	Médecine et santé au travail
PU-PH	BOREL Anne-Laure	Nutrition
PU-PH	BOSSON Jean-Luc	Biostatistiques, informatique médicale et technologies de communication
MCU-PH	BOTTARI Serge	Biologie cellulaire
PR Ass.MG	BOUCHAUD Jacques	Médecine Générale
PU-PH	BOUGEROL Thierry	Psychiatrie d'adultes
PU-PH	BOUILLET Laurence	Médecine interne ; gériatrie et biologie du vieillissement ; addictologie
MCU-PH	BOUSSAT Bastien	Epidémiologie, économie de la santé et prévention
PU-PH	BOUZAT Pierre	Anesthésiologie-réanimation et médecine péri-opératoire
PU-PH émérite	BRAMBILLA Christian	Pneumologie
PU-PH émérite	BRAMBILLA Elisabeth	Anatomie et cytologie pathologiques
MCU-PH	BRENIER-PINCHART Marie Pierre	Parasitologie et mycologie
PU-PH	BRICAULT Ivan	Radiologie et imagerie médicale
PU-PH	BRICHON Pierre-Yves	Chirurgie thoracique et cardiovasculaire
MCU-PH	BRIOT Raphaël	Thérapeutique-médecine de la douleur ; Addictologie
PU-PH émérite	CAHN Jean-Yves	Hématologie
PU-PH émérite	CARPENTIER Patrick	Chirurgie vasculaire, médecine vasculaire
PR Ass.MG	CARRILLO Yannick	Médecine Générale
PU-PH	CESBRON Jean-Yves	Immunologie
PU-PH	CHABARDES Stephan	Neurochirurgie
PU-PH	CHABRE Olivier	Endocrinologie, diabète et maladies métaboliques
PU-PH	CHAFFANJON Philippe	Anatomie
MCF Ass.MG	CHAMBOREDON Benoît	Médecine Générale
PU-PH	CHARLES Julie	Dermato-vénérologie
MCF Ass.MG	CHAVVET Marion	Médecine Générale
PU-PH	CHAVANON Olivier	Chirurgie thoracique et cardiovasculaire

CORPS	NOM-PRENOM	Discipline universitaire
PU-PH	CHIQUET Christophe	Ophthalmologie
PU-PH	CHIRICA Mircea	Chirurgie viscérale et digestive
PU-PH	CINQUIN Philippe	Biostatistiques, informatique médicale et technologies de communication
MCU-PH	CLAVARINO Giovanna	Immunologie
PU-PH	COHEN Olivier	Histologie, embryologie et cytogénétique
PU-PH	COURVOISIER Aurélien	Chirurgie infantile
PU-PH	COUTTON Charles	Génétique
PU-PH	COUTURIER Pascal	Médecine interne ; gériatrie et biologie du vieillissement ; addictologie
PU-PH	CRACOWSKI Jean-Luc	Pharmacologie fondamentale ; pharmacologie clinique ; addictologie
PU-PH	DEBATY Guillaume	Médecine d'Urgence
PU-PH	DEBILLON Thierry	Pédiatrie
PU-PH	DECAENS Thomas	Gastroentérologie ; hépatologie ; addictologie
PR Ass. Méd.	DEFAYE Pascal	Cardiologie
PU-PH	DEGANO Bruno	Pneumologie ; addictologie
PU-PH	DEMATTEIS Maurice	Pharmacologie fondamentale ; pharmacologie clinique ; addictologie
PU-PH émérite	DEMONGEOT Jacques	Biostatistiques, informatique médicale et technologies de communication
MCU-PH	DERANSART Colin	Physiologie
PU-PH	DESCOTES Jean-Luc	Urologie
PU-PH	DETANTE Olivier	Neurologie
MCU-PH	DIETERICH Klaus	Génétique
MCU-PH	DOUTRELEAU Stéphane	Physiologie
MCU-PH	DUMESTRE-PERARD Chantal	Immunologie
PU-PH	EPAULARD Olivier	Maladies infectieuses ; Maladies tropicales
PU-PH	ESTEVE François	Biophysique et médecine nucléaire
MCU-PH	EYSSERIC Héliène	Médecine légale et droit de la santé
PU-PH	FAUCHERON Jean-Luc	Chirurgie viscérale et digestive
MCU-PH	FAURE Julien	Biochimie et biologie moléculaire
PU-PH	FERRETTI Gilbert	Radiologie et imagerie médicale
PU-PH	FEUERSTEIN Claude	Physiologie
PU-PH	FONTAINE Éric	Nutrition
PU-PH	FRANCOIS Patrice	Epidémiologie, économie de la santé et prévention
MCU-MG	GABOREAU Yoann	Médecine Générale
PU-PH	GARBAN Frédéric	Hématologie ; Transfusion
PU-PH	GAUDIN Philippe	Rhumatologie
PU-PH	GAVAZZI Gaëtan	Médecine interne ; gériatrie et biologie du vieillissement ; addictologie
PU-PH	GAY Emmanuel	Neurochirurgie
MCU-PH	GILLOIS Pierre	Biostatistiques, informatique médicale et technologies de communication
PU-PH	GIOT Jean-Philippe	Chirurgie plastique, reconstructrice et esthétique ; Brûlologie
MCU-PH	GRAND Sylvie	Radiologie et imagerie médicale
PU-PH émérite	GRIFFET Jacques	Chirurgie infantile
MCU-PH	GUZUN Rita	Nutrition
PU-PH	HAINAUT Pierre	Biochimie et biologie moléculaire
PU-PH émérite	HALIMI Serge	Nutrition
PU-PH	HENNEBICQ Sylviane	Biologie et médecine du développement et de la reproduction ; gynécologie médicale
PU-PH	HOFFMANN Pascale	Gynécologie-obstétrique ; gynécologie médicale
PU-PH émérite	HOMMEL Marc	Neurologie
PU-MG	IMBERT Patrick	Médecine Générale

CORPS	NOM-PRENOM	Discipline universitaire
PU-PH émérite	JOUK Pierre-Simon	Génétique
PU-PH	KAHANE Philippe	Physiologie
MCU-PH	KASTLER Adrian	Radiologie et imagerie médicale
PU-PH	KRAINIK Alexandre	Radiologie et imagerie médicale
PU-PH	LABARERE José	Epidémiologie, économie de la santé et prévention
MCU-PH	LABLANCHE Sandrine	Endocrinologie, diabète et maladies métaboliques
MCU-PH	LANDELLE Caroline	Bactériologie – virologie ; Hygiène hospitalière
PU-PH	LANTUEJOL Sylvie	Anatomie et cytologie pathologiques
PR Ass. Méd.	LARAMAS Mathieu	Cancérologie ; radiothérapie
MCU-PH	LARDY Bernard	Biochimie et biologie moléculaire
MCU - PH	LE GOUELLEC LE PISSART Audrey	Biochimie et biologie moléculaire
PU-PH	LECCIA Marie-Thérèse	Dermato-vénérologie
MCF Ass.MG	LEDOUX Jean-Nicolas	Médecine Générale
PU-PH émérite	LETOUBLON Christian	Chirurgie viscérale et digestive
PU-PH	LEVY Patrick	Physiologie
PU-PH	LONG Jean-Alexandre	Urologie
MCU-PH	LUPO Julien	Bactériologie-virologie ; Hygiène hospitalière
PU-PH	MAIGNAN Maxime	Médecine d'urgence
PU-PH	MAITRE Anne	Médecine et santé au travail
MCU-PH	MALLARET Marie-Reine	Bactériologie – virologie ; Hygiène hospitalière
MCU-PH	MARLU Raphaël	Hématologie ; Transfusion
PR Ass. Méd.	MATHIEU Nicolas	Gastroentérologie ; hépatologie ; addictologie
MCU-PH	MAUBON Danièle	Parasitologie et mycologie
PU-PH	MAURIN Max	Bactériologie-virologie ; Hygiène hospitalière
MCU-PH	MC LEER Anne	Histologie, embryologie et cytogénétique
MCU-PH	MONDET Julie	Histologie, embryologie et cytogénétique
PU-PH	MORAND Patrice	Bactériologie-virologie ; Hygiène hospitalière
PU-PH	MOREAU-GAUDRY Alexandre	Biostatistiques, informatique médicale et technologies de communication
PU-PH	MORO Elena	Neurologie
PU-PH	MORO-SIBILOT Denis	Pneumologie ; addictologie
MCU-PH	MORTAMET Guillaume	Pédiatrie
PU-PH	MOUSSEAU Mireille	Cancérologie ; radiothérapie
PU-PH émérite	MOUTET François	Chirurgie plastique, reconstructrice et esthétique ; brûlologie
MCF Ass.MG	ODDOU Christel	Médecine Générale
PR Ass. Méd.	ORMEZANO Olivier	Cardiologie
MCU-PH	PACLET Marie-Hélène	Biochimie et biologie moléculaire
PU-PH	PAILHE Régis	Chirurgie orthopédique et traumatologie
PU-PH	PALOMBI Olivier	Anatomie
PU-PH	PARK Sophie	Hématologie ; Transfusion
PU-PH	PASSAGGIA Jean-Guy	Anatomie
PR Ass.MG	PAUMIER-DESBRIERES Françoise	Médecine Générale
PU-PH	PAYEN DE LA GARANDERIE Jean-François	Anesthésiologie-réanimation et médecine péri-opératoire
MCU-PH	PAYSANT François	Médecine légale et droit de la santé
MCU-PH	PELLETIER Laurent	Biologie cellulaire
PU-PH	PELLOUX Hervé	Parasitologie et mycologie
PU-PH	PEPIN Jean-Louis	Physiologie
PU-PH	PERENNOU Dominique	Médecine physique et de réadaptation

CORPS	NOM-PRENOM	Discipline universitaire
PU-PH	PERNOD Gilles	Chirurgie vasculaire ; Médecine vasculaire
PU-PH	PIOLAT Christian	Chirurgie infantile
PU-PH	PISON Christophe	Pneumologie ; Addictologie
PU-PH	PLANTAZ Dominique	Pédiatrie
PU-PH	POIGNARD Pascal	Bactériologie-virologie ; Hygiène hospitalière
PU-PH	POLACK Benoît	Hématologie ; Transfusion
PU-PH	POLOSAN Mircea	Psychiatrie d'adultes ; Addictologie
PU-PH	RAMBEAUD Jean-Jacques	Urologie
PU-PH	RAY Pierre	Biologie et médecine du développement et de la reproduction ; gynécologie médicale
PR Ass. Méd.	RECHE Fabian	Chirurgie viscérale et digestive
MCU-PH	RENDU John	Biochimie et biologie moléculaire
MCU-PH émérite	RIALLE Vincent	Biostatistiques, informatique médicale et technologies de communication
PU-PH	RIETHMULLER Didier	Gynécologie-obstétrique ; gynécologie médicale
PU-PH	RIGHINI Christian	Oto-rhino-laryngologie
PU-PH émérite	ROMANET Jean Paul	Ophthalmologie
PU-PH	ROSTAING Lionel	Néphrologie
PU-PH	ROUSTIT Matthieu	Pharmacologie fondamentale ; pharmacologie clinique ; addictologie
MCU-PH	ROUX-BUISSON Nathalie	Biochimie et biologie moléculaire
PR Ass.MG	ROYER DE VERICOURT Guillaume	Médecine Générale
PU-PH émérite	SARAGAGLIA Dominique	Chirurgie orthopédique et traumatologie
MCU-PH	SATRE Véronique	Génétique
PU-PH	SAUDOU Frédéric	Biologie cellulaire
PU-PH	SCHMERBER Sébastien	Oto-rhino-laryngologie
PU-PH	SCHWEBEL Carole	Médecine intensive-réanimation
PU-PH	SCOLAN Virginie	Médecine légale et droit de la santé
MCU-PH	SEIGNEURIN Arnaud	Epidémiologie, économie de la santé et prévention
PU-PH émérite	STAHL Jean-Paul	Maladies infectieuses ; Maladies tropicales
PU-PH	STANKE Françoise	Pharmacologie fondamentale ; pharmacologie clinique ; addictologie
MCU-PH	STASIA Marie-José	Biochimie et biologie moléculaire
PU-PH	STURM Nathalie	Anatomie et cytologie pathologiques
PU-PH	TAMISIER Renaud	Physiologie
PU-PH	TERZI Nicolas	Médecine intensive-réanimation
PU-PH	THEVENON Julien	Génétique
MCU-PH	TOFFART Anne-Claire	Pneumologie ; Addictologie
PU-PH	TONETTI Jérôme	Chirurgie orthopédique et traumatologie
PU-PH	TOUSSAINT Bertrand	Biochimie et biologie moléculaire
PU-PH	VALMARY-DEGANO Séverine	Anatomie et cytologie pathologiques
PU-PH	VANZETTO Gérard	Cardiologie
PU-PH	VUILLEZ Jean-Philippe	Biophysique et médecine nucléaire
PU-PH	WEIL Georges	Epidémiologie, économie de la santé et prévention
PU-PH	ZAOUI Philippe	Néphrologie
PU-PH émérite	ZARSKI Jean-Pierre	Gastroentérologie ; hépatologie ; addictologie

PU-PH : Professeur des Universités - Praticiens Hospitaliers
 MCU-PH : Maître de Conférences des Universités - Praticiens Hospitaliers
 PU-MG : Professeur des Universités de Médecine Générale
 MCU-MG : Maître de Conférences des Universités de Médecine Générale
 PR Ass. Méd. : Professeur des Universités Associé de Médecine
 PR Ass.MG : Professeur des Universités Associé de Médecine Générale
 MCF Ass.MG : Maître de Conférences Associé de Médecine Générale

REMERCIEMENTS

À notre maître et président du jury :

- À Monsieur le Professeur CHIQUET : Merci de me faire l'honneur de présider ce jury. Merci pour votre implication dans la formation des internes et dans la gestion du service d'ophtalmologie du CHU. Et merci pour la confiance que vous m'avez accordé lors de mes semestres au CHU.

À nos maîtres et membres du jury :

- À Monsieur le Professeur APTEL : Merci de me faire l'honneur d'être mon directeur de thèse. Soyez assuré de toute ma gratitude, pour votre savoir et votre aide précieuse dans les travaux que vous m'avez confié, ainsi que de mon profond respect.
- À Monsieur le Professeur GAIN : Veuillez accepter mes sincères remerciements d'avoir accepté de siéger au jury de ma thèse, ainsi que pour l'intérêt porté à ce travail. Soyez certains de toute ma gratitude pour votre expertise et de toute ma considération

À ceux qui ont participé au travail de thèse :

À Monsieur le Docteur Andrew TOREN : Cher Andrew, même si tu n'es pas membre du jury, tu as pu apporter toute ton expérience ainsi qu'un anglais médical plus que parfait dans les deux articles sur lesquels j'ai pu travailler avec toi !! Sois assuré de toute ma gratitude

Aux docteurs et aux équipes d'ophtalmologie qui ont participé à ma formation :

Au CH de Chambéry :

- *Au chef de service, Dr Olivier SAVY* : merci de m'avoir accordé votre confiance, de m'avoir accompagné avec bienveillance dans mes premières chirurgies de cataracte. Merci également de m'avoir proposé (très tôt) de réaliser mon assistantat dans votre service. J'espère pouvoir vous rendre cette confiance.
- *Au Dr COMBEY DE LAMBERT* : merci pour ta bienveillance et pour ta bonne humeur en toute occasion !
- *Au Dr CHIBANI* : merci pour votre accompagnement, et au bon souvenir de vos blocs avec la playlist des années 90 ou la nouvelle playlist avec Maître Gims !
- *À mes anciens assistants, Dr Benjamin MOTTET, et Dr Nischal ARYAL-CHARLES* : Vous m'avez transmis votre exigence et votre passion de l'ophtalmologie ! Au plaisir de vous revoir !
- *À mes anciens co-internes devenus docteurs : Dr Marc-Antoine CHAPPELET, Dr Olivier GAVARD, Dr Nicolas COSTE, Dr Mehdi TADJINE* : merci pour ces nombreuses heures passées à me former au bloc opératoire, vous êtes mes maîtres chirurgicaux et je vous en serai toujours reconnaissant
- *À toute l'équipe des orthoptistes, des infirmières de consultation, des aides-soignantes, des infirmières du bloc opératoire, des secrétaires*

Un mot commun pour vous tous : Merci pour votre accueil, lors de mes 3 stages d'interne dans le service. J'y ai trouvé à chaque fois un service chaleureux, accueillant, travaillant efficacement et dans la bonne humeur ! J'ai eu la chance de pouvoir revenir plusieurs fois, j'ai la chance de pouvoir poursuivre l'aventure encore deux ans en tant que futur assistant, et j'en suis sincèrement ravi !

Au CH d'Annecy :

- *Au chef de service, Dr Matthieu TONINI* : Merci pour ton accueil, pour ta bonne humeur, et pour ta relaxation sans faille au bloc pendant les chirurgies ! Ma première cataracte en entier, c'était avec toi, et pour cela je te serai à jamais reconnaissant !
- *Au Dr Hafide KHAYI, Dr Caroline DUPUY, Dr Cécile MUSSON*
- *A Emilie JOLY-POTTUZ* : la reine du style et de la réfraction ! Bises à toi et ta petite famille !
- *À toute l'équipe des orthoptistes, des infirmières de consultation, des aides-soignantes, des infirmières du bloc opératoire, des secrétaires*

Un mot commun pour vous tous : Merci pour votre accueil, j'ai passé six mois super avec vous, que de bons souvenirs !

Au CHU de Grenoble :

- Aux Dr GALLICE, Dr PALOMBI, Dr BERNHEIM, Dr SEMECAS, Dr KOSACKI, Dr ZAATAR, Dr. SALMON, Dr PEREZ ROUSTIT, Dr CASTELAIN, Dr DUFOURNET, Dr PEGOURIE, Dr POLLET-VILLARD : merci à tous pour votre formation théorique et chirurgicale, ainsi que pour votre confiance !
- Au Dr Oualid ATTOUI : à ta disponibilité sans faille pour m'aider quand j'étais en difficulté, et à ta maîtrise très précoce des injections de Botox
- Aux Dr. GUERLOT, Dr. BLOT, Dr THIA SOUY Tchong, Dr RUTGE, Dr REMOND : on a fait un petit bout d'internat et ensemble et ce fut un plaisir.
- Au Dr Lucile COTELLA : bonne continuation dans ta région du Sud, et sans rancune...aucune.
- À toute l'équipe des orthoptistes, des infirmières de consultation, des infirmières d'hospitalisation, des aides-soignantes, des infirmières du bloc opératoire, des secrétaires
- A Menana : tu m'as accueilli au CHU en hôpital de jour et je n'aurai pas pu rêver meilleurs accompagnement et compagnie. Tu vas beaucoup me manquer. Je te souhaite le meilleur !

Un mot commun pour vous tous : Merci pour votre accueil durant ces cinq années, je ne garde que de bons souvenirs ! Vous allez me sincèrement me manquer

À mes co-internes

- *Pierre* : Le PEC ! La gentillesse incarnée, et une musculature digne des dieux grecs ! Bonne continuation à Annecy, et au plaisir de te revoir !
- *Aurélia* : LA grande sportive de notre promotion ! A bientôt !
- *Thibaud* : Mon co-interne de promo, mon ami, mon cogestionnaire du planning au CHU pendant 1 an, et j'en passe ! Qui aurait cru il y a cinq ans, que tu finirais avec des pantalons 7/8^e et des socquettes ? Qui aurait cru il y a cinq ans que tu achèterais des vêtements de créateurs, de deuxième main certes, et aux couleurs vraiment trop flashy ? Qui aurait cru il y a cinq ans, que tu finirais en soirée électro à la belle, ou au BBR, et que tu rentrerais déchiré à 4h du matin ? Et au fond...j'aime penser que c'est un peu grâce à moi, tout ça ! ;) A très bientôt, l'ami !
- *Christophe* : petit ange parti trop tôt..... (en psychiatrie)
- *Sébastien* : Ça a été un plaisir de bosser avec toi ! C'est vrai que parfois, avec ta clope électronique ça peut donner l'impression que tu t'en fous, mais j'ai surtout vu une personne pragmatique et efficace !
- *Claire* : Toujours enthousiaste et jamais à cours d'idée pour améliorer le confort du bureau des internes ! Au plaisir !
- *Mathilde* : Matou :) Toujours en pleine forme, et souriante ! La plus grande fan du moindre flocon de neige, des repas d'hiver, de l'hiver et Val d'Isère en fait ! Et j'ai failli oublier la Corse ! Et également mon alter égo féminin pour ton côté fashion-victim et addict aux réseaux sociaux ! Plein de bisous !
- *Thomas* : On a passé un seul semestre ensemble, et on n'a pas beaucoup discuté, mais ce fut un plaisir ! Bonne continuation !

- *Camille* : ma petite CamBruni, j'ai tellement d'admiration et d'affection. Je t'ai vu éclore en ophtalmologie à Annecy, et j'espère avoir été un bon mentor depuis. Je n'oublierai pas nos soirées au BBR alors qu'on bossait le lendemain ! Également un petit mot pour ton homme et futur mari, Marvin, je vous embrasse tous les deux et vous souhaite le meilleur (ainsi qu'au petit bébé) !
- *Anne-Sophie* : On n'a pas beaucoup travaillé ensemble, et j'espère que tu vas prendre pleinement confiance à l'avenir ! Bonne continuation pour la suite !
- *Lucas* : On a bien rigolé lors de notre semestre ensemble ! A ton amour pour la formation en privé des externes du service, et à ta progression stylistique durant tes premières années d'internat !
- *Aymeric* : On s'est retrouvés sur des projets universitaires communs, t'es un gars top! Inchallah l'orbito-palpébrale arrivera à Grenoble grâce à toi !
- *Ohud* : Une maîtrise quasi-parfaite du français en si peu de temps, une incroyable gentillesse, et que dire de tes capacités en consultation ou au bloc. Bonne continuation !
- *Romain* : On a passé un seul petit semestre ensemble, et t'as géré tranquillou. Et puis t'es – à peu près- le sosie français de Jackson Avery de Grey's Anatomy, ce n'est pas rien !
- *Jeremy* : Super rencontre ! T'es un super gars, ne changes rien ! A très vite !
- *Louise* : L'ouzbek ! J'espère t'avoir bien guidé durant ton premier semestre à Chambéry et que tu ne te laisseras pas trop distraire par tes activités extra-scolaires (théâtre, violoncelle, piscine, week-end scoutistes). Poursuis bien ta formation ;)
- *Maelys* : J'espère avoir été un bon mentor pour ton premier semestre ! Tu as fait de très bons débuts à Chambé et la suite de ton internat s'annonce sur la même lancée ! A bientôt !
- *Hussain* : tu as vécu une intégration difficile, mais tout doucement tu prends tes marques. Bonne fin d'internat !
- *Adrian* : Tu n'es qu'au début de ton internat, mais tu es super motivé et tu as envie d'apprendre !
- *Nicolas* : Je n'ai pas pu travailler avec toi, mais tu sembles sérieux et efficace ! Bon courage pour la fin de tes études
- *Louis* : Coupes-moi ces cheveux, sérieux ! (en vrai t'es plus beau comme ça) Bonne continuation !
- *Sofia* : J'espère que tu ne regrettes pas mes conseils concernant le choix de Grenoble ! Bon courage pour la suite
- *À mes anciennes co-internes FFI Nitya, Gabriella, Emmanuella, Ana Maria, Loredana* : bonne continuation à vous toutes !

Au service de Neuro-Radiologie (CHU de Grenoble) ayant participé à ma formation :

- *Au Pr Alexandre KRAINIK,*
- *Aux Drs. Sylvie GRAND, Florence TAHON, Arnaud ATTYE, Adrian KASTLER, Alexis GALLOUX, Olivier HECK, Kamel BOUBAGRA,*
- *À mes anciens co-internes Maxime, Fanny, Charlotte*
- *À toute l'équipe des manipulateurs, aux brancardiers, à l'équipe des secrétaires*

Un mot commun pour vous tous : Merci pour votre accueil plus que chaleureux et bienveillant, j'ai adoré ce stage ! Mes salutations à toute l'équipe !

Au service d'ORL du CHU de Grenoble

- Aux Prs. Christian RIGHINI, Emile REYT et Sébastien SCHMERBER,
- À mes anciens assistants Drs. Eléa LAMBLIN, Éric BOYER et Philippe JUNET
- À mes anciens co-internes Raphaële, Cindy, Claire, Marie, Ashley, Akil, Christol
- À toute l'équipe infirmière d'hospitalisation et de consultation, l'équipe des secrétaires

Un mot commun pour vous tous : Merci pour votre accueil dans votre service ! Ce fut mon premier stage d'internat, mes premiers blocs, mes premières astreintes, mes premières consultations en solo... Une vraie épreuve du feu, mais qui m'a formé, et qui maintenant me sert au quotidien...et pour évaluer du mieux que je peux un nystagmus :) Un immense merci !

A mes amis :

- Cyril, Teva, Aurélien, JB : 5 ans ensemble, des souvenirs incroyables, de la P1 jusqu'à l'ECN avec des résultats en Thaïlande ! Au plaisir de tous vous revoir et de passer à nouveau des moments ensemble
- A Maxime : mon coloc pendant 1 an, radiologue et sportif émérite !
- A Claire Sandré, aka Francis aka Francisco, aka Cendrillon, etc! Ma co-interne des débuts, on a galéré tous les deux... Puis il y a eu toutes les soirées, les réveils déchirés déjà en retard pour aller faire le tour du service, bouteille d'eau dans la blouse, et Eric qui nous crame ! Au plaisir de te revoir ! (Et oui, 4 lignes aussi !)
- A Maxence et Laurine : Bonne continuation à vous deux !
- A Vadim mon ami d'enfance, et Romary, pour nos sorties régulières pour aller aux concerts de rock/métal/alternative et plus si affinités !
- A tous les autres, Fanny, Marion, Robin, Maverick, Babz, Victor Meunier, Victor Meyerie, Jordan & Adrien en radiologie...

A ma famille :

- A mes parents, mes grands-parents, mes deux sœurs, mes oncles et tantes qui m'ont toujours soutenu et qui m'apportent tant d'affection. (Et à Kikito, ses frères Droopy et Oural)
- A mon grand père et à mon arrière-grand-mère décédée durant mon internat, j'aurai aimé que vous puissiez vivre ce moment avec moi, et j'espère que vous êtes fiers là-haut.
- A Johanna, ma chérie, mon amour : bientôt dix ans qu'on est ensemble, et que tu es là pour moi. Bientôt je l'espère, on sera réunis et de nouveaux défis nous attendrons... Également, j'embrasse toute ta famille, Serge, Béa, Benji, Martine, Gilles, Caro & Jérémy, et MAGNUM etc... qui ont toujours fait preuve de tant d'affection et de bienveillance.

A tous ceux que j'ai oublié de mentionner : merci de votre soutien

A la XBOX, à Fortnite et al., aux films Marvel, à Netflix : tié la famille

A l'URSSAF : on est ensemble, a la vie à la mort (quasi)

A l'ordre des médecins (qui me demande chaque année d'apporter une nouvelle photo d'identité) : je n'ai pas changé de visage, promis

TABLE DES MATIERES

RESUME (ABSTRACT)	12
INTRODUCTION	13
MATERIELS & METHODES	16
Population.....	16
Procédure chirurgicale.....	16
Suivi et collecte des données.....	18
Acquisition OCT de segment antérieur.....	19
Paramètres étudiés de la bulle de filtration.....	19
Analyse OCT.....	20
Analyse statistique.....	21
RESULTATS	22
Caractéristiques de la population étudiée	22
Efficacité.....	22
Tolérance	24
Analyse OCT de la bulle de filtration.....	24
DISCUSSION	28
CONCLUSION	33
BIBLIOGRAPHIE	34
SERMENT D'HIPPOCRATE	38

ABSTRACT

Purpose: To evaluate anatomical characteristics of the filtering blebs and scleral wall thickness using anterior segment optical coherence tomography after ab externo Preserflo MicroShunt™ micro-invasive glaucoma surgery (MIGS) with mitomycin C application as well as efficacy and safety of the microshunt.

Methods: Single-site, prospective, interventional case series conducted in a tertiary university hospital. Open-angle glaucoma patients underwent ab externo Preserflo MicroShunt™ implantation with 0.2 mg/ml MMC sponge application. Anterior segment OCT of the filtering bleb and the underlying scleral wall were performed pre-operatively and 1 week, 1, 3, and 6 months post-operatively.

Results: Fourteen eyes of 14 patients were included. IOP was significantly reduced from a mean preoperative value of 19.7 ± 10.1 mmHg to a mean postoperative value of 13.2 ± 8.8 , 7.9 ± 2.8 , 12.25 ± 4.5 , 16.7 ± 8.5 , and 15.3 ± 7.2 mmHg at 0 ($p < 0.001$) and 7 days ($p < 0.001$), and 1 ($p = 0.014$), 3 ($p = 0.02$) and 6 months ($p = 0.012$), respectively. Glaucoma medications number were also significantly reduced ($p < 0.01$ for all values) from 3.2 ± 0.7 pre-operatively to 0, 0, 0.2 ± 0.7 , 0.5 ± 1.1 at day 7 and 1, 3 and 6 months, respectively. No major postoperative complications were reported. Needling of the bleb was performed post-operatively in 1 eye (7.1%). The proportion of subjects with IOP decrease $> 20\%$ at month 6 compared to baseline was significantly higher in patient with high bleb height ($p = 0.02$) and high distance between the implant and the conjunctiva ($p = 0.01$), but was not related to the presence of subconjunctival or subtenon fluid, the presence of subconjunctival cysts nor the bleb tissue hyporeflectivity ($p > 0.1$)

Conclusions: We found significant and comparable results in terms of efficacy and safety with the Preserflo MicroShunt™ compared to previous studies. Anterior-segment OCT imaging showed similar macroscopic characteristics of functional blebs in most of the patients.

INTRODUCTION

Glaucoma is an optic neuropathy characterized by progressive deterioration of the optic nerve and the subsequent development of visual field defects. It is the second leading cause of blindness worldwide and the leading cause of irreversible blindness [1-4].

Glaucoma therapy is based on lowering intraocular pressure (IOP) to an individual target level in order to decrease the rate of progression of glaucomatous optic neuropathy. Several large prospective studies have demonstrated the important role of lowering pressure in the prevention of glaucoma development in subjects with ocular hypertension and glaucoma progression in glaucoma subjects [5-9].

Glaucoma treatment is traditionally initiated with either medical therapy or laser intervention. Topical medications have a good efficacy and safety profile but their chronic use is known to cause dry eye and ocular surface disease. Nonadherence or poor compliance to treatments dosed daily are common in glaucoma and has been linked to poor outcomes and increased healthcare costs [8-12].

Surgical treatment for glaucoma sometime becomes necessary when medical nor laser treatments are not efficient enough to lower the intra-ocular pressure.

Conventional glaucoma surgery techniques such as filtering surgery (trabeculectomy, deep sclerectomy) and glaucoma drainage devices lower IOP by diverting aqueous humor from the anterior chamber (AC) to the subconjunctival space resulting in the creation of a filtering bleb.

Trabeculectomy represents the gold standard surgical treatment in glaucoma patients resistant to medical therapy. This surgery is performed ab externo and causes disruption of the conjunctiva and Tenon capsule, frequently leading to excessive fibrosis of the filtering bleb and failure of the surgery. Antifibrotic agents are

frequently used, via topical applications or subconjunctival injections, to reduce the risk of failure [10,11]. However, the use of antifibrotic agents increase the risk of sight-threatening complications such as hypotony and infection. In a recent large clinical study, complications following trabeculectomy with MMC included hyphema (25%), hypotony (24%), shallow anterior chamber (24%), wound leak (18%), choroidal detachment (14%), wipe-out effect (0.4%) as well as late complications including cataract formation (20%) and endophthalmitis (0.3%). [11]

In recent years, a wide variety of novel techniques called Micro-Invasive Glaucoma Surgery (MIGS) has emerged and aims to lower intraocular pressure (IOP) and maintain a good safety profile. These surgeries are mostly performed ab interno and in this case preserve the conjunctival and Tenon capsule's integrity. These micro-implants can be placed in different anatomical sites of the eye and increase the aqueous drainage by various mechanisms such as increasing the outflow through the Schlemm's canal (iStent, Hydrus, Kahook), suprachoroidal space (Cypass, glaukos, gold-shunt) or subconjunctival space (Xen, Preserflo MicroShunt™) [13,14,15].

The Preserflo Microshunt (Santen, Japan) is an ab externo MIGS implant that aims to create a fistula from the anterior chamber to the subconjunctival space. It is an 8.5 mm-long (outer diameter 350 µm; internal lumen diameter 70 µm) glaucoma drainage device made from a highly biocompatible, bioinert material called poly (styrene-block-isobutylene-block-styrene), or SIBS. The surgical technique is comparable to traditional trabeculectomy, but the controlled flow through the implant should allow for a better predictable IOP decrease and reduced rate of complications. The biocompatible material of the implant should minimize the healing process of the surrounding tissues and thus the risk of bleb fibrosis and rate needling. The first studies published or reported have indeed shown a low risk of failure and rate of bleb

needling (about 5-10% at 1-2 years) after a Preserflo MicroShunt™ implantation [13,14,15,16].

The primary goal of our study is to evaluate the clinical and anatomical characteristics of the filtering blebs and the underlying scleral wall using anterior segment optical coherence tomography after an ab externo Preserflo MicroShunt™ micro-invasive glaucoma surgery (MIGS) associated with mitomycin C application.

METHODS

Data source and population studied

This study was a prospective observational case series. Fourteen patients, over 18 years old, suffering from unilateral or bilateral glaucoma progressive despite maximal tolerated medical treatment were included. All patients followed in the Glaucoma Unit of the Grenoble University Hospital, underwent a complete ophthalmic examination before and after surgery including predetermined imaging tests. All patients provided both verbal and written informed consent to have their data recorded. Data collection was authorized by the *Commission Nationale de l'Informatique et des Libertés* (CNIL), the French information technology and personal data protection authority. Ethics committee approval to analyze the data was obtained from an institutional review board (IRB). The research described herein adhered to the tenets of the Declaration of Helsinki.

Patients were included our study if they satisfied the following inclusion criteria: diagnosis of glaucoma defined as IOP >21 mmHg before or during diurnal curve measurement with or without glaucoma medications, consecutive and reliable abnormal standard automated perimetry with abnormal results on the Glaucoma Hemifield Test and pattern standard deviation outside 95% of normal limits, optic nerve damage (asymmetric cup/disc ratio >0.2, rim thinning, notching, excavation, or retinal nerve fiber layer defect), and treated with glaucoma medications with or without a history of laser trabeculoplasty. Exclusion criteria were non glaucomatous ocular diseases other than cataract, history of filtering surgery such as trabeculectomy, deep sclerectomy, or MIGS without an available healthy quadrant of conjunctiva for the operative site, ocular traumatism, and connective tissue related disorders (Marfan's disease, Ehlers-Danlos disease).

Surgical technique [13]

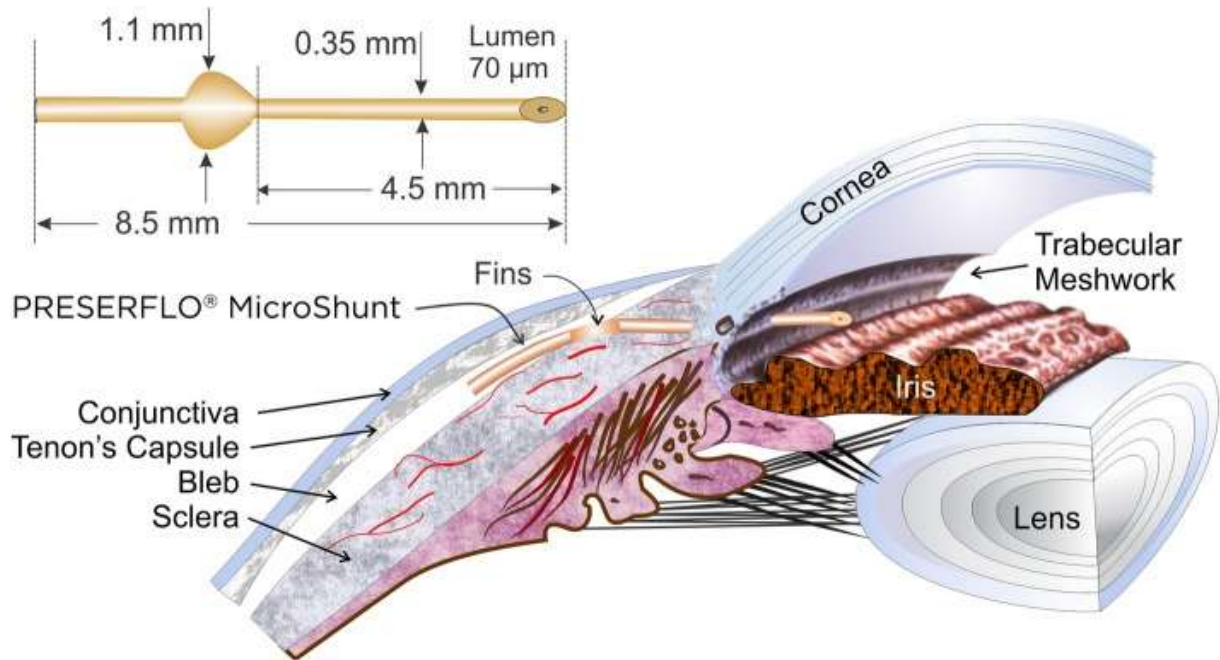
The procedure is performed under topical, regional or general anesthesia depending on patient and surgeon preference.

An incision through the conjunctiva and the tenon's capsule 6 to 8mm long, 2.5mm posterior to the limbus is first made. The tenon's is dissected from the sclera with scissors over a large area around the incision and posteriorly towards the equator. Hemostasis is performed with thermocautery. MMC 0.2 mg/mL or 50 mg/mL 5-FU was applied using the provided « LASIK Shield » sponges. The three sponges are positioned subconjunctival in the dissected space. The duration of application is 2-3 minutes depending on the surgeon preference. The MMC is then rinsed thoroughly with BSS.

A compass is used to locate the starting point of the scleral tunnel 3 mm from the surgical limbus. A keratome creates a scleral tunnel 1mm wide and 2 mm long before entering the anterior chamber with a 23-gauge needle. The MicroShunt® is then inserted into the scleral tunnel into the anterior chamber with its insertion stopped and stabilized by two fins of the implant in the scleral pocket. Aqueous flow at the distal end of the implant is confirmed and the implant is carefully positioned directly on the scleral under tenon's layer without embed the distal end into tenon's capsule. The conjunctiva is sutured with a Vicryl 8/0 running suture to achieve watertight closure.

Post-operatively, patients were treated with dexamethasone eye drops 5 times/day for one month and the, 3 times/day for 2 months.

Figure 1. Presentation of the Preserflo Microshunt drain and subconjunctival arrangement after surgical implantation [13].



Follow-up and data collection

Patients were included from June 2019 to February 2020. Baseline evaluation included best-corrected visual acuity, slit lamp bio-microscopy with gonioscopy and mydriatic fundus examination, Goldmann applanation tonometry with three measurements, ultrasound pachymetry, specular microscopy, visual field when applicable, and anterior segment OCT. The axial length was measured using the IOL-Master 900 (Carl Zeiss Meditec, Oberkochen, Germany). Corneal pachymetry measurements were obtained with the global pachymetry scan protocol of the CompactTouch (Quantel Medical, France). Refraction was performed using an autorefractometer (AR-360; Nidek Co., Gamagori, Japan), gonioscopy was performed using a Goldmann 3-mirror lens, visual field was performed using an automated diagnostic system (Humphrey Field Analyzer; 24–2 SITA-standard

program; Carl Zeiss Meditec, Dublin, CA), and OCT using an OCT-5000 with an anterior segment examination lens (Zeiss Meditec, Dublin, CA). The OCT acquisition and analysis are detailed below. During the follow-up, all the investigations except visual field, pachymetry and specular microscopy were performed one week, 1,2,3,6 and 12 months post-operatively. Visual field and specular microscopy were done at 6 and 12 months post-operatively.

Anterior OCT acquisition:

Spectral Domain optical coherence tomography (SD-OCT) of the perilimbal sclera was obtained with the cornea anterior segment module (CIRRUS 5000 HD OCT, Carl Zeiss Meditec, CA) using the HD CORNEA mode acquisition. In each eye quadrant, one individual scan was recorded which included the limbus. The orientation of each individual scan was perpendicular to the limbus (radial orientations). For image acquisition in each of the four quadrants (inferior, nasal, superior, temporal), patients were asked to maintain gaze position in the opposite direction to the quadrant examined, and care was taken to include the limbus on all scans. An additional scan was acquired at each postoperative visit in the bleb quadrant (mostly superior meridian), parallel to the limb, including the Preserflo Microshunt implant. See Figure 2.

Bleb parameters

We used previous work examining clinical morphologic parameters of the filtering bleb observed with slit lamp or photographs [^{17,18,19}], to define OCT bleb parameters of a successful filtering bleb with clinical and anterior OCT features. The following bleb characteristics were manually assessed for each patient: bleb height, distance

between Preserflo Microshunt implant effective position and the upper layer of conjunctiva, presence of sub-tenon fluid, presence of sub-conjunctival fluid, and presence of micro/big intra-conjunctival cysts. The presence of the latter three criteria may define a presumed successful filtering bleb. Conversely, their absence may determine early signs of failure of the filtering bleb.

Scleral image analysis (Figure 2)

Previously described protocols in studies by Buckhurst et al. in 2015 [20], Ebnetter et al., and others [20-23] were adapted in our OCT analysis of the filtering bleb.

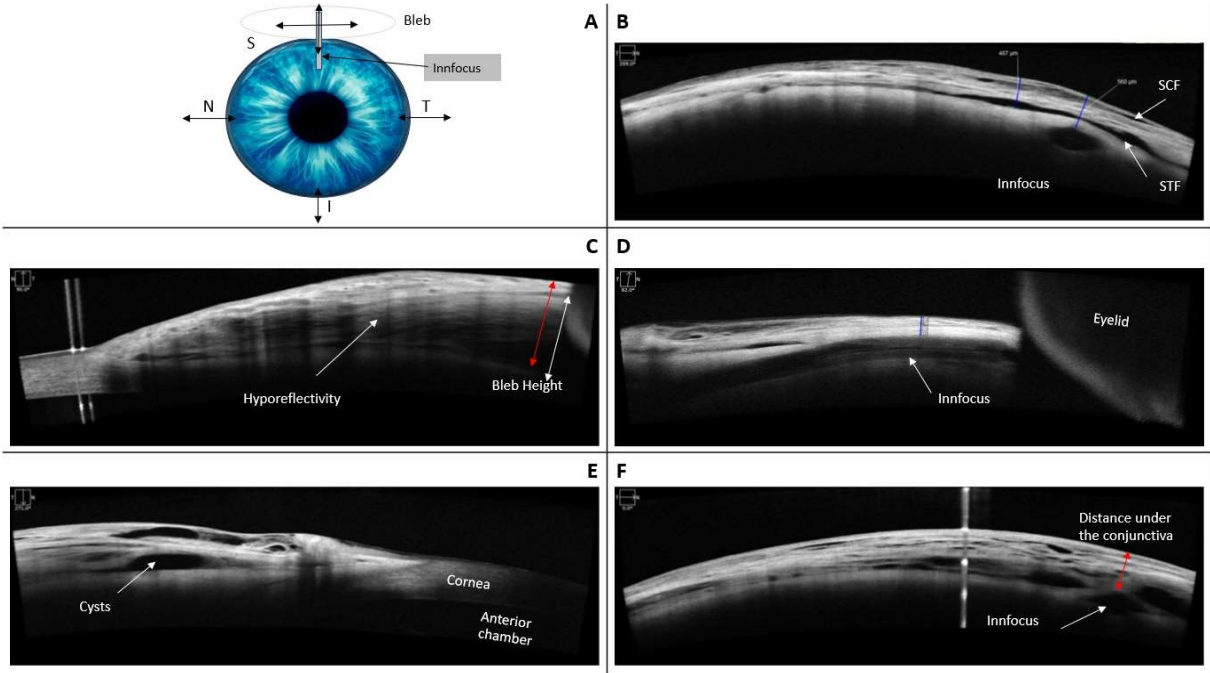
All five meridians were analyzed separately in random order by the same examiner (two examiners in total) using the protocol described below. The five scans with the best quality were used. The nasal, temporal and inferior scan were used as controls.

The caliper orientation and placement for each measurement were oriented with the scleral interfaces delineated by the change in image reflectivity. Bleb height was

measured between the lamina fusca of the sclera and the upper layer of conjunctiva.

The separation between the different image reflectivity provided the value for the bleb height at each point of measurement

Figure 2. Example of scleral measurement acquisition from Anterior OCT.



A. Schematic example of a left eye and orientation and placement of scans. B. Example for subconjunctival fluid (SCF), subtenon fluid (STF) and tube position. C Example for bleb height measurement and hyporeflexivity. D Example for tube position, sagittal cut. E. Example for conjunctival cysts. F Example for distance under the conjunctiva and tube position.

Statistical analysis

Student’s t-test was used to compare means and percentages, and chi squared tests were used for the analysis of dichotomous variables. Statistical significance was set at p=0.05. Statistical software (SPSS, Inc., Chicago, IL) was used for data analysis.

RESULTS

Baseline characteristics

We included 14 eyes of 14 patients (6 men, 8 women). The ages ranged from 44 to 94 years, with an overall mean age of 71.1 ± 16.2 years. All patients had open-angle glaucoma with characteristic visual field and optic nerve head findings. 7 patients were phakic, 7 were pseudophakic.

The mean number of previous glaucoma topical therapies in the study eye was 3.2 ± 0.7 .

The patient characteristics are summarized in **Table 1**.

Table 1. Patients characteristics (n=14)

Sex (M/F)	0.75 (6/8)
Age	71.1 ± 16.2
Lens status	7 phakic / 7 pseudophakic
Eye (R/L)	1.8 (9/5)
Glaucoma	
> GPAO	11 (78.6%)
> Secondary Glaucoma	3 (21.4%)
UG	2
PACG	1
Visual Acuity (logmar)	0.20 ± 0.29
IOP	23.72 ± 9.8
Number of treatments	3.2 ± 0.69
CCT (μm)	486.37 ± 25.7
MMC vs 5-FU application	8/6 (1.33)

Efficacy

IOP was significantly reduced from a mean preoperative value of 19.7 ± 10.1 mmHg to a mean postoperative value of 13.2 ± 8.8 , 7.9 ± 2.8 , 12.25 ± 4.5 , 16.7 ± 8.5 , and 15.3 ± 7.2 mmHg at 0 ($p < 0.001$) and 7 days ($p < 0.001$), and 1 ($p = 0.014$), 3 ($p = 0.02$) and 6 months ($p = 0.012$) respectively. Glaucoma medications were also significantly reduced ($p < 0.01$ for all values) from 3.2 ± 0.7 pre-operatively to 0, 0, 0.2 ± 0.7 , 0.5 ± 1.1 at day 7 and 1, 3 and 6 months, respectively ($p = 0.012$).

Mean IOP reduction from baseline was 6.5 mmHg (32.8%) at day 0 post-surgery day, 11.7 mmHg (59.5%) at 7 days, 7.4 mmHg (37%) at 1 month, 2.9 mmHg (14.9%) at 3 months, 4.4 mmHg (22.3%) at 6 months.

Absolute and relative intraocular pressure reductions from baseline of each follow-up, with number of glaucomatous medications, are shown in **Table 2**. One patient (7.1%) underwent a needling procedure during the follow-up.

Table 2. IOP measurements, IOP variation vs Baseline.

	Min	Max	Mean IOP (mmHg) [no. glaucomatous medication]	IOP variation vs Baseline	%
Baseline	9	43	19.7 ± 10.1 [$n = 3.2 \pm 0.7$]		
D0	4	36	13.2 ± 8.8 [$n = 0$]	-6.5	-32.8%
D7	4	14	7.9 ± 2.8 [$n = 0$]	-11.7	-59.53%
M1	5	21	12.25 ± 4.5 [$n = 0$]	-7.4	-37.75%
M3	9	35	16.7 ± 8.5 [$n = 0.2 \pm 0.7$]	-2.9	-14.91%
M6	8	32	15.3 ± 7.2 [$n = 0.5 \pm 1.1$]	-4.4	-22.29%

Safety

No peri-operative complications occurred. Mean visual acuity remained unchanged (best corrected visual acuity logMAR 0.20 ± 0.29 before surgery (Baseline) and logMAR 0.56 ± 1.1 at last follow-up (M6) ($p=0.37$). Visual acuity loss of three lines or more was observed in six patients (42.8%), five at day 7 and one at one month, with four fully recovering initial acuity after.

Post-operative complications occurred in five patients (35.7%). No postsurgical infectious complications (endophthalmitis, bleb infection, hypopyon) or allergic reactions were observed. Choroidal detachments, with immediate post-operative flat anterior chamber occurred in 1 of 14 patients (7.1%). Three patients had an early post-operative bleb leak (conjunctival leakage) at D0 or D7 control, with complete resolution within 15 days.

In three patients, the IOP increase required resumption of additional medical therapies (glaucomatous medication), and one of them undergone needling with subconjunctival 5-Fluorouracil injection, between 3 and 6 months after surgery, due to non-functional filtering bleb.

All of the occurrences of complications are summarised in the **Table 3**.

Table 3. Occurrence of complications.

Choroidal detachment	1 (7.1%)
Flat anterior chamber	1 (7.1%)
Seidel	3 (21.3%)

OCT analysis of filtering bleb

Up to 6 scans per patient, depending on the quality of the OCT screening, were performed at baseline, D7, M1, M3 and M6. The OCT procedure is shown in Figure 2.

Each scan was assessed by two individual examiners to record each OCT parameter from baseline to six months. Analysis were done on the fourteen patients who had M6 OCT scan.

Subconjunctival fluid was observed in 100% (14/14) of the eyes at 7 days, in 92.3% (12/13) of the eyes at 1 month, in 90% (9/10) of the eyes at 3 months, in 90.9% (10/11) of the eyes at 6 months. Subtenon fluid was observed in 14 eyes (100%) at 7 days, then 11 eyes (84.6%) at 1 month, then 10 eyes (100%) at 3 months, then 11 eyes (100%) at 6 months. Bleb tissue hyporeflectivity was found in the same proportions as the sub-tenon fluid.

Bleb micro or macro cysts were observed was observed in 100% (14/14) of the eyes at 7 days, in 92.3% (12/13) of the eyes at 1 month, in 90% (9/10) of the eyes at 3 months, in 90.9% (10/11) of the eyes at 6 months. At 7 days, we observed mostly large intra-conjunctival cysts in 13 patients (92.9%). At 1 month, we observed mostly large intra-conjunctival cysts in 10 patients (69.2%), and 2 patients (15.5%) had small cysts, one patient had no cysts (7.7%). At 3 months, we observed mostly small intra-conjunctival cysts in 6 patients (60%), and 3 patients had large cysts (30%), one patient had no cysts (10%). At 6 months, we observed mostly small intra-conjunctival cysts in 6 patients (54.5%), 5 patients had large cysts (45.50%). See **Table 4**.

Table 4. OCT Bleb analysis.

	Subconjunctival fluid		Subtenoinian fluid		Cysts		
	-	+	-	+	-	small	small & large
D7	0%	100%	0%	100%	0%	35.7%	64.3%
M1	7.7%	92.3%	15.4%	84.6%	7.7%	69.2%	23.1%
M3	10%	90%	0%	100%	10%	60%	30%
M6	9.1%	90.9%	0%	100%	0%	54.50%	45.50%

Bleb height was manually assessed at all dates of examination, with an average bleb height mean of $804.4 \pm 280.7 \mu\text{m}$ at 7 days, $877.8 \pm 383.1 \mu\text{m}$ at 1 month, $872.7 \pm 357.1 \mu\text{m}$ at 3 months, and $844.5 \pm 309.1 \mu\text{m}$ at 6 months. We assessed an overall median for all date of examination to classify in two groups: values under the median were considered as low-size filtering bleb, then those above the median were considered as functional filtering bleb. The results for the two groups are shown in

Table 5.

Position of the implant in the subconjunctival tenon's tissue was observed at all dates of examination, with a mean distance under the conjunctival layer of $499 \pm 143.6 \mu\text{m}$ at 7 days, $538.5 \pm 181.7 \mu\text{m}$ at 1 month, 560 ± 307.2 at 3 months, and $705.6 \pm 219 \mu\text{m}$ at 6 months. Overall, from measurements throughout the follow-up, the implant had average distance of $575.6 \mu\text{m}$ under the conjunctiva.

We manually assessed for each patient the effective position of the implant, based on overall post-operative examinations, separating the fourteen patients in two groups: one group of 3 (25%) patients had shallow position of the implant (superficial intra-tenon position), then 9 (75%) patients had a deep implantation position of the device (deep tenon, near sclera). We did not manage to classify two patients who didn't have enough quality OCT scans. Using the median value for implant position for all examination, we correlated our morphological analysis of the bleb with the measurements of distance under the conjunctival layer: the 3 "superficial intra-tenon position" patients had mean values under the overall median, and the 9 "deep tenon implant". Results are shown in **Table 5**.

The proportion of subjects with IOP decrease > 20% at month 6 compared to baseline was significantly higher in patient with high bleb height (p=0.02) and high distance between the implant and the conjunctiva (p=0.01), but was not related to the presence of subconjunctival or subtenon fluid, the presence of subconjunctival cysts nor the bleb tissue hyporeflectivity (p>0.1).

Table 5. Implant position and bleb height.

	Distance under the conjunctival layer (µm)				Bleb Height (µm)			
	Median	Min	Max	Mean	Median	Min	Max	Mean
D7	530	300	636	499 [±143.6]	853.5	192	1214	804.4 [±280.7]
M1	478.5	393	804	538.5[±181.7]	923	285	1500	877.8 [±383.1]
M3	527	270	883	560[±307.8]	803	376	1554	872.7 [±357.1]
M6	669	393	991	705.6 [±219.1]	843.5	356	1314	844.5 [±309]
All Dates	543	270	991	584.9 [±208.9]	853.5	192	1554	847.5 [±316.3]
	Distribution (n = 12)			Distribution (n = 14)				
	n	%	number of patients resuming glaucoma medications at M6	n	%	number of patients resuming glaucoma medications at M6		
Under Median	3	25.00 %	2	6	42.9%	2		
Above Median	9	75.00 %	1	8	57.1%	1		

DISCUSSION

The primary goal of the Preserflo Microshunt implant surgery to lower intraocular pressure and glaucoma medications was achieved. Pre-operative mean medicated intraocular pressure (IOP) was 19.7 ± 10.1 mmHg to a mean postoperative value of 13.2 ± 8.8 , 7.9 ± 2.8 , 12.25 ± 4.5 , 16.7 ± 8.5 , and 15.3 ± 7.2 mmHg at 0 ($p < 0.001$) and 7 days ($p < 0.001$), and 1 ($p = 0.014$), 3 ($p = 0.02$) and 6 months ($p = 0.012$) respectively. Glaucoma medications were also significantly reduced ($p < 0.01$ for all values) from 3.2 ± 0.7 pre-operatively to 0, 0, 0.2 ± 0.7 , 0.5 ± 1.1 at day 7 and 1, 3 and 6 months, respectively ($p < 0.05$). Mean IOP change from baseline to 6 months was -4.4 mmHg (-22.4% , $p < 0.05$).

One on the fourteen patients were considered as failure (non-filtering bleb) and required a needling procedure at 5 months postoperative. No patients needed an additional glaucoma surgery or surgical revision of the initial surgery. There were no post-operative infections, no allergic reactions, no conjunctival erosion, and no implant exposition.

Because of the recent availability of the device, there are currently few studies [13,16,24] who have studied the efficacy of Preserflo implant surgery. Authors found better efficacy results (around 50% IOP reduction at 12 months following) [13,16,21,25] or similar results [24] in lowering IOP at twelve months or more. Other studies and clinical trials are expected for the next years: a prospective randomized FDA clinical trial comparing the safety and efficacy of the Preserflo MicroShunt to trabeculectomy in POAG is underway (NCT0188425). Another clinical trial in the Netherlands (NCT03931564) aims to compare the cost-effectiveness of the Preserflo MicroShunt to trabeculectomy and is expected to complete by July 2022 [19].

The Preserflo Microshunt implant, either alone or in combination with phacoemulsification [16], significantly reduces both IOP and the number of antiglaucoma medications to a similar rate than trabeculectomy, but with a better safety profile [13,25]. Needling occurrence (7.1%) in our study could not be compared to other previous studies [13,16,24,25] which did not describe any surgical revision. In recent years, some authors tried to establish clinical classification to determine predictive signs for a postoperative functional filtering bleb providing an extended lowering of the IOP. We referred to two widely used clinical scales for bleb morphology classifications: IBAGS (Indiana Bleb Appearance Grading Scale) and Moorfields grading system [17,18]. Clinical parameters were assessed with slit lamp examination combined with photographs: bleb height, bleb extent, vascularity, seidel test (each parameter scaled from 0 to maximum 4) for the IBAGS [17], bleb area, bleb height, vascularity for the Moorfields [18]. Further studies include that assessing the presence of micro-cysts [17,19] and bleb hyporefectivity (with ultrasound biomicroscopy) [19,26], and a not encapsulated moderately elevated bleb [19,27] were correlated to a successful filtering bleb with better clinical outcome. Other studies examined the width of filtration openings on the scleral flap, bleb wall thickness, fluid-filled cavity height, bleb volume, and bleb wall intensity helped with 3D anterior segment OCT as predictive factors of clinical outcomes [28-30]. The position of the implant, bleb hyporefectivity, the presence of subtenon or subconjunctival fluid to our knowledge have not been assessed.

In our study, the proportion of subjects with IOP decrease > 20% at month 6 compared to baseline was significantly higher in patient with high bleb height ($p=0.02$) and high distance between the implant and the conjunctiva ($p=0.01$), but was not related to the presence of subconjunctival or subtenon fluid, the presence of

subconjunctival cysts nor the bleb tissue hyporefectivity ($p>0.1$). Moreover, two of the three patients with “intra-tenon” (shallow) position of the implant resumed glaucoma medications at 6-month study, whereas one of the nine patients with deep tenon position of the implant. A deeper relative position of the implant under the tenon’s layer, demonstrated a thick bleb and greater IOP reduction with lesser glaucoma medications, whereas a more superficial position in the conjunctiva showed a less important bleb height, with a more important number of glaucoma medications at 6 months.

The design of our study has a number of limitations. The number of patients is small in comparison to previous larger studies of the Preserflo implant. Secondly, there was no control group of Preserflo implantation without MMC. Thirdly, only 11 of 14 (78.6%) of patients had 6-month data available. The follow up was limited to six months although an eventual 12 month follow up analysis is planned.

Due to a European-wide supply issue of mitomycin C, 6 patients (42,9%) received adjunctive 5-Fluorouracil instead. In the group of patients which received 5-FU, one patient (16.7%) restarted glaucoma medications compared with two patients (25%) in the MMC group. The average IOP reduction at six months with the same for both groups ($p>0.1$). The average number of glaucomatous medications was higher in MMC group at M3 and M6 ($p=0.02$). The rate of complications was higher in the 5-FU group with 2 post-operative bleb leaks and 1 choroidal detachment.

Table 6. MMC vs 5 FU IOP changes.

	MMC Group (n=8)			5-FU group (n=6)		
	Mean IOP (mmHg) [no. glaucomatous medication]	IOP variation vs Baseline	%	Mean IOP (mmHg)	IOP variation vs Baseline	%
Baseline	19.6 ±11.1 [n=3.4]			19.8 ±9.7 [n=3]		
D0	13.4 ±5.7 [n=0]	-6.2	-31.8%	13 ±13.3 [n=0]	-6.8	-34.4%
D7	8.3 ±3.1 [n=0]	-11.3	-57.9%	7.6 ±2.7 [n=0]	-12.2	-62.0%
M1	10.9 ±3.6 [n=0]	-8.7	-44.6%	14.1 ±5.3 [n=0]	-5.7	-28.9%
M3	16.5 ±10.0 [n=0.3]	-3.1	-15.9%	17.2 ±5.9 [n=0]	-2.6	-12.8%
M6	15.6 ±8.9 [n=0.7]	-4	-20.3%	14.8 ±4.9 [n=0.3]	-4.9	-25.2%

There were limitations related to the acquisition of OCT measurements. Despite two examiners performing all the measurements blinding was not possible and few duplicate measures were performed. There was an initial learning curve in the process of OCT scans that could result in low quality scans due to artefacts or poor gaze position. Our scans using the anterior segment OCT software were susceptible to variation in position and no automated calibration using eye position tracking is yet available to ensure repeat measurements are recorded in the exact position between different follow-up visits.

Some of the previously described clinical parameters were not assessed during our study as we were not able to reliably reproduce results: essentially bleb area (extent/total volume), bleb wall thickness (presence of encapsulation or not) and vascularity [18,25,27].

During all follow-up visits, we assessed the bleb status by slit lamp examination but did not formally grade the bleb using IBAGS or Moorfields grading system, so we were unable to show a correlation between IOP and bleb vascularity. Some authors also have incorporated the use of OCT-Angiography in the assessment of filtering blebs and quantitatively and qualitatively measured vessel vascularization present [31]. Bleb vascularization has been defined as a predictive factor for a successful filtering bleb, and can be assessed using objective and quantitative parameters on OCT angiography. In other studies, a good clinical outcome was observed in patients that had a bleb without excessive vascularization and when the presence of “corkscrew vessels” were rare [18,27].

The formats of the OCT scans, in a simple cross section instead of a volume scan, did not allow us to assess bleb area and bleb wall thickness. These parameters would have required a much longer time of acquisition with our OCT (CIRRUS 5000 HD OCT) or another machine to conveniently assess it. The presence of encapsulation of the filtering bleb was eliminated for each patient. However, our OCT scans were limited in characterizing bleb walls due to either the scans being too short or the sloping nature of the bleb on temporal or nasal meridian.

CONCLUSIONS

Overall, in this study, we showed significant results in terms of efficacy and safety in Preserflo Microshunt surgery. The limited follow-up length of 6 months and the small number of patients are important limitations. This study's novel investigation into bleb evaluation post Preserflo surgery using anterior OCT scans presents the potential for new anterior segment OCT parameters to assess and manage a filtering bleb post operatively and possibly guide therapeutic decisions. Relying on the clinical and OCT parameters already suggested by different authors, we observed potential novel bleb parameters associated with a better clinical outcome (well-filtering bleb, associated with an extended lowering of the IOP, low rate of complications, low rate of 5FU needling or surgery). In our study, we suggest that a high bleb height and a high distance under the conjunctiva (deep tenon implant position), depending on the surgical technique, is related to a better clinical outcome. The presence of small or large cysts, subtenon or subconjunctival fluid shall be considered as predictive factors for a functional filtering bleb, although we did not find any significative relation between them and a higher IOP reduction. Conjunctival and scleral tissue should be carefully examined at each post-operative control via slit lamp, with the option of using anterior OCT or using clinical grading scale to manage therapeutic decision. This study will be continued until at least twelve months to allow a greater number of patient follow-up and further collection of filtering bleb characteristics post-operatively.


REFERENCES

1. Resnikoff S. Pascolini D. Etya'ale D. Kocur I. Pararajasegaram R. Pokharel GP. et al. Global data on visual impairment in the year 2002. Bull World Health Organ. 2004 Nov;82(11):844–51.
2. Weinreb RN. Khaw PT Primary open-angle glaucoma. Lancet Lond Engl. 2004 May 22;363(9422):1711–20.
3. Quigley HA. Broman AT. The number of people with glaucoma worldwide in 2010 and 2020. Br J Ophthalmol. 2006 Mar;90(3):262–7.
4. Tham YC. Li X. Wong TY. Quigley HA. Aung T. Cheng CY. Global prevalence of glaucoma and projections of glaucoma burden through 2040: a systematic review and meta-analysis. Ophthalmology. 2014 Nov;121(11):2081-90
5. Garway-Heath DF. Crabb DP. Bunce C. Lascaratos G. Amalfitano F. Anand N. et al. Latanoprost for open-angle glaucoma (UKGTS): a randomised. multicentre. placebo-controlled trial. Lancet Lond Engl. 2015 Apr 4;385(9975):1295–304.
6. Gordon MO. Beiser JA. Brandt JD. Heuer DK. Higginbotham EJ. Johnson CA. et al. The Ocular Hypertension Treatment Study: baseline factors that predict the onset of primary open-angle glaucoma. Arch Ophthalmol Chic Ill 1960. 2002 Jun;120(6):714-720; discussion 829-830.
7. Heijl A. Bengtsson B. Hyman L. Leske MC. Early Manifest Glaucoma Trial Group. Natural history of open-angle glaucoma. Ophthalmology. 2009 Dec;116(12):2271–6.
8. The Advanced Glaucoma Intervention Study (AGIS): 7. The relationship between control of intraocular pressure and visual field deterioration. The AGIS Investigators. Am J Ophthalmol. 2000 Oct;130(4):429–40.

9. Kass MA. Heuer DK. Higginbotham EJ. Johnson CA. Keltner JL. Miller JP. et al. The Ocular Hypertension Treatment Study: a randomized trial determines that topical ocular hypotensive medication delays or prevents the onset of primary open-angle glaucoma. *Arch Ophthalmol Chic Ill* 1960. 2002 Jun;120(6):701-713; discussion 829-830.
10. Heijl A. Leske MC. Bengtsson B. Hyman L. Bengtsson B. Hussein M. et al. Reduction of intraocular pressure and glaucoma progression: results from the Early Manifest Glaucoma Trial. *Arch Ophthalmol Chic Ill* 1960. 2002 Oct;120(10):1268–79.
11. Lichter PR. Musch DC. Gillespie BW. Guire KE. Janz NK. Wren PA. et al. Interim clinical outcomes in the Collaborative Initial Glaucoma Treatment Study comparing initial treatment randomized to medications or surgery. *Ophthalmology*. 2001 Nov;108(11):1943–53.
12. Chauhan BC. Mikelberg FS. Artes PH. Balazsi AG. LeBlanc RP. Lesk MR. et al. Canadian Glaucoma Study: 3. Impact of risk factors and intraocular pressure reduction on the rates of visual field change. *Arch Ophthalmol Chic Ill* 1960. 2010 Oct;128(10):1249–55.
13. Omar Sadruddin. Leonard Pinchuk. Raymund Angeles. Paul Palmberg .Ab externo implantation of the MicroShunt. a poly (styrene- block-isobutylene- block-styrene) surgical device for the treatment of primary open-angle glaucoma: a review. *Eye Vis (Lond)* 2019 Nov 15;6:36.
14. Kateki Vinod. Steven J Gedde. Clinical investigation of new glaucoma procedures. *Curr Opin Ophthalmol* 2017 Mar;28(2):187-193.

15. Marco Nardi. Chiara Posarelli. Francesco Nasini. Michele Figus. Mini Drainage Devices for Anterior and Intermediate Filtration. *Dev Ophthalmol.* 2017;59:90-99
16. Leonard Pinchuk et al. The development of a micro-shunt made from poly(styrene-block-isobutylene-block-styrene) to treat glaucoma. *J Biomed Mater Res B Appl Biomater* 2017 Jan;105(1):211-221
17. Louis B Cantor 1. Anand Mantravadi. Darrell WuDunn. Kala Swamynathan. Arnold Cortes. Morphologic classification of filtering blebs after glaucoma filtration surgery: the Indiana Bleb Appearance Grading Scale. *J Glaucoma.* 2003 Jun;12(3):266-71
18. A. P. Wells et al. A Pilot Study of a System for Grading of Drainage Blebs after Glaucoma Surgery. *J Glaucoma* 2004;13:454–460)
19. Anna T Do 1. Hardik Parikh. Joseph F Panarelli. Subconjunctival microinvasive glaucoma surgeries: an update on the Xen gel stent and the PreserFlo MicroShunt. *Curr Opin Ophthalmol.* 2020 Mar;31(2):132-138
20. Hetal D. Buckhurst. 1 . * Bernard Gilmartin. 2 Robert P. Cubbidge. 2 and Nicola S Logan. Measurement of Scleral Thickness in Humans Using Anterior Segment Optical Coherent Tomography. *PlosOne* 2015
21. Juan F Battle et. Al. Three-Year Follow-up of a Novel Aqueous Humor MicroShunt. *J Glaucoma.* 2016 Feb;25(2):e58-65
22. Scott A Read. et al. Diurnal Variation of Anterior Scleral and Conjunctival Thickness. *Ophthalmic Physiol Opt.* 2016 May;36(3):279-89.
23. Andreas Ebnetter. Nathanael U Häner. Martin S Zinkernagel. Metrics of the Normal Anterior Sclera: Imaging With Optical Coherence Tomography. *Graefes Arch Clin Exp Ophthalmol.* 2015 Sep;253(9):1575-80

24. Anthony J King 1. Anupa Shah. Eleni Nikita. Kuang Hu. Caroline A Mulvaney. Richard Stead. Augusto Azuara-Blanco. Subconjunctival draining minimally-invasive glaucoma devices for medically uncontrolled glaucoma. Cochrane Database Syst Rev. 2018 Dec 16;12(12):CD012742
25. I Riss 1. J Batlle 2. One-year results on the safety and efficacy of the InnFocus MicroShunt™ depending on placement and concentration of mitomycin C]. J Fr Ophtalmol 2015 Nov;38(9):855-60
26. Tetsuya Yamamoto. Takeshi Sakuma. Yoshiaki Kitazawa. An Ultrasound Biomicroscopic Study of Filtering Blebs after Mitomycin C Trabeculectomy.
27. F. Grehn. G. Picht. Classification of Developing Filtering Blebs after Trabeculectomy. Glaucoma Update VI pp 211-216
28. Utako Tsutsumi-Kuroda et al. Early bleb parameters as long-term prognostic factors for surgical success: a retrospective observational study using three-dimensional anterior-segment optical coherence tomography. BMC Ophthalmol. 2019; 19: 155.
29. Soeren Waibel. Eberhard Spoerl. Olga Furashova. Lutz E Pillunat. Karin R Pillunat. Bleb Morphology After Mitomycin-C Augmented Trabeculectomy: Comparison Between Clinical Evaluation and Anterior Segment Optical Coherence Tomography. J Glaucoma. 2019 May;28(5):447-451
30. Fumika Watanabe-Kitamura. Toshihiro Inoue. Sachi Kojima. Kei-Ichi Nakashima. Ayako Fukushima. Hidenobu Tanihara. Prospective 3D Investigation of Bleb Wall after Trabeculectomy Using Anterior-Segment OCT. Hindawi Journal of Ophthalmology Volume 2017. Article ID 8261364.
31. Je Hyun Seo. Ye An Kim. Keun Heung Park. Young Lee. Evaluation of Functional Filtering Bleb Using Optical Coherence Tomography Angiography



SERMENT D'HIPPOCRATE

En présence des Maîtres de cette Faculté, de mes chers condisciples et devant l'effigie d'HIPPOCRATE,

Je promets et je jure d'être fidèle aux lois de l'honneur et de la probité dans l'exercice de la Médecine.

Je donnerai mes soins gratuitement à l'indigent et n'exigerai jamais un salaire au dessus de mon travail. Je ne participerai à aucun partage clandestin d'honoraires.

Admis dans l'intimité des maisons, mes yeux n'y verront pas ce qui s'y passe ; ma langue taira les secrets qui me seront confiés et mon état ne servira pas à corrompre les mœurs, ni à favoriser le crime.

Je ne permettrai pas que des considérations de religion, de nation, de race, de parti ou de classe sociale viennent s'interposer entre mon devoir et mon patient.

Je garderai le respect absolu de la vie humaine.

Même sous la menace, je n'admettrai pas de faire usage de mes connaissances médicales contre les lois de l'humanité.

Respectueux et reconnaissant envers mes Maîtres, je rendrai à leurs enfants l'instruction que j'ai reçue de leurs pères.

Que les hommes m'accordent leur estime si je suis fidèle à mes promesses.

Que je sois couvert d'opprobre et méprisé de mes confrères si j'y manque.

THÈSE SOUTENUE PAR : Kévin ALLAIX

TITRE :

SIX MONTHS RESULTS ON EFFICACY, SAFETY, AND OPTICAL COHERENCE
TOMOGRAPHY MONITORING OF THE BLEB, FOLLOWING INNFOCUS
MICROSHUNT™ IMPLANTATION

CONCLUSION :

We found significant and comparable results in terms of efficacy and safety with the Preserflo MicroShunt™ MIGS compared to previous studies. Anterior-segment OCT imaging showed similar macroscopic characteristics of functional blebs in most of the patients.

VU ET PERMIS D'IMPRIMER

Grenoble, le : 11/09/20

LE DOYEN



Pr. Patrice MORAND

LE PRÉSIDENT DE LA THÈSE

Pr. Florent APTEL

Pour le Président
et par délégation
Le Doyen de Médecine
Pr. Patrice MORAND

