



HAL
open science

Impact of direct oral anticoagulant therapy on intraventricular thrombus evaluated with cardiac magnetic resonance imaging

Marine Boulanger

► **To cite this version:**

Marine Boulanger. Impact of direct oral anticoagulant therapy on intraventricular thrombus evaluated with cardiac magnetic resonance imaging. Human health and pathology. 2021. dumas-03457340

HAL Id: dumas-03457340

<https://dumas.ccsd.cnrs.fr/dumas-03457340>

Submitted on 30 Nov 2021

HAL is a multi-disciplinary open access archive for the deposit and dissemination of scientific research documents, whether they are published or not. The documents may come from teaching and research institutions in France or abroad, or from public or private research centers.

L'archive ouverte pluridisciplinaire **HAL**, est destinée au dépôt et à la diffusion de documents scientifiques de niveau recherche, publiés ou non, émanant des établissements d'enseignement et de recherche français ou étrangers, des laboratoires publics ou privés.



Distributed under a Creative Commons Attribution - NonCommercial - ShareAlike 4.0 International License

UNIVERSITE DE MONTPELLIER
FACULTE DE MEDECINE MONTPELLIER-NIMES

THESE

Pour obtenir le titre de
DOCTEUR EN MEDECINE

Présentée et soutenue publiquement
Par
Marine BOULANGER

le 12/10/2021

**Impact of direct oral anticoagulant therapy on
intraventricular thrombus evaluated with cardiac
magnetic resonance imaging**

Directeur de thèse : Docteur Pierre ROBERT

JURY

Président : Madame le Professeur Florence LECLERCQ

Assesseurs : Monsieur le Docteur Benoit LATTUCA
Monsieur le Docteur Pierre ROBERT
Monsieur le Docteur Benoit AZAIS

UNIVERSITE DE MONTPELLIER
FACULTE DE MEDECINE MONTPELLIER-NIMES

THESE

Pour obtenir le titre de
DOCTEUR EN MEDECINE

Présentée et soutenue publiquement
Par
Marine BOULANGER

le 12/10/2021

**Impact of direct oral anticoagulant therapy on
intraventricular thrombus evaluated with cardiac
magnetic resonance imaging**

Directeur de thèse : Docteur Pierre ROBERT

JURY

Président : Madame le Professeur Florence LECLERCQ

Assesseurs : Monsieur le Docteur Benoit LATTUCA
Monsieur le Docteur Pierre ROBERT
Monsieur le Docteur Benoit AZAIS

ANNEE UNIVERSITAIRE 2020 - 2021

PERSONNEL ENSEIGNANT

Professeurs Honoraires

ALBAT Bernard	BRUNEL Michel	HUMEAU Claude	MIRO Luis
ALLIEU Yves	CANAUD Bernard	JAFFIOL Claude	NAVARRO Maurice
ALRIC Robert	CHAPTAL Paul-André	JANBON Charles	NAVRATIL Henri
ARNAUD Bernard	CIURANA Albert-Jean	JANBON François	OTHONIEL Jacques
ASENCIO Gérard	CLOT Jacques	JARRY Daniel	PAGES Michel
ASTRUC Jacques	COSTA Pierre	JOURDAN Jacques	PEGURET Claude
AUSSILLOUX Charles	D'ATHIS Françoise	KLEIN Bernard	PELISSIER Jacques
AVEROUS Michel	DEMAILLE Jacques	LAFFARGUE François	PETIT Pierre
AYRAL Guy	DESCOMPS Bernard	LALLEMANT Jean Gabriel	POUGET Régis
BAILLAT Xavier	DIMEGLIO Alain	LAMARQUE Jean-Louis	PUJOL Henri
BALDET Pierre	DUBOIS Jean Bernard	LAPEYRIE Henri	RABISCHONG Pierre
BALDY-MOULINIER Michel	DUJOLS Pierre	LEROUX Jean-Louis	RAMUZ Michel
BALMES Jean-Louis	DUMAS Robert	LESBROS Daniel	REBOUL Jean
BANSARD Nicole	DUMAZER Romain	LOPEZ François Michel	RIEU Daniel
BAYLET René	ECHENNE Bernard	LORIOT Jean	ROCHEFORT Henri
BILLIARD Michel	FABRE Serge	LOUBATIERES Marie Madeleine	ROUANET DE VIGNE LAVIT Jean Pierre
BLARD Jean-Marie	FREREBEAU Philippe	MAGNAN DE BORNIER Bernard	SAINT AUBERT Bernard
BLAYAC Jean Pierre	GALIFER René Benoît	MARTY ANE Charles	SANCHO-GARNIER Hélène
BLOTMAN Francis	GODLEWSKI Guilhem	MARY Henri	SANY Jacques
BONNEL François	GRASSET Daniel	MATHIEU-DAUDE Pierre	SEGNARBIEUX François
BOURGEOIS Jean-Marie	GUILHOU Jean-Jacques	MEYNADIER Jean	SENAC Jean-Paul
BOUSQUET Jean	GUITER Pierre	MICHEL François-Bernard	SERRE Arlette
BRUEL Jean Michel	HEDON berbard	MION Charles	SOLASSOL Claude
BUREAU Jean-Paul	HERTAULT Jean	MION Henri	VIDAL Jacques
			VISIER Jean Pierre

Professeurs Emérites

ARTUS Jean-Claude	LE QUELLEC Alain
BLANC François	MARES Pierre
BONAFE Alain	MAUDELONDE Thierry
BOULENGER Jean-Philippe	MAURY Michèle
BOURREL Gérard	MESSNER Patrick
BRINGER Jacques	MILLAT Bertrand
CLAUSTRES Mireille	MONNIER Louis
DAURES Jean-Pierre	MOURAD Georges
DAUZAT Michel	PREFAUT Christian
DAVY Jean-Marc	PUJOL Rémy
DEDET Jean-Pierre	RIBSTEIN Jean
ELEDJAM Jean-Jacques	SCHVED Jean-François
GROLLEAU RAOUX Robert	SULTAN Charles
GUERRIER Bernard	TOUCHON Jacques
GUILLOT Bernard	UZIEL Alain
JONQUET Olivier	VOISIN Michel
LANDAIS Paul	ZANCA Michel
LARREY Dominique	

Docteurs Emérites

PRAT Dominique
PUJOL Joseph

ANNEE UNIVERSITAIRE 2020 - 2021

PERSONNEL ENSEIGNANT

Professeurs des Universités - Praticiens Hospitaliers

PU-PH de classe exceptionnelle

ALRIC Pierre	Chirurgie vasculaire ; médecine vasculaire (option chirurgie vasculaire)
BACCINO Eric	Médecine légale et droit de la santé
BASTIEN Patrick	Parasitologie et mycologie
BEREGI Jean-Paul	Radiologie et imagerie médicale
BLAIN Hubert	Médecine interne ; gériatrie et biologie du vieillissement, médecine générale, addictologie
BOULOT Pierre	Gynécologie-obstétrique ; gynécologie médicale
CAPDEVILA Xavier	Anesthésiologie-réanimation et médecine péri-opératoire
CHAMMAS Michel	Chirurgie orthopédique et traumatologique
COLSON Pascal	Anesthésiologie-réanimation et médecine péri-opératoire
COMBE Bernard	Rhumatologie
COSTES Valérie	Anatomie et cytologie pathologiques
COTTALORDA Jérôme	Chirurgie infantile
COUBES Philippe	Neurochirurgie
COURTET Philippe	Psychiatrie d'adultes ; addictologie
CRAMPETTE Louis	Oto-rhino-laryngologie
CRISTOL Jean Paul	Biochimie et biologie moléculaire
CYTEVAL Catherine	Radiologie et imagerie médicale
DE LA COUSSAYE Jean Emmanuel	Médecine d'urgence
DE WAZIERES Benoît	Médecine interne ; gériatrie et biologie du vieillissement, médecine générale, addictologie
DELAPORTE Eric	Maladies infectieuses ; maladies tropicales
DEMOLY Pascal	Pneumologie ; addictologie
DOMERGUE Jacques	Chirurgie viscérale et digestive

DUFFAU Hugues	Neurochirurgie
ELIAOU Jean François	Immunologie
FABRE Jean Michel	Chirurgie viscérale et digestive
FRAPIER Jean-Marc	Chirurgie thoracique et cardiovasculaire
HAMAMAH Samir	Biologie et Médecine du développement et de la reproduction ; gynécologie médicale
HERISSON Christian	Médecine physique et de réadaptation
JABER Samir	Anesthésiologie-réanimation et médecine péri-opératoire
JEANDEL Claude	Médecine interne ; gériatrie et biologie du vieillissement, médecine générale, addictologie
JORGENSEN Christian	Thérapeutique ; médecine d'urgence ; addictologie
KOTZKI Pierre Olivier	Biophysique et médecine nucléaire
LABAUGE Pierre	Neurologie
LEFRANT Jean-Yves	Anesthésiologie-réanimation et médecine péri-opératoire
LEHMANN Sylvain	Biochimie et biologie moléculaire
LUMBROSO Serge	Biochimie et Biologie moléculaire
MERCIER Jacques	Physiologie
MEUNIER Laurent	Dermato-vénéréologie
MONDAIN Michel	Oto-rhino-laryngologie
MORIN Denis	Pédiatrie
PAGEAUX Georges-Philippe	Gastroentérologie ; hépatologie ; addictologie
PUJOL Pascal	Biologie cellulaire
QUERE Isabelle	Chirurgie vasculaire ; médecine vasculaire (option médecine vasculaire)
RENARD Eric	Endocrinologie, diabète et maladies métaboliques ; gynécologie médicale
REYNES Jacques	Maladies infectieuses, maladies tropicales
RIPART Jacques	Anesthésiologie-réanimation et médecine péri-opératoire
ROUANET Philippe	Cancérologie ; radiothérapie
SOTTO Albert	Maladies infectieuses ; maladies tropicales
TAOUREL Patrice	Radiologie et imagerie médicale

TOUITOU Isabelle	Génétique
VANDE PERRE Philippe	Bactériologie-virologie ; hygiène hospitalière
YCHOU Marc	Cancérologie ; radiothérapie

PU-PH de 1^{re} classe

AGUILAR MARTINEZ Patricia	Hématologie ; transfusion
ASSENAT Éric	Gastroentérologie ; hépatologie ; addictologie
AVIGNON Antoine	Nutrition
AZRIA David	Cancérologie ; radiothérapie
BAGHDADLI Amaria	Pédopsychiatrie ; addictologie
BLANC Pierre	Gastroentérologie ; hépatologie ; addictologie
BORIE Frédéric	Chirurgie viscérale et digestive
BOURDIN Arnaud	Pneumologie ; addictologie
CAMBONIE Gilles	Pédiatrie
CAMU William	Neurologie
CANOVAS François	Anatomie
CAPTIER Guillaume	Anatomie
CARTRON Guillaume	Hématologie ; transfusion
CAYLA Guillaume	Cardiologie
CHANQUES Gérald	Anesthésiologie-réanimation et médecine péri-opératoire
CORBEAU Pierre	Immunologie
COULET Bertrand	Chirurgie orthopédique et traumatologique
CUVILLON Philippe	Anesthésiologie-réanimation et médecine péri-opératoire
DADURE Christophe	Anesthésiologie-réanimation et médecine péri-opératoire
DAUVILLIERS Yves	Physiologie
DE TAYRAC Renaud	Gynécologie-obstétrique, gynécologie médicale
DE VOS John	Histologie, embryologie et cytogénétique

DEMARIA Roland	Chirurgie thoracique et cardio-vasculaire
DEREURE Olivier	Dermatologie - vénéréologie
DROUPY Stéphane	Urologie
DUCROS Anne	Neurologie
DUPEYRON Arnaud	Médecine physique et de réadaptation
FESLER Pierre	Médecine interne ; gériatrie et biologie du vieillissement, médecine générale, addictologie
GARREL Renaud	Oto-rhino-laryngologie
GENEVIEVE David	Génétique
GUILLAUME Sébastien	Psychiatrie d'adultes ; addictologie
GUIU Boris	Radiologie et imagerie médicale
HAYOT Maurice	Physiologie
HOUEDE Nadine	Cancérologie ; radiothérapie
KLOUCHE Kada	Médecine intensive-réanimation
KOENIG Michel	Génétique
KOUYOUMDJIAN Pascal	Chirurgie orthopédique et traumatologique
LAFFONT Isabelle	Médecine physique et de réadaptation
LAVABRE-BERTRAND Thierry	Histologie, embryologie et cytogénétique
LAVIGNE Jean-Philippe	Bactériologie-virologie ; hygiène hospitalière
LE MOING Vincent	Maladies infectieuses ; maladies tropicales
LECLERCQ Florence	Cardiologie
MARIANO-GOULART Denis	Biophysique et médecine nucléaire
MATECKI Stéfan	Physiologie
MORANNE Olivier	Néphrologie
MOREL Jacques	Rhumatologie
NAVARRO Francis	Chirurgie viscérale et digestive
NOCCA David	Chirurgie viscérale et digestive
PASQUIE Jean-Luc	Cardiologie



PERNEY Pascal	Médecine interne ; gériatrie et biologie du vieillissement, médecine générale, addictologie
PRUDHOMME Michel	Anatomie
PUJOL Jean Louis	Pneumologie ; addictologie
PURPER-OUAKIL Diane	Pédopsychiatrie ; addictologie
ROGER Pascal	Anatomie et cytologie pathologiques
TRAN Tu-Anh	Pédiatrie
VERNHET Hélène	Radiologie et imagerie médicale

PU-PH de 2ème classe

BOURGIER Céline	Cancérologie; radiothérapie
CANAUD Ludovic	Chirurgie vasculaire ; médecine vasculaire (option chirurgie vasculaire)
CAPDEVIELLE Delphine	Psychiatrie d'Adultes ; addictologie
CLARET Pierre-Géraud	Médecine d'urgence
COLOMBO Pierre-Emmanuel	Cancérologie ; radiothérapie
COSTALAT Vincent	Radiologie et imagerie médicale
DAIEN Vincent	Ophthalmologie
DORANDEU Anne	Médecine légale et droit de la santé
FAILLIE Jean-Luc	Pharmacologie fondamentale ; pharmacologie clinique ; addictologie
FUCHS Florent	Gynécologie-obstétrique ; gynécologie médicale
GABELLE DELOUSTAL Audrey	Neurologie
GAUJOUX Viala Cécile	Rhumatologie
GODREUIL Sylvain	Bactériologie-virologie ; hygiène hospitalière
GUILPAIN Philippe	Médecine Interne, gériatrie et biologie du vieillissement; addictologie
HERLIN Christian	Chirurgie plastique, reconstructrice et esthétique, brûlologie
IMMEDIATO DAIEN Claire	Rhumatologie
JACOT William	Cancérologie ; Radiothérapie
JEZIORSKI Eric	Pédiatrie

JUNG Boris	Médecine intensive-réanimation
KALFA Nicolas	Chirurgie infantile
LACHAUD Laurence	Parasitologie et mycologie
LALLEMANT Benjamin	Oto-rhino-laryngologie
LE QUINTREC DONNETTE Moglie	Néphrologie
LETOUZEY Vincent	Gynécologie-obstétrique ; gynécologie médicale
LONJON Nicolas	Neurochirurgie
LOPEZ CASTROMAN Jorge	Psychiatrie d'Adultes ; addictologie
LUKAS Cédric	Rhumatologie
MENJOT de CHAMPFLEUR Nicolas	Radiologie et imagerie médicale
MILLET Ingrid	Radiologie et imagerie médicale
MURA Thibault	Biostatistiques, informatique médicale et technologies de la communication
NAGOT Nicolas	Biostatistiques, informatique médicale et technologies de la communication
OLIE Emilie	Psychiatrie d'adultes; addictologie
PANARO Fabrizio	Chirurgie viscérale et digestive
PARIS Françoise	Biologie et médecine du développement et de la reproduction ; gynécologie médicale
PELLESTOR Franck	Histologie, embryologie et cytogénétique
PEREZ MARTIN Antonia	Chirurgie vasculaire ; médecine vasculaire (option médecine vasculaire)
POUDEROUX Philippe	Gastroentérologie ; hépatologie ; addictologie
RIGAU Valérie	Anatomie et cytologie pathologiques
RIVIER François	Pédiatrie
ROSSI Jean François	Hématologie ; transfusion
ROUBILLE François	Cardiologie
SEBBANE Mustapha	Médecine d'urgence
SIRVENT Nicolas	Pédiatrie
SOLASSOL Jérôme	Biologie cellulaire
STOEBNER Pierre	Dermato-vénéréologie



SULTAN Ariane	Nutrition
THOUVENOT Éric	Neurologie
THURET Rodolphe	Urologie
TUAILLON Edouard	Bactériologie-virologie; hygiène hospitalière
VENAIL Frédéric	Oto-rhino-laryngologie
VILLAIN Max	Ophthalmologie
VINCENT Denis	Médecine interne ; gériatrie et biologie du vieillissement, médecine générale, addictologie
VINCENT Thierry	Immunologie
WOJTUSCISZYN Anne	Endocrinologie-diabétologie-nutrition

PROFESSEURS DES UNIVERSITES

1^{re} classe :

COLINGE Jacques (Cancérologie, Signalisation cellulaire et systèmes complexes)
LAOUDJ CHENIVESSE Dalila (Biochimie et biologie moléculaire)
VISIER Laurent (Sociologie, démographie)

PROFESSEURS DES UNIVERSITES - Médecine générale

1^{re} classe :

LAMBERT Philippe
AMOUYAL Michel

PROFESSEURS ASSOCIES - Médecine Générale

CLARY Bernard
DAVID Michel
GARCIA Marc

PROFESSEURS ASSOCIES - Médecine

BESSIS Didier (Dermato-vénérologie)

MEUNIER Isabelle (Ophtalmologie)

MULLER Laurent (Anesthésiologie-réanimation et médecine péri-opératoire)

PERRIGAULT Pierre-François (Anesthésiologie-réanimation et médecine péri-opératoire)

QUANTIN Xavier (Pneumologie)

ROUBERTIE Agathe (Pédiatrie)

VIEL Eric (Soins palliatifs et traitement de la douleur)

ANNEE UNIVERSITAIRE 2020 - 2021

PERSONNEL ENSEIGNANT

Maîtres de Conférences des Universités - Praticiens Hospitaliers

MCU-PH Hors classe - Echelon Exceptionnel

RICHARD Bruno	Médecine palliative
SEGONDY Michel	Bactériologie-virologie ; hygiène hospitalière

MCU-PH Hors classe

BADIOU Stéphanie	Biochimie et biologie moléculaire
BOULLE Nathalie	Biologie cellulaire
CACHEUX-RATABOUL Valère	Génétique
CARRIERE Christian	Bactériologie-virologie ; hygiène hospitalière
CHARACHON Sylvie	Bactériologie-virologie ; hygiène hospitalière
FABBRO-PERAY Pascale	Epidémiologie, économie de la santé et prévention
GIANCILY-BLAIZOT Muriel	Hématologie ; transfusion

MCU-PH de 1^{re} classe

BERTRAND Martin	Anatomie
BOUDOUSQ Vincent	Biophysique et médecine nucléaire
BRET Caroline	Hématologie biologique
BROUILLET Sophie	Biologie et médecine du développement et de la reproduction ; gynécologie médicale
COSSEE Mireille	Génétique
GIRARDET-BESSIS Anne	Biochimie et biologie moléculaire
LAVIGNE Géraldine	Hématologie ; transfusion
LESAGE François-Xavier	Médecine et Santé au Travail
MARTRILLE Laurent	Médecine légale et droit de la santé
MATHIEU Olivier	Pharmacologie fondamentale ; pharmacologie clinique ; addictologie

MOUZAT Kévin	Biochimie et biologie moléculaire
PANABIERES Catherine	Biologie cellulaire
RAVEL Christophe	Parasitologie et mycologie
SCHUSTER-BECK Iris	Physiologie
STERKERS Yvon	Parasitologie et mycologie
THEVENIN-RENE Céline	Immunologie
 <u>MCU-PH de 2^{ème} classe</u>	
BERGOUX Anne	Génétique
CHIRIAC Anca	Immunologie
DE JONG Audrey	Anesthésiologie-réanimation et médecine péri-opératoire
DU THANH Aurélie	Dermato-vénéréologie
FITENI Frédéric	Cancérologie ; radiothérapie
GOUZI Farès	Physiologie
HERRERO Astrid	Chirurgie viscérale et digestive
HUBERLANT Stéphanie	Gynécologie-obstétrique ; Gynécologie médicale
KUSTER Nils	Biochimie et biologie moléculaire
MAKINSON Alain	Maladies infectieuses, Maladies tropicales
PANTEL Alix	Bactériologie-virologie ; hygiène hospitalière
PERS Yves-Marie	Thérapeutique; addictologie
ROUBILLE Camille	Médecine interne ; gériatrie et biologie du vieillissement ; addictologie
SZABLEWSKY	Anatomie et cytologie pathologiques

Maîtres de Conférences des Universités - Médecine Générale

MCU-MG de 1^{re} classe

COSTA David

OUDE ENGBERINK Agnès

MCU-MG de 2^{ème} classe

FOLCO-LOGNOS Béatrice

CARBONNEL François

Maîtres de Conférences associés - Médecine Générale

CAMPAGNAC Jérôme

LOPEZ Antonio

MILLION Elodie

PAVAGEAU Sylvain

REBOUL Marie-Catherine

SERAYET Philippe

ANNEE UNIVERSITAIRE 2020 - 2021

PERSONNEL ENSEIGNANT

Maitres de Conférences des Universités

Maitres de Conférences hors classe

BADIA Eric	Sciences biologiques fondamentales et cliniques
CHAZAL Nathalie	Biologie cellulaire

Maitres de Conférences de classe normale

BECAMEL Carine	Neurosciences
BERNEX Florence	Physiologie
CHAUMONT-DUBEL Séverine	Sciences du médicament et des autres produits de santé
DELABY Constance	Biochimie et biologie moléculaire
GUGLIELMI Laurence	Sciences biologiques fondamentales et cliniques
HENRY Laurent	Sciences biologiques fondamentales et cliniques
HERBET Guillaume	Neurosciences
LADRET Véronique	Mathématiques appliquées et applications des mathématiques
LAINE Sébastien	Sciences du Médicament et autres produits de santé
LE GALLIC Lionel	Sciences du médicament et autres produits de santé
LOZZA Catherine	Sciences physico-chimiques et technologies pharmaceutiques
MAIMOUN Laurent	Sciences physico-chimiques et ingénierie appliquée à la santé
MOREAUX Jérôme	Science biologiques, fondamentales et cliniques
MORITZ-GASSER Sylvie	Neurosciences
MOUTOT Gilles	Philosophie
PASSERIEUX Emilie	Physiologie
RAMIREZ Jean-Marie	Histologie
RAYNAUD Fabrice	Sciences du Médicament et autres produits de santé
TAULAN Magali	Biologie Cellulaire

ANNEE UNIVERSITAIRE 2020 - 2021

PERSONNEL ENSEIGNANT

Praticiens Hospitaliers Universitaires

BARATEAU Lucie	Physiologie
BASTIDE Sophie	Epidémiologie, économie de la santé et prévention
CAZAUBON Yoann	Pharmacologie fondamentale ; pharmacologie clinique ; addictologie
DAGNEAUX Louis	Chirurgie orthopédique et traumatologique
DUFLOS Claire	Biostatistiques, informatique médicale et technologies de la communication
GOULABCHAND Radjiv	Médecine interne ; gériatrie et biologie du vieillissement ; addictologie
LATTUCA Benoit	Cardiologie
MARIA Alexandre	Médecine interne ; gériatrie et biologie du vieillissement ; addictologie
MIOT Stéphanie	Médecine interne ; gériatrie et biologie du vieillissement ; addictologie
SARRABAY Guillaume	Génétique
SOUCHE François-Régis	Chirurgie viscérale et digestive

ANNEE UNIVERSITAIRE 2020 - 2021

PERSONNEL ENSEIGNANT

PH chargés d'enseignements

ABOUKRAT Patrick	BLANCHET Catherine	COROIAN Flavia-Oana	GINIES Patrick
AKKARI Mohamed	BLATIERE Véronique	COUDRAY Sarah	GRECO Frédéric
ALRIC Jérôme	BOBBIA Xavier	CRANSAC Frédéric	GUEDJ Anne Marie
AMEDRO Pascal	BOGE Gudrun	CUNTZ Danielle	GUYON Gaël
AMOUREUX Cyril	BOURRAIN Jean Luc	DARDALHON Brigitte	HENRY Vincent
ANTOINE Valéry	BOUYABRINE Hassan	DAVID Aurore	JAMMET Patrick
ARQUIZAN Caroline	BRINGER-DEUTSCH Sophie	DE BOUTRAY Marie	JEDRYKA François
ATTALIN Vincent	BRINGUIER BRANCHEREAU Sophie	DE LA TRIBONNIÈRE Xavier	JREIGE Riad
AYRIGNAC Xavier	BRISOT Dominique	DEBIEN Blaise	KINNE Mélanie
BADR Maliha	BRONER Jonathan	DELPONT Marion	LABARIAS Coralie
BAIS Céline	CADE Stéphane	DENIS Hélène	LACAMBRE Mathieu
BARBAR Saber Davide	CAIMMI Davide Paolo	DEVILLE de PERIERE Gilles	LANG Philippe
BASSET Didier	CARR Julie	DJANIKIAN Flora	LAZERGES Cyril
BATIFOL Dominique	CARTIER César	DONNADIEU-RIGOLE Hélène	LE GUILLOU Cédric
BATTISTELLA Pascal	CASPER Thierry	FAIDHERBE Jacques	LEGLISE Marie Suzanne
BAUCHET Luc	CASSINOTTO Christophe	FATTON Brigitte	LOPEZ Régis
BENEZECH Jean-Pierre	CATHALA Philippe	FAUCHERRE Vincent	LUQUIENS Amandine
BENNYS Karim	CAZABAN Michel	FILLERON Anne	MANZANERA Cyril
BERNARD Nathalie	CHARBIT Jonathan	FITENI Frédéric	MARGUERITTE Emmanuel
BERTCHANSKY Ivan	CHEVALLIER Thierry	FOURNIER Philippe	MARTIN Lucille
BIBOULET Philippe	CHEVALLIER-MICHAUD Josyane	GAILLARD Nicolas	MATTATIA Laurent
BIRON-ANDREANI Christine	COLIN Olivier	GALMICHE Sophie	MEROUEH Fadi
BLANC Brigitte	CONSEIL Mathieu	GENY Christian	MEYER Pierre
BLANCHARD Sylvie	CORBEAU Catherine	GERONIMI Laetitia	MILESI Christophe

MORAU Estelle	SEGURET Fabienne
MOSER Camille	SENESSE Pierre
MOUSTY Eve	SKALLI El Medhi
MOUTERDE Gaël	SOLA Christelle
PANSARD Nicole	SOULLIER Camille
PERNIN Vincent	STOEBNER DELBARRE Anne
PERRIGAULT Pierre François	TEOT Luc
PEYRON Pierre-Antoine	THIRION Marina
PICARD Eric	VACHIERY-LAHAYE Florence
PICOT Marie Christine	VERNES Eric
PIERONI Laurence	VINCENT Laure
POQUET Hélène	WAGNER Laurent
PUJOL Sarah-Lise	ZERKOWSKI Laetitia
PUPIER Florence	
QUANTIN Xavier	
RAFFARD Laurence	
RAPIDO Francesca	
RIBRAULT Alice	
RICHAUD-MOREL Brigitte	
RIDOLFO Jérôme	
RIPART Sylvie	
RONGIERES Michel	
ROULET Agnès	
RUBENOVITCH Josh	
SANTONI Fannie	
SASSO Milène	
SCHULDINER Sophie	

REMERCIEMENTS

Au Professeur LECLERCQ pour m'avoir épaulée sur cette thèse depuis l'élaboration du sujet jusqu'à la dernière relecture.

A Pierre pour m'avoir grandement aidée pour l'inclusion surtout lorsque j'étais à l'autre bout du monde.

A Myriam pour tes relectures, tes conseils et la correction de mon anglais un peu bancal.

A Benoît AZAIS pour avoir rendu l'IRM un peu moins abstraite.

A Adeham pour m'avoir aidé à pister les thrombus à Nîmes.

A mes co-internes pour avoir rendu mes stages moins difficiles que ce soit à Montpellier, à Perpignan, à Nîmes ou à la Réunion.

A mes proches,

Tout d'abord à ma mère sans qui rien n'aurait été possible. Les mots ne sont pas suffisants pour t'exprimer mon amour et ma reconnaissance. Tu as vécu ces dures années de médecine avec moi, jours et nuits, dans les rires et les pleurs. Je ne serai pas en train d'écrire ces lignes sans toi à mes côtés.

A Kévin, pour l'amour et le soutien indéfectibles toutes ses années pour la thèse comme dans la vie malgré mes doutes et mon stress maladif, pour me nourrir tous les jours, pour les allers retours à des heures improbables week-end et jours fériés compris, pour tous les fous rires, les voyages.... Tout simplement merci d'être toi.

A mon frère, pour les bonnes parties de jeux du dimanche après-midi au milieu de cours d'histoire et de charabia physique passionnant.

A Cécile et Léonce pour les plats que je ne suis pas près d'oublier de sitôt.

A Manuela pour tes encouragements, bon courage pour la suite, ton tour arrivera plus vite que tu ne le penses !

SOMMAIRE

<i>Abstract</i>	23
<i>Abbreviations</i>	25
<i>Background:</i>	26
<i>Methods</i>	28
<i>Results</i>	31
<i>Discussion</i>	38
<i>Conclusion</i>	42
<i>Références</i>	43
<i>Annexe: Institutional Review Board</i>	45
<i>Résumé</i>	48

Abstract

BACKGROUND: Left ventricular thrombus (LVT) observed in cardiomyopathy is associated with risks for systemic embolism, morbidity and mortality. Right ventricular thrombus (RVT) is rare but with potential risk of acute pulmonary embolism. Current first-line therapy of intraventricular thrombus (IVT) is vitamin K antagonists (VKA) but with numerous limits regarding efficacy and safety.

OBJECTIVE: The purpose of this study was to evaluate the efficacy of direct oral anticoagulants (DOA) therapy on IVT resolution with cardiac magnetic resonance (CMR) evaluation.

METHODS: From June 2018 to September 2021, we included patients with IVT diagnosis on transthoracic echography, CMR and/or Computed Tomography (CT) scan and treated with DOA in Montpellier and Nîmes University Hospital. Patients with CMR contra-indications or treated with VKA were excluded. The primary end point was the resolution of IVT on CMR at 6 months follow up and secondary end point included mortality, thromboembolic and bleeding events during the same follow-up.

RESULTS: Thirty-four patients with a mean age of 58 ± 16 years and a majority of male (n=30, 88.2%) were enrolled including 32 LVT and 2 RVT. Ischemic cardiomyopathy was the most common aetiology (n = 30, 88.2%) with mainly patients admitted for anterior STEMI (n=20, 58.8%). RVT was found exclusively in dilated cardiomyopathy with biventricular dysfunction. Patients were treated with apixaban (55.9%), dabigatran (32.4%) or rivaroxaban (11.7%). Antiplatelet therapy was used in 88.2% of the population. IVT resolution was observed at follow-up CMR in 25 (73.5%) patients, 23 (71.9%) LVT and

all RVT. Stroke occurred in one patient (2.9%) and severe bleeding (BARC \geq 3) in one patient (2.9%) at 6 months follow-up.

CONCLUSION: In this prospective, observational and multicenter pilot study, DOA therapy was associated with IVT resolution in 73.5% of patients with serious events observed in 5.8% of patients. The preliminary results suggests that DOA are effective in treating IVT with few ischemic and bleeding events. Larger observational data and randomized studies with comparison with VKA will be required to confirm these results.

KEY WORDS: intraventricular thrombus, direct oral anticoagulants, vitamin K antagonists, echocardiography, cardiac magnetic resonance

Abbreviations

AF = atrial fibrillation

BARC = Bleeding Academic Research Consortium

CMR = cardiac magnetic resonance

CT = computed tomography

DOA = direct oral anticoagulants

INR = international normalized ratio

IVT = intraventricular thrombus

LVEF = left ventricular ejection fraction

LVT = left ventricular thrombus

MACE = major adverse cardiovascular events

PCI = primary percutaneous coronary intervention

RVT = right ventricular thrombus

STEMI = ST elevation myocardial infarction

TTE = transthoracic echography

VKA = vitamin K antagonists

VTE = venous thromboembolism

Background:

Left ventricular thrombus (LVT) is a common complication of cardiomyopathy with systolic dysfunction or of ST-elevation myocardial infarction (STEMI), particularly anterior, and is associated with substantial risks of systemic embolism, morbidity and mortality (1).

Right ventricular thrombus (RVT) is rare but with potential risk of acute pulmonary embolism. While the incidence of LVT after acute myocardial infarction declined related to improvement of reperfusion strategies, they were increasingly observed in chronic ischemic or non-ischemic cardiomyopathy (2).

Current guidelines recommend the use of vitamin K antagonists (VKA) for up to 6 months in case of LVT after acute myocardial infarction but with a low level of evidence (3,4).

Conversely, no specific recommendations regarding duration of anticoagulant therapy are available for LVT complicating chronic dilated cardiomyopathy (5). Several case reports or meta-analysis of case reports of successful resolution of LVT with direct oral anticoagulants (DOA) were reported (6–8). A recent meta-analysis including 6 retrospective studies enrolling 837 patients showed that DOA and VKA have similar efficacy and safety in treating LVT, prompting the inference that DOA are the possible alternatives of VKA in LVT therapy (9). However, a multicenter, retrospective study showed a higher risk of systemic embolism events with DOA compared with warfarin (10). No randomized or large prospective study comparing DOA and VKA is currently available.

Warfarin is limited by the need for frequent international normalized ratio (INR) monitoring with narrow therapeutic range, multiple drug interactions or food restrictions. Time in therapeutic range (TTR) is used to calculate the percentage of time a patient on VKA spent in the therapeutic range using the INR. In European recommendation, VKA are considered effective and relatively safe when TTR is above 70% (11). In a systematic review of studies measuring anticoagulation control, the percentage of TTR was

63.5% (12). Conversely, DOA do not require monitoring, have proved their non-inferiority to warfarin in the prevention of thromboembolism in patients with non-valvular atrial fibrillation (AF) and demonstrated important decrease of cerebral bleedings compared to VKA in AF in randomized trials (13).

Regarding intraventricular thrombus (IVT) imaging, transthoracic echography (TTE) and cardiac magnetic resonance (CMR) are commonly used. TTE uses morphological identification, CMR can identify IVT based on its morphology and avascular tissue characteristics (14,15). TTE is more accessible and is usually the first test used for IVT screening in cardiomyopathy and after acute myocardial infarction however lower sensitivity of TTE was reported compared to CMR imaging (14).

The primary objective of our study was to evaluate the efficacy of DOA therapy on IVT resolution with CMR evaluation.

Methods

Study design and population

The study was a prospective, observational and multicenter pilot study conducted in Montpellier and Nîmes University Hospitals from June 2018 to September 2021.

All patients with ischemic or non-ischemic cardiomyopathy with diagnosis of IVT on TTE, CMR or CT scan were screened and those treated with DOA (full or low dose) were included. Patients with CMR contra-indications, treated with VKA or low-molecular weight heparin were excluded.

The patients' baseline characteristics include the age and gender, cardiovascular risk factors, the past medical history of ischemic event, atrial fibrillation, or stroke, the long-term use of antiplatelet or anticoagulation therapy (*Table 1*).

Ethics regulation

All patients were given full information. We obtained oral consent from the patients, specifying that the management was not modified by the protocol, including the follow-up by CMR.

The study was conducted according to the declaration of Helsinki principles and approved by local ethics committee (International review board number: IRB-MTP_2021_04-202100778).

TTE and MRI assessment

Patients with IVT on TTE, CMR or CT scan were screened for the study.

Left ventricular thrombus (LVT) was defined on TTE with or without contrast as an echo dense mass in the left ventricular cavity with margins distinct from ventricular endocardium and distinguishable from papillary muscles, chordae, trabeculations, or

technical artifact that was seen clearly throughout the cardiac cycle in at least two different echocardiographic views. Additionally, this mass had to be contiguous with the endocardium in an area of abnormal wall motion. The thrombus size was measured with the largest 2-dimensional area available on the index echocardiogram. Echocardiographic data included the location, the morphologic characteristics and mobility of thrombus. Left ventricular aneurysm was defined as an akinetic or dyskinetic bulge interrupting the normal ventricular contour during diastole and systole.

Thrombus was identified on CMR as left ventricular mass with post-contrast inversion-recovery characteristics consistent with avascular tissue. Thrombus appeared as a low signal intensity mass surrounded by high-signal intensity structures such as intracavitary blood and/or hyper enhanced myocardial infarction. 3D acquisition was used, when possible, otherwise 2D protocol with 3 sequential slices.

Left ventricular ejection fraction were assessed on both imaging modalities.

Right ventricular thrombus was analyzed in the same way as left ventricular thrombus.

Primary endpoint

The primary endpoint was IVT resolution on CMR imaging at 6 months follow up.

The resolution of IVT corresponds to a complete disappearance of IVT on follow-up CMR.

Secondary endpoints

Secondary endpoints included IVT reduction on CMR, comparison between TTE and CMR imaging for IVT resolution, major ischemic (stroke, myocardial infarction, systemic embolism), major bleedings (BARC ≥ 3) and death during follow-up.

Reduction of IVT correspond to a regression of IVT largest diameter of 30% or more to eliminate a measurement variation. If any doubt, a review by a second radiologist was performed.

Data assessment and follow-up

Data were assessed from medical records and follow-up was performed by cardiologist and radiologist from both centers. Patients were contacted by telephone for ischemic and bleeding events.

Statistical analysis

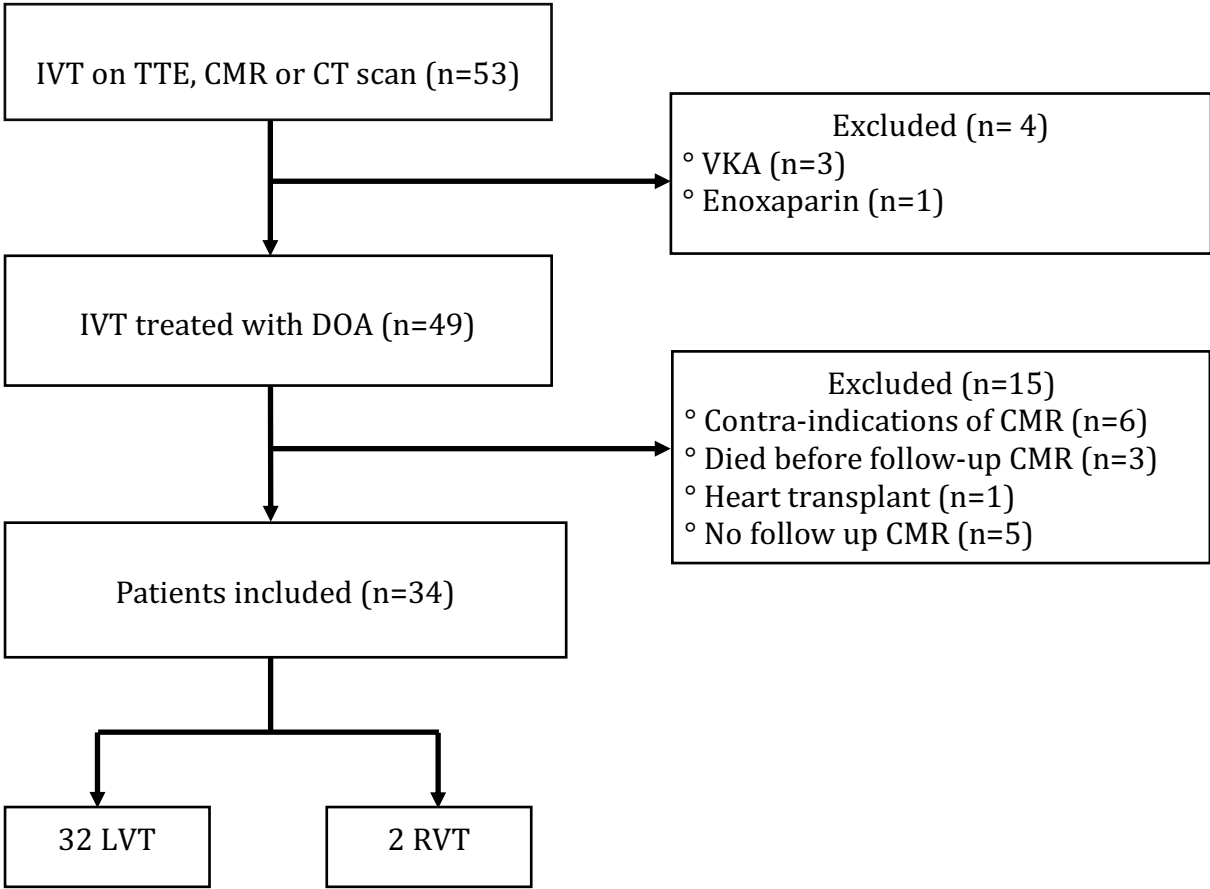
Values are reported as mean \pm SD or median (interquartile range) for continuous variables and as number (%) of patients for categorical variables. A Kappa statistic was calculated to measure the agreement between follow-up TTE and CMR for IVT detection.

Results

Characteristics of the patients

Of the 53 patients with the diagnosis of IVT during the study, 34 were finally included in this analysis with 32 LVT and 2 RVT (Figure 1).

Figure 1: Flow Chart



Baseline characteristics of the patients with IVT treated with DOA are shown in Table 1.

Among the patients included, there were 30 (88.2%) men and mean age was 58 ± 16 years.

Regarding cardiovascular risk factors, there were 4 (11.8%) patients with diabetes (1 (2.9%) with diabetes type 2 and 3 (8.8%) with diabetes type 1), 5 (14.7%) had hypertension, 16 (47.1%) were active smokers, median BMI was 24 kg/m² (22-27).

Ischemic cardiomyopathy was the most common aetiology (n=30, 88.2%) with mainly patients admitted for anterior STEMI (n=20, 58.8%) when the IVT was diagnosed. 62.5% of patients with LVT had anterior STEMI. Eight (23.5%) patients had anterior chronic infarction (more than a week) and 2 (5.9%) patients had ischemic disease without infarction (multivessel coronary artery disease with left ventricular dysfunction). The 2 patients with RVT had a dilated cardiomyopathy with biventricular dysfunction. 1 patient had endomyocardial fibrosis due to Churg and Strauss disease. In 5 patients, IVT was diagnosed following an initial presentation of stroke.

Table 1: Baseline characteristics of patients

Age, yrs	58 ± 16
Male	30 (88.2)
Body mass index, kg/m²	24 (22-27)
Active smoking	16 (47.1)
Hypertension	5 (14.7)
Diabetes	4 (11.8)
Creatinine clearance, ml/min	83 (77-97)
Prior atrial fibrillation	0 (0)
Prior stroke	
- initial presentation of stroke	5 (14.7)
- former stroke	1 (2.9)
Prior major bleeding	1 (2.9)
Previous antiplatelet therapy	
- Aspirin	7 (20.6)
- Clopidogrel	1 (2.9)
- Ticagrelor	2 (5.9)

Previous anticoagulant therapy	
- VKA	0 (0)
- DOA	3 (8.8)
Type of cardiomyopathy	
- Ischemic cardiomyopathy	30 (88.2)
Anterior STEMI	20 (58.8)
Anterior chronic infarction	8 (23.5)
Ischemic disease without infarction	2 (5.9)
- Dilated cardiomyopathy	3 (8.8)
- Endomyocardial fibrosis	1 (2.9)
Values are n, mean ± SD, n (%), median (interquartile range)	

TTE and CMR characteristics

There were 25 IVT diagnosed on TTE. Left ventricular ejection fraction (LVEF) was moderately impaired with mean LVEF of $39.5 \pm 11.9\%$. Akinesia of apical segments was the most frequent left ventricular wall motion abnormality (67.6%). Apical IVT was predominant (96%). IVT was mobile in 6 (24.0%) patients and calcified in 1 (4.0%) patient. Contrast TTE has been used 3 times to assist IVT diagnosis. The baseline echocardiographic characteristics are shown in *Table 2*.

Twenty-two CMR were performed to confirm the presence of IVT seen in TTE or to search for IVT in patients at risk. There were 20 (95.2%) apical left ventricular thrombus and 1 (4.8%) right ventricular thrombus. LVEF was more altered than TTE with mean LVEF of $33.9 \pm 13.4\%$. Apical hypokinesia was the most frequent left ventricular motion abnormality (40.9%). The baseline CMR characteristics are shown in *Table 3*.

1 right ventricular thrombus was diagnosed on CT scan.

Table 2 : Baseline Echocardiographic characteristics

TTE	34
Patients with IVT	25 (73.5)
Left ventricular ejection fraction, %	39.5 ± 11.9
Left ventricular wall motion	
- Apical akinesia	23 (67.6)
- Apical hypokinesia	3 (8.8)
- Global hypokinesia	4 (11.8)
Left ventricular aneurysm	4 (11.8)
Ventricular thrombus	
- Largest diameter, mm	26.5 (20-33)
- Apical thrombus	24 (96)
- Mobile thrombus	6 (24)
- Calcified thrombus	1 (4)
Contrast TTE	3 (8.8)
Right ventricular dysfunction	4 (11.8)
Values are n, n (%), mean ± SD, median (interquartile range)	

Table 3: Baseline Cardiac Magnetic Resonance characteristics

CMR	22
Patients with IVT	21 (95.5)
Left ventricular ejection fraction, %	33.9 ± 13.4
Left ventricular wall motion	
- Apical akinesia	8 (36.4)
- Apical hypokinesia	9 (40.9)
- Global hypokinesia	4 (18.2)
- Apical Dyskinesia	1 (4.5)
Left ventricular aneurysm	7 (31.8)
Ventricular thrombus	
- Largest diameter, mm	11 (8-18)
- Apical left ventricular thrombus	20 (95.2)
- Right ventricular thrombus	1 (4.8)
Values are n, n (%), mean ± SD, median (interquartile range)	

Treatment of IVT

Four (11.8%) patients were treated with DOA therapy alone: 2 patients with apixaban 5mg twice daily, 1 patient with dabigatran 150mg twice daily and 1 patient with dabigatran 110mg twice daily. Most patients (16 patients, 47.1%) were treated with anticoagulation together with aspirin and clopidogrel. The most common DOA prescribed was apixaban 5mg twice a day with 14 patients (41.2%) (*Table 4*).

Table 4: Anticoagulation and antiplatelet therapy

Anticoagulation only	4 (11.8)
Anticoagulation + antiplatelet	
- DOA + aspirin	9 (26.5)
- DOA + clopidogrel	3 (8.8)
Anticoagulation + dual antiplatelet therapy	
- DOA + aspirin + clopidogrel	16 (47.1)
- DOA + aspirin + ticagrelor	1 (2.9)
- DOA + aspirin + prasugrel	1 (2.9)
Anticoagulation type	
- Apixaban 2,5mg x2	5 (14.7)
- Apixaban 5mg x2	14 (41.2)
- Rivaroxaban 15mg	3 (8.8)
- Rivaroxaban 20mg	1 (2.9)
- Dabigatran 110mg x2	7 (20.6)
- Dabigatran 150mg x2	4 (11.8)
Values are n (%)	

Thrombus resolution and reduction

IVT resolution was observed in 25 (73.5%) patients with a median time between IVT diagnosis (on TTE, CMR or CT scan) and follow-up CMR of 99 days (interquartile range: 79 to 196 days). The resolution occurred in all RVT and 23 (71.9%) LVT.

In the 9 patients with persistent IVT, 6 patients have a time between diagnosis and follow-up CMR less than 6 months.

Among 7 patients with residual IVT who underwent initial and follow-up CMR, IVT reduction was observed in 4 (57.1%) patients.

CMR vs TTE for detection of IVT

Twenty-seven patients had both follow-up TTE and CMR. IVT disappeared in 18 patients in both tests. In 4 patients, CMR revealed the presence of IVT when it was absent on TTE and 2 patients had IVT on TTE and not on CMR. Kappa statistic for IVT detection was 0.36 which corresponds to a poor agreement.

Cardiovascular events and bleeding

One patient had an ischemic stroke one day following apixaban introduction. Anticoagulant therapy was changed for dabigatran. There was no death or myocardial infarction during the follow-up. Major bleeding (BARC ≥ 3) occurred in 1 (2.9%) patient for whom a transfusion was necessary because of occult bleeding. This patient was treated with apixaban 5mg twice a day associated with aspirin.

Ischemic and bleeding events were not available in 4 patients.

Discussion

IVT resolution was observed at follow-up CMR in 73.5% of patients treated with DOA with rare adverse events (5.8%), one patient presented an ischemic stroke and one patient severe bleeding (BARC \geq 3).

Incidence of LVT from acute myocardial infarction and infarct size have decreased since the introduction of primary percutaneous coronary intervention (PCI) and early reperfusion.

In Driesman et al. (16), the incidence of early LVT after acute anterior myocardial infarction was 15.2% in the era of PCI as opposed to 40% and 28% in the prethrombolytic and thrombolytic eras. Le May et al. (17) found a lower rates with 2.9%. Isolated RVT is rare, most are present with LVT and have been described in association with hypercoagulability states, autoimmune diseases, dilated cardiomyopathy, inferior myocardial infarction and arrhythmogenic right ventricular cardiomyopathy. RVT data are very limited with most case reports (18,19). Despite the few number of patients with RVT in our study, we had resolution of all RVT.

Current guidelines recommend the use of VKA to treat LVT but several case reports of successful resolution of LVT with DOA were reported (6–8). A retrospective observational study found a similar efficacy between VKA and DOA in LVT resolution with 71.5% of resolution with VKA and 70.6% with DOA (20). An observational prospective study of a large cohort of patients found that LVT resolution was better and earlier in the DOA group compared to patients treated with VKA (81% vs 63%) (21). DOA were the first line therapy in our center when IVT was detected, while VKA were reserved to contra-indications of DOA. Use of VKA is declining in favor of DOA regarding numerous limits including the narrow therapeutic index, a slow onset of action, the need for constant monitoring or several drugs' interactions and foods restrictions. The role of DOA for stroke prevention in

AF has been established in randomized studies and registries: rivaroxaban was noninferior to VKA and apixaban was superior to VKA in the prevention of stroke or systemic embolism (22,23). Current guidelines recommend DOA in preference to VKA in this case (Class I; Level of Evidence A) (11). DOA are also used in treatment of acute venous thromboembolism (VTE), prevention of recurrent VTE and prophylaxis in major orthopedic surgery. When the medications were release, the main issue was the lack of reversal agent but there is a specific antidote to dabigatran called idarucizumab (Praxbind®) since 2015 and andexanet alpha (Ondexxya®), an antidote for factor Xa inhibitors apixaban and rivaroxaban, has a conditional marketing authorisation in the European Union since 2019.

European guidelines recommend 6 months of treatment after LVT diagnosis but this strategy was empirical (4). In our study, 6 of 9 patients with residual IVT had a follow-up CMR less than 6months after diagnosis. We can assume that IVT could have disappeared if CMR had been performed at 6 months.

The diagnosis of IVT can be performed by TTE or CMR. TTE was the main test used for IVT detection due to its great accessibility, most CMR were performed to confirm the presence of IVT seen on TTE. Weinsaft et al. (14) reported that noncontrast TTE has a sensitivity of 35%, specificity of 98%, a positive predictive value of 67% and a negative predictive value of 94% when using Delayed Enhancement CMR as the reference for LVT diagnosis. This could explain the small number of patients in our study, IVT would probably have been higher if CMR had been performed systematically in all patients with anterior myocardial infarction.

The agreement between follow-up TTE and CMR for IVT detection was low in our study. Among 27 patients who had both tests, 9 IVT were present including 6 detected on one test but not on the other. This could be explained by insufficient image quality of TTE specially of the apex, the non-systematic use of TTE with contrast or the inter-individual variability

with 4 patients with IVT on CMR and not on TTE or by the long period between the two tests in 2 patients (6 months).

Only 3 TTE with contrast were used to help IVT diagnosis in our study. This may be due to the fact that Sonovue, the ultrasound contrast agent used in our center, was contraindicated in patients with recent acute coronary syndrome or clinically unstable ischemic cardiac disease since 2004 because of 3 cases of adverse events with fatal outcome in patients with underlying severe cardiac disease. Since 2015, the European Medicines Agency removed the contraindications and replaced it with special warnings and precautions for use. Weinsaft et al. (14) showed that contrast TTE improved sensitivity nearly two-fold (64%). Based on these data, contrast TTE could be a good test for IVT screening particularly in patients with anterior myocardial infarction.

Limitations:

This study has several limitations.

This is a pilot study with low number of patients, our objective was to include prospectively about one hundred patients. The number of patients was insufficient to extrapolate our results but they are encouraging regarding both efficacy and safety of DOA for resolution of IVT.

The study gave no information regarding duration of anticoagulation therapy needed after resolution of thrombus. This follow-up of 6 months is relatively short but efficacy of DOA is probably optimal at this end point.

The diagnosis was principally based on echocardiography which has a low sensitivity and CMR and contrast TTE were not routinely used to detect IVT in patients at risk, IVT may be missed.

It was an observational study. Randomized prospective trials are needed to determine the real incidence of IVT with the modern reperfusion strategy of STEMI as effectiveness of DOA compared to VKA for thrombus resolution.

Conclusion

In this prospective pilot, observational and multicenter study, DOA therapy was associated with the complete resolution of the IVT in 73.5% with severe events observed in 5.8% of patients. The preliminary results suggest that DOA are effective in treating IVT with few ischemic and bleeding events.

Larger observational data and randomized studies with comparison with VKA will be required to confirm these results.

Références

1. Lattuca B, Bouziri N, Kerneis M, Portal J-J, Zhou J, Hauguel-Moreau M, et al. Antithrombotic Therapy for Patients With Left Ventricular Mural Thrombus. *J Am Coll Cardiol.* avr 2020;75(14):1676-85.
2. Habash et Vallurupalli - 2017 - Challenges in management of left ventricular thromb.pdf.
3. O’Gara PT, Kushner FG, Ascheim DD, Casey DE, Chung MK, de Lemos JA, et al. 2013 ACCF/AHA Guideline for the Management of ST-Elevation Myocardial Infarction. *J Am Coll Cardiol.* janv 2013;61(4):e78-140.
4. Ibanez B, James S, Agewall S, Antunes MJ, Bucciarelli-Ducci C, Bueno H, et al. 2017 ESC Guidelines for the management of acute myocardial infarction in patients presenting with ST-segment elevation. *Eur Heart J.* 7 janv 2018;39(2):119-77.
5. Kajy M, Shokr M, Ramappa P. Use of Direct Oral Anticoagulants in the Treatment of Left Ventricular Thrombus: Systematic Review of Current Literature. *Am J Ther.* 2019;7.
6. Shokr M, Ahmed A, Abubakar H, Sayedahmad Z, Rashed A, Afonso L, et al. Use of direct oral anticoagulants in the treatment of left ventricular thrombi: A tertiary center experience and review of the literature. *Clin Case Rep.* janv 2019;7(1):135-42.
7. Leow AS-T, Sia C-H, Tan BY-Q, Loh JP-Y. A meta-summary of case reports of non-vitamin K antagonist oral anticoagulant use in patients with left ventricular thrombus. *J Thromb Thrombolysis.* juill 2018;46(1):68-73.
8. Bahmaid RA, Ammar S, Al-Subaie S, Soofi MA, Mhish H, Yahia MA. Efficacy of direct oral anticoagulants on the resolution of left ventricular thrombus—A case series and literature review. *JRSM Cardiovasc Dis.* janv 2019;8:204800401983954.
9. Xuan H, Chen Y-M, Dai Y-L, Zhou J, Jiang Y-F, Zhou Y-F. Safety and Efficacy of Vitamin K Antagonists vs. Novel Oral Anticoagulants in Patients With Left Ventricular Thrombus: A Meta-Analysis. *Front Cardiovasc Med.* 29 avr 2021;8:636491.
10. Robinson AA, Trankle CR, Eubanks G, Schumann C, Thompson P, Wallace RL, et al. Off-label Use of Direct Oral Anticoagulants Compared With Warfarin for Left Ventricular Thrombi. *JAMA Cardiol.* 1 juin 2020;5(6):685.
11. Potpara T, Dagres N, Arbelo E, Bax JJ, Boriani G, Castella M, et al. The Task Force for the diagnosis and management of atrial fibrillation of the European Society of Cardiology (ESC). :126.
12. van Walraven C, Jennings A, Oake N, Fergusson D, Forster AJ. Effect of Study Setting on Anticoagulation Control. *Chest.* mai 2006;129(5):1155-66.
13. Ruff CT, Giugliano RP, Braunwald E, Hoffman EB, Deenadayalu N, Ezekowitz MD, et al. Comparison of the efficacy and safety of new oral anticoagulants with warfarin in patients with atrial fibrillation: a meta-analysis of randomised trials. *The Lancet.* mars 2014;383(9921):955-62.
14. Weinsaft JW, Kim J, Medicherla CB, Ma CL, Codella NCF, Kukar N, et al. Echocardiographic Algorithm for Post-Myocardial Infarction LV Thrombus. *JACC Cardiovasc Imaging.* mai 2016;9(5):505-15.
15. Bulluck H, Chan MHH, Paradies V, Yellon RL, Ho HH, Chan MY, et al. Incidence and predictors of left ventricular thrombus by cardiovascular magnetic resonance in acute ST-segment elevation myocardial infarction treated by primary percutaneous coronary intervention: a meta-analysis. *J Cardiovasc Magn Reson.* déc 2018;20(1):72.
16. Driesman A, Hyder O, Lang C, Stockwell P, Poppas A, Abbott JD. Incidence and Predictors of Left Ventricular Thrombus After Primary Percutaneous Coronary Intervention for Anterior ST-Segment Elevation Myocardial Infarction. *Clin Cardiol.* 2015

Oct;38(10):590-7.

17. Le May MR, Acharya S, Wells GA, Burwash I, Chong AY, So DY, et al. Prophylactic Warfarin Therapy After Primary Percutaneous Coronary Intervention for Anterior ST-Segment Elevation Myocardial Infarction. *JACC Cardiovasc Interv.* janv 2015;8(1):155-62.
18. Kuno T, Imaeda S, Hashimoto K, Ryuzaki T, Saito T, Yamazaki H, et al. Recent Inferior Myocardial Infarction Complicated with a Right Ventricular Thrombus Detected by Three Cardiac Imaging Modalities. *Intern Med.* 2018;57(5):693-5.
19. Sousa C, Almeida P, Gonçalves A, Rodrigues J, Rangel I, Macedo F, et al. Large Right Ventricular Thrombus. *Acta Médica Port.* 30 juin 2014;27(3):390.
20. Daher J, Da Costa A, Hilaire C, Ferreira T, Pierrard R, Guichard JB, et al. Management of Left Ventricular Thrombi with Direct Oral Anticoagulants: Retrospective Comparative Study with Vitamin K Antagonists. *Clin Drug Investig.* 1 avr 2020;40(4):343-53.
21. Jones DA, Wright P, Alizadeh MA, Fhadil S, Rathod KS, Guttmann O, et al. The use of novel oral anticoagulants compared to vitamin K antagonists (warfarin) in patients with left ventricular thrombus after acute myocardial infarction. *Eur Heart J - Cardiovasc Pharmacother.* 1 sept 2021;7(5):398-404.
22. Patel MR, Mahaffey KW, Garg J, Pan G, Singer DE, Hacke W, et al. Rivaroxaban versus Warfarin in Nonvalvular Atrial Fibrillation. *N Engl J Med.* 8 sept 2011;365(10):883-91.
23. Granger CB, Alexander JH, McMurray JJV, Lopes RD, Hylek EM, Hanna M, et al. Apixaban versus Warfarin in Patients with Atrial Fibrillation. *N Engl J Med.* 15 sept 2011;365(11):981-92.

Annexe: Institutional Review Board



Institutional Review Board (I.R.B.) MONTPELLIER UNIVERSITY HOSPITAL

IRB Secretary

Phone : 04.67.33.98.33 / 04.67.33.08.12

IRB Accreditation number : 198711

President :

MOLINARI Nicolas

Vice President :

JUNG Boris
PANARO Fabrizio

Members :

AMEDRO Pascal
AYRIGNAC Xavier
CHIRIAC Anca
GODREUIL Sylvain
LEMAITRE Laurent
MILLET Ingrid
OLIE Emilie

DR1 Officials

Data Protection Officer

Research organized and practiced on the human being for the development of biological or medical knowledge known as 'research involving the human person' as defined in Article L. 1121-1 of the Public Health Code are to be reviewed by a committee Protection of Persons (CPP) and can not be reviewed by the IRB.

Project Title :

Effet des anticoagulants oraux directs sur les thrombus intra VG évalués par IRM cardiaque

IRB ID : 202100778

Applicant :

- Responsable de l'étude :
Mme LE PROFESSEUR LECLERCQ FLORENCE (f-leclercq@chu-montpellier.fr)
- Contact pour le droit d'information des patients :
Mme LE PROFESSEUR LECLERCQ FLORENCE (f-leclercq@chu-montpellier.fr)

Organizational Affiliation :

- UNIVERSITY HOSPITAL CENTER OF MONTPELLIER

Opinion of the IRB :

APPROVED

Documents sent to the summary of the IRB for the evaluation :

- Synopsis : 10/03/2021
- Comments :

Approval Number assigned by the IRB : IRB-MTP_2021_04_202100778

MONTPELLIER UNIVERSITY HOSPITAL
191, Avenue du Doyen Gaston GIRAUD
34295 MONTPELLIER CEDEX 5

This notice does not relieve the Study principal investigator of the obligations under the processing of personal datum

SERMENT

- *En présence des Maîtres de cette école, de mes chers condisciples et devant l'effigie d'Hippocrate, je promets et je jure, au nom de l'Être suprême, d'être fidèle aux lois de l'honneur et de la probité dans l'exercice de la médecine.*

- *Je donnerai mes soins gratuits à l'indigent et n'exigerai jamais un salaire au-dessus de mon travail.*

- *Admis (e) dans l'intérieur des maisons, mes yeux ne verront pas ce qui s'y passe, ma langue taira les secrets qui me seront confiés, et mon état ne servira pas à corrompre les mœurs, ni à favoriser le crime.*

- *Respectueux (se) et reconnaissant (e) envers mes Maîtres, je rendrai à leurs enfants l'instruction que j'ai reçue de leurs pères.*

- *Que les hommes m'accordent leur estime si je suis fidèle à mes promesses. Que je sois couvert (e) d'opprobre et méprisé (e) de mes confrères si j'y manque.*

Résumé

INTRODUCTION : Les thrombus intraventriculaires gauches (TVG) sont associés à des risques d'embolies systémiques, de morbidités et de mortalité. Les thrombus intraventriculaires droits (TVD) sont rares mais avec un risque potentiel d'embolie pulmonaire. Le traitement de première intention actuellement correspond aux antagonistes de la vitamine K (AVK), mais ils présentent plusieurs limites en termes d'efficacité et de sécurité.

OBJECTIF : L'objectif de cette étude était d'évaluer l'efficacité des anticoagulants oraux directs (AOD) sur la disparition des thrombus intraventriculaires (TIV) en imagerie par résonance magnétique (IRM).

METHODE : De juin 2018 à septembre 2021, nous avons inclus les patients ayant un diagnostic de TIV en échographie transthoracique (ETT), en IRM ou en tomodensitométrie (TDM) et traités par AOD au centre hospitalier universitaire de Montpellier et de Nîmes. Les patients présentant une contre-indication à l'IRM ou traités par AVK ou héparine de bas poids moléculaire ont été exclus. Le critère de jugement principal était la disparition du TIV en IRM à 6 mois et les critères de jugements secondaires comprenaient la mortalité, les événements thromboemboliques et les événements hémorragiques.

RESULTATS : Trente-quatre patients avec un âge moyen de 58 ± 16 ans et une majorité d'hommes (n=30, 88.2%) ont été inclus dont 32 TVG et 2 TVD. La cardiomyopathie ischémique était l'étiologie la plus fréquente (n = 30, 88.2%) avec principalement des infarctus du myocarde antérieur (n = 20, 58.8%). Les TVD étaient retrouvés uniquement

dans les cardiopathies dilatées avec dysfonction biventriculaire. Les patients étaient traités par apixaban (55,9%), dabigatran (32,4%) ou rivaroxaban (11,7%). Les antiagrégants plaquettaires ont été utilisés chez 88,2 % de la population. La disparition du TIV a été observée chez 25 (73,5 %) patients lors de l'IRM de suivi, 23 (71.9%) TVG et tous les TVD. Un accident vasculaire cérébral est survenu chez un patient (2.9%) et une hémorragie sévère (BARC \geq 3) chez un patient (2.9%) à 6 mois de suivi.

CONCLUSION : Dans cette étude pilote, prospective, observationnelle et multicentrique, le traitement par AOD a été associé à une disparition du TIV chez 73,5% des patients avec des événements graves observés chez 5,8 % des patients. Les résultats préliminaires suggèrent que les AOD sont efficaces pour traiter les TIV avec peu d'événements ischémiques et hémorragiques. La réalisation d'études randomisées avec comparaison entre les AOD et les AVK sont nécessaires pour confirmer ces résultats.

MOTS CLES : thrombus intraventriculaire, anticoagulants oraux directs, anti vitamine K, échocardiographie, imagerie par résonance magnétique