



HAL
open science

Dorsal onlay oral mucosa graft urethroplasty for female urethral stricture = Uréthroplastie dorsale par greffon de muqueuse orale dans les sténoses de l'urètre féminin

Claire Richard

► **To cite this version:**

Claire Richard. Dorsal onlay oral mucosa graft urethroplasty for female urethral stricture = Uréthroplastie dorsale par greffon de muqueuse orale dans les sténoses de l'urètre féminin. Life Sciences [q-bio]. 2021. dumas-03544191

HAL Id: dumas-03544191

<https://dumas.ccsd.cnrs.fr/dumas-03544191>

Submitted on 26 Jan 2022

HAL is a multi-disciplinary open access archive for the deposit and dissemination of scientific research documents, whether they are published or not. The documents may come from teaching and research institutions in France or abroad, or from public or private research centers.

L'archive ouverte pluridisciplinaire **HAL**, est destinée au dépôt et à la diffusion de documents scientifiques de niveau recherche, publiés ou non, émanant des établissements d'enseignement et de recherche français ou étrangers, des laboratoires publics ou privés.



**UNIVERSITE
BRETAGNE
LOIRE**

THÈSE D'EXERCICE / UNIVERSITÉ DE RENNES 1
sous le sceau de l'Université Bretagne Loire

Thèse en vue du

DIPLÔME D'ÉTAT DE DOCTEUR EN MÉDECINE

présentée par

Claire RICHARD

Née le 3 mars 1993 à Saint-Jean-de-Braye.

**Dorsal onlay oral
mucosa graft
urethroplasty for
female urethral
stricture.**

***Uréthroplastie
dorsale par greffon
de muqueuse orale
dans les sténoses de
l'urètre féminin.***

**Thèse soutenue à RENNES
le 16 avril 2021**

devant le jury composé de :

Pr Karim BENSALAH

PU-PH, CHU de Rennes / *Président du jury*

Pr Romain MATHIEU-SANQUER

PU-PH, CHU de Rennes / *Juge*

Pr Célia RAVEL

PU-PH, CHU de Rennes / *Juge*

Dr Benoît PEYRONNET

MCU-PH, CHU de Rennes / *Directeur de thèse*

Dr Andrea MANUNTA

Docteur en médecine / *Juge*

Dr Benjamin BRUCKER

MD - asst. Prof / *Juge invité*



THÈSE D'EXERCICE / UNIVERSITÉ DE RENNES 1
sous le sceau de l'Université Bretagne Loire

Thèse en vue du

DIPLÔME D'ÉTAT DE DOCTEUR EN MÉDECINE

présentée par

Claire RICHARD

Née le 3 mars 1993 à Saint-Jean-de-Braye.

**Dorsal onlay oral
mucosa graft
urethroplasty for
female urethral
stricture.**

***Uréthroplastie
dorsale par greffon
de muqueuse orale
dans les sténoses de
l'urètre féminin.***

**Thèse soutenue à RENNES
le 16 avril 2021**

devant le jury composé de :

Pr Karim BENSALAH

PU-PH, CHU de Rennes / *Président du jury*

Pr Romain MATHIEU-SANQUER

PU-PH, CHU de Rennes / *Juge*

Pr Célia RAVEL

PU-PH, CHU de Rennes / *Juge*

Dr Benoît PEYRONNET

MCU-PH, CHU de Rennes / *Directeur de thèse*

Dr Andrea MANUNTA

Docteur en médecine / *Juge*

Dr Benjamin BRUCKER

MD - asst. Prof / *Juge invité*

PROFESSEURS DES UNIVERSITÉS

NOM	PRENOM	TITRE	SOUS-SECTION CNU
ANNE-GALIBERT	Marie-Dominique	PU-PH	Biochimie et biologie moléculaire
BARDOU-JACQUET	Edouard	PU-PH	Gastroentérologie ; hépatologie ; addictologie
BELAUD-ROTUREAU	Marc-Antoine	PU-PH	Histologie, embryologie et cytogénétique
BELLISSANT	Eric	PU-PH	Pharmacologie fondamentale ; pharmacologie clinique ; addictologie
BELOEIL	Hélène	PU-PH	Anesthésiologie-réanimation et médecine péri-opératoire
BENDAVID	Claude	PU-PH	Biochimie et biologie moléculaire
BENSALAH	Karim	PU-PH	Urologie
BEUCHEE	Alain	PU-PH	Pédiatrie
BONAN	Isabelle	PU-PH	Médecine physique et de réadaptation
BONNET	Fabrice	PU-PH	Endocrinologie, diabète et maladies métaboliques ; gynécologie médicale
BOUDJEMA	Karim	PU-PH	Chirurgie viscérale et digestive
BOUGET	Jacques	Pr Emérite	Thérapeutique-médecine de la douleur ; addictologie
BOUGUEN	Guillaume	PU-PH	Gastroentérologie ; hépatologie ; addictologie
BRASSIER	Gilles	PU-PH	Neurochirurgie
BRETAGNE	Jean-François	Pr Emérite	Gastroentérologie ; hépatologie ; addictologie
BRISSOT	Pierre	Pr Emérite	Gastroentérologie ; hépatologie ; addictologie
CARRE	François	Pr Emérite	Physiologie
CATTOIR	Vincent	PU-PH	Bactériologie-virologie ; hygiène hospitalière
CHALES	Gérard	Pr Emérite	Rhumatologie
COGNÉ	Michel	PU-PH	Immunologie
CORBINEAU	Hervé	PU-PH	Chirurgie thoracique et cardiovasculaire

CUGGIA	Marc	PU-PH	Biostatistiques, informatique médicale et technologies de communication
DAUBERT	Claude	Pr Emérite	Cardiologie
DAVID	Véronique	PU-PH	Biochimie et biologie moléculaire
DAYAN	Jacques	Pr Associé	Pédopsychiatrie ; addictologie
DE CREVOISIER	Renaud	PU-PH	Cancérologie ; radiothérapie
DECAUX	Olivier	PU-PH	Médecine interne ; gériatrie et biologie du vieillissement ; addictologie
DESRUES	Benoît	PU-PH	Pneumologie ; addictologie
DEUGNIER	Yves	Pr Emérite	Gastroentérologie ; hépatologie ; addictologie
DONAL	Erwan	PU-PH	Cardiologie
DRAPIER	Dominique	PU-PH	Psychiatrie d'adultes ; addictologie
DUPUY	Alain	PU-PH	Dermato-vénérologie
ECOFFEY	Claude	PU-PH	Anesthésiologie-réanimation et médecine péri-opératoire
EDAN	Gilles	Pr en surnombre	Neurologie
FERRE	Jean-Christophe	PU-PH	Radiologie et imagerie médicale
FEST	Thierry	PU-PH	Hématologie ; transfusion
FLECHER	Erwan	PU-PH	Chirurgie thoracique et cardiovasculaire
GANDEMER	Virginie	PU-PH	Pédiatrie
GANDON	Yves	PU-PH	Radiologie et imagerie médicale
GANGNEUX	Jean-Pierre	PU-PH	Parasitologie et mycologie
GARIN	Etienne	PU-PH	Biophysique et médecine nucléaire
GARLANTEZEC	Ronan	PU-PH	Epidémiologie, économie de la santé et prévention
GAUVRIT	Jean-Yves	PU-PH	Radiologie et imagerie médicale
GODEY	Benoît	PU-PH	Oto-rhino-laryngologie
GUGGENBUHL	Pascal	PU-PH	Rhumatologie
GUILLE	François	Pr Emérite	Urologie
GUYADER	Dominique	PU-PH	Gastroentérologie ; hépatologie ; addictologie
HAEGELEN	Claire	PU-PH	Anatomie
HOUOT	Roch	PU-PH	Hématologie ; transfusion

JEGO	Patrick	PU-PH	Médecine interne ; gériatrie et biologie du vieillissement ; addictologie
JEGOUX	Franck	PU-PH	Oto-rhino-laryngologie
JOUNEAU	Stéphane	PU-PH	Pneumologie ; addictologie
KAYAL	Samer	PU-PH	Bactériologie-virologie ; hygiène hospitalière
LAMY DE LA CHAPELLE	Thierry	PU-PH	Hématologie ; transfusion
LAVIOLLE	Bruno	PU-PH	Pharmacologie fondamentale ; pharmacologie clinique ; addictologie
LAVOUE	Vincent	PU-PH	Gynécologie-obstétrique ; gynécologie médicale
LE BRETON	Hervé	PU-PH	Cardiologie
LE TULZO	Yves	PU-PH	Médecine intensive-réanimation
LECLERCQ	Christophe	PU-PH	Cardiologie
LEDERLIN	Mathieu	PU-PH	Radiologie et imagerie médicale
LEGUERRIER	Alain	Pr Emérite	Chirurgie thoracique et cardiovasculaire
LE JEUNE	Florence	PU-PH	Biophysique et médecine nucléaire
LEVEQUE	Jean	PU-PH	Gynécologie-obstétrique ; gynécologie médicale
LIEVRE	Astrid	PU-PH	Gastroentérologie ; hépatologie ; addictologie
MABO	Philippe	PU-PH	Cardiologie
MAHE	Guillaume	PU-PH	Chirurgie vasculaire ; médecine vasculaire
MALLEDANT	Yannick	Pr Emérite	Anesthésiologie-réanimation et médecine péri-opératoire
MATHIEU-SANQUER	Romain	PU-PH	Urologie
MENER	Eric	Pr associé	Médecine générale
MICHELET	Christian	Pr Emérite	Maladies infectieuses ; maladies tropicales
MOIRAND	Romain	PU-PH	Gastroentérologie ; hépatologie ; addictologie
MORANDI	Xavier	PU-PH	Anatomie
MOREL	Vincent	Pr associé	Médecine palliative
MOSSER	Jean	PU-PH	Biochimie et biologie moléculaire
MOURIAUX	Frédéric	PU-PH	Ophtalmologie

MYHIE	Didier	Pr associé	Médecine générale
NAUDET	Florian	PU-PH	Thérapeutique-médecine de la douleur ; addictologie
ODENT	Sylvie	PU-PH	Génétique
OGER	Emmanuel	PU-PH	Pharmacologie fondamentale ; pharmacologie clinique ; addictologie
PARIS	Christophe	PU-PH	Médecine et santé au travail
PERDRIGER	Aleth	PU-PH	Rhumatologie
PESCHANSKY	Nicolas	Pr Associé	Médecine d'urgence
PLADYS	Patrick	PU-PH	Pédiatrie
RAVEL	Célia	PU-PH	Histologie, embryologie et cytogénétique
RENAUT	Pierric	Pr associé	Médecine générale
REVEST	Matthieu	PU-PH	Maladies infectieuses ; maladies tropicales
RIFFAUD	Laurent	PU-PH	Neurochirurgie
RIOUX-LECLERCQ	Nathalie	PU-PH	Anatomie et cytologie pathologiques
ROBERT-GANGNEUX	Florence	PU-PH	Parasitologie et mycologie
ROPARS	Mickaël	PU-PH	Chirurgie orthopédique et traumatologique
SAINT-JALMES	Hervé	Pr Emérite	Biophysique et médecine nucléaire
SAULEAU	Paul	PU-PH	Physiologie
SCHNELL	Frédéric	PU-PH	Physiologie
SEGUIN	Philippe	PU-PH	Anesthésiologie-réanimation et médecine péri-opératoire
SIPROUDHIS	Laurent	PU-PH	Gastroentérologie ; hépatologie ; addictologie
SOMME	Dominique	PU-PH	Médecine interne ; gériatrie et biologie du vieillissement ; addictologie
SOULAT	Louis	Pr associé	Médecine d'urgence
SULPICE	Laurent	PU-PH	Chirurgie viscérale et digestive
TADIE	Jean Marc	PU-PH	Médecine intensive-réanimation
TARTE	Karin	PU-PH	Immunologie
TATTEVIN	Pierre	PU-PH	Maladies infectieuses ; maladies tropicales
THIBAUT	Ronan	PU-PH	Nutrition

THIBAULT	Vincent	PU-PH	Bactériologie-virologie ; hygiène hospitalière
THOMAZEAU	Hervé	Pr Emérite	Chirurgie orthopédique et traumatologique
TORDJMAN	Sylvie	PU-PH	Pédopsychiatrie ; addictologie
VERHOYE	Jean-Philippe	PU-PH	Chirurgie thoracique et cardiovasculaire
VERIN	Marc	PU-PH	Neurologie
VIEL	Jean-François	PU-PH	Epidémiologie, économie de la santé et prévention
VIGNEAU	Cécile	PU-PH	Néphrologie
VIOLAS	Philippe	PU-PH	Chirurgie infantile
WATIER	Eric	PU-PH	Chirurgie plastique, reconstructrice et esthétique ; brûlologie
WODEY	Eric	PU-PH	Anesthésiologie-réanimation et médecine péri-opératoire

MAITRES DE CONFERENCE DES UNIVERSITÉS

NOM	PRENOM	TITRE	SOUS-SECTION CNU
ALLORY	Emmanuel	MCF associé	Médecine générale
AME	Patricia	MCU-PH	Immunologie
AMIOT	Laurence	MCU-PH	Hématologie ; transfusion
ANSELM	Amédéo	MCU-PH	Chirurgie thoracique et cardiovasculaire
ARNAUD	Alexis	MCU-PH	Chirurgie infantile
BANATRE	Agnès	MCF associé	Médecine générale
BASTIAN	Benjamin	MCF associé	Médecine générale
BEGUE	Jean Marc	MCU-PH	Physiologie
BERTHEUIL	Nicolas	MCU-PH	Chirurgie plastique, reconstructrice et esthétique ; brûlologie
BROCHARD	Charlène	MCU-PH	Physiologie
CABILLIC	Florian	MCU-PH	Biologie cellulaire

CASTELLI	Joël	MCU-PH	Cancérologie ; radiothérapie
CAUBET	Alain	MCU-PH	Médecine et santé au travail
CHAPRON	Anthony	MCF	Médecine générale
CHHOR-QUENIART	Sidonie	MCF associé	Médecine générale
CORVOL	Aline	MCU-PH	Médecine interne ; gériatrie et biologie du vieillissement ; addictologie
DE TAYRAC	Marie	MCU-PH	Biochimie et biologie moléculaire
DEGEILH	Brigitte	MCU-PH	Parasitologie et mycologie
DROITCOURT	Catherine	MCU-PH	Dermato-vénéréologie
DUBOURG	Christèle	MCU-PH	Biochimie et biologie moléculaire
DUGAY	Frédéric	MCU-PH	Histologie, embryologie et cytogénétique
EDELIN	Julien	MCU-PH	Cancérologie ; radiothérapie
FIQUET	Laure	MCF associé	Médecine générale
GOUIN épouse THIBAUT	Isabelle	MCU-PH	Hématologie ; transfusion
GUILLET	Benoit	MCU-PH	Hématologie ; transfusion
JAILLARD	Sylvie	MCU-PH	Histologie, embryologie et cytogénétique
KALADJI	Adrien	MCU-PH	Chirurgie vasculaire ; médecine vasculaire
KAMMERER-JACQUET	Solène-Florence	MCU-PH	Anatomie et cytologie pathologiques
LAVENU	Audrey	MCF	sciences physico-chimiques et ingénierie appliquée à la santé
LE GALL	François	MCU-PH	Anatomie et cytologie pathologiques
LEMAITRE	Florian	MCU-PH	Pharmacologie fondamentale ; pharmacologie clinique ; addictologie
MARTINS	Pédro Raphaël	MCU-PH	Cardiologie
MENARD	Cédric	MCU-PH	Immunologie
MICHEL	Laure	MCU-PH	Neurologie
MOREAU	Caroline	MCU-PH	Biochimie et biologie moléculaire

MOUSSOUNI	Fouzia	MCF	Informatique
NYANGOH TIMOH	Krystel	MCU-PH	Anatomie
PANGAULT	Céline	MCU-PH	Hématologie ; transfusion
ROBERT	Gabriel	MCU-PH	Psychiatrie d'adultes ; addictologie
TURLIN	Bruno	MCU-PH	Anatomie et cytologie pathologiques
VERDIER épouse LORNE	Marie-Clémence	MCU-PH	Pharmacologie fondamentale ; pharmacologie clinique ; addictologie
ZIELINSKI	Agata	MCF	Philosophie

Remerciements

À **Monsieur le Professeur Karim BENSALAH**, vous me faites l'honneur de présider ma soutenance de thèse. Vos métaphores pleines de sens ont jalonné mon internat, merci de m'avoir transmis des valeurs importantes en chirurgie comme dans la vie : le refus du dogme, l'esprit de synthèse et l'humilité. Recevez ici toute ma reconnaissance et l'expression de mon plus profond respect.

À **Monsieur le Professeur Romain MATHIEU**, pour me faire l'honneur de juger ce travail. Merci pour votre bonne humeur et votre disponibilité à chaque instant.

À **Madame la Professeur Célia RAVEL**, pour me faire l'honneur d'être membre du jury de cette thèse. Merci pour votre soutien et votre enthousiasme lors de nos échanges inspirants.

À **Monsieur le Docteur Andrea MANUNTA**, pour votre patience et votre gentillesse infinie lors de mes premiers pas d'interne. Merci de m'avoir appris à opérer en « faisant la brasse » et « du ski sur le vagin », de m'avoir inculqué votre perfectionnisme et votre goût des jolis gestes. Vous resterez pour moi un modèle tant d'empathie que de chirurgien.

To **Doctor Benjamin BRUCKER**, Associate Professor, Department of Urology at NYU Langone School of Medicine, New York. I would like to express my deepest regards and gratitude for having accepted to help me in this work. It is a great privilege and honour to have an international expert in female urethral stricture part of my MD thesis committee. I would also like to thank **Alice Drain**, for her help in data collection and for having lent me her voice and beautiful American accent.

À mon directeur de thèse et mentor **Monsieur le Docteur Benoit PEYRONNET**. Mon admiration et ma reconnaissance sont infinies. Ta bienveillance, ton énergie et ton optimisme à toute épreuve sont des moteurs qui me donnent envie de travailler chaque jour un peu plus pour devenir meilleure et t'aider « à changer le monde ». Merci d'avoir cru en moi, de m'avoir toujours soutenue, recadrée parfois et de me faire prendre confiance. M'épanouir dans cette spécialité passionnante à tes côtés est une chance incommensurable.

À **toute l'équipe d'urologie du CHU de Rennes** sans qui les moments passés dans le service n'auraient pas la même saveur.

Vous m'avez accueilli avec bienveillance et j'espère vous la rendre chaque jour.

Aux consultations, dans le service, en HDJ, au bloc et au secrétariat j'ai rencontré des personnes formidables qui font de ce service une famille. Merci à Hélène Richard – que les externes prennent régulièrement pour ma mère, ma tante ou ma soeur – et Muriel Ki-Zerbo de faire de ce service une équipe soudée, malgré les moments difficiles imposés par la situation sanitaire actuelle.

À **mes chefs** Juliette, Lucas, Vivien, Zineddine, Quentin, Baptiste, Lauranne merci pour votre compagnonnage et votre soutien.

À **mes co-internes Rennais** Camille, François, Mehdi, Etienne, Ronan, Marie, Anna, Anis, Anne, Raphael, et Brice, Valentine, Alexandre que je connais moins mais dont j'espère beaucoup, pour tous les fous rires dans le bureau, les nocturnes à faire de la base, les petits dej à l'internat et les verres en ville après les longues journées.

Aux différentes équipes qui ont marqué mon parcours.

À l'équipe Vannetaise : Georges, Francky, Marie et Gregory pour m'avoir fait vivre le semestre le plus joyeux et ensoleillé de mon internat entre les journées au bloc et les apéros sur le port.

À l'équipe Briochine : Luc, Emmanuel, François, Yann, Raïssa, Fabien et Grégoire ainsi que les super-nanas du blocs Edith, Anne-Laure, Sandrine, Séverine et Wendy pour ce semestre fabuleux. Merci de m'avoir accueilli et fait progresser, travailler à vos côtés pendant ces 7 mois m'a épanoui professionnellement et humainement.

À l'équipe de gynécologie de la Sagesse où je suis actuellement. Merci Pierre-Louis de partager de bon cœur avec moi votre savoir-faire au bloc et votre empathie au service des femmes. Merci à Carole pour tous ces moments de partage autour de la colonne de BUD ou de bons thés, apprendre à tes côtés est une chance inouïe et nos discussions passionnantes et engageantes me manqueront ! Enfin, merci à toute l'équipe de PMA de m'avoir accueilli aussi chaleureusement.

A ma famille et amis, soutiens indéfectibles depuis toujours.

A mes grands-parents.

A André et Marie-Jo, pour m'avoir accueillie pendant mes années lycée et offert une adolescence de rêve et beaucoup de liberté.

A Simonne, mon modèle de résilience et sans doute la femme la plus forte que je connaisse.

A Marcel, je n'oublierai jamais ta fierté d'avoir une petite fille admise en médecine, cette thèse est pour toi, qui me regarde de là-haut.

A mes parents, merci de m'avoir appris la valeur du travail et du mérite, sans votre soutien rien n'aurait été possible.

Papa, merci pour le regard fier et aimant que tu poses depuis toujours sur moi. J'espère avoir hérité de ta sensibilité et de ta persévérance.

Maman, merci de t'être dévouée pour nous offrir une enfance heureuse et protégée. Tu m'as insufflé depuis toujours la conviction que je pouvais tout réussir. Merci pour ta pugnacité et pour ton goût des belles choses.

A mes frères Félix et Alban. Merci d'avoir toujours veillé sur moi comme si c'était moi la petite sœur. Merci de m'avoir préparé des petits dej de compét pendant mes révisions, d'avoir beaucoup trop joué les taxis pour venir me chercher, de m'avoir supporté et réconforté dans les moments difficiles, pour les fous rires, les grandes discussions et toutes vos petites attentions. Je vous aime.

A ma belle-famille, Bénédicte, Vincent, JM, PH, Sixtine et Hermine de m'avoir accueilli si simplement et naturellement au sein de votre grande famille.

A ma sœur de cœur, Pauline. Merci d'avoir été là à chaque étape de ma vie. Le chemin a été long depuis la cour de Ste Cécile et je suis fière des femmes que nous sommes devenues : presque conformes à nos rêves de petites filles. Double B nous sommes et nous le resterons.

A mes amis les plus chers.

Vero, ma girl boss. Merci pour les crampes à force de rire, pour ta philosophie et ta joie de vivre qui illumine ma vie depuis nos années lycée.

Roxane et Benoist, les plus belles rencontres de l'internat. Je suis fière de partager votre vie et d'avancer avec vous en sirotant de la liqueur d'orange et en dansant trop tard après le couvre-feu dans votre salon.

Aux autres membres de la Team Submarine, Lecluze, Toub, Laura...merci d'être là.

Parastou pour nos soirées endiablées et nos discussions-tisanes interminables.

Marie et Mathieu, pour les weekends de folie à Gouville, à Tours ou à Rennes, on a hâte de voir grandir la petite fille que vous attendez.

A tous ceux qui m'ont accompagné pendant l'internat, l'externat, au lycée et les amis d'enfance qui se reconnaîtront. Le temps file mais les souvenirs restent.

A l'homme de ma vie.

Merci Louis-Paul pour ton amour et ton infaillible soutien.

Je suis fière de notre duo prêt à soulever des montagnes pour vivre nos rêves.

A notre futur qui s'annonce plein de bonheur.

Table des matières

<i>Professeurs des Universités – Praticiens Hospitaliers</i>	2
<i>Maitre de Conférences des Universités – Praticiens hospitaliers</i>	6
Remerciements	9
Liste des illustrations	12
Article	13
<i>Author’s and affiliations</i>	13
<i>Résumé (français)</i>	14
<i>Abstract (english)</i>	15
<i>Introduction</i>	16
<i>Methods</i>	17
Study population	17
Surgical Procedure	17
Follow-up and outcome.....	18
Statistical analysis.....	19
<i>Results</i>	20
Patients’ characteristics.....	20
Perioperative outcomes.....	20
Functional and anatomical outcomes.....	20
<i>Discussion</i>	21
<i>Conclusion</i>	23
Références	24
Abréviations	26
Illustrations	27
Table 1 – Patient’s characteristics.....	27
Table 2 – Perioperative outcomes.....	28
Table 3 – Functional outcomes.....	28
Figure 1 – Surgical procedure.....	30
Figure 2 – Oral mucosa graft harvest area.....	31
Figure 3 – Stricture recurrence free survival.....	31

Liste des illustrations

Tables

Table 1 – Patient’s characteristics

Table 2 – Perioperative outcomes

Table 3 – Functional outcomes

Figures

Figure 1 – Surgical procedure.

Figure 2 – Oral mucosa graft harvest area.

Figure 3 – Stricture recurrence free survival

Article

Dorsal onlay oral mucosa graft urethroplasty for female urethral stricture.

Authors and affiliations

Claire Richard¹, Benoit Peyronnet¹, Alice Drain², Juliette Hascoet¹, Nirit Rosenblum²,
Rachael D. Sussman³, Lucas Freton¹, Lee C Zhao², Victor W Nitti⁴, Benjamin M Brucker²

1: Department of Urology, University of Rennes, Rennes, France

2: Department of Urology, New York University Langone Health, New York, USA

3: Department of Urology, USA MedStar Georgetown university hospital, Washington, USA

4: Department of Urology, UCLA, Los Angeles, USA

Résumé

Introduction – L’objectif de cette étude était d’évaluer les résultats de l’uréthroplastie dorsale par greffon de muqueuse orale pour les sténoses de l’urètre féminin.

Méthodes – Toutes les femmes ayant été opérées d’une uréthroplastie dorsale par greffon de muqueuse orale (buccale ou linguale) pour une sténose de l’urètre entre 2011 et 2020 dans deux centres universitaires ont été incluses. Les critères d’exclusion étaient les patientes âgées de moins de 18 ans, les patients de sexe masculin ou la réalisation d’une uréthroplastie pour d’autres indications que la sténose de l’urètre (ex : érosion prothétique). Quatre chirurgiens ont réalisé les uréthroplasties suivant une technique standardisée. Le critère de jugement principal était le succès clinique défini comme toute amélioration subjective des symptômes du bas appareil urinaire d’après l’auto-évaluation des patientes 1 à 3 mois après l’ablation de la sonde vésicale.

Résultats – Dix-neuf patientes ont été incluses durant la période de l’étude. Le temps opératoire moyen était de 126.6 minutes et la durée de séjour moyenne d’un jour (0-3). Il y a eu deux complications post opératoires mineurs (une infection urinaire et une sinusite, Clavien 2). Le taux de succès clinique était de 94.7% entre 1 à 3 mois et 90.9 % à un an.

Après une durée moyenne de suivi de 12 mois (1-49), il y a eu une récurrence (5.3%), le succès clinique était atteint pour 17 patientes (89.5%) et le débit urinaire maximal ainsi que le résidu post mictionnel étaient significativement améliorés (15.2 vs. 7.4 ml/s en pré opératoire; $p=0.008$ et 71.5 vs. 161.1 ml en pré opératoire ; $p=0.001$ respectivement). Le taux d’incontinence d’effort de novo était de 15.7% entre 1 à 3 mois et 9.1% à un an.

Conclusion – L’uréthroplastie dorsale par greffon de muqueuse orale pour les sténoses de l’urètre féminin semble être une technique faisable par différents chirurgiens et est associée à une morbidité post opératoire faible et des résultats fonctionnels satisfaisants avec un taux de récurrence faible. D’autres séries avec de plus larges échantillons et des durées de suivi plus longues sont nécessaires pour confirmer ces résultats.

Abstract

Background - Female urethral stricture (FUS) is a rare, and largely underdiagnosed condition. Urethral dilation and vaginal flap urethroplasty have been the most commonly described treatments.

Objective - To assess the outcomes of dorsal onlay oral mucosa graft urethroplasty for FUS.

Design settings and participants - We retrospectively reviewed the charts of all female patients who underwent dorsal onlay oral (buccal or lingual) mucosa urethroplasty for urethral stricture between 2011 and 2020 at two academic institutions.

Surgical procedure: Four surgeons performed the urethroplasties using a standardized technique: suprameatal incision, dissection and longitudinal opening of the dorsal aspect of the urethra, harvest of the oral mucosa graft, graft onlay sutured into the urethral opening.

Measurements: The primary endpoint was clinical success defined as any subjective improvement in LUTS self-assessed by the patients 1 to 3 months after catheter removal.

Results and limitations - Nineteen patients were included. Mean operative time was 126.6 minutes, median length of hospital stay was one day (range:0-3). There were two minor postoperative complications (1 UTI and 1 sinusitis, Clavien 2). The clinical success rate was 94.7% at 1 to 3 months and 90.9% at 1 year. After a median follow-up of 12 months (range 1-49) there was one recurrence (5.3%), clinical success was achieved in 17 patients (89.5%) and both the maximum urinary flow rate and post void residual were significantly improved (15.2 vs. 7.4ml/s preoperatively; $p=0.008$ and 71.5 vs. 161.1ml preoperatively; $p=0.001$ respectively). The *de novo* stress urinary incontinence rate was 15.7% at 1 to 3 months and 9.1% at 1 year.

Conclusion - Dorsal onlay oral mucosa graft urethroplasty for FUS appears feasible across multiple surgeons and is associated with a low perioperative morbidity, satisfactory functional outcomes and a low recurrence rate. Other series with larger sample size and longer follow-up are needed to confirm these findings.

Patient summary - Repairing narrowed urethra with dorsal onlay oral mucosa graft in women appears feasible, safe and reproducible.

Introduction

The most widely accepted definition of female urethral stricture (FUS) is a symptomatic, anatomical narrowing of the urethra diagnosed by failure to catheterize, urethral calibration, visual inspection, endoscopy or radiography (1). FUS is a rare, but also largely under diagnosed condition, accounting for 4 to 16% of all female bladder outlet obstructions (BOO) (2,3).

Similar to the diagnostic approach, there is no universally accepted therapeutic algorithm for FUS. As a first line treatment, urethral dilatation (UD) may be attempted initially. However, this technique has high rates of recurrence, often with more complex stricture than before dilatation due to the exacerbation of periurethral fibrosis (4). In the last several years there has been an increasing interest in female urethral reconstruction strategies involving flaps and grafts due to promising long-term results (5). The two main techniques of augmentation urethroplasty differ by the source of healthy tissue used for the repair: vaginal or oral mucosa. The different approaches include vaginal flap urethroplasty, free graft urethroplasty (oral or vaginal mucosa) and distal urethrectomy with advancement meatoplasty (6). The location of the stricture may influence the choice of the appropriated repair technique. Distal FUS may be managed by vaginal flap or advancement meatoplasty whereas midurethral or proximal strictures would require graft urethroplasty (7).

Although those definitive treatment options demonstrated promising outcomes in small sample series (80 to 92% and 89 to 91% mean success rates for vaginal flap and oral mucosa augmentation respectively), there is no evidence to recommend one technique over another and the choice of the surgical approach is currently mostly left at the surgeons' discretion (1,5).

For oral mucosal graft urethroplasty, the approach can be ventral or dorsal. The current body of evidence is too scarce to determine the possible superiority of either of the two approaches (5). The ventral approach requires minimal urethral mobilization, but carries a greater risk of urethrovaginal fistula, hypospadias, and lack a well vascularized bed for the graft (8,9). The dorsal approach offers a good mechanical and vascular support for the graft through the clitoral cavernosal tissue. However, there is a theoretical risk of sphincter or clitoral neurovascular bundles injuries (4,9,10). The donor site of the graft can be either lingual or buccal, with the same outcomes (11). A few series of dorsal onlay oral mucosa graft urethroplasty for FUS have been reported but with very small sample size and without a detailed description of the surgical technique.

The aim of this study was to describe the technique and assess the outcomes of dorsal onlay oral mucosa urethroplasty for female urethral stricture.

Methods

Study population

The charts of all female patients who underwent dorsal onlay oral (buccal or lingual) mucosa urethroplasty for urethral stricture between 2011 and 2020 at two academic institutions were included, after institutional review board approval at each institution (s18-00215 and CERU_2020\018). The exclusion criteria were patients aged < 18-years, male patients or urethroplasty performed for other indications than urethral stricture (e.g. sling erosion). Four surgeons performed the urethroplasties using a standardized technique that the first team of surgeons taught to the second team of surgeons.

Surgical procedure

- Urethral dissection:

The patient is placed in the dorsal lithotomy position, under general anesthesia. An antibiotic prophylaxis is used systematically. A small foley catheter is placed when possible. A Lone-Star self-retaining retractor (Cooper Surgical) is used to allow appropriate exposure. The procedure begins with the injection of xylocaine 1% (200 mg/20 ml) with 1: 100,000 epinephrine around the urethral meatus to facilitate the dissection and hemostasis.

An inverted “U” shape semi lunar incision is performed above the urethral meatus (Fig. 1A). The dissection is carried out in the plane developed between the underlying urethra and overlying clitoral cavernosus tissue. No electrocautery is used in this area to prevent damage to the clitoral innervation. Once the urethra has been dropped from the dorsal attachments, to the level of the bladder neck, a dorsal urethrotomy is performed at a 12 o’ clock position using Metzenbaum scissors until the strictured area has been completely opened and healthy urethra proximal to the stricture has been reached (Fig. 1B). Holding stitches are placed on the proximal edges of the urethrotomy, offering a better exposure of the opened urethra before the placement of the graft (Fig. 1C). At this stage, the catheter is removed, and endoscopy is performed to ensure that the stricture had been completely incised. It is also possible to use a bougie for calibration prior to and after urethrotomy. A double armed 5-0 PDS is pre-placed on

the top of the urethral incision in an outside-in fashion. Once the urethral incision has been sized, a second team begins to harvest the oral mucosa graft.

- Harvest of the oral mucosa graft:

Lingual mucosa graft (Fig. 2A): after having identified the Wharton's duct orifices, a submucosal infiltration is performed to facilitate the dissection without damaging the underlying musculature nor the lingual nerve. A 1-2 cm x 2-5cm (depending on the length of the stricture) ellipsoid area is marked. The graft edges are incised using a scalpel and the graft is excised using sharp scissors. The graft is matured on the back table by removing the fat and muscular tissue of its non-mucosal side in order to improve its uptake. The harvest site can be closed or left open at the end of the procedure.

Buccal mucosa graft (Fig. 2B): The procedure parallels the harvest of an oral mucosa graft except the mucosa is harvested on the inside of the cheek. The Stensen's duct (located at the upper second molar) should be identified prior to start in order to be preserved during the graft harvesting. Only the mucosa and submucosal tissue should be harvested making sure to spare the muscle.

- Anastomosis between the graft and the urethral plate:

The needles of the pre-placed double armed 5/0 pds are passed inside-out in the oral mucosa graft with its mucosal surface facing the urethral lumen. A running suture is used on each side to suture the graft the right and the left edges of the urethral incision (Fig. 1D). The graft is appended to the dorsal periurethral tissue using a 3/0 Vicryl to ensure a proper back in and prevent sacculation (Fig. 1E). After having removed any excess graft, the distal edge of the graft is sutured to the superior edge of the periurethral incision, using interrupted 3/0 Vicryl suture, in order to recreate the ventral aspect of the urethral meatus. (Fig. 1F).

A 18 Fr silicone catheter is placed carefully at the end of the procedure. The patients are generally discharged within 24 to 48h and the Foley catheter is left for 14 days. After catheter removal, a uroflowmetry with PVR measurement are obtained.

Follow-up and outcome

Pre and postoperative evaluations included a clinical interview with history taking and symptoms assessment, a physical examination, uroflowmetry and post-void residual volume (PVR) measurements. If feasible, voiding cystourethrography or video-urodynamic (VUD), Gel-Infused Translabial Ultrasound (GILTUS) and urethrocystoscopy were performed prior to surgery.

The primary endpoint was clinical success defined as any subjective improvement in LUTS self-assessed by the patients 1 to 3 months after catheter removal, using the Perception Global Impression of Improvement questionnaire (PGI-I). Surgical complications were collected and graded according the Clavien-Dindo classification (13).

Statistical analysis

Means and standard deviations were reported for continuous variables, and proportions for nominal variables. Comparisons between groups were performed using the χ^2 test or Fisher's exact test for discrete variables, and Mann-Whitney test for continuous variables as appropriate. Change of continuous variables over time was assessed using the paired student t-test. Stricture recurrence free survival (SRFS) was estimated using the Kaplan Meier method. Statistical analyses were performed using JMP v.12.0 software (SAS Institute Inc., Cary, NC, USA). All tests were two-sided with a level of $p < 0.05$ considered statistically significant.

Results

Patients' characteristics

Nineteen women were included over the study period. The patients' characteristics are presented in table 1. The mean age at the time of surgery was 58 years (± 13). The stricture etiology was mainly iatrogenic (52.6%), post-traumatic (15.8%) or unknown (31.6%). Most of the women had undergone previous urethral dilatation (78.9%) and three had a history of previous urethroplasty (15.8%). Presenting preoperative symptoms included voiding symptoms (94.7%), storage symptoms (57.9%), recurrent urinary tract infections (31.6%) and bladder pain (21%). The strictures were located to the mid urethra in 68.4% women, with a mean length of 11.1mm (± 0.6).

Perioperative outcomes

The perioperative outcomes are summarized in table 2. The mean operative time was 126.6 minutes (± 13), and the median length of hospital stay was one day (range, 0-3). The median length of catheterization was 15 days (range, 9-23). There was no readmission. There were two postoperative complications, both of which were minor (1 UTI and 1 sinusitis, Clavien grade 2).

Functional and anatomical outcomes

The functional outcomes are shown in table 3. The clinical success rate was 94.7% at 1 to 3 months and 90.9 % at 1 year. After a median follow-up of 12 months (range, 1-49), one patient experienced a recurrence (5.3%), which was successfully managed with a urethral dilatation in the office, with no further recurrence after 12 months. Clinical success was achieved in 17 patients (89.5%) and both the maximum urinary flow rate and PVR improved significantly postoperatively (15.2 vs. 7.4 ml/s preoperatively; $p=0.008$ and 71.5 vs. 161.1 ml preoperatively; $p=0.001$ respectively). Voiding symptoms and recurrent urinary tract infections resolved completely in most patients (83.3% and 66.7% respectively) while storage symptoms resolved in only 36.4% of patients. The *de novo* stress urinary incontinence rate was 15.7% at 1 to 3 months and 9.1% at 1 year (resolve spontaneously in one patient). The one-year estimated recurrence free survival was 91.7% (Fig. 3).

Discussion

Female urethral stricture is a rare and under diagnosed condition whose management is challenging for reconstructive urologists. Diverse surgical approaches have been described with scant data assessing their results and no existing guidelines. Our series, focused on dorsal onlay oral mucosa graft urethroplasty, suggests it is a safe and effective technique with high rates of patency and clinical success and a very low perioperative morbidity. Given that urethroplasties were performed by four surgeons at two academic institutions, this technique appears feasible and reproducible.

To date, robust data on the different surgical approaches for FUS are missing to help surgeons tailoring the therapeutic approach and counseling patients appropriately. Compared to a ventral approach, several advantages of a dorsal onlay technique for female urethroplasty have been established. It offers a more physiological urethral reconstruction with a urinary stream directed away from the vagina, it minimizes the risk of graft sacculation (4), the risk of urethrovaginal fistula is avoided (14), the above clitoral cavernosal tissue provide a good mechanical and vascular support for the graft (10), and the ventral aspect of the urethra is respected leaving the possibility to perform a mid-urethral sling in case of future stress urinary incontinence (10).

In our series, there were only one post-operative *de novo* incontinence persisting at 1 year. This result is consistent with the existing literature which suggests that *de novo* incontinence is a rare occurrence after dorsal urethroplasties. In a recent meta-analysis of FUS management modalities, *de novo* incontinence rates for the ventral and dorsal approaches were similar (5.8% vs. 3.6% respectively) (5). The theoretical increased risk of damaging the urethral resistance using a dorsal approach owing to the inverted horseshoe shape of the external urethral sphincter with a thick dorsal portion does not seem to translate clinically into an increased risk of *de novo* stress urinary incontinence (15). The damages done to the infraurethral hammock while dissecting the ventral aspect of the urethra may jeopardize urinary continence in proportions similar to the dorsal urethra incision which may be part of the explanation. Anyhow, the rates of *de novo* incontinence seem to be low with both approaches, possibly due to the paramount role of the bladder neck, which is preserved during urethroplasty, in female continence.

Another concern with the dorsal urethral approach is the theoretical risk of damaging the clitoral neurovascular bundles (NVBs). In fact, the NVBs would lie ventral and lateral to the urethra,

far from the dissection area, suggesting that they can be safely avoided during the procedure (1,16). Although sexual function after urethral reconstruction has been poorly assessed, one study concluded that sexual function was no deteriorate and rather improved after dorsal urethroplasty (5,17). In our series, only one woman declared a postoperative sexual dysfunction consisting in pain with intercourse related to vaginal dryness. Our data regarding post-operative *de novo* incontinence and sexual outcomes are limited due to the small sample and missing data, futures studies are needed to provide more robust evidence to help in surgical approach decision making.

Regarding the tissue to be used for female urethral reconstruction (oral free graft vs. local vaginal flap), the available literature has not provided a clear-cut answer yet. Both systematic reviews on FUS management published in 2013 and 2021 suggested oral mucosa graft outcomes might be slightly better, with pooled mean success rates from 90-91% for vaginal flap vs. 89-94% for oral mucosa graft (1,5), in line with our findings. Recently, the large Society of Urodynamics, Female Pelvic Medicine and Urogenital Reconstruction (SUFU) series founded better outcomes for patients treated by urethroplasty with local vaginal tissue flap (ULT) than free graft (UFG) included oral mucosa, with recurrence free rates at 12 months of 83% for ULT vs. 77% for UFG (18). However, it has to be underscored that in this study the authors pooled together in the UFG group oral mucosa grafts and other reconstructions with split thickness skin and xenograft whose outcomes are less established. This heterogenous group could have led to a confusion bias and may explain the different outcomes compared with our findings. In the largest series of dorsal buccal graft urethroplasty published in 2019, only 77% of the 39 women included remained stricture free with a mean time to recurrence of 14 months (19). Those two studies were multi-institutional, conducted among diverse set of surgeons and institutions. The heterogeneous techniques used may have influenced their findings (18). The strength of our study lies in the fact that the four surgeons in both centers used the same standardized technique as described in this manuscript. The systematization of the procedure used here may explain the more favorable outcomes observed in our cohort.

The preoperative work-up varies widely among female urethroplasty series. Urethrocystoscopy and voiding cystourethrography were the most frequent diagnostic tests in Osman et al. systematic review (1). In our series, all women had pre-operative uroflow and post-void residual assessment and a majority undergone video-urodynamics and cystoscopy. More than half of the women of our study had Gel-Infused Translabial Ultrasound (GILTUS) or/and urodynamics

with pressure-flow study. This consistent and comprehensive preoperative work-up may also explain the promising outcomes reported herein. There was a high degree of certainty on the diagnosis of FUS for all patients, the size and location of the stricture was precisely determined allowing optimal preoperative planning and coexisting dysfunction which could affect the postoperative outcomes, such as impaired detrusor contractility, had been detected (20,21).

In our study, 21.1% of the women underwent upfront urethroplasty with no prior attempt of urethral dilatation. This may also have contributed to the high success rate of urethroplasties. In Hampson et al. series, only 13% of the patient were treatment-naïve (19). Indeed, it is well established in male urethral stricture literature that repeated dilatations may exacerbate periurethral fibrosis and thus jeopardize further treatment (4,22). In the light of our findings, considering early urethral reconstruction in FUS management could appear to be an effective and safe option.

Our study has several limitations that should be emphasized. As the other works published on this rare topic, it was a retrospective series with a small sample size and a relatively short follow-up. Despite the assessment of subjective improvement using the PGI-I score, the lack of validated questionnaires and patient reported outcomes on urinary symptoms, sexual function and quality of life limit the conclusions that could be drawn from this study from the symptoms and quality of life standpoints. Finally, our study lacked a control group which can be regarded as a significant drawback.

Conclusion

The present report describes in details a standardize technique of dorsal onlay oral mucosa graft urethroplasty for FUS which appears feasible across multiple surgeons and is associated with a low perioperative morbidity, satisfactory functional outcomes and a low recurrence rate. Our findings support the idea that early urethral reconstruction is an effective and safe option to propose rather than repeated urethral dilations. Other studies with larger sample size and longer follow-up are needed to confirm those findings and to determine the relative value of dorsal onlay oral mucosa graft urethroplasty vs other techniques for the management of FUS.

Références

1. Osman NI, Mangera A, Chapple CR. A Systematic Review of Surgical Techniques Used in the Treatment of Female Urethral Stricture. *Eur Urol*. 2013 Dec;64(6):965–73.
2. Groutz A, Blaivas JG, Chaikin DC. Bladder outlet obstruction in women: Definition and characteristics. :8.
3. Brucker BM, Shah S, Mitchell S, Fong E, Nitti MD, Kelly CE, et al. Comparison of Urodynamic Findings in Women With Anatomical Versus Functional Bladder Outlet Obstruction. *Female Pelvic Med Reconstr Surg*. 2013 Jan;19(1):46–50.
4. Migliari R, Leone P, Berdondini E, De Angelis M, Barbagli G, Palminteri E. Dorsal Buccal Mucosa Graft Urethroplasty for Female Urethral Strictures. *J Urol*. 2006 Oct;176(4):1473–6.
5. Sarin I, Narain TA, Panwar VK, Bhadoria AS, Goldman HB, Mittal A. Deciphering the enigma of female urethral strictures: A systematic review and meta-analysis of management modalities. *Neurourol Urodyn*. 2021 Jan;40(1):65–79.
6. Faiena I, Koprowski C, Tunuguntla H. Female Urethral Reconstruction. *J Urol*. 2016 Mar;195(3):557–67.
7. Rosenblum N, Nitti VW. Female Urethral Reconstruction. *Urol Clin North Am*. 2011 Feb;38(1):55–64.
8. Önel FF, Antar B, Köse O, Erdem MR, Önel ŞY. Techniques and Results of Urethroplasty for Female Urethral Strictures: Our Experience With 17 Patients. *Urology*. 2011 Jun;77(6):1318–24.
9. Petrikovets A, Sun HH, Kiechle J, Chapman GC, Gonzalez CM, Hijaz A. Ventral-onlay buccal mucosal graft urethroplasty for the treatment of female urethral stricture: a step-by-step video for Female Pelvic Reconstructive Surgeons. *Int Urogynecology J*. 2019 Dec;30(12):2191–3.
10. Sharma GK, Pandey A, Bansal H, Swain S, Das SK, Trivedi S, et al. Dorsal onlay lingual mucosal graft urethroplasty for urethral strictures in women. *BJU Int*. 2010 May;105(9):1309–12.
11. Wang A, Chua M, Talla V, Fernandez N, Ming J, Sarino EM, et al. Lingual versus buccal mucosal graft for augmentation urethroplasty: a meta-analysis of surgical outcomes and patient-reported donor site morbidity. *Int Urol Nephrol* [Internet]. 2021 Jan 7; Available from: <https://doi.org/10.1007/s11255-020-02720-7>

12. Soave A, Dahlem R, Pinnschmidt HO, Rink M, Langetepe J, Engel O, et al. Substitution Urethroplasty with Closure Versus Nonclosure of the Buccal Mucosa Graft Harvest Site: A Randomized Controlled Trial with a Detailed Analysis of Oral Pain and Morbidity. *Eur Urol*. 2018 Jun;73(6):910–22.
13. Dindo D, Demartines N, Clavien P-A. Classification of Surgical Complications: A New Proposal With Evaluation in a Cohort of 6336 Patients and Results of a Survey. *Ann Surg*. 2004 Aug;240(2):205–13.
14. tsivian2006.pdf.
15. Wallner C, Dabhoiwala NF, DeRuiter MC, Lamers WH. The Anatomical Components of Urinary Continence. *Eur Urol*. 2009 Apr;55(4):932–44.
16. O’Connell HE, DeLANCEY JOL. CLITORAL ANATOMY IN NULLIPAROUS, HEALTHY, PREMENOPAUSAL VOLUNTEERS USING UNENHANCED MAGNETIC RESONANCE IMAGING. *J Urol*. 2005 Jun;173(6):2060–3.
17. Manasa T, Khattar N, Tripathi M, Varshney A, Goel H, Sood R. Dorsal onlay graft urethroplasty for female urethral stricture improves sexual function: Short-term results of a prospective study using vaginal graft. [cited 2021 Jan 27]; Available from: <https://www.ncbi.nlm.nih.gov/pmc/articles/PMC6792406/>
18. Lane GI, Smith AL, Stambakio H, Lin G, Al Hussein Alawamlh O, Anger JT, et al. Treatment of urethral stricture disease in women: A multi-institutional collaborative project from the SUFU research network. *Neurourol Urodyn*. 2020 Nov;39(8):2433–41.
19. Hampson LA, Myers JB, Vanni AJ, Virasoro R, Smith III TG, Capiel L, et al. Dorsal buccal graft urethroplasty in female urethral stricture disease: a multi-center experience. *Transl Androl Urol*. 2019 Mar;8(S1):S6–12.
20. Nitti VW, Tu LM, Gitlin J. DIAGNOSING BLADDER OUTLET OBSTRUCTION IN WOMEN. *J Urol*. 1999;161(5):1535–40.
21. Sussman RD, Kozirovsky M, Telegrafi S, Peyronnet B, Palmerola R, Smilen S, Pape DM, Rosenblum N, Nitti VW, Brucker BM. Gel-Infused Translabial Ultrasound in the Evaluation of Female Urethral Stricture. *Female Pelvic Med Reconstr Surg*. 2019 Jan 17;
22. Greenwell TJ, Castle C, Andrich DE, MacDONALD JT, Nicol DL, Mundy AR. REPEAT URETHROTOMY AND DILATION FOR THE TREATMENT OF URETHRAL STRICTURE ARE NEITHER CLINICALLY EFFECTIVE NOR COST-EFFECTIVE. *J Urol*. 2004 Jul;172(1):275–7.

Abréviations

FUS : Female urethral stricture / Sténose de l'urètre féminin

BOO : Bladder outlet obstructions / Obstruction sous vésicale

UD : Urethral dilatation / Dilatation urétrale

PDS : Polydioxanone suture

PVR : Post-void residual volume / Résidus post mictionnel

VUD : Video-urodynamic / Vidéo-urodynamique

GILTUS : Gel-Infused Translabial Ultrasound / Echographie translabiale

LUTS : Low urinary tract symptoms / Symptômes du bas appareil urinaire

UTI : Urinary tract infection / Infection urinaire

NVBs : Neurovascular bundles / Bandelettes neurovasculaires

ULT : Urethroplasty with Local Tissue / Urethroplastie avec tissu local

UFG : Urethroplasty with Free Graft / Urethroplastie avec greffon libre

Illustrations

Table 1: Patients characteristics

	N=19
Mean age (years)	58 ±13
Mean BMI (kg/m²)	25.5 ±5.7
ASA score	
1	7 (36.8%)
2	10 (52.6%)
3	2 (10.5%)
Postulated cause of stricture	
Iatrogenic	10 (52.6%)
Post-traumatic	3 (15.8%)
Unknown	6 (31.6%)
History of previous urethral dilation	15 (78.9%)
History of previous urethroplasty	3 (15.8%)
Location of the stricture	
Distal urethra	3 (15.8%)
Mid urethra	13 (68.4%)
Proximal urethra	3 (15.8%)
Mean length of the stricture (mm)	11.1 ±0.6
Preoperative symptoms	
Recurrent urinary tract infections	6 (31.6%)
Storage symptoms	11 (57.9%)
Voiding symptoms	18 (94.7%)
Pain	4 (21%)
Preoperative work-out	
Uroflow and post-void residual	19 (100%)
Urodynamics with pressure flow studies	11 (57.9%)
Urethrocystoscopy	14 (73.7%)
Video-Urodynamic (VUD)	13 (68.4%)
Ultrasound (GITLUS)	10 (52.6%)

GITLUS : Gel-Infused Translabial Ultrasound

Table 2: Perioperative outcomes

	N=19
Mean operative time (minutes)	126.6 ±32.2
Mean estimated blood loss (ml)	53.9 ±60.5
Median length of stay (days)	1 (range: 0-3)
Median length of catheterization (days)	15 (range: 9-23)
Postoperative complications	2 (10.5%)
Clavien grade 1-2	2 (10.5%)
Clavien grade 3 to 5	0 (0%)
Readmission	0 (0%)

Table 3: Functional outcomes

	N=19
At 1 to 3 months	
Clinical success	18 (94.7%)
Patient global impression of improvement	
Very much better	6 (31.6%)
Much better	10 (52.6%)
Better	2 (10.5%)
Unchanged	1 (5.3%)
Worse to very much worse	0 (0%)
Maximum urinary flow rate (ml/s)	
Preoperatively	7.4±6.7
At 1 to 3 months	18.3±11.3
p-value	0.004
Post void residual (ml)	
Preoperatively	161.1±182
At 1 to 3 months	41.9±56.2
p-value	0.004
<i>De novo</i> stress urinary incontinence	3 (15.8%)
Resolution of	
Recurrent UTI	4/6 (66.7%)
Voiding symptoms	15/18 (83.3%)
Storage symptoms	4/11 (36.4%)
Pain	3/4 (75%)

At 1 year (N=11)	
Clinical success	10 (90.9%)
Patient global impression of improvement	
Very much better	2 (18.2%)
Much better	4 (36.4%)
Better	4 (36.4%)
Unchanged	1 (9.1%)
Worse to very much worse	0 (0%)
Maximum urinary flow rate (ml/s)	
Preoperatively	6.5±7.1
At 1 year	12.1±10.9
p-value	0.08
Post void residual (ml)	
Preoperatively	234.9±202.3
At 1 year	122.6±167.2
p-value	0.10
De novo stress urinary incontinence	1 (9.1%)
Sexual dysfunction	1 (9.1%)
At last follow-up (N=19)	
Median follow-up (months)	12 (range: 1-49)
Clinical success	17 (89.5%)
Patient global impression of improvement	
Very much better	4 (21%)
Much better	8 (42.1%)
better	5 (26.3%)
Unchanged	1 (10.5%)
Worse to very much worse	0 (0%)
Maximum urinary flow rate (ml/s)	
Preoperatively	7.4±6.7
At 1 year	15.2±10.2
p-value	0.008
Post void residual (ml)	
Preoperatively	161.1±182
At 1 year	71.5±84.6
p-value	0.01

UTI : urinary tract infection

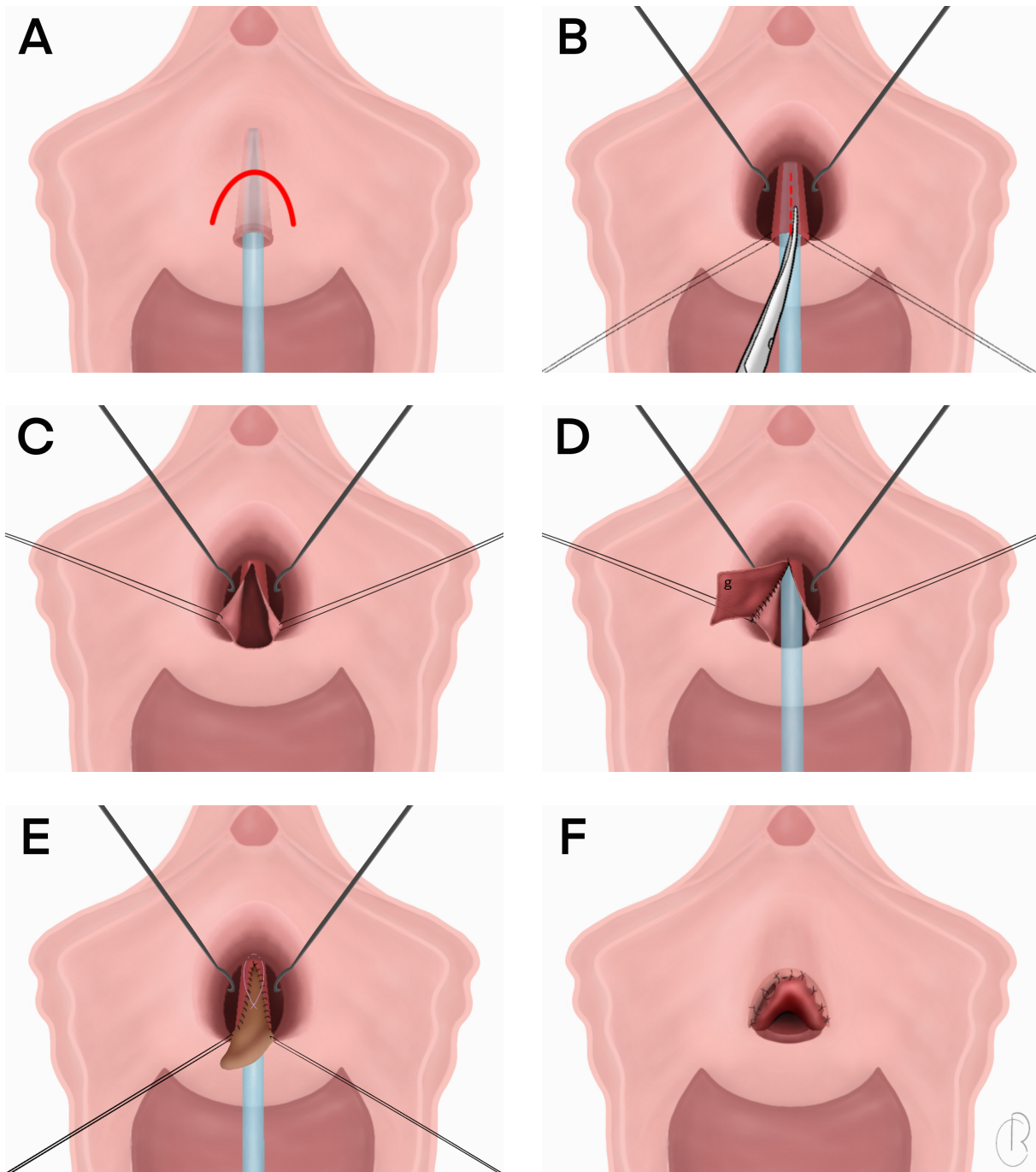


Figure 1 – Surgical procedure.

A: Inverted “U” shape semi lunar incision above the urethral meatus.

B: After having dissected the plane between the underlying urethra and overlying clitoral cavernous tissue, a dorsal urethrotomy is performed at a 12 o’ clock position until the healthy proximal urethra is reached.

C: Holding stitches are placed for better exposure of the opened urethra.

D: The graft (g) is anastomosed to the right margin of the urethral plate.

E: After having sutured the graft to the left edge of the urethral incision, the graft is quilted to the dorsal periurethral tissue to ensure a proper back in.

F: The distal part of the graft is sutured to the superior edge of the periurethral incision in order to recreate the ventral aspect of the urethral meatus.

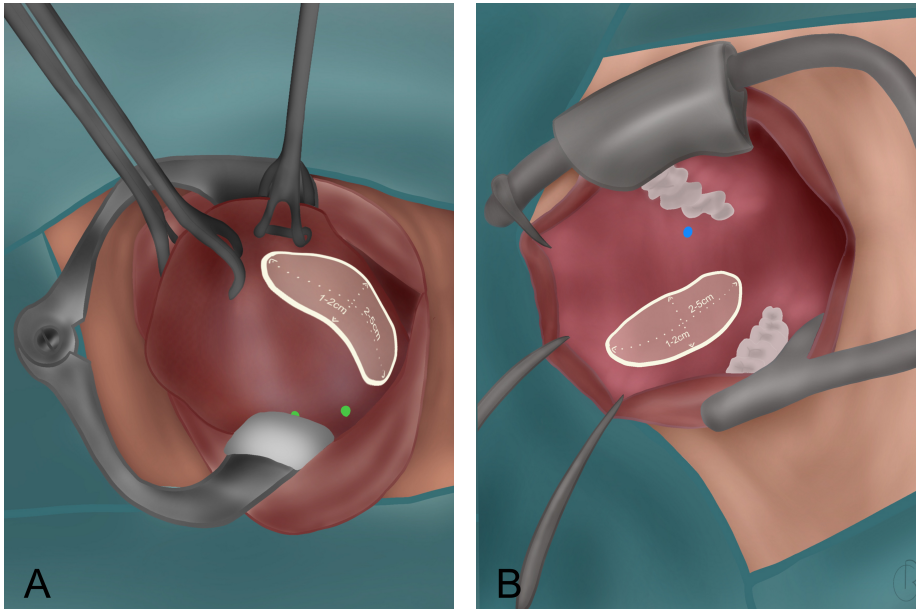


Figure 2 – Oral mucosa graft harvest area. A: Lingual mucosa. Green points materialize Wharton's ducts orifices. B: Buccal mucosa. The blue point materializes the right Stensen's duct orifice.

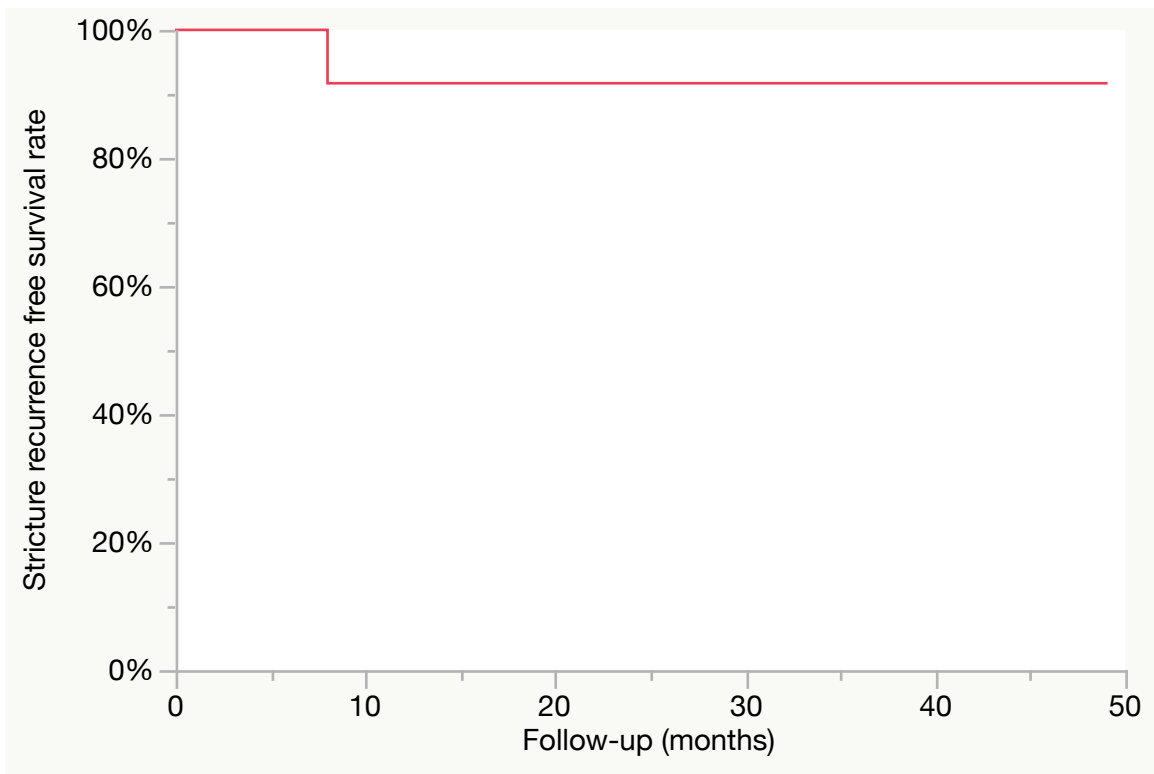


Figure 3 – Stricture recurrence free survival
1-year estimated recurrence free survival= 91.7%

RICHARD Claire - Uréthroplastie dorsale par greffon de muqueuse orale dans les sténoses de l'urètre féminin.

32 feuilles., 2 illustrations., 1 graphique., 3 tableau. 30 cm. Thèse : Médecine ; Rennes 1; 2021 ; N°

Introduction – L'objectif de cette étude était d'évaluer les résultats de l'uréthroplastie dorsale par greffon de muqueuse orale pour les sténoses de l'urètre féminin. **Méthodes** – Toutes les femmes ayant été opérées d'une uréthroplastie dorsale par greffon de muqueuse orale (buccale ou linguale) pour une sténose de l'urètre entre 2011 et 2020 dans deux centres universitaires ont été incluses. Les critères d'exclusion étaient les patientes âgées de moins de 18 ans, les patients de sexe masculin ou la réalisation d'une uréthroplastie pour d'autres indications que la sténose de l'urètre (ex : érosion prothétique). Quatre chirurgiens ont réalisé les uréthroplasties suivant une technique standardisée. Le critère de jugement principal était le succès clinique défini comme toute amélioration subjective des symptômes du bas appareil urinaire d'après l'auto-évaluation des patientes 1 à 3 mois après l'ablation de la sonde vésicale. **Résultats** – Dix-neuf patientes ont été incluses durant la période de l'étude. Le temps opératoire moyen était de 126.6 minutes et la durée de séjour moyenne d'un jour (0-3). Il y a eu deux complications post opératoires mineurs (une infection urinaire et une sinusite, Clavien 2). Le taux de succès clinique était de 94.7% entre 1 à 3 mois et 90.9 % à un an. Après une durée moyenne de suivi de 12 mois (1-49), il y a eu une récurrence (5.3%), le succès clinique était atteint pour 17 patientes (89.5%) et le débit urinaire maximal ainsi que le résidu post mictionnel étaient significativement améliorés (15.2 vs. 7.4 ml/s en pré opératoire; $p=0.008$ et 71.5 vs. 161.1 ml en pré opératoire ; $p=0.001$ respectivement). Le taux d'incontinence d'effort de novo était de 15.7% entre 1 à 3 mois et 9.1% à un an. **Conclusion** – L'uréthroplastie dorsale par greffon de muqueuse orale pour les sténoses de l'urètre féminin semble être une technique faisable par différents chirurgiens et est associée à une morbidité post opératoire faible et des résultats fonctionnels satisfaisants avec un taux de récurrence faible. D'autres séries avec de plus larges échantillons et des durées de suivi plus longues sont nécessaires pour confirmer ces résultats.

Background - Female urethral stricture (FUS) is a rare, but also largely underdiagnosed condition. Urethral dilation and vaginal flap urethroplasty have been the most commonly described treatments for FUS. **Objective** - The aim of this study was to assess the outcomes of dorsal onlay oral mucosa graft urethroplasty for FUS. **Design settings and participants** - We retrospectively reviewed the charts of all female patients who underwent dorsal onlay oral (buccal or lingual) mucosa urethroplasty for urethral stricture between 2011 and 2020 at two academic institutions. The exclusion criteria were patients under 18-year-old, or urethroplasty performed for other indications than urethral stricture (e.g. sling erosion). Surgical procedure: Four surgeons performed the urethroplasties using a standardized technique: suprameatal incision, dissection and longitudinal opening of the dorsal aspect of the urethra, harvest of the oral mucosa graft, graft onlay sutured into the urethral opening. Outcomes measurements and statistical analysis. The primary endpoint was clinical success defined as any subjective improvement in LUTS self-assessed by the patients 1 to 3 months after catheter removal. **Results and limitations** - Nineteen patients were included over the study period. The mean operative time was 126.6 minutes and the median length of hospital stay was one day (range:0-3). There were two postoperative complications both of which were minor (1 UTI and 1 sinusitis, Clavien grade 2). The clinical success rate was 94.7% at 1 to 3 months and 90.9 % at 1 year. After a median follow-up of 12 months (range 1-49) there was one recurrence (5.3%), clinical success was achieved in 17 patients (89.5%) and both the maximum urinary flow rate and post void residual were significantly improved (15.2 vs. 7.4 ml/s preoperatively; $p=0.008$ and 71.5 vs. 161.1 ml preoperatively; $p=0.001$ respectively). The de novo stress urinary incontinence rate was 15.7 % at 1 to 3 months and 9.1% at 1 year. **Conclusion** - Dorsal onlay oral mucosa graft urethroplasty for FUS appears feasible across multiple surgeons and is associated with a low perioperative morbidity, satisfactory functional outcomes and a low recurrence rate. Other series with larger sample size and longer follow-up are needed to confirm these findings.

Rubrique de classement : UROLOGIE

Mots-clés : Sténose urètre féminin ; Uréthroplastie ; Reconstruction ; Symptômes du bas appareil urinaire ; Muqueuse orale

Mots-clés anglais MeSH : Female; Mouth mucosa; Reconstructive surgical procedures; Urethral stricture

Président : Monsieur le Professeur Karim BENSALAH

JURY :

Assesseurs : Monsieur le Docteur Benoît PEYRONNET [directeur de thèse]
Monsieur le Professeur Romain MATHIEU-SANQUER
Madame la Professeure Célia RAVEL
Monsieur le Docteur Andrea MANUNTA
Monsieur le Docteur Benjamin BRUCKER