



HAL
open science

A comparative study of three-dimensional cone-beam CT sialography and ultrasonography in detection of non-tumoral salivary duct pathologies

Volkan Cetinkaya

► **To cite this version:**

Volkan Cetinkaya. A comparative study of three-dimensional cone-beam CT sialography and ultrasonography in detection of non-tumoral salivary duct pathologies. Médecine humaine et pathologie. 2022. dumas-03780116

HAL Id: dumas-03780116

<https://dumas.ccsd.cnrs.fr/dumas-03780116v1>

Submitted on 19 Sep 2022

HAL is a multi-disciplinary open access archive for the deposit and dissemination of scientific research documents, whether they are published or not. The documents may come from teaching and research institutions in France or abroad, or from public or private research centers.

L'archive ouverte pluridisciplinaire **HAL**, est destinée au dépôt et à la diffusion de documents scientifiques de niveau recherche, publiés ou non, émanant des établissements d'enseignement et de recherche français ou étrangers, des laboratoires publics ou privés.

IMPORTANT : OBLIGATIONS DE LA PERSONNE CONSULTANT CE DOCUMENT

Conformément au *Code de la propriété intellectuelle*, nous rappelons que le document est destiné à un **usage strictement personnel**. Les "analyses et les courtes citations justifiées par le caractère critique, polémique, pédagogique, scientifique ou d'information" sont autorisées sous réserve de mentionner les noms de l'auteur et de la source (article L. 122-4 du *Code de la propriété intellectuelle*). Toute autre représentation ou reproduction intégrale ou partielle, faite sans le consentement de l'auteur ou de ses ayants droit, est illicite.

De ce fait, nous vous rappelons notamment que, **sauf accord explicite** de l'auteur de la thèse ou du mémoire, **vous n'êtes pas autorisé** à rediffuser ce document sous quelque forme que ce soit (impression papier, transfert par voie électronique, ou autre). Tout contrevenant s'expose aux peines prévues par la loi.

NANTES UNIVERSITÉ

FACULTÉ DE MÉDECINE

Année : 2022

N°

THÈSE

pour le

DIPLÔME D'ÉTAT DE DOCTEUR EN MÉDECINE

CHIRURGIE ORALE

par

Volkan CETINKAYA

Présentée et soutenue publiquement le 17 juin 2022

**A COMPARATIVE STUDY OF THREE-DIMENSIONAL CONE-BEAM CT
SIALOGRAPHY AND ULTRASONOGRAPHY IN DETECTION OF NON-
TUMORAL SALIVARY DUCT PATHOLOGIES**

Président : Monsieur le Professeur Pierre CORRE

Directeur de thèse : Monsieur le Docteur Hélios BERTIN

Remerciements

A Monsieur le Professeur Pierre Corre,

Je vous suis reconnaissant d'avoir accepté d'être le président de mon jury, c'est un grand honneur pour moi.

J'ai toujours admiré votre humilité et surtout votre accessibilité ainsi que votre écoute. Merci pour votre accueil chaleureux dans votre service.

Recevez en témoignage mon plus grand respect.

A Monsieur le Professeur Philippe Lesclous,

Je vous remercie d'avoir accepté de faire partie du jury.

Votre disponibilité et votre soutien durant mon internat m'ont été très précieux. Merci d'avoir toujours été à l'écoute et très compréhensif à chaque fois que j'ai fait appel à vous.

Veillez trouver dans ce travail un témoignage de ma profonde reconnaissance.

A Monsieur le Docteur Hélios Bertin,

Tu as une place primordiale dans la réalisation de ce travail, je te suis très reconnaissant de m'avoir épaulé dans ces moments difficiles. Merci pour ta disponibilité et ton écoute, merci d'avoir partagé tes connaissances avec moi.

Bon séjour au Canada.

A Madame le Docteur Anne-Sophie Delemazure,

Je te remercie d'avoir accepté de faire partie du jury. Tes conseils ont apporté un point de vue différent à mon travail.

A Monsieur le Docteur Maxime Guillemin,

Tu as été un vrai pilier dans le choix de ma ville et de ma spécialité. Je te remercie pour ta disponibilité et surtout tes conseils avisés qui m'ont rassuré et m'ont aiguillé.

J'espère continuer à travailler avec toi et à te côtoyer autant que le temps nous l'accorde.

Au service de Neurotraumatologie,

Merci au Docteur Philippe Cam et au Docteur Joseph Cristini de m'avoir pris sous leur aile pour mon premier stage. Vous m'avez appris tout concernant la neurochirurgie, merci pour votre disponibilité et votre soutien, sans vous je n'aurais pas vécu le même stage. Merci à mes co-internes avec qui j'ai passé de très bons moments. Je pense également à l'équipe paramédicale qui était présente

Au service d'ORL,

Merci au Professeur Olivier Malard de m'avoir accueilli dans le service et également aux autres chefs de l'équipe. J'ai beaucoup appris lors de ce stage. Merci à mes co-internes avec qui j'ai passé de très bons moments, qui m'ont aidé et avec qui j'ai eu d'énormes fous rires. Merci à toute l'équipe paramédicale qui m'a épaulé et avec qui j'ai passé des moments uniques.

Au service de Chirurgie Maxillo-Faciale de La Roche-sur-Yon,

Au Docteur Philippe Lebaud, merci de m'avoir accueilli dans le service, j'ai passé de très bons moments avec toi. Ta motivation et ton abnégation sont des qualités que j'admire. Je remercie également les autres chefs de l'équipe qui m'ont épaulé durant ce semestre et l'équipe paramédicale avec qui j'ai passé d'excellents moments.

Au service de Chirurgie Maxillo-Faciale de Nantes,

Au Docteur Marine Anquetil qui était très disponible et très à l'écoute, j'ai adoré ce semestre. A mes co-internes avec qui j'ai passé de très bons moments, inoubliables pour la plupart, à toute l'équipe paramédicale avec qui a été très disponible pour moi.

Au Centres de Soins Dentaires,

Ma maison, toujours très heureux de la retrouver chaque été. A tous mes chefs, co-internes et à toute l'équipe paramédicale, merci pour ces bons moments passés ensemble, ces fous rires et surtout ces fausses rumeurs auxquelles tout le monde croît.

Au TEC,

Merci à toute l'équipe paramédicale pour tous les moments passés, les bons comme les plus difficiles, tout a été plus simple avec vous.

Au PTMC,

Merci à toute l'équipe paramédicale avec qui j'ai tissé des liens, j'ai adoré mes moments passés, même quand je restais plusieurs heures debout.

A ma Famille, ceux pour qui et surtout grâce à qui j'ai parcouru tout ce chemin,

Papa, tu m'as inculqué la valeur du travail acharné, tu m'as poussé à me fixer un objectif et à l'atteindre malgré toutes les difficultés rencontrées. Merci d'avoir été présent durant toutes ces années difficiles à étudier la médecine.

Maman, tu as été présente durant toutes ces années où je révisais, tu as facilité ma tâche tous les jours face à cette montagne de travail. Merci d'être là pour moi et de me soutenir quoi qu'il arrive.

Tolga, celui avec qui j'ai tout partagé, un vrai modèle pour moi, merci d'être présent et de me soutenir quoi qu'il arrive, je suis fier de tout ce que tu as accompli.

Dilara, ma confidente, celle avec qui j'ai tout partagé également, merci pour ton soutien infaillible et pour ton écoute, je sais que je peux toujours compter sur toi, je suis également fier de ce que tu accomplis.

A ma Famille en Turquie,

Mes grands-parents, mes oncles et tantes, mes cousins, vous avez tous eu une place importante dans mon éducation, dans la personne que je suis aujourd'hui. Buraya gelmemde çok büyük payiniz var, hiç birinizi unutmuyorum ve hepimizi özleyorum.

A Redha,

Mon frère, tant physiquement que mentalement, tu as été très important dans ma vie et tu le seras encore. Merci pour ta sagesse et tes conseils avisés qui m'ont permis de prendre les bonnes décisions plus d'une fois.

A Ayad,

Mon frère père de famille, un exemple de sagesse et de maturité pour moi, tes conseils sont toujours bons à entendre et ta compagnie un plaisir. J'espère continuer à te côtoyer autant que la vie nous l'accordera.

A Doria, merci d'avoir été présente ces dernières années (même si personne ne connaît le nombre exact), tu m'as soutenu durant tous ces moments difficiles. J'ai beaucoup appris à tes côtés, tu m'as aidé à devenir plus mature, je t'en suis extrêmement reconnaissant. J'admire ta force de caractère.

A S. City,

A ce groupe inégalable avec ses membres uniques et originaux, tous ces moments lunaires passés dans toutes ces villes. C'est toujours un grand honneur de prendre part à ses rendez-vous toujours plus gigantesques.

A mes amis parisiens,

Je suis nostalgique de ma période où j'avais encore des cheveux et où je me souciais uniquement de passer du bon temps avec vous.

A mes amis et co-internes nantais,

A ces nombreuses soirées et activités avec vous, j'ai trouvé de belles amitiés et des personnalités uniques.

A la 13^{ème} Légende,

Cette talentueuse équipe composée de génies, on continuera à régner sur le PIMP tant qu'on le voudra, c'est toujours un honneur et un plaisir de jouer à vos côtés.

A Don Bosco,

Pour cette saison que je viens de passer avec vous, j'ai trouvé une vraie famille. En espérant que ce groupe reste intact et qu'on poursuive nos montées annuelles.

Table des matières

Abbreviations	7
Abstract	8
Introduction	9
Materials and methods	10
1. Achievement of imaging examinations	10
2. Image analysis (for 3D-CBCT) and comparison of imaging modalities	11
3. Statistical analysis	11
Results	12
1. Epidemiological results	12
2. Comparison of imaging procedures	13
3. Secondary endpoints	17
Discussion	18
Conclusion	21
References	22
Figure legends	26

Abbreviations

3D-CBCT: Three-Dimensional Cone Beam Computed Tomography

US: Ultrasonography

CT-scan: Computed Tomography Scan

MRI: Magnetic Resonance Imaging

NPV: Negative Predictive Value

PPV: Positive Predictive Value

IC: Confidence Interval

Abstract

Introduction: Non-tumor salivary gland diseases are the most common disorders of the salivary glands. Imaging the salivary gland is important to diagnose the type of lesion and to choose the suitable treatment. The purpose of this study was to compare 3D-CBCT sialography and ultrasonography (US) for the diagnosis of non-tumoral salivary duct pathologies.

Materials and methods: We retrospectively compared the two imaging modalities carried out in the same patients referred for salivary obstructive symptoms, salivary inflammation, or secretion disorders. The primary endpoint was the examination's capacity of the imaging procedure to diagnose a lesion (sensitivity). The secondary objectives were the detection rates according to the type of lesion (lithiasis, stenosis, dilatation), the analysis of the causes of failure, the parameters of radiation exposure and safety (for 3D-CBCT sialography).

Results: On 236 patients who received a 3D-CBCT sialography between 2017 and 2021 in our institution, 157 were finally included in per-protocol analysis. 3D-CBCT sialography allowed to detect ductal lesions in 113 patients versus 86 with ultrasonography; higher sensitivity and negative predictive value were observed with 3D-CBCT sialography than US: 0.85 vs 0.65 and 0.70 vs 0.44 respectively. 3D-CBCT sialography outperformed US for visualization of sialolithiasis as evidenced by high sensitivity, sensibility, NPV and PPV (0.80, 0.82, 0.88 and 0.70 respectively). Ultrasound did not reveal any salivary stenosis (19 cases diagnosed by 3D-CBCT sialography). However, a catheterization failure was observed with 3D-CBCT sialography in 30 patients (12.8%).

Conclusion: Our study confirms the use of sialography as a first-line examination as an alternative to ultrasound for the exploration of salivary ductal pathologies.

Keywords

Cone-Beam CT; Sialography; Ultrasound; Salivary Duct pathology

Introduction

Non-tumor salivary gland diseases are the most common disorders of salivary glands, affecting nearly 1% of the population (1–3). These pathologies include salivary stone, ductal strictures, chronic inflammation and anatomical abnormalities (4,5). Clinically, these pathologies cause a decrease of salivary flow which is responsible for obstructive symptoms including salivary pain and swelling at mealtime. The main cause of salivary gland obstruction is represented by sialolithiasis in 60-70% of cases, followed by stenosis and ductal inflammation in 15-25% and 5-10% of cases, respectively (4,6). There are many imaging techniques available to diagnose the salivary ductal lesions. Among these techniques, ultrasonography (US), two-dimensional (2D) or three-dimensional (3D)-plain sialography, CT-scan, MRI and scintigraphy have been identified (2,7,8). In addition to diagnosis, salivary imaging provides information on the size, the location, the number, and the morphology of the lesions. This is essential in lithiasis pathology to choose the most suitable technique for stone removal. The same applies to salivary stenosis pathology where the location, type and length of the lesions are important parameters (9–11).

US is a first-line examination for the diagnosis of ductal and parenchymal pathologies thanks to its accessibility, a low cost, and the absence of radiation exposure. However, US is deficient in identifying the structures behind the bony structures, it does not give a representation of the salivary ducts and struggles to diagnose stones smaller than 2mm or chronic ductal inflammation (12–15). In showing the filled ductal tree, sialography represents the gold standard technique for the diagnosis of non-tumor salivary gland diseases (1,16,17). Conventional 2D-plain radiography is tending to be replaced by 3D-sialography representing a more accurate examination (1,18). The 3D-Cone-Beam CT (3D-CBCT)-sialography has showed to give 3D images of the ductal system with a high spatial resolution (5,18–21). Various studies have showed its superiority to conventional sialography in exploring the ductal tree until the fifth or the sixth divisions (1,21). Nevertheless, this technique requires salivary catheterization with a risk of failure, the injection of an iodinated contrast product and exposes to a significant irradiation.

Currently, there is no objective study that compares ultrasonography with 3D-CBCT sialography. It is not clear which of these two procedures is most effective for the first-line diagnosis of non-tumor salivary gland diseases. The purpose of this study was to compare ultrasonography and 3D-CBCT sialography for the diagnosis of non-tumoral salivary duct pathologies.

Materials and methods

This monocentric retrospective study compared both imaging modalities (US and 3D-CBCT sialography) carried out in the same patients. All patients who received 3D-CBCT sialography at our institution between January 2017 and December 2021 were included in this study. These patients were seen for the first time or referred to the maxillofacial surgery department of the University Hospital of Nantes (Nantes, France) for salivary obstructive symptoms, salivary inflammation (acute or chronic) or salivary secretion disorders (mainly dry mouth). Exclusion criteria for this study was the absence of an ultrasound examination making it impossible to compare the two procedures. Patients with 3D-CBCT sialography failure were secondarily excluded from the per-protocol analysis. For each patient, clinical data were collected: age, gender, medical background (especially if the patient had a salivary gland surgery or a radioactive iodine therapy), complaints (salivary colic, salivary hernia, infection, swelling, pain, asymptomatic), affected gland, side, evolution of symptoms. When available, we also recorded the results of a possible sialoendoscopy procedure, which we considered to be the gold standard for the diagnosis of lesions. Due to the retrospective nature of this study, it was granted in written an exemption of ethics committee, as per French legislation article L. 1121-1 paragraph 1 and R1121-2 of the Public Health Code.

1. Achievement of imaging examinations

Ultrasound examinations were performed by multiple radiologists. The analysis included the entire gland involved from the main duct to the glandular parenchyma. The salivary stones were visualized as a hyperechogeneous image with a posterior dark cone. In some cases, the stones were suspected indirectly as ductal dilatation which was measured by the sonographer. When possible, the stone was searched in the main canal. The gland was measured to assess any salivary hypertrophy. Finally, the parenchyma was studied to identify heterogeneity, an inflammatory Doppler signal, and the presence of microcysts as observed in chronic sialadenitis.

The technique for 3D-CBCT sialography was previously described (20). All the procedures were performed by the same examiner (H.B.). Briefly, after locating the salivary duct ostium, 0.5-1.0 mL of high-concentration water-soluble iodinated contrast product (XENETIX 300®, 300 mg/mL; Guerbet, France) was injected under usual aseptic conditions using a lachrymal cannula (25G Moria® L12 mm; MORIA Inc., Doylestown, PA). The iodine contrast was maintained in the gland by placing a microsurgical clamp (Biover TKM2, Hergiswil,

Switzerland) on the ostium of the Wharton's duct or with a plastic straight Halstead clamp placed on the ostium of the Stensen's duct. Image acquisition was performed immediately after injection, on a wide-field CBCT device (NewTom VGi, QR, Verona, Italy). Front and profile scout views were first achieved. Special exposure parameters were used to limit the radiation: reduced field of view 75 x 120mm focused on the symptomatic gland, 110 kV, tube current and exposure time were modulated according to the scout views. The data acquisition time was 9 s. The radiation dose and early adverse effects of cannulation (bleeding, pain, canal perforation and iodine allergy) were systematically recorded.

2. Image analysis (for 3D-CBCT sialography) and comparison of imaging modalities

Imaging data were archived in an imaging software (CARESTREAM View PACS v. 11.3; Carestream Health, Inc., Rochester, NY, 2011). The analysis aimed to identify a lesion in the salivary duct tree (primary endpoint). Sialolithiasis appeared as a subtraction image within a hyperintense salivary duct on the 3D-CBCT sialography. Dilatation was diagnosed as sialectasis in the ductal salivary system while ductal stenoses appeared as a signal defect of the salivary ducts. Secondary endpoints were the type of lesion observed, their precise location (anterior third, middle third and posterior third of the main salivary duct), number and size of sialolithiasis. The radiation exposure parameters were systematically reported.

The main objective of this study was to compare the detection rates of a salivary ductal lesion between the two procedures (sensitivity of the examinations). The secondary objectives were the detection rates according to the type of lesion (lithiasis, stenosis, dilatation), the analysis of the causes of failure for the 3D-CBCT sialography, as well as the parameters of radiation exposure and the search for adverse effects (3D-CBCT sialography).

3. Statistical analysis

The statistical analysis was performed using GraphPad Prism 9.0 software for Mac (GraphPad Software, La Jolla, CA, USA). In the few cases where several lesions were identified in the same patient, these were analyzed independently and compared between the two imaging modalities. A χ^2 test was used to determine the differences between both imaging modalities for the identification of lesions. In cases of a small numbers of patients, a Fischer's exact test was used to compare the data. A p-value of less than 0.05 was taken to indicate statistical significance.

Results

1. Epidemiological results

Between the 1st of January 2017 and the 31st of December 2021, 236 patients were referred for salivary symptoms and underwent a 3D-CBCT sialography. Among these patients, 79 were secondary excluded from the study: 30 patients were excluded for a sialography failure mainly for a defect of catheterization, or sublingual opacification, while 49 patients did not undergo an US imaging. Our per-protocol analysis therefore included 157 patients. The mean age of patients was 50.4 years, 93 were females (59.3%) and 64 were males (40.7%). Thirteen patients had already received a surgery for a stone removal, 2 patients had been treated by radioactive iodine therapy for a papillary carcinoma of the thyroid gland. The submandibular gland was mostly involved in two third of the cases. Regarding the symptoms, obstructive signs were the most frequent, followed by infection and gland swelling. Most patients consulted for symptoms that had been occurring for more than 3 months. Patients' characteristics are showed in table 1.

Patients' epidemiological and clinical characteristics	
Age (in years): mean, \pm S.D.	50.4 \pm 16.6
Gender: Females/Males, n (%)	93 (59.3%) / 64 (40.7%)
Affected gland:	
Submandibular gland, n (%)	97 (61.8%)
Parotid gland, n (%)	56 (35.7%)
Multifocal, n (%)	4 (2.5%)
Affected side:	
Left, n (%)	80 (50.9%)
Right, n (%)	65 (41.4%)
Both, n (%)	12 (7.7%)
Symptoms:	
Hernia and/or colic	96 (61.1%)
Infection	32 (20.4%)
Swelling	18 (11.5%)
Non typical pain	8 (5.1%)
Asymptomatic	3 (1.9%)
Evolution of symptoms:	
Less than 14 days	7 (4.5%)
2-12 weeks	47 (29.9%)
More than 3 months	103 (65.6%)

Table 1. Epidemiologic and clinical characteristics of the patients. n, number of patients; SD, standard deviation.

2. Comparison of imaging procedures

Regarding the primary endpoint, 3D-CBCT sialography detected a salivary ductal lesion in 113 patients while US detected a salivary lesion in 86 patients (table 2). When analyzing the discordant data, it was observed that 13 lesions were seen with US but were not seen in 3D-CBCT sialography, and 40 lesions were seen in 3D-CBCT sialography but not in the US modality. Regardless of the type of lesion analyzed, the sensitivity and the negative predictive value (NPV) were higher for 3D-CBCT sialography than for ultrasound: 0.85 [IC95% 0.76-0.91] vs 0.65 [IC95% 0.55-0.73] and 0.70 [IC95% 0.56-0.82] vs 0.44 [IC95% 0.33-0.55] respectively. The specificity and the positive predictive value (PPV) were higher with US than for 3D-CBCT sialography: 0.70 [IC95% 0.56-0.82] vs 0.44 [IC95% 0.33-0.55] and 0.85 [IC95% 0.76-0.91] vs 0.65 [IC95% 0.55-0.73] respectively. Among the 13 lesions detected by US and not diagnosed by 3D-CBCT sialography, only 3 lesions were confirmed by sialoendoscopy and there was spontaneous improvement in symptoms and/or no lesion found by sialoendoscopy in the 10 other cases.

3D-CBCT sialography	Ultrasonography		TOTAL
	Yes	No	
Yes	73	40	113
No	13	31	44
TOTAL	86	71	157

Table 2. Primary endpoint: detection of a salivary duct lesion, χ^2 test ($p < 0.0001$)

Most of lesions found were sialolithiasis in 88 cases (62%). 3D-CBCT sialography allowed to detect 71 lithiasis while US diagnosed 70 sialolithiasis (table 3). The mean lithiasis size was 7.62 ± 3.91 mm in 3D-CBCT sialography versus 6.41 ± 3.87 mm in US ($p=0.08$). Most of calculus were located in the posterior part of the main duct or in intra-glandular situation (50 cases), while anterior part and medium part were involved in 14 and 10 cases respectively (figure 1). US and 3D-CBCT sialography failed to diagnose a salivary stone in 18 and 17 cases respectively. There was no difference in lithiasis location in the salivary duct for 21 patients, while the examinations were discordant for 6 patients. With regard to the 18 cases of failure in ultrasound, there was no lesion identified in 15 cases, and 3 cases were classified as dilatations in US with no visible stone. In these cases, stones not detected by US presented a mean size of 6.30 ± 4.56 mm, there was no predominant location for these failure cases (9 calculus were posterior, 7 were anterior and 2 were located in the middle third of the main duct). For 11

patients a sialoendoscopy or a surgical procedure were performed allowing to identify and to treat a sialolithiasis in 10 cases, while one patient presented with a ductal dilatation. Regarding the 17 cases of diagnosis failure in 3D-CBCT sialography but confirmed sialoliths in US, 4 were isolated ductal dilatation and one was a stenosis in sialography, while 12 others were normal procedures in sialography. In these patients, sialoendoscopy was performed in 6 cases confirming 2 cases of dilatations, 2 cases of stenosis and 2 cases of lithiasis with a mean 4mm size. Failures of 3D-CBCT sialography to detect a lithiasis concerned specifically the distal localization (i.e. intraglandular stones). 3D-CBCT sialography outperformed US for visualization of sialolithiasis as evidenced by high sensitivity, sensibility, NPV and PPV: 0.80 [IC95% 0.69-0.88] vs 0.75 [IC95% 0.63-0.83], 0.82 [IC95% 0.67-0.91] vs 0.67 [IC95% 0.53-0.79], 0.88 [IC95% 0.78-0.94] vs 0.78 [IC95% 0.67-0.86] and 0.70 [IC95% 0.56-0.82] vs 0.63 [IC95% 0.49-0.75] respectively.

3D-CBCT sialography	Ultrasonography		TOTAL
	Visualized	Not visualized	
Visualized	53	18	71
Not visualized	17	0	17
TOTAL	70	18	88

Table 3. Detection of a sialolithiasis, Fischer exact test ($p=0,019$)

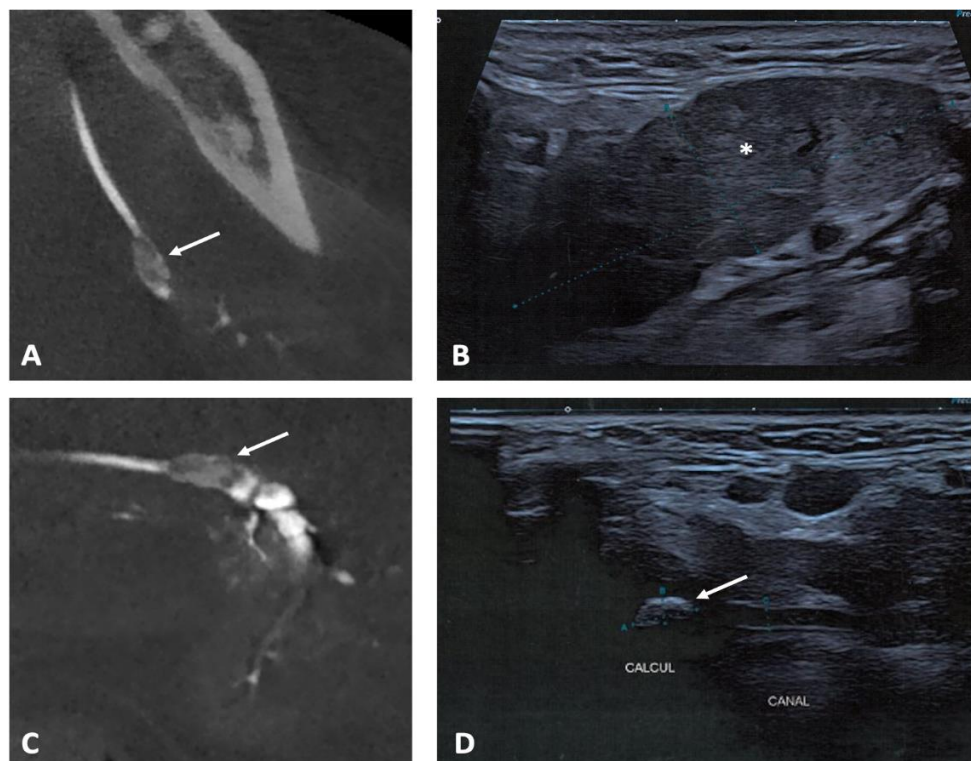


Figure 1

A dilatation was diagnosed in 35 cases (24.6%) by both modalities (figure 2). 3D-CBCT sialography allowed to diagnose a dilatation in 27 patients while US confirmed the diagnosis in 20 patients (table 4). US failed to diagnose a dilatation in 15 patients (sialolithiasis were confirmed in 4 cases and no lesion was found in 11 cases), while 3D-CBCT sialography failed to detect a dilatation in 8 patients (3 were finally diagnosed as stenosis, 3 as sialolithiasis and no lesion was found in 2 cases). The locations of dilatations were the same whatever the imaging modality.

3D-CBCT sialography	Ultrasonography		
	Dilatation	No dilatation	TOTAL
Dilatation	12	15	27
No dilatation	8	0	8
TOTAL	20	15	35

Table 4. Detection of a dilatation, Fischer exact test ($p=0.005$)

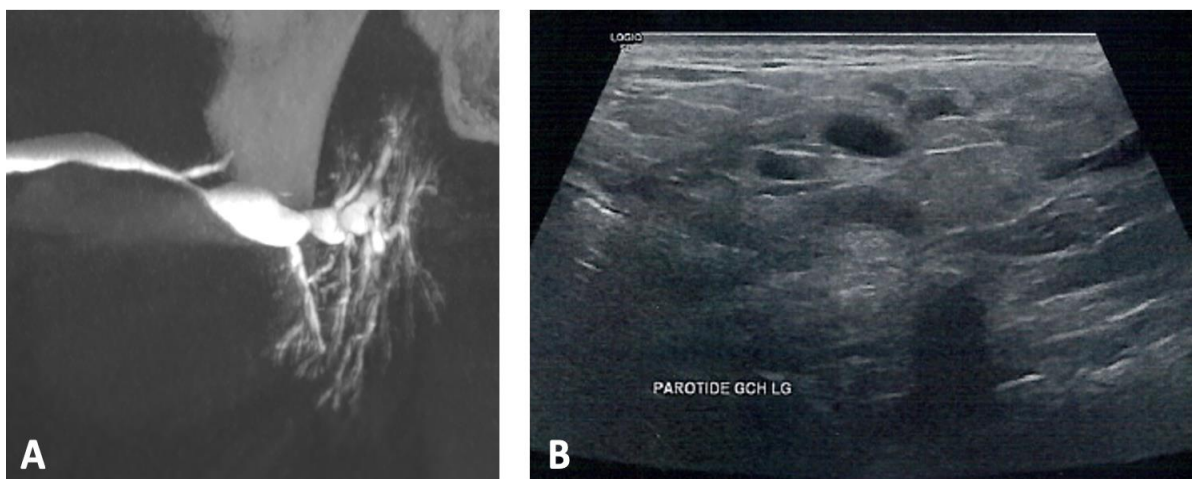


Figure 2

A total of 19 stenosis was diagnosed using 3D-CBCT sialography (13.4% of lesions). These lesions were located in posterior third of the main duct in 5 patients, in anterior third for 4 patients and in middle third for 2 other patients (figure 3). The stenosis was diffused on the main salivary duct in 8 patients. Among these 19 patients diagnosed with stenosis, 3 patients presented with a chronic sialodochitis, 2 received a previous radioactive iodine therapy and 2 patients presented a stenosis secondary to a lithiasis. US was not able to diagnose any stenosis in our study.

3D-CBCT sialography	Ultrasonography		
	Stenosis	No stenosis	TOTAL
Stenosis	0	19	19
No stenosis	0	0	0
TOTAL	0	19	19

Table 5. Detection of a stenosis, Fisher exact test ($p>0.999$)

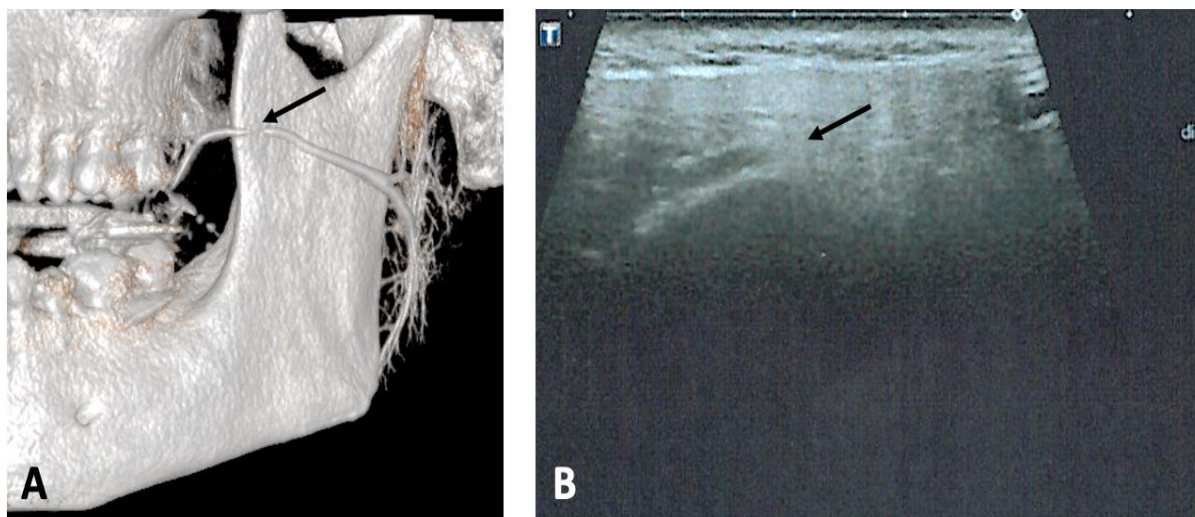


Figure 3

3. Secondary endpoints

In the 236 patients receiving a 3D-CBCT sialography, a catheterization failure was observed in 30 patients (12.8%). These failures were mostly due to a difficulty of cannulation in 26 patients, while three patients presented an obstructive ostial lithiasis with no possibility to cannulate the salivary duct. Another patient received an opacification of the sublingual gland with no visualization of the submandibular gland. No adverse effects of the catheterization (bleeding, perforation) or of the iodine contrast (allergy) were observed or reported by the patients.

Regarding the radiation exposure, the mean Dose Area Product (DAP) generated by CBCT was 235. mGy.cm² and the mean radiation produced was 13,1 mAs.

Discussion

Many imaging modalities have been described for the diagnosis of salivary ductal pathologies. Whatever the technique used, the objective of imaging is to diagnose the lesion, to specify its size and its location in the salivary tree. Indeed, it is on these parameters that the therapeutic strategy of the main salivary pathologies depends. In our current practice, 3D-CBCT sialography is the reference examination that can meet all these objectives. In addition, salivary catheterization provides information on the predictable ease or difficulty of penetration of the salivary ostium in salivary endoscopy. The size of the salivary ducts once dilated is also an important element to consider in sialoendoscopy. In the literature, 3D-CBCT sialography has shown superiority to conventional 2D sialography (1,5,19). This modality is particularly described lately for the diagnosis and follow-up of chronic salivary pathologies such as Sjögren's syndrome (22–24). No study to date has compared 3D-CBCT sialography and ultrasonography for the primary diagnosis of salivary ductal lesion. Our study is therefore the first comparing both imaging procedures and aims to define the place of 3D-CBCT sialography as a first-line examination in non-tumor salivary pathologies. Our series of 236 patients who received 3D-CBCT sialography is the largest in the literature. The study population is comparable to the literature in terms of mean age and female/male distribution (1,18). The submandibular gland was the most affected in 61.8% of cases, in relation to a more frequent lithiasis pathology in this location. In their study on 2277 gland pathologies, Goncalves *et al.* found a submandibular involvement in 57.4% of patients (15). In our study, salivary stones were responsible for the obstructive symptoms in 62% of cases. In the literature, benign salivary gland obstruction seems to be caused by sialoliths in 60-75% of cases and stenosis of the salivary duct in 15-25% of cases (4,6,11,25). Interestingly, more than half of our patients had salivary obstructive symptoms that had lasted for more than 3 months, some for several years. This is due to the patients' tolerance of the hernia episodes which are most often resolved at the end of the meals. Consultation of a specialist is most often motivated by painful episodes of salivary colic or infectious sialadenitis.

With high sensitivity (0.85) and NPV (0.70), our results revealed that 3D-CBCT sialography outperformed US for the diagnosis of main salivary ductal lesions. In particular, sialography was superior to ultrasonography for the visualization of dilatations and ductal stenosis. Nevertheless, stenoses are uncommon pathologies, not easily observable with ultrasonography which does not use the spontaneous contrast of saliva. Indeed, salivary duct can only be

demonstrated when they are filled, which occurs in cases of obstructive salivary stone and advanced stenoses. Some authors recommend the administration of vitamin C or lemon juice to stimulate the secretion and filling of the salivary ducts during the US exam (26,27). In 14 patients with salivary symptoms and failure of a US exam, Kroll *et al.* showed that seven patients presented salivary ductal stenoses mainly located in the main efferent duct or close to the papilla (18). Our results regarding dilatation must be balanced with the artificial ductal expansion created by the injection of the contrast medium in 3D-CBCT sialography, while ultrasound detects spontaneous dilation of the salivary ducts. In addition, with sialography, there is no reference value to qualify as ductal dilatation. Sialoliths were the most represented lesions of the salivary ducts in our series. There did not appear to be any difference between the two imaging tests for the diagnosis of lithiasis. Nevertheless, the comparison of the results with those of sialoendoscopy confirmed the diagnosis of stones in 10 normal ultrasound examinations. Size and location of the lithiasis were comparable to the literature (1,17). The failures of 3D-CBCT sialography for the visualization of calculi were confirmed in only two of the 17 patients with pathological ultrasonography and concerned exclusively very distal intraglandular calculi. 3D-CBCT sialography appeared as a reliable imaging technique for most of ductal lesions compared to ultrasonography. These diagnostic performances of 3D-CBCT sialography had already been highlighted by various authors who showed a higher sensitivity than conventional 2D sialography for the identification of sialolithiasis, the three-dimensional visualization of the ductal system up to the sixth branch (1,5,19). Given its accessibility, a low-cost and ease of performance, ultrasound is considered the first-line examination in salivary lithiasis pathology (4,28). A recent meta-analysis from Kim *et al.* highlighted the excellent sensitivity (0.899), specificity (0.966), negative predictive value (0.808) and positive predictive value (0.986) obtained with US (29). Nevertheless, these results have to be tempered by poorer performances in submandibular localization compared to the parotid gland whereas the submandibular gland is the site of most salivary lithiasis (75-80%) (30). This is partly related to the anatomy of Wharton's canal which is in a buccal position in its medial and anterior portions with the difficulty of identifying lithiasis close to the papilla (12,26). Moreover, ultrasound tends to fail in the case of stones with a diameter of less than 2 mm since these stones do not generate an acoustic shadows (25,31). Some authors consider that 10–20% stones are radiolucent, and thus not detectable by CT or ultrasonography (25). These stones remain visualizable in sialography by appearing as negative images within a canal filled with contrast medium (20). CT-scan and MR sialography represents complementary imaging modalities to diagnose the main salivary ductal lesions (32). CT-scan offers higher specificity than US and

standard x-rays for stone disease by specifying the number, the size and the location of lithiasis (8,33). However, considering the radiation generated and the as low as reasonably achievable principle of radioprotection, CBCT has to be preferred (20). Thanks to a modulation of exposure parameters, we managed to reduce the radiation exposure in 3D-CBCT sialography. Whereas the radiation generated remains higher than conventional radiographs (34,35). Since it is a non-ionizing exam with no need for a duct cannulation, MR-sialography is an alternative for the exploration of parenchymal and ductal lesions of the major salivary glands (25,36–38). However it raises the problems of a poor accessibility, a high-cost and a lower sensitivity for the exploration of the distal divisions of the salivary system (39,40).

Our study suffers from several drawbacks. The first lies in our per-protocol analysis by eliminating from the analysis patients presenting a procedure failure in 3D-CBCT sialography. The salivary catheterism is sometimes a challenge in patients presenting with a low salivary flow, or a stenosis of the papilla. Thus 30 patients (12.8%) presented a failure of catheterization, or the opacification of a sublingual gland with no visualization of the submandibular ductal system. This failure rate is coherent with the literature analysis which reports a 14-15% rate (18,20). The second issue is related to the performance of the ultrasound exams by multiple operators while 3D-CBCT sialography was performed by a single trained operator. This factor is important to consider since operator skills and probably the device used are considered as factors that may influence diagnostic accuracies when US is employed to detect salivary gland stones (29). Furthermore few ultrasound professionals skillfully image the head-and-neck region, and training has probably to be improved (41). Finally, it is regrettable that we did not have a reference imaging examination to compare sialography and ultrasonography. In some cases, the use of sialoendoscopy data allowed us to conclude in cases of discordant procedures. Further studies correlating the data obtained with 3D-CBCT sialography and the intraoperative findings in sialoendoscopy could be of interest.

Conclusion

Our study showed the superiority of 3D-CBCT sialography over ultrasonography for the diagnosis and the localization of the main salivary ductal lesions. This imaging modality could represent a first-line examination of patient with suspicion of lithiasis, stenosis and salivary dilatation, except when the salivary papilla is hardly visible. In addition to a well-conducted examination, 3D-CBCT sialography represents an essential investigation tool to determine the therapeutic strategy.

References

1. Jadu F, Lam E. A comparative study of the diagnostic capabilities of 2D plain radiograph and 3D cone beam CT sialography. *Dentomaxillofac Radiol.* janv 2013;42(1):20110319-20110319.
2. Afzelius P, Nielsen MY, Ewertsen C, Bloch KP. Imaging of the major salivary glands. *Clin Physiol Funct Imaging.* janv 2016;36(1):1-10.
3. Rice DH. Noninflammatory, non-neoplastic disorders of the salivary glands. *Otolaryngol Clin North Am.* oct 1999;32(5):835-42.
4. Koch M, Zenk J, Iro H. Algorithms for Treatment of Salivary Gland Obstructions. *Otolaryngol Clin North Am.* déc 2009;42(6):1173-92.
5. Varoquaux A, Larribe M, Chossegros C, Cassagneau P, Salles F, Moulin G. Sialographie 3D en cone beam : étude préliminaire. *Rev Stomatol Chir Maxillofac.* nov 2011;112(5):293-9.
6. Koch M, Zenk J, Iro H. Speichelgangsendoskopie in der Diagnostik und Therapie von obstruktiven Speicheldrüsenerkrankungen. *HNO.* févr 2008;56(2):139-44.
7. Burke CJ, Thomas RH, Howlett D. Imaging the major salivary glands. *Br J Oral Maxillofac Surg.* juin 2011;49(4):261-9.
8. Faye N, Tassart M, Périé S, Deux JF, Kadi N, Marsault C. Imagerie des lithiases salivaires. *J Radiol.* janv 2006;87(1):9-15.
9. Luers JC, Grosheva M, Reifferscheid V, Stenner M, Beutner D. Sialendoscopy for sialolithiasis: Early treatment, better outcome. *Head Neck.* avr 2012;34(4):499-504.
10. Koch M, Zenk J, Iro H. Stenosis and stenosis-like lesions in the submandibular duct: Detailed clinical and sialendoscopy-based analysis and proposal for a classification. *Oral Surg Oral Med Oral Pathol Oral Radiol.* nov 2020;130(5):486-95.
11. Ngu R, Brown J, Whaites E, Drage N, Ng S, Makdissi J. Salivary duct strictures: nature and incidence in benign salivary obstruction. *Dentomaxillofac Radiol.* févr 2007;36(2):63-7.
12. Terraz S, Poletti PA, Dulguerov P, Dfouni N, Becker CD, Marchal F, et al. How Reliable Is Sonography in the Assessment of Sialolithiasis? *Am J Roentgenol.* juill 2013;201(1):W104-9.
13. Brown JE. Interventional Sialography and Minimally Invasive Techniques in Benign Salivary Gland Obstruction. *Semin Ultrasound CT MRI.* déc 2006;27(6):465-75.
14. Koch M, Sievert M, Iro H, Mantsopoulos K, Schapher M. Ultrasound in Inflammatory and Obstructive Salivary Gland Diseases: Own Experiences and a Review of the Literature. *J Clin Med.* 12 août 2021;10(16):3547.

15. Goncalves M, Mantsopoulos K, Schapher M, Iro H, Koch M. Ultrasound Supplemented by Sialendoscopy: Diagnostic Value in Sialolithiasis. *Otolaryngol Neck Surg.* sept 2018;159(3):449-55.
16. Buckenham TM, George CD, McVicar D, Moody AR, Coles GS. Digital sialography: imaging and intervention. *Br J Radiol.* juin 1994;67(798):524-9.
17. Becker M, Marchal F, Becker CD, Dulguerov P, Georgakopoulos G, Lehmann W, et al. Sialolithiasis and Salivary Ductal Stenosis: Diagnostic Accuracy of MR Sialography with a Three-dimensional Extended-Phase Conjugate-Symmetry Rapid Spin-Echo Sequence. *Radiology.* nov 2000;217(2):347-58.
18. Kroll T, May A, Wittekindt C, Kähling C, Sharma SJ, Howaldt HP, et al. Cone beam computed tomography (CBCT) sialography—an adjunct to salivary gland ultrasonography in the evaluation of recurrent salivary gland swelling. *Oral Surg Oral Med Oral Pathol Oral Radiol.* déc 2015;120(6):771-5.
19. Drage N, Brown J. Cone beam computed sialography of sialoliths. *Dentomaxillofacial Radiol.* juill 2009;38(5):301-5.
20. Bertin H, Bonnet R, Delemazure AS, Mourrain-Langlois E, Mercier J, Corre P. Three-dimensional cone-beam CT sialography in non tumour salivary pathologies: procedure and results. *Dentomaxillofacial Radiol.* janv 2017;46(1):20150431.
21. Abdel-Wahed N, Amer ME, Abo-Taleb NSM. Assessment of the role of cone beam computed sialography in diagnosing salivary gland lesions. *Imaging Sci Dent.* mars 2013;43(1):17-23.
22. Thomas N, Kaur A, Reddy SS, Nagaraju R, Nagi R, Shankar VG. Three-dimensional cone-beam computed tomographic sialography in the diagnosis and management of primary Sjögren syndrome: Report of 3 cases. *Imaging Sci Dent.* juin 2021;51(2):209-16.
23. Aframian DJ, Keshet N, Nadler C. Cone beam computerized tomography sialography—An emerging novel diagnostic tool for Sjögren’s syndrome. *Oral Dis.* mars 2018;24(1-2):191-3.
24. Keshet N, Aricha A, Friedlander-Barenboim S, Aframian DJ, Nadler C. Novel parotid sialo-cone-beam computerized tomography features in patients with suspected Sjogren’s syndrome. *Oral Dis.* janv 2019;25(1):126-32.
25. Jäger L, Menauer F, Holzknecht N, Scholz V, Grevers G, Reiser M. Sialolithiasis: MR Sialography of the Submandibular Duct—An Alternative to Conventional Sialography and US? *Radiology.* sept 2000;216(3):665-71.
26. Goncalves M, Schapher M, Iro H, Wuest W, Mantsopoulos K, Koch M. Value of Sonography in the Diagnosis of Sialolithiasis: Comparison With the Reference Standard of Direct Stone Identification: Sonography in the Diagnosis of Sialolithiasis. *J Ultrasound Med.* nov 2017;36(11):2227-35.

27. Bozzato A, Hertel V, Bumm K, Iro H, Zenk J. Salivary simulation with ascorbic acid enhances sonographic diagnosis of obstructive sialadenitis. *J Clin Ultrasound*. juill 2009;37(6):329-32.
28. Gritzmann N, Rettenbacher T, Hollerweger A, Macheiner P, Hübner E. Sonography of the salivary glands. *Eur Radiol*. mai 2003;13(5):964-75.
29. Kim DH, Kang JM, Kim SW, Kim S, Jung JH, Hwang SH. Utility of Ultrasonography for Diagnosis of Salivary Gland Sialolithiasis: A Meta-Analysis. *The Laryngoscope*. 19 janv 2022;lary.30020.
30. Koch M, Zenk J, Bozzato A, Bumm K, Iro H. Sialoscopy in Cases of Unclear Swelling of the Major Salivary Glands. *Otolaryngol Neck Surg*. déc 2005;133(6):863-8.
31. Födra C, Kaarmann H, Iro H. [Sonography and plain roentgen image in diagnosis of salivary calculi--experimental studies]. *HNO*. juill 1992;40(7):259-65.
32. Schwarz D, Kabbasch C, Scheer M, Mikolajczak S, Beutner D, Luers JC. Comparative analysis of sialendoscopy, sonography, and CBCT in the detection of sialolithiasis: CBCT Imaging of Sialolithiasis. *The Laryngoscope*. mai 2015;125(5):1098-101.
33. Avrahami E, Englander M, Chen E, Shabtay D, Katz R, Harell M. CT of submandibular gland sialolithiasis. *Neuroradiology*. avr 1996;38(3):287-90.
34. Roberts JA, Drage NA, Davies J, Thomas DW. Effective dose from cone beam CT examinations in dentistry. *Br J Radiol*. janv 2009;82(973):35-40.
35. Jadu F, Yaffe M, Lam E. A comparative study of the effective radiation doses from cone beam computed tomography and plain radiography for sialography. *Dentomaxillofacial Radiol*. juill 2010;39(5):257-63.
36. Gadodia A, Seith A, Sharma R, Thakar A, Parshad R. Magnetic resonance sialography using CISS and HASTE sequences in inflammatory salivary gland diseases: Comparison with digital sialography. *Acta Radiol*. mars 2010;51(2):156-63.
37. Gadodia A, Bhalla A, Sharma R, Thakar A, Parshad R. MR sialography of iatrogenic sialocele: comparison with conventional sialography. *Dentomaxillofacial Radiol*. mars 2011;40(3):147-53.
38. Varghese JC, Thornton F, Lucey BC, Walsh M, Farrell MA, Lee MJ. A prospective comparative study of MR sialography and conventional sialography of salivary duct disease. *Am J Roentgenol*. déc 1999;173(6):1497-503.
39. Tassart M, Zeitoun D, Iffenecker C, Bahlouli F, Bigot JM, Boudghène F. [MR Sialography]. *J Radiol*. janv 2003;84(1):15-26.
40. Kalinowski M, Heverhagen JT, Rehberg E, Klose KJ, Wagner HJ. Comparative study of MR sialography and digital subtraction sialography for benign salivary gland disorders. *AJNR Am J Neuroradiol*. oct 2002;23(9):1485-92.

41. Thomas WW, Douglas JE, Rassekh CH. Accuracy of Ultrasonography and Computed Tomography in the Evaluation of Patients Undergoing Sialendoscopy for Sialolithiasis. *Otolaryngol Neck Surg.* mai 2017;156(5):834-9.


Figure legends

Figure 1. Visualization of a salivary stone located in the distal third of Wharton's duct, seen on 3D-CBCT sialography and ultrasonography. Calculus appears as a negative image within the contrast-filled canal on axial (A) and sagittal (C) sections in 3D-CBCT sialography. Ultrasound exploration and measure (B) of the submandibular gland (*), and evidence of the stone as a hyperechogenic mass within the canal with posterior shadow cone (D).

Figure 2. Diagnosis of salivary ductal dilatations of Stensen duct and the intraparotid ductal branches with 3D-CBCT sialography and ultrasonography.


Figure 3. Evidence of a salivary stenosis of the pre-masseteric portion of the left Stensen duct visible on 3D-CBCT sialography and with US.

Vu, le Président du Jury,




Professeur Pierre CORRE

Vu, le Directeur de Thèse,



Docteur Hélios BERTIN

Vu, le Doyen de la Faculté,



Professeur Pascale JOLLIET

Titre de Thèse : Etude comparative entre le sialo-cone-beam et l'échographie dans la détection de lésion canalaire salivaire non-tumorale

RESUME

Introduction : Les pathologies non-tumorales représentent les plus fréquentes pathologies affectant les glandes salivaires. L'imagerie des glandes salivaires est importante pour diagnostiquer le type de lésion et ainsi, décider du traitement adéquat. Le but de cette étude était de comparer le sialo-cone-beam et l'échographie dans le diagnostic de pathologies canalaire salivaire non-tumorales.

Matériels et méthodes : Nous avons comparé de manière rétrospective deux examens d'imagerie réalisés chez les mêmes patients étant adressés pour des symptômes d'obstruction salivaire, d'inflammation salivaire ou d'anomalies sécrétoires. Le critère de jugement principal était la capacité d'une imagerie à diagnostiquer une lésion (sensibilité). Les critères de jugement secondaires étaient le taux de détection selon le type de lésion (lithiase, sténose, dilatation), l'analyse des causes d'échec diagnostic, les paramètres de sécurité et d'exposition aux radiations (pour le sialo-cone-beam).

Résultats : Parmi les 236 patients chez qui un sialo-cone-beam a été réalisé entre 2017 et 2021 dans notre établissement, 157 ont finalement été inclus dans l'analyse per-protocole. Le sialo-cone-beam a permis la détection d'une lésion canalaire salivaire chez 113 patients contre 86 patients pour l'échographie ; une meilleure sensibilité et une meilleure valeur prédictive négative ont été observées avec le sialo-cone-beam comparé à l'échographie : 0,85 contre 0,65 et 0,70 contre 0,44 respectivement. Le sialo-cone-beam a surpassé l'échographie pour la mise en évidence de lithiases salivaires comme le montrent son importante sensibilité, spécificité, valeur prédictive négative et valeur prédictive positive (0,80, 0,82, 0,88 et 0,70 respectivement). L'échographie n'a mis en évidence aucune sténose (19 cas ont été détectés par le sialo-cone-beam). Cependant, un échec de cathétérisme a été observé avec le sialo-cone-beam chez 30 patients (12,8%).

Conclusion : Notre étude confirme l'utilisation de la sialographie en examen de première intention en tant qu'alternative à l'échographie pour l'exploration des pathologies canalaire salivaire.

MOTS-CLES

CONE BEAM ; SIALOGRAPHIE ; ECHOGRAPHIE ; LESION CANALAIRE SALIVAIRE