



HAL
open science

Les défis de la réhabilitation prothétique en reconstruction maxillo-mandibulaire par lambeau libre de fibula : revue systématique de la littérature

Thanh Thuy Nham

► To cite this version:

Thanh Thuy Nham. Les défis de la réhabilitation prothétique en reconstruction maxillo-mandibulaire par lambeau libre de fibula : revue systématique de la littérature. Médecine humaine et pathologie. 2022. dumas-03788256

HAL Id: dumas-03788256

<https://dumas.ccsd.cnrs.fr/dumas-03788256>

Submitted on 26 Sep 2022

HAL is a multi-disciplinary open access archive for the deposit and dissemination of scientific research documents, whether they are published or not. The documents may come from teaching and research institutions in France or abroad, or from public or private research centers.

L'archive ouverte pluridisciplinaire **HAL**, est destinée au dépôt et à la diffusion de documents scientifiques de niveau recherche, publiés ou non, émanant des établissements d'enseignement et de recherche français ou étrangers, des laboratoires publics ou privés.

IMPORTANT : OBLIGATIONS DE LA PERSONNE CONSULTANT CE DOCUMENT

Conformément au *Code de la propriété intellectuelle*, nous rappelons que le document est destiné à un **usage strictement personnel**. Les "analyses et les courtes citations justifiées par le caractère critique, polémique, pédagogique, scientifique ou d'information" sont autorisées sous réserve de mentionner les noms de l'auteur et de la source (article L. 122-4 du *Code de la propriété intellectuelle*). Toute autre représentation ou reproduction intégrale ou partielle, faite sans le consentement de l'auteur ou de ses ayants droit, est illicite.

De ce fait, nous vous rappelons notamment que, **sauf accord explicite** de l'auteur de la thèse ou du mémoire, **vous n'êtes pas autorisé** à rediffuser ce document sous quelque forme que ce soit (impression papier, transfert par voie électronique, ou autre). Tout contrevenant s'expose aux peines prévues par la loi.

UNIVERSITE de NANTES

FACULTE DE MEDECINE

Année: 2021/2022

N°

THÈSE

pour le

DIPLÔME D'ÉTAT DE DOCTEUR EN MÉDECINE

D.E.S de Chirurgie Générale

Par

Thanh Thuy NHAM

Née le 20 septembre 1991, à Chonburi Thaïlande

Présentée et soutenue publiquement le jeudi 30 juin 2022

**LES DEFIS DE LA REHABILITATION PROTHETIQUE EN RECONSTRUCTION
MAXILLO-MANDIBULAIRE PAR LAMBEAU LIBRE DE FIBULA**

REVUE SYSTEMATIQUE DE LA LITTERATURE

Président

Monsieur le Professeur Pierre CORRE

Directrice de thèse

Madame le Docteur Julie LONGIS

Membres du Jury

Monsieur le Docteur Alain HOORNAERT

Monsieur le Docteur Benoit PIOT

Monsieur le Docteur Hélios BERTIN

REMERCIEMENTS

Aux membres du jury :

Professeur Pierre Corre,

je te remercie de présider ma thèse. Tu es un maître incontestable de notre belle spécialité et un modèle dans ta pratique. Tes qualités humaines sont aussi admirables que tes qualités chirurgicales. J'espère ainsi qu'à travers mon travail, je puisse honorer ton enseignement. Merci de tout ce que tu fais pour nous, tes internes, depuis le début.

Docteur Julie Longis,

je te remercie d'avoir accepté d'être ma directrice de thèse malgré ton emploi du temps rempli. J'ai passé un semestre extraordinaire avec toi, apprenant de ta rigueur chirurgicale, l'enseignement des techniques et tes qualités humaines. J'ai pu grâce à toi me passionner pour la reconstruction maxillo-faciale et l'implantologie, ce qui m'a mené jusqu'à ce sujet de thèse. Alors chère Julie, tu as toute mon admiration.

Docteur Alain Hoornaert,

je vous remercie d'avoir accepté de faire partie de mon jury de thèse. La formation d'implatologie orale que vous dispensez m'a été fondamentale dans la compréhension de l'univers de la réhabilitation prothétique. J'espère pouvoir bientôt travailler et apprendre à vos côtés.

Docteur Benoit Piot,

merci infiniment de faire partie de mon jury de thèse. Tu es notre maitre incontestable en cancérologie. J'ai beaucoup appris de ton expérience et ton relationnel délicat avec des patients souvent compliqués. Ta franchise, ta patience et ta gentillesse sont infinies. Ton humour et tes goûts musicaux sont inoubliables. *"Alors, il est beau le lambeau?"*

Docteur Hélios Bertin,

je te remercie de faire partie de mon jury de thèse. J'ai passé une superbe année en Master 2 avec toi aussi passionnante que sympathique à tes côtés. On connaît tous tes qualités universitaires mais en travaillant à tes côtés, j'ai pu remarquer à quel point tu es brillant (et drôle aussi !). Encore merci Hélios!

A ma co-directrice de thèse, Docteur Carine Koudougou: toi qui m'accompagnes depuis mon premier semestre de chirurgie maxillo-faciale, je souhaite te témoigner une particulière reconnaissance. Tu m'as prodigué des conseils inestimables sur ce travail de revue systématique. Tu m'as tant aidé dans le moindre détails méthodologiques. Ma gratitude est éternelle.

A mon chéri : Julien, mon ami, ma moitié. Voilà, plus de 12 ans que tu m'accompagne au quotidien dans ces études : doutes et remises en question, 2 concours, des déménagements impromptus, des nuits d'astreintes où tu subis les coups de téléphone ... tu as tant enduré pour moi. Je souhaite te témoigner toute ma gratitude et mon amour pour toujours.

A mes parents : Maman, tu es la joie de vivre incarnée, une femme admirable et toujours en avance sur son temps. Tu es aussi mon amie, ma confidente. Depuis toujours, tu as su éveiller ma curiosité. Tu as su m'inculquer la rigueur du travail et la persévérance. Tu as su aussi me donner l'envie de la lecture, la musique et la cuisine. Devenir médecin, tu en rêvais pour tes enfants. L'empathie je l'ai vite appris de toi. Maman, j'espère que tu es fière de moi. **Papa**, tu n'étais pas tendre mais sans toi j'aurai peut-être dévié de la trajectoire que vous aviez tracé pour moi. Travailleur acharné et fidèle à sa famille, tu as tant sacrifié pour nous. Tu m'as toujours poussé au bout de mes limites et cela n'a pas toujours été facile à accepter. Papa, j'espère que tu es fier de moi maintenant

A mes sœurs chéries : Hélène, on a tant aimé faire les 400 coups ensemble. Notre enfance, on l'a passé à se confier tous les soirs avant de s'endormir puisqu'on partageait la même chambre. Toujours inséparables, tu as même marché sur mes pas. Je suis si fière de toi, devenue médecin aussi. **Cindy**, la petite dernière. Qu'est-ce que l'on n'a pas été tendre avec toi ! Mais regardes ce que tu es devenue, une femme de caractère mais toujours avec ton sourire rayonnant. Saches que je suis aussi fière de toi que tu l'es de moi ! Je te remercie d'avoir su être une oreille attentive quand j'en avais besoin.

A mes tantes, Tante Hong et Tante Oanh : vous m'avez soutenu de loin depuis ma plus tendre enfance. Merci d'avoir été là !

Ma belle-famille : Liliane et Gérard, vous m'avez toujours suivi et soutenu durant mes études de médecine. Vous avez participé à rendre mon quotidien tellement plus confortable que ce soit sur Paris où chez vous. Je ne compte pas les week-end à me faire bichonner pendant que j'avais la tête dans mes photocopies. Vos bons petits plats, Liliane. Nos sorties course à pied et kayak, Gérard. Gérard, je vous souhaite d'être en paix de là où vous lisez ces lignes. A vous deux, que je porterai toujours dans mon cœur. **Camille**, ma belle et douce petite sœur. Merci d'avoir été là dans les moments importants de ma vie.

A mes professeures : Mme Israël, vous m'avez donné confiance en moi, motivée à participer à des épreuves scientifiques et fais découvrir le monde académique. Un monde si loin de celui qui m'entourait. Mais grâce à vous j'ai acquis l'espoir de l'atteindre un jour. Merci pour tout. **Mme Marty**, vous avez tant fait pour moi. Sachez que votre éducation a été déterminante pour mes débuts. Je ne l'oublierai jamais.

A mes collègues et ami(e)s de l'internat de chirurgie : Anh-Claire, mon amie et mon double. Du DU de microchirurgie à Rennes au semestre de CMF à Nantes on est rapidement devenu inséparables : gastronomie, course à pied et yoga. Il n'y a guère que pour savoir qui assistera à tel bloc, qu'on pourrait se chamailler, animées par la passion d'opérer. J'espère que ce n'est que le début de belles aventures.

Charlotte, mon amie de promo, une femme avec de belles convictions et beaucoup de talent. Merci pour ce semestre où tu as partagé tes connaissances en plastique de la face avec moi, comme j'adore opérer avec toi ! **Julia** mon amie, je ne compte plus les semestres où nous avons été co-internes. Tu as toujours été si disponible au quotidien pour moi et pour les autres. Merci d'avoir été là ! **Mathilde**, ma petite sœur de cœur. Tes yeux rieurs égayaient mon quotidien. J'espère qu'on aura encore pleins de bons moments à partager ! **Laurine**, mon amie plasticienne. J'admire ta capacité à apaiser le monde autour de toi. J'ai si hâte que tu reviennes à Nantes ! **Gabriel**, mais qu'aurai été le Master 2 sans toi ? et surtout cet examen de Biosémantique ? Merci pour ces moments de rigolades lors dîners avec Lise et toi ! **Audrey H. et Sarah N.**, ça a été un formidable semestre en ORL avec vous. Je pense régulièrement au cocktail citron-meringué que l'on aimait partager en parlant voyages et randonnées, après une journée de trachéotomies en urgence ou de corps étrangers inhalés. Mais je pense aussi à **Adrien, Arthur, Kahina, Laura, Omar et Hicham** : j'ai tant aimé travailler, apprendre et rire à vos côtés ! **Gaston et Nathaly**, ou comment tenir à 3 internes le semestre de neurotraumatologie. Une expérience qui nous a soudés. J'ai connu le partage et la solidarité avec vous. Merci d'avoir compté dès le début de mon internat.

Mes co-internes de CMF : Victoria, Samy, Audrey Crozet (tu as failli nous faire croire que tu étais aussi finalement CMF!), **Sarah C., Volkan, Ambroise, Sophie, Amaury, Marine C., Tom, Jules, Agathe, Hélène**. Ces graines de génies de la chirurgie, attentionnés et drôles qui partagent mon quotidien. Merci pour tout !

Aux chefs de CMF : Les jeunes – Marine A. : co-interne puis CCA, on beaucoup cuisiné ensemble ! merci d'avoir été là et d'être là au quotidien. **Justine** : un plaisir d'avoir pu opérer mes dernières traumatologie ou chirurgies des tumeurs bénignes avec toi ! Merci d'être toujours disponible pour nous! **Quentin** : des doigts de fées pour l'orthognathique chez cet handballeur d'1m80! Merci pour tous ces verres que tu nous as payé ! **Maé** : c'est surtout toi qui m'as accompagné, aiguiller dans mes débuts en CMF. Je ne l'oublierai jamais merci pour tout. **Juliette**, de co-interne dévouée tu es passée à chef. J'espère qu'on aura l'occasion de se voir plus maintenant que tu es dans le coin ! **Pierre Guy**, sans toi, je n'aurai peut-être pas choisi la CMF. Alors tout simplement merci ! Je pense aussi à **Jihane**, toi qui m'a donné le goût des compétitions des courses à pied, de co-interne à maintenant bientôt chirurgien installée, merci pour ces bons moments passés et ceux à venir!

Les plus vieux – Fanny-Laure : je garde un souvenir ému de mes premières dents de sagesse avec toi, merci d'avoir été ma cheffe! Tu m'as donné l'envie de courir mon premier marathon! **Anaëlle** : mon premier binôme de chef au CHU avec qui je garde d'excellents souvenirs. **Fabien et Mathieu** : merci d'accueillir avec tant de bienveillance les bébés que nous sommes lorsque nous découvrons la spécialité à Saint-Nazaire! **Guillaume M.** : merci de m'avoir fait découvrir et aimer la rhinoplastie ! **Claire F**: après nos débuts ensemble tu as très vite tracé ton chemin et acquis une grande expérience. Tu as toute mon admiration! **Julien G.**: je te remercie de ce que tu fais pour nous, pour tes nombreuses interventions dans le service car je pourrais t'écouter parler implantologie pendant des heures.

Au Docteur Jean-Philippe Perrin : merci de vous rendre toujours disponible lorsque l'on sèche en analyse céphalométrique ou en orthodontie. Mon seul regret c'est de ne pas avoir un semestre de plus pour le passer à vos côtés! **Au Docteur Jacques Schmidt** : t'avoir eu comme professeur à mes consultations en tant que jeune interne a été d'un tel réconfort, merci de faire ce que tu fais pour nous, ton enseignement est inestimable!

Aux chirurgiens plasticiens : **Monia, Elodie, Jeremy, Laurine, Ugo, Hadrien, Diane, Eva et Audrey L.** je ne compte plus les afterworks passés en terrasse. Que de bons souvenirs, merci les copains ! **Aux autres chirurgiens avec qui j'ai eu la chance de travailler – Luc et Joseph** : vous avez été là dans les bons et les moments difficiles d'un semestre inoubliable, merci pour votre engagement au quotidien auprès des patients! **Pauline R. et Marine L.** j'ai tellement eu de chance de vous avoir eu comme cheffes : avec quelques premières (trachéotomie, lambeau de grand pectoral, parotide, pleins d'ATT et de carcino-cutanés). Je garde un excellent souvenir de nos conversations jonglant entre la chirurgie et la gastronomie !

A l'équipe de l'IGR été 2020 : **Quitterie, Samia, Fabienne, Apolline, Sarah, Ingrid, Joanne, Jean-François.** Merci pour ce semestre passionnant, riche et inoubliable. **Au Docteur Temam**, je vous remercie de m'avoir accueilli à l'institut Gustave Roussy. Je garde le souvenir d'avoir côtoyé un brillant chirurgien qui savait naviguer avec son bistouri avec une stupéfiante aisance.

A mes amis hors médecine : **Paupy et Flo**, merci d'égayer mes soirées, très souvent en semaine, avec votre bonhomie et bon-vivre. Merci de votre soutien ! Vous êtes extra ! **Kirsten et Wallace**, nous nous suivons depuis presque 10 ans. Votre ouverture d'esprit, vos parcours académiques brillants et atypiques forcent le respect. Merci d'exister dans mon cœur.

A mes collègues et ami(e)s durant l'année de Master 2 Régis: mon voisin de bureau adoré, ce master 2 n'aurait pas été pareil sans toi! Merci pour ton aide, ta bonne humeur, ton oreille attentive au quotidien! **Mathilde, Laura, Séverine et Jérôme**: merci de m'avoir accompagné et aidé lors de mon projet de Master 2. Les séances d'immunohistochimie rythmées de pauses tasse café étaient passionnantes! **Au Docteur Françoise Rédini**: merci infiniment de m'avoir accueilli à bras ouvert dans votre équipe à Phy.Os. Vous avez su me guider dans ma réflexion toujours avec beaucoup de bienveillance. Je vous dois aussi beaucoup!

A mes amis de la faculté de médecine à Paris: **Marine, Loïc, Carole, Arthur et Mathilde, Cécile, Estelle, Emilie, Noémie, Thomas, Anne, Adrien et beaucoup d'autres** qui ont rendu inoubliables ces années d'externat parisiens! Entres stages, soirées Caves / Post-partiels/ Tonus, vacances à Cabourg à Ancelles nos QG... merci d'avoir rendu tellement fun ces études longues et parfois bien difficiles.

A mes amis de Troyes : Gersende, Farida, Lara, Clément M., Clément L., Tiphanie, Sandy, Julien, Alice, Antoine, Nathalie, Cécile L, je vous avais très tôt confié mes ambitions et mes rêves. Vous aviez été les premiers à croire en moi, alors merci ! **Mention spécial pour Blaise:** ravie de te revoir sur Nantes autour d'un métier qui nous passionne !

Au personnel du service de Chirurgie Maxillo-Faciale à Nantes :

A Christine, Florence, Béatrice, Ronan, Amandine, Aurélie, Anne-Sophie, Amandine, Séverine mais aussi celles qui sont parties Pierrette et Valérie : nos yeux et nos oreilles dans le service de consultation. Merci de nous accompagner dans les gestes de soins avec tant de dévouement !

A Sonia, merci à ton travail et à nos discussions autour des prothèses ! **A Morgan,** tellement de bons souvenirs avec toi ô jeun et talentueux prothésiste !

A Morgane, Alison, Marjorie, Chloé, Fanny, Céline et Céline, Caroline, Coline Clémence, Marion, Solène, Laura, Coralie, Dorothée et tous les autres : vous tenez parfois le service à bout de bras mais nous sommes toujours rassurés de le savoir entre vos mains. Merci pour votre bonne humeur et votre implication au quotidien !

A Mathieu, Bérénice, Isabelle, Elonora, Guenola, Arnaud et tous les nouveaux dont j'aurai oublié le nom : gardiens du bon déroulement d'un bloc, vous qui prenez soin de nous depuis le début de notre internat ainsi qu'à chaque moment des interventions, merci pour tout !

A Mélanie, Mary, Fiona et Soizig : avec vous, j'adore passer au secrétariat raconter ma vie! Merci pour tout le travail que vous abattez au quotidien.

Enfin également, à Sœur Philippe, grâce à qui j'ai pu trouver une atmosphère sereine, studieuse au foyer La Ruche et réussir le début de cette aventure qu'est la Médecine.

TABLE OF CONTENTS

ABBREVIATIONS	8
KEY POINTS.....	9
ABSTRACT.....	10
INTRODUCTION	11
MATERIALS AND METHODS	12
RESULTS	14
DISCUSSION	24
CONCLUSION	30
REGISTRATION ON PROSPERO	30
BIBLIOGRAPHY.....	31

ABBREVIATIONS

CAD / CAM	Computer-aided design / Computer-aided manufacturing
CMA	Comprehensive Meta-Analysis (software)
FFF	Fibula Free Flap
MINORS	Methodological Index for Non-randomised Studies
OMC	Oro-maxillo-facial
ORN	Osteoradionecrosis
PRISMA	Preferred Reporting Items for Systematic Reviews and Meta-Analyses guidelines
DPR	Dental Prosthetic Rehabilitation
nr	No reported
RT	Radiotherapy
VSP	Virtual Surgical Planning

KEY POINTS

Question

How commonly are dental prosthetic rehabilitation current issues in patients with reconstructed jaws by fibula free flap?

Findings

In this review of 36 studies involving 1166 patients who underwent surgical reconstruction of the jaws with FFF, dental prosthetic rehabilitation (DPR) was reported in 53% of cases. Cancer was the main reason for bone resection. DPR with dental implant allowed better patients' satisfaction than conventional prosthesis. Immediate implantation in the fibula free flap permitted to reduce DPR delay with implant high survival rate even in case of post-operative radiotherapy. Virtual surgical planning improve the accuracy of DPR process.

Meaning

To improve quality of dental prosthetic rehabilitation and thus patients' satisfaction, implant supported prosthesis with immediate implantation in the grafted fibula helped by virtual surgical planification should be considered in first intention. These data must be clarified by further comparative studies with larger sample sizes.

ABSTRACT

Importance: Dental Prosthetic rehabilitation (DPR) is the ultimate key step in patients with reconstructed jaws by fibula free flap. However, a functional and satisfactory dental prosthesis in the shortest delay possible, is still a challenge in those patients.

Objective: To provide an overview of the surgical and the clinical outcomes of dental prosthetic rehabilitation in patients with reconstructed jaws with fibula free flap (FFF) and what are the current issues.

Evidence review: MEDLINE/PubMed, Embase, Scopus and Science Direct were searched from databases inception in October 2021 and were updated in March 2022 for studies describing dental rehabilitation for patients after a maxilla-mandibular reconstruction by fibula free flap. The primary outcome “dental prosthesis” was defined as the number of patients who complete DPR procedure with a dental prosthesis. Two reviewers independently screened studies for inclusion, extracted data and assessed the study quality.

Findings: 36 studies were included in the review, reported on a total of 1166 patients (range, 6-117 patients) who underwent reconstruction of the jaws by fibula free flap (FFF). Dental prosthetic rehabilitation prevalence was 53% and concerned mandible in 85.7% of cases. Prostheses supported by implants were used in 58.9%. It improves the quality of prosthetic rehabilitation and patients’ satisfaction compared to conventional removable prosthesis. Cancer was the most common aetiology of defects of the jaws with 58.3%. In all patients with reconstructed jaws by FFF, post-operative radiotherapy was described in 38.2% of cases. The current issues identified during the prosthetic rehabilitation process were post-operative radiotherapy, inadequate soft tissue environment, prosthetic corridor mismatch, fibula limited height. Patients’ satisfaction about their dental prosthesis remained underestimated by most of authors.

Conclusions and Relevance: Prostheses supported by implants improved patients’ quality of life compared to conventional prostheses and should be considered in first intention. Immediate dental implantation on the FFF grafted before radiotherapy showed high survival rate but success of implant-retained overdenture should be evaluated on studies with larger sample sizes. Performing virtual surgical planning improve DPR quality but the cost limit their use. Soft tissue management must be studied for their impact on quality of dental rehabilitation in further comparative studies.

Key words: Prosthetic, Dental rehabilitation, Fibula free flap, Reconstruction of the jaws

DENTAL PROSTHETIC REHABILITATION CURRENT ISSUES IN PATIENTS RECONSTRUCTED JAWS WITH FIBULA FREE FLAP: A SYSTEMATIC REVIEW

INTRODUCTION

Dental prosthetic rehabilitation (DPR) is the ultimate most important step after the reconstruction of the jaws by fibula free flap¹. It permits speech, chewing, swallowing, improving cheek and lip support and saliva retention. It restores an aesthetic smile and psycho-social life functions². What is more, in patients requiring postoperative radiotherapy (RT), extended dental extractions are needed in the irradiated area to prevent osteoradionecrosis (ORN) of the jaw. Thus, a large proportion of patients become edentulous³.

DPR can be performed with implant-supported prosthesis or removable conventional prosthesis⁴. Both improve patient's quality of life⁵. This last decade, implants are increasingly used due to an excellent survival rate, more than 90% in fibula osseous flap and demonstrated an excellent osteointegration⁶. Implants allow prosthesis stability, good retention with a significant upgrade function of masseter effort on the defect side⁷. Thus, irradiated implants show an excellent survival rate⁸ estimated at 90% when implantations occurred in the native jaws before radiation therapy. However, data concerning implants survival rates in the irradiated fibula free flap grafted remains less evaluated.

Several authors recognized the importance of prosthetic rehabilitation in patients' quality of life but there is no consensus about the ideal moment to begin the dental rehabilitation process. Given the lack of data-driven approaches to dental prosthetic rehabilitation after reconstruction of the jaw with FFF, the aim of this systematic review was to describe the outcomes and the current issues that could interfere with a successful dental rehabilitation.

MATERIALS AND METHODS

Data Sources and Search

This review adhered to the PRISMA Guidelines, including protocol registration with PROSPERO⁹ on October 21, 2021. The research was conducted in October 2021 and was updated in April 2022. The following databases were assessed: MEDLINE/PubMed, Scopus, Embase and ScienceDirect. The studies were selected from the recent literature published after January 2000. The search strategy was made by using the terms “free fibula flap”, “osseous flap”, “prosthesis rehabilitation”, “dental rehabilitation”, “dental implant”, “conventional prosthesis”, “prosthodontic rehabilitation” in combination with the Boolean operators AND OR (Table 1). Manual research was made in the reference lists, Google Scholar, and Research Gate to complement the electronic search. The Zotero software program (Corporation for Digital Scholarship) was used to manage the references and remove the duplicated studies¹⁰.

Table 1

Main search strategy

PICOS:

P= (free fibula flap) OR (osseous flap)

I= (prosthesis rehabilitation) OR (dental rehabilitation) OR (dental implant)
OR (conventional prosthesis) OR (prosthodontic rehabilitation)

C = -

O = (dental prosthesis)

S = -

Search (PubMed-Medline):

((free fibula flap) OR (osseous flap)) AND ((prosthesis rehabilitation) OR
(dental rehabilitation) OR (dental implant) OR (conventional prosthesis) OR
(prosthodontic rehabilitation))

Inclusion Criteria and Outcome Definition

Studies that described the treatment procedure and follow-up of dental prosthetic rehabilitation after jaws reconstruction with fibula free flap were included. Case reports, other literature reviews, articles with insufficient published data and studies that have confounded data with other osseous free flaps were excluded.

Data Extraction and Quality Assessment

It involved two reviewers oro-maxillo-facial (OMC) surgeons specialized in prosthodontic rehabilitation ((T.T.N.) and (C.K.)) independently, and if there was any disagreement, a third reviewer (J.L.) was consulted. First, the articles were screened for full-text reading based on a review of the titles and abstracts. Only the papers that were relevant based on reading of the full text were included in the analysis.

The first reviewer (TTN) extracted the relevant data from the eligible articles and organised them into tables, which were crosschecked by the second reviewer (CK). Quality of studies and the potential bias were assessed by the two reviewers using the Methodological Index for Non-randomised Studies (MINORS)¹¹ adapted for observational studies.

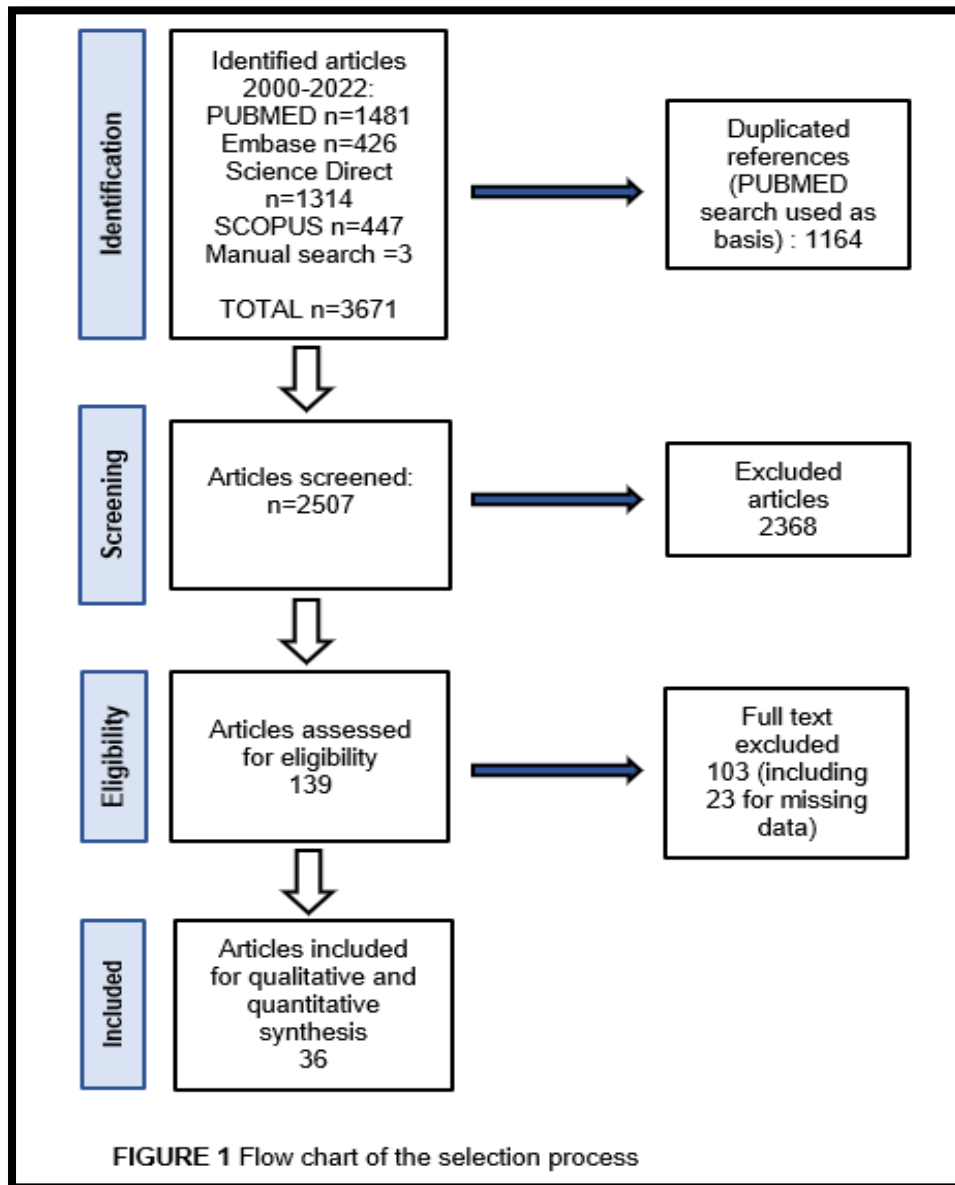
Data Synthesis

The extracted data consisted of information about the study design, patient's characteristics, post-operative radiotherapy, FFF harvested characteristics, the use of virtual surgical planning and dental rehabilitation outcomes. The statistical analysis was performed with Comprehensive Meta-Analysis Software for Windows (Comprehensive Meta-Analysis Software, Biostat Inc. Englewood, USA) to determine data prevalence with 95% confidence interval of different dichotomous outcomes.

RESULTS

Selection of the studies

After full-text review (Figure 1), 36 studies were included in the analysis. We selected the articles for which the data was the most detailed.



None was prospective, only three were comparative: the first compared immediate implantation versus delayed¹², the second rehabilitated versus non-rehabilitated patients after ameloblastoma resection¹³ and the last the use of Virtual Surgical Planning (VSP) versus no-VSP¹⁴. The number of patients studied was 6 for the smallest cohort¹⁵ to 117 for the biggest¹⁶. These studies evaluated 1166 patients

with 13,3 mean age for the youngest cohort¹⁵ and 68 mean age for the oldest¹⁷. The mean post-operative follow-up was ranged from 8¹⁷ to 121 months¹⁸. Reasons for bone resection were cancer with a prevalence of 58.3% (54.6-61.9%) $p < 0.001$ followed by benign tumours with 24% (20.5-27.8%) $p < 0.001$. Two studies^{19,20} hasn't reported the indications for bone resection. Data was resumed in Table 2. Overall rates for quantitative variables could not be calculated by CMA software, because of the lack of confidence intervals in most of studies.

Characteristics of the surgical reconstruction

The main reconstruction site concerned the mandible with 85.7% (82.1-88.7%) $p < 0.001$ ^{13,15,16,20-32} prevalence. The fibula free flap (FFF) harvested has a mean height only detailed in 2 studies: Bulat and al.³³ and Peng and al.³⁴ study respectively 11.24 mm and 15.2mm. The FFF mean length was detailed in 12 studies^{13,14,16,18,27,29,31-36} ranged from 6.8cm¹⁸ to 13.66cm²⁹. Double-barrel technique was reported on 16 studies^{13,18,20,22,23,28-30,32,33,36-41} and represented 28% (22.2-34.6%) $p < 0.001$ of the FFF harvested.

Success of prosthetic rehabilitation

Dental prosthetic rehabilitation (DPR) was defined by the presence of conventional prostheses or functional implants which could retain overdenture. Studies are separated into two subgroups. On the one hand, those which described DPR in patients reconstructed jaws with FFF: rates of DPR could be evaluated on 22 studies^{12,13,16,17,19,20,22,24-27,29,31,32,34,35,37,39,42-45}, reported from 21% to 94% and the prevalence was calculated at 53% (49.2-56.8%) $p = 0,119$. On the other hand, those which 100% of selected rehabilitated patients in the reconstructed with FFF to describe the outcomes^{15,18,21,23,28,30,33,36,38,40,41,46-48} of DPR.

The authors distinguished prostheses supported by implants and removable conventional prosthesis. Two studies used removable conventional prostheses exclusively^{15,35} 25 studies used implant supported prostheses only^{12-14,17,21-27,29,32,33,36-43,45-47} and 8 used both^{16-19,29,31,34,44}. Shroff and al, hasn't report type of PR²⁰. Prostheses supported by implant were performed in 58.9% (51.2-66.2%) $p = 0.024$. Implants were not functional for the final prostheses from 4%³⁸ to 37.8%²⁶ of the cases.

Patients' satisfaction was not quantified except on Bodard and all. study. They reported 96% of functional implant placed in the FFF grafted³⁸, 69.6% of 23 patients rehabilitated with dental implants have considered their occlusion as "satisfactory" and 74% has described their oral rehabilitation as "satisfactory".

Timing of prosthetic rehabilitation

Mean delay between the surgical reconstruction by FFF and the prosthetic procedure was described in 22 studies^{12,14,19,21–25,27,28,30,33,35–40,42,43,45,47}.

In 3 studies^{12,30,47}, prosthetic rehabilitation have begun during the reconstruction surgery with immediate implant placement in the FFF. In these studies, Shen Yu-Fu and al, have loaded prosthesis between 6-12 months while Allen and al. have performed between 4-6 weeks after immediate implantation on the fibula grafted. Williams and al. have not precise this detail.

Prosthetic rehabilitation has begun between 3 and 12 months post operative in 8 studies^{14,19,27,28,33,35,37,45} and after 12 months in 12 studies^{14,21–25,36,38–40,42,43}. The longest mean delay described was 28 months after surgical reconstruction with FFF²³.

Virtual surgical planning and Computer-aided design and manufacturing (CAD/CAM) modelling

Virtual surgical planning (VSP) involves collecting data prior to surgery as a foundation for diagnosis and the creation of a treatment plan that can be precisely reproduced in the operating room. Computer-aided design and manufacturing (CAD/CAM) technology for VSP was used by the authors for precision complex reconstructive surgery with FFF in 7 studies^{14,17,18,29,37,39,47}. Navarro-Cuéllar and al, is the only study that compared the used of CAD/CAM in twelve patients with reconstructed maxilla with FFF. Position of the bone in anatomical position was significantly better with 100% acceptable position versus 66% for no CAD/CAM group. Ischemia time was significantly shorter in the VSP group versus the no-VSP group, respectively 71min versus 96min $p=0.023$ like as operative time 6.7h versus 8.2h $p=0.027$ with better aesthetic results (83.3% vs 33,3% $p=0.036$). Procedural differences were found in the use of CAD/CAM technologies:

- Virtual Surgical planning without cutting guides or surgical template: Byun and al. has used CAD system with navigation for assistance in the surgery only because customized plates were not legal in Korea¹⁸. Shen Yi and al, had used only computer simulation and stereomodel to plan surgery without cutting guides²⁹.
- Cutting guides for osteotomies on the FFF and prefabricated plates to inset the fibula in the planned position^{12,14,17,37,39,47}.
- Surgical template for implantation guided, which allowed immediate or delayed placement of dental implant on the grafted fibula: Williams and al., have placed the fibula cutting guide with guided holes for implants placement secured with screws to the fibula when the flap remains on the leg to perfuse. Implants are placed prior to sectioning the bone.

Current issues in dental prosthetic rehabilitation

Twenty authors^{16–18,22,24–28,30,34–39,42–45} have described the current issues (Table 4). Exact quantification of each on the no-rehabilitated subgroup hadn't been carried out by the authors except 3 two teams^{24,34,45}. Pappalardo and al, were the only ones that compared rehabilitated (RH) versus no-rehabilitated (no-RH) in 34 patients affected by bone resection for ameloblastoma. They found that tumour location site, soft-tissue or bone defect characteristics did not affect significantly rate of prosthetic rehabilitation in these patients

Post-operative radiotherapy was the most issue reported by the authors^{17,18,25,27,28,35,37,38,43,45} with prevalence of 38.2% (33.8-42.8%) $p < 0.001$ in all patients with FFF reconstruction. These data were not mentioned by the authors in the rehabilitated or no-rehabilitated patients' subgroups. Dental implant survival in the fibula free flap grafted were evaluated without precision on success of DPR:

- 86% in Jacobsen's study⁴³, 93% in Hakim's study and 96% in Lodders' study²⁵ in case of immediate implantation on a non-irradiated fibula and without radiotherapy after the surgical reconstruction.
- 38% for Jacobsen's study, 55.3% for Lodders' study and 77% for Bodard's study in case of implantation in an irradiated FFF, with a mean delay after the irradiation of the FFF respectively to 12, 17 and 23.5 months.

- 89.6% in Hakim and al. study (mean follow-up 49.5 months) in case of implantation on the FFF placed before the radiotherapy adjuvant at 6 weeks after the ablative surgery. These dental implants are irradiated after their placement in the fibula grafted bone.

Inadequate soft tissue is the second current issue reported, it gathered: poor retention^{24,35}, thick skin flap in the FFF³⁶, hyperplastic reaction of peri-implant^{38,42}, large soft tissue defect^{22,45}. To avoid thick skin flap paddle, Fan and al. have proposed to use the fibula osteomyofascial flap with a remucosalized flap by surrounding mucosa within 1 month. They have found no significative differences in surgical complications or side effects after adjuvant radiotherapy. None of the patients required debulking in second procedure. In the osteomyofascial group 82% of patients were satisfied compared to 52% in the osseocutaneous flap. Only conventional prostheses were performed in this study. According to Chipasco and al., hyperplastic reaction tissue can be removing surgically or with topical applications of silver nitrate and substituted with palatal mucosa grafts.

Then, unfavourable relationship between maxilla and mandible^{25,26,38,44,45}, FFF failure^{17,24,25,27,39}, cancer recurrence^{24,25,27,39,45} were identified each 5 times as current issues followed by FFF limited height^{28,30,36,43} financial reason^{16,35,37,44} and death^{24,27,43,45}.

Other issues were less identified: poor oral condition (trismus^{24,27} or microstomia⁴⁵), paediatric population^{24,37}, low functional deficit^{24,44}, patient refusal or expectant attitude^{24,34}, poor cooperation^{17,27}, geographical distance to the hospital⁴³ and poor general physical condition²⁴.

Table 2 Study design and demographics data in all patients

Source	Study type	Sample size	Mean age	Mean Follow-up (months)	Mean delay*
Allen ¹² , 2020 (USA)	Retrospective comparative	27	63	12	0
Avraham ³⁷ , 2014 (USA)	Retrospective descriptive	52	44	33	3
Bodard ³⁸ , 2011 (France)	Retrospective	23	46	27,5	23,5
Bulat ³³ , 2021 (Russia)	Retrospective	8	50	14	3,5
Byun ¹⁸ , 2020 (South Korea)	Retrospective	9	49	121	nr
Chaine ³² , 2009 (France)	Retrospective	9	35	53	nr
Chiapasco ⁴² , 2006 (Italy)	Retrospective	59	59	55	12
Fan ³⁵ , 2016 (China)	Retrospective	51	51	nr	3
Fang ³⁶ , 2014 (China)	Retrospective	74	47	nr	13,5
Ferrari ²³ , 2013 (Italy)	Retrospective	14	50	110	28
Futran ¹⁹ , 2002 (USA)	Retrospective	27	59	26	5
Goker ³⁹ , 2020 (Italy)	Retrospective	14	52	54	24
Hakim ²² , 2015 (Germany)	Retrospective	37	52	95	12
He ²⁸ , 2011 (China)	Retrospective	7	40	28	8
Hundepool ²⁴ , 2008 (The Netherlands)	Retrospective	70	53	39,5	17,5
Iizuka ³¹ , 2005 (Switzerland)	Retrospective	28	58	48	nr
Jacobsen ⁴³ , 2014 (Germany)	Retrospective	34	38	23	17
Li ¹⁵ , 2009 (China)	Retrospective	6	13,3	24	nr
Lim ⁴⁴ , 2014 (Singapore)	Retrospective	44	29	nr	nr
Lodders ²⁵ , 2021 (The Netherlands)	Retrospective	44	60	59	23,5
López-Arcas ¹⁶ , 2010 (Spain)	Retrospective	117	57	46	nr
Navarro Cuéllar ¹⁴ , 2021 (Spain)	Retrospective comparative	12	58	11	6 (no-RT)-12(RT)
Ooi ³¹ , 2014 (Singapore)	Retrospective	30	27	59	nr
Pappalardo ¹³ , 2018 (Taiwan)	Retrospective	34	33,2	89	nr
Parbo ²⁷ , 2013 (Denemark)	Retrospective	36	54	22	9
Pellegrino ⁴⁰ , 2018 (Italy)	Retrospective	21	49,6	90	20,8
Peng ³⁴ , 2005 (China)	Retrospective	33	52	67	nr
Raoul ²¹ , 2009 (France)	Retrospective	31	46	76	16
Seier ¹⁷ , 2019 (Switzerland)	Retrospective	21	68	8	nr
Shen, Yi ²⁹ (China)	Retrospective	45	36	35	nr
Shen, Yu-Fu ³⁰ , 2015 (Taiwan)	Retrospective	10	31,6	83,7	0
Shroff ²⁰ , 2017 (India)	Retrospective	30	39,5	nr	nr

Smolka ⁴⁵ , 2008 (Switzerland)	Retrospective	56	56	44	6
Sozzi ⁴¹ , 2017 (Italy)	Retrospective	22	48	93,6	nr
Williams ⁴⁷ , 2021 (USA)	Retrospective	22	nr	nr	0
Zavattero ⁴⁶ , 2021 (Italy)	Retrospective	10	56	>24	nr

Table 2 (continued)

**Between surgical and the beginning of prosthetic procedure nr: non-reported data, RT: radiotherapy, RH: Dental prosthetic rehabilitated patient, VSP: Virtual Surgical Planning*

Table 3 Dental Prosthetic rehabilitation data

Source	DPR rate	Indication for bone resection		DPR type	Reconstruction site	VSP	FFF Mean Height (mm)	FFF Mean Length (cm)	FFF Double-barrel	Post-operative RT
		Cancer	Benign							
Allen ⁵⁰	78% (21/27)	89%	-	100 % DI	M (100%)	nr	nr	nr	nr	56% (15/27)
Avraham ⁴⁸	35% (18/52)	44%	27%	100 % DI	M (100%)	100%	nr	nr	59%	31% (16/52)
Bodard ⁴⁹	100% (23/23)	70%	-	100 % DI	M (100%)	nr	nr	nr	4%	21,7% (5/23)
Bulat ⁴⁵	100% (8/8)	-	-	100 % DI	M (100%)	100%	11,24	10,91	0%	0%
Byun ²³	100% (9/9)	89%	-	33% C & 67% DI	mx (100%)	11%	nr	6,8	0%	0%
Chaine ³⁷	22% (2/9)	-	100%	100 % DI	M (100%)	nr	nr	12	0%	0%
Chiapasco ³⁸	27% (16/59)	76%	12%	100 % DI	M(78%) & mx (22%)	nr	nr	nr	nr	nr
Fan ⁴⁶	61% (31/51)	78%	12%	100 % C	M (100%)	nr	nr	8	nr	59% (30/51)
Fang ⁴⁷	100% (74/74)	64%	5%	100 % DI	M (100%)	nr	nr	11,6	0%	nr
Ferrari ²⁸	100% (14/14)	36%	7%	100 % DI	M (100%)	nr	nr	nr	7%	nr
Futran ²⁴	52% (22/27)	nr	-	36% C & 64% DI	mx (100%)	nr	nr	nr	nr	nr
Goker ³⁹	79% (11/14)	57%	36%	100 % DI	M (93%) & mx (7%)	43%	nr	nr	29%	14% (2/14)
Hakim ²⁷	78% (29/37)	-	100%	100 % DI	M (92%) & mx (8%)	nr	nr	nr	8%	43% (16/37)
He ³³	100% (7/7)	43%	57%	43% C & 57% DI	M (100%)	nr	nr	nr	100%	43%
Hundepool ²⁹	26% (18/70)	70%	7%	100 % DI	M (100%)	nr	nr	nr	nr	nr
Iizuka ³¹	21% (6/28)	100%	-	100 % DI	M (100%)	nr	nr	nr	nr	68% (19/28)
Jacobsen ⁵¹	68% (23/34)	35%	3%	100 % DI	M (100%)	nr	nr	nr	nr	9% (3/33)
Li ²⁰	100% (6/6)	-	100%	100 % C	M (100%)	nr	nr	nr	nr	0%
Lim ⁵²	48% (21/44)	-	100%	86% C & 14% DI	M (100%)	nr	nr	nr	nr	0%
Lodders ³⁰	66% (29/44)	100%	-	100 % DI	M(86%) & mx (14%)	nr	nr	nr	nr	nr
López-Arcas ²¹	83% (97/117)	61%	13%	91% C & 9%DI	M (100%)	nr	nr	11,7	nr	nr
Navarro Cuéllar ¹⁹	100% (12/12)	100%	-	100 % DI	mx (100%)	50%	nr	8,8	nr	67%
Ooi ³⁶	60% (18/30)	-	100%	83% C & 17% DI	M (100%)	nr	nr	8,2	nr	0% (0/30)
Pappalardo ¹⁸	65% (22/34)	-	100%	100 % DI	M (100%)	nr	nr	8,1	40%	0%
Parbo ³²	94% (34/36)	78%	6%	100 % DI	M (100%)	nr	nr	7,1	nr	44% (16/36)

Pellegrino ⁴⁰	100% (21/21)	71%	29%	100 % DI	M(76%) & mx (24%)	nr	nr		10%	33%
Peng ⁴³	70% (23/33)	59%	32%	83% C & 17% DI	mx (100%)	nr	15,2	10,1	nr	nr
Raoul ²⁶	100% (31/31)	52%	13%	100 % DI	M(81%) & mx (19%)	nr	nr		nr	19%
Seier ²²	38% (8/21)	57%	5%	100 % DI	M(88%) & mx (14%)	100%	nr		nr	29% (6/21)
Shen, Yi ³⁴	27% (12/45)	11%	67%	8% C & 92% DI	M (100%)	100%	nr	13,66	100%	nr
Shen, YuFu ³⁵	100% (10/10)	-	100%	100 % DI	M (100%)	nr	nr		0%	0%
Shroff ²⁵	10% (3/10)	nr	nr	nr	M (93%) & mx(7%)	nr	nr		60%	nr
Smolka ⁵³	43% (24/56)	100%	-	100 % DI	M (100%)	nr	nr		nr	54% (30/56)
Sozzi ⁴¹	100% (22/22)	50%	32%	100 % DI	M(64%) & mx (36%)	nr	nr		9%	5%
Williams ⁴⁴	100% (22/22)	27%	50%	100 % DI	M (91%) & mx (9%)	100%	nr		nr	27%
Zavattero ⁴²	100/ (10/10)	50%	40%	100 % DI	M(70%) & mx (30%)	nr	nr		nr	20%

Table 3 (continued)

DPR: Dental Prosthetic Rehabilitation; FFF: Fibula Free Flap; DI: dental implants supported prostheses; C: Conventional prostheses; M: mandible site, mx: maxilla site; nr: non-reported dat; RT: radiotherapy

Table 4 Current issues reported

Current issues	Sources (DPR rate)
Post operative radiotherapy (x10)	Avraham ³⁷ [35%(18/52)]; Bodard ³⁸ [100% (23/23)]; Byun ¹⁸ [100% (9/9)]; Fan ³⁵ [61% (31/51)]; He ²⁸ [100% (7/7)]; Jacobsen ⁴³ [68% (23/34)]; Lodders ²⁵ [66% (29/44)]; Parbo ²⁷ [94% (34/36)]; Seier ¹⁷ [38% (8/21)]; Smolka ⁴⁵ [43% (24/56)]
Inadequate soft tissue (x7)	Bodard ³⁸ [100% (23/23): hyperplastic reaction]; Chiapasco ⁴² [27% (16/59): poor retention]; Fan ³⁵ [61% (31/51)]; Fang ³⁶ [100% (74/74): thick skin flap]; Hakim ²² [78% (29/37)]; Hundepool ²⁴ [26% (18/70): 4% of non RH-patients (3/70)]; Smolka ⁴⁵ [43% (24/56): large soft tissue defect]
Unfavourable relationship between maxilla and mandible (x5)	Bodard ³⁸ [100% (23/23)]; lizuka ²⁶ [21% (6/28): 45% of non-RH patients (10/22)]; Lim ⁴⁴ [48% (21/44)]; Lodders ²⁵ [66% (29/44)]; Smolka ⁴⁵ [43% (24/56)]
FFF Failure (x5)	Goker ³⁹ [79% (11/14)]; Hundepool ²⁴ [26% (18/70): 3% of non RH-patients (2/70)]; Lodders ²⁵ [66% (29/44)]; Parbo ²⁷ [94% (34/36)]; Seier ¹⁷ [38% (8/21)]
Cancer recurrence (x5)	Goker ³⁹ [79% (11/14)]; Hundepool ²⁴ [26% (18/70): 3% of non RH-patients (2/70)]; Lodders ²⁵ [66% (29/44)]; Parbo ²⁷ [94% (34/36)]; Smolka ⁴⁵ [43% (24/56)]
FFF limited height (x4)	Fang ³⁶ [100% (74/74)]; He ²⁸ [100% (7/7)]; Jacobsen ⁴³ [68% (23/34)]; Shen, Yu-Fu ³⁰ [100% (10/10)]
Death (x4)	Hundepool ²⁴ [26% (18/70): 37% of non RH-patients (26/70)]; Jacobsen ⁴³ [68% (23/34)]; Parbo ²⁷ [94% (34/36)]; Smolka ⁴⁵ [43% (24/56)]
Financial (x4)	Avraham ³⁷ [35%(18/52)]; Fan ³⁵ [61% (31/51)]; López-Arcas ¹⁶ [83% (97/117)]; Lim ⁴⁴ [48% (21/44)]
Poor oral condition(x3)	Hundepool ²⁴ [26% (18/70): trismus with 4% of non RH-patients (3/70)]; Parbo ²⁷ [94% (34/36): trismus]; Smolka ⁴⁵ [43% (24/56): Microstomia]
Paediatric population (x2)	Avraham ³⁷ [35%(18/52)]; Hundepool ²⁴ [26% (18/70): 1.4% of non RH-patients (1/70)]
Low functional deficit after FFF (x2)	Lim ⁴⁴ [48% (21/44)]; Hundepool ²⁴ [26% (18/70): 4% of non RH-patients (3/70)]
Patient refusal (x2)	Hundepool ²⁴ [26% (18/70): 5.7% of non RH-patients (4/70)]; Peng ³⁴ [70% (23/33): 40% of non-RH patients (4/10)]
Poor cooperation(x2)	Parbo ²⁷ [94% (34/36)]; Seier ¹⁷ [38% (8/21)]
Patient expectant attitude (x1)	Peng ³⁴ [70% (23/33): 60% of non-RH patients (6/10)]
Poor general physical condition (x1)	Hundepool ²⁴ [26% (18/70): 4% of non RH-patients (3/70)]
Geographical distance to the hospital (x1)	Jacobsen ⁴³ [68% (23/34)]

DPR: Dental Prosthetic Rehabilitation, Non-RH : non-Rehabilitated patients

DISCUSSION

In this systematic review, more than half of patients with reconstructed jaws by FFF were concerned by dental prosthetic rehabilitation and almost two-thirds of those patients had prostheses supported by implants.

Quality of prosthetic rehabilitation with implant supported prostheses

Oral rehabilitation using dental implants aim to restore both oral and aesthetic functions in the last three decades¹. Its advantages compared to conventional removable prostheses are: better retention, stabilization⁴⁹ and quality of life⁵⁰⁻⁵³ with an impact on speech and swallowing in addition to aesthetic outcomes⁵⁴. In this review, conventional prostheses easily shows high rates of rehabilitated patients^{4,15,16} but the authors didn't give any information about their real functionality. In case of DPR with implant retained-overdenture Bodard and al. and Shen Yu-Fu reported from 74% to 100% patients' satisfaction. It reflects the high quality of prosthetic rehabilitation with dental implants. Thereby, prostheses supported by implants in patients with reconstructed jaw with FFF should be considered in first intention.

Eligible patients for dental prosthetic rehabilitation with implants

Proposing prosthetic rehabilitation by dental implants involves defining eligibility criteria as argued Raoul and al., Ferrari and al. and Hundepool and al. studies^{21,23,24}: patient good cooperation, good oral hygiene and no periodontal disease, good residual tongue function, favourable prognosis, no alcohol and tobacco, no trismus, and no serious systemic comorbidities⁵⁵.

In our review, only one study concerned the paediatric population¹⁵ and none has been rehabilitated with dental implants without author's explanations. However, data from literature suggest that DPR with dental implant could be safely used on the grafted fibula in paediatric populations with reconstructed jaws. Genden and al, have described DPR with dental implant in FFF grafted in 2 children affected by aggressive fibroma without additional impact on the growth of their jaws. These patients demonstrated normal growth at the donor site, symmetry of the mandible and the maxilla with long-term follow-up⁵⁶. According to Bohner and al, the use of implants in

children could be proposed in the native jaws, in the anterior region of maxilla and mandible, after 10 years old to avoid structural and growth-related complications⁵⁷.

Favourable prognosis as eligible criteria does not mean eliminating patients which were affected by malignant tumours. Moreover, malignant tumours are the most common causes of defects of the jaws in our systematic review, representing 58.3% of the reconstructed patients. In our review, some studies had shown high prevalence (>60%) of prosthetic rehabilitation by dental implants^{12,25,27} in patients whose main aetiology of bone defect was cancer. Good survival in the stage IV oral squamous carcinoma patients concerned by fibula free flap reconstruction, reach now 81% at one year and more than 70% at three years⁵⁸ and could justify the proposing of dental rehabilitation as soon as possible. It remains for practitioners to consider post-operative radiotherapy.

Delay of dental implantation and post-operative radiotherapy

There is no consensus about the ideal moment to propose prosthetic rehabilitation by implants. The excellent primary stability of implants on FFF may allow immediate loading prostheses of the implants⁵⁹, especially in case of benign tumours resection or when radiotherapy is not considered. Success rate with primary implant placement is similar to those placed secondarily without an impact on flap survival⁶⁰. The beginning of the prosthetic rehabilitation procedure was immediate implantation, in all patients for Allen and al., Shen and al. and Williams and al. studies and for a quarter of the patients of Avraham and al study.

Immediate placement of implants in fibula grafted using or not Virtual Surgical Planning (VSP) may reduce the time required to achieve dental rehabilitation with a surgical complication rate similar to patients not concerned by VSP^{12,37}. Allen and all., has described a specific protocol: interdisciplinary planning session with VSP and CAD/CAM, an immediate dental implantation during the reconstruction surgery with FFF. It enables a complete DPR at 90 days postoperative without additional delay in the post-operative radiotherapy¹². These studies are the minority. Indeed, most of the

studies in this review reported delaying the procedure more than 12 months. The immediate approach in Allen's study would permit adequate time of osseointegration (6 weeks) before the damaging effects of radiation exposure, reduces the total number of procedures necessary to achieve dental restoration and shortens the overall time to final prosthesis placement¹². Immediate implantation on FFF grafted should be considered on further larger series of patients.

The best moment for dental implantation on patient concerned by irradiation treatment must be anticipated. Dental implant survival rates were similar in both native jaws and fibula grafts, and can exceed 96%^{8,25}. When implantation is prior to irradiation of the native jaws or fibula grafted bones, implant survival rates were also similar in both cases with 89%^{8,22}. In contrast, in case of implantation 12 months after the end of radiotherapy, in an irradiated fibula graft, implants survival rate drops to 38%⁴³. Implants failure didn't seem irreversible since 77% of implant survival rate was described if implantation on the fibula graft occurred meanly 23.5 months after the end of irradiation³⁸. Thereby, immediate implantation or before radiation therapy (at 6 weeks) in the grafted FFF would permit satisfaction survival rates. In case of delayed implantation on the FFF, implant survival would be better if implantation occurs two years after the irradiation of the FFF. These results should be interpreted with caution: implant survival rate does not necessarily reflect DPR success. Indeed, Koudougou and al. has reported that success of implant-retained overdenture⁸ was 67.4% for patient who underwent implant surgery before the RT on native jaws while implant survival rate was 89.6%. Further comparative studies must be conducted to evaluate DPR success rather than implant survival on reconstructed jaws with fibula grafts, with or without post-operative radiotherapy.

Virtual surgical planning and CAD/CAM modelling impact quality and delay of prosthetic rehabilitation

The unfavourable relationship between maxilla and mandible is one of the main current issue reported in this review and can lead to up to a third of unfunctional

implants²⁶. Unusable implants would compromise DPR success. Indeed, the main challenge in prosthetic rehabilitation is to position the FFF in a prosthetic corridor on the closest position to the native jaw and to get the subcrestal position of the implants. Virtual surgical planning (VSP) and CAD/CAM technologies have improved the quality of prosthetically guided outcomes of the reconstruction with FFF^{5,61}. It permits fabrication of cutting guides or templates implantation guides which could help accuracy and fidelity of VSP⁶²⁻⁶⁴ in dental implant functional positioning^{65,66}. It has an impact on operative efficiency with shorter ischemia time, decreased complication rates and allows to reduce the delay to get oral functional prostheses^{62-64,67-69}. In Navarro-Cuéllar study, FFF grafted presented better anatomical position and aesthetic results when VSP with CAD/CAM was used¹⁴. With a small sample size (12 patients), they have failed to demonstrate that VSP and CAD/CAM improve significantly DPR success rate.

In this review, the height difference between native jaws^{34,70} and FFF grafted bones^{33,34}, can reach 17mm especially in the symphyseal area. The consequence is an insufficiency of the vertical dimension of occlusion (VDO). From a functional viewpoint, the implants should support very long prosthetic suprastructures to reach the occlusal plane with the risk of unfavourable bending movements and implant overload, which may threaten long-term implant survival⁴⁷. The use of double-barrel technique fibula grafting was described to double the fibula bone height to 3cm. It is possible if the defect is less large than 10cm⁷¹. During the double-barrel fibula harvest^{65,66}, cutting or templates implantation guides made from the VSP and CAD/CAM modelling enhance the surgery accuracy^{65,66} but this technique could presents a risk of blocking the blood supply to the graft⁷¹⁻⁷⁴. Other techniques were described in literature, all relate to secondary surgeries: vertical distraction osteogenesis in the single barrel of FFF^{40,75} or osseous Iliac onlay grafted on the fibula²².

Virtual Surgical planning require additional time for creation of custom plates and models but none of patients affected by malignant tumours, experienced additional delay in ablative surgery⁴⁷. From an economic point of view, the cost of digital technologies being approximately 5000\$ can limit its use whereas the decreasing of operative room occupancy time can save money³⁷. Digital technologies allows workflow and planned surgery, but long-term and comparative studies with pharmacoeconomic considerations should be conducted to determine their efficiency on the quality of prosthetic rehabilitation.

The role of peri-implant soft tissue in the quality of dental rehabilitation

Peri-implant soft tissue is essential for long-term marginal bone stability around dental implants⁷⁶. The extraoral skin paddle of the FFF can be thick and has not alveolar attachment nor has it got a vestibule. Implants allow prosthesis stability, good retention and masticatory function. But thick skin paddle can lead to poor hygiene around dental implants. It results in peri-implantitis followed by marginal bone loss⁷⁶.

These patients need surgical reshaping³² in the majority of cases up to 62.2%²². Various techniques have been reported: the use of the fibula osteomyofascial flap with a remucosalized flap on the primary surgery³⁵ or split-thickness skin graft⁷⁷ and palatal mucosa graft after skin removal from the FFF skin paddle⁷⁸ on a second stage. Recent studies⁷⁹⁻⁸¹ have proposed the two-stage prefabricated vascularised fibula flap and a prelaminated with a skin graft to overcomes problems associated with bulky skin flaps. In this study, the limiting factors remains the time-delay, bone defects that doesn't include large soft tissue defects (tongue, buccal mucosa or soft palate), where local control is highly predictable and where radiotherapy adjuvant is not indicated⁷⁹. Further comparative studies should be conducted to determine results of systematic soft tissue management with vestibuloplasty or refine the skin paddle techniques.

Limitations

This meta-analysis focusses on retrospective observational studies which therefore does not consider confounding biases. These studies are limited by heterogeneous cohorts and aetiologies with sometimes small sample size. There is also, a lack of consensus on the definition of successful prosthetic rehabilitation which is not about having a prosthesis in the oral cavity. The definition of a successful DPR should be the one that takes patient's satisfaction into account. Although, quality of life is regularly cited as better in patients with DPR¹³, evaluation of patients' satisfaction remains underestimated.

There is undoubtedly publication bias. The nationalities of the studies are those of the industrialized countries. Prosthetic rehabilitation remains an expensive process and its accessibility is still limited to poor populations^{82,83}. The financial limitation is regularly highlighted in this review but paradoxically having a favourable health care system doesn't mean high DPR rates²⁶.

Further controlled and randomized studies, with assessment of the quality as success of dental prosthetic rehabilitation are required.

Conclusion

Prostheses supported by implant improve patient’s quality of life and satisfaction compared to conventional prostheses. It should be proposed in first intention in the patients’ reconstructed jaws with fibula free flap (FFF) whatever the bone defect aetiology. Immediate implantation on the grafted fibula, before radiotherapy improve dental implant survival rate but success of implant-retained overdenture should be evaluated in further comparative studies. Virtual surgical planning and CAD/CAM improve the quality of surgical reconstruction, prosthetic rehabilitation and thus patient satisfaction but their high cost limits their use. Further comparative studies should be conducted focusing on the surgical management of thick skin paddle and vestibuloplasty to determine their impact on the quality of rehabilitation.

Registration on PROSPERO

NIHR | National Institute
for Health Research

PROSPERO
International prospective register of systematic reviews

[Home](#) | [About PROSPERO](#) | [How to register](#) | [Service information](#)

[Search](#) | [My PROSPERO](#) | Logout: **Thanh-Thuy NHAM**

Register your review now

Edit your details

You have 1 records

My other records

These are records that have either been published or rejected and are not currently being worked on.

ID	Title	Status	Last edited
CRD42021279371	Prosthetic rehabilitation in patients with defects of the jaws reconstructed with fibula free flap: a systematic review	Registered	29/10/2021

BIBLIOGRAPHY

1. Moscoso JF, Keller J, Genden E, et al. Vascularized bone flaps in oromandibular reconstruction. A comparative anatomic study of bone stock from various donor sites to assess suitability for enosseous dental implants. *Arch Otolaryngol Head Neck Surg.* 1994;120(1):36-43. doi:10.1001/archotol.1994.01880250032004
2. Schmelzeisen R, Neukam FW, Shirota T, Specht B, Wichmann M. Postoperative function after implant insertion in vascularized bone grafts in maxilla and mandible. *Plast Reconstr Surg.* 1996;97(4):719-725. doi:10.1097/00006534-199604000-00005
3. Rogers SN, Panasar J, Pritchard K, Lowe D, Howell R, Cawood JI. Survey of oral rehabilitation in a consecutive series of 130 patients treated by primary resection for oral and oropharyngeal squamous cell carcinoma. *Br J Oral Maxillofac Surg.* 2005;43(1):23-30. doi:10.1016/j.bjoms.2004.08.020
4. Garrett N, Roumanas ED, Blackwell KE, et al. Efficacy of conventional and implant-supported mandibular resection prostheses: study overview and treatment outcomes. *J Prosthet Dent.* 2006;96(1):13-24. doi:10.1016/j.prosdent.2006.05.010
5. Urken ML, Buchbinder D, Costantino PD, et al. Oromandibular reconstruction using microvascular composite flaps: report of 210 cases. *Arch Otolaryngol Head Neck Surg.* 1998;124(1):46-55. doi:10.1001/archotol.124.1.46
6. Burgess M, Leung M, Chellapah A, Clark JR, Batstone MD. Osseointegrated implants into a variety of composite free flaps: A comparative analysis. *Head Neck.* 2017;39(3):443-447. doi:10.1002/hed.24609
7. Fueki K, Roumanas ED, Blackwell KE, et al. Effect of implant support for prostheses on electromyographic activity of masseter muscle and jaw movement in patients after mandibular fibula free flap reconstruction. *Int J Oral Maxillofac Implants.* 2014;29(1):162-170. doi:10.11607/jomi.3197
8. Koudougou C, Bertin H, Lecaplain B, et al. Postimplantation radiation therapy in head and neck cancer patients: Literature review. *Head Neck.* 2020;42(4):794-802. doi:10.1002/hed.26065
9. Prospero. International prospective register of systematic reviews; 2022. Available from URL. Accessed March 27, 2022. https://www.crd.york.ac.uk/prospero/display_record.php?RecordID=279371
10. Zotero Documentation. Available from URL. Accessed March 27, 2022. <https://www.zotero.org/support/dev/start>
11. Slim K, Nini E, Forestier D, Kwiatkowski F, Panis Y, Chipponi J. Methodological index for non-randomized studies (minors): development and validation of a new instrument. *ANZ J Surg.* 2003;73(9):712-716. doi:10.1046/j.1445-2197.2003.02748.x

12. Allen RJ, Nelson JA, Polanco TO, et al. Short-Term Outcomes following Virtual Surgery-Assisted Immediate Dental Implant Placement in Free Fibula Flaps for Oncologic Mandibular Reconstruction. *Plast Reconstr Surg.* 2020;146(6):768e-776e. doi:10.1097/PRS.00000000000007352
13. Pappalardo M, Tsao CK, Tsang ML, Zheng J, Chang YM, Tsai CY. Long-term outcome of patients with or without osseointegrated implants after resection of mandibular ameloblastoma and reconstruction with vascularized bone graft: Functional assessment and quality of life. *J Plast Reconstr Aesthet Surg.* 2018;71(7):1076-1085. doi:10.1016/j.bjps.2018.03.008
14. Navarro Cuéllar C, Martínez EB, Navarro Cuéllar I, et al. Primary Maxillary Reconstruction With Fibula Flap and Dental Implants: A Comparative Study Between Virtual Surgical Planning and Standard Surgery in Class IIC Defects. *J Oral Maxillofac Surg.* 2021;79(1):237-248. doi:10.1016/j.joms.2020.08.003
15. Li J song, Chen W liang, Huang Z quan, Zhang D ming. Pediatric mandibular reconstruction after benign tumor ablation using a vascularized fibular flap. *J Craniofac Surg.* 2009;20(2):431-434. doi:10.1097/SCS.0b013e31819b96db
16. López-Arcas JM, Arias J, Del Castillo JL, et al. The fibula osteomyocutaneous flap for mandible reconstruction: a 15-year experience. *J Oral Maxillofac Surg.* 2010;68(10):2377-2384. doi:10.1016/j.joms.2009.09.027
17. Seier T, Hingsammer L, Schumann P, Gander T, Rücker M, Lanzer M. Virtual planning, simultaneous dental implantation and CAD/CAM plate fixation: a paradigm change in maxillofacial reconstruction. *Int J Oral Maxillofac Surg.* Published online December 20, 2019. doi:10.1016/j.ijom.2019.11.010
18. Byun SH, Lim HK, Yang BE, Kim SM, Lee JH. Delayed Reconstruction of Palatomaxillary Defect Using Fibula Free Flap. *J Clin Med.* 2020;9(3). doi:10.3390/jcm9030884
19. Futran ND, Wadsworth JT, Villaret D, Farwell DG. Midface reconstruction with the fibula free flap. *Arch Otolaryngol Head Neck Surg.* 2002;128(2):161-166. doi:10.1001/archotol.128.2.161
20. Shroff SS, Nair SC, Shah A, Kumar B. Versatility of Fibula Free Flap in Reconstruction of Facial Defects: A Center Study. *J Maxillofac Oral Surg.* 2017;16(1):101-107. doi:10.1007/s12663-016-0930-6
21. Raoul G, Ruhin B, Briki S, et al. Microsurgical reconstruction of the jaw with fibular grafts and implants. *J Craniofac Surg.* 2009;20(6):2105-2117. doi:10.1097/SCS.0b013e3181bec611
22. Hakim SG, Kimmerle H, Trenkle T, Sieg P, Jacobsen HC. Masticatory rehabilitation following upper and lower jaw reconstruction using vascularised free fibula flap and

- enossal implants-19 years of experience with a comprehensive concept. *Clin Oral Investig.* 2015;19(2):525-534. doi:10.1007/s00784-014-1247-9
23. Ferrari S, Copelli C, Bianchi B, et al. Rehabilitation with endosseous implants in fibula free-flap mandibular reconstruction: a case series of up to 10 years. *J Craniomaxillofac Surg.* 2013;41(2):172-178. doi:10.1016/j.jcms.2012.07.006
 24. Hundepool AC, Dumans AG, Hofer SOP, et al. Rehabilitation after mandibular reconstruction with fibula free-flap: clinical outcome and quality of life assessment. *Int J Oral Maxillofac Surg.* 2008;37(11):1009-1013. doi:10.1016/j.ijom.2008.05.021
 25. Lodders JN, Leusink FKJ, Ridwan-Pramana A, et al. Long-term outcomes of implant-based dental rehabilitation in head and neck cancer patients after reconstruction with the free vascularized fibula flap. *Journal of Cranio-Maxillofacial Surgery.* 2021;49(9):845-854. doi:10.1016/j.jcms.2021.03.002
 26. Iizuka T, Häfliger J, Seto I, Rahal A, Mericske-Stern R, Smolka K. Oral rehabilitation after mandibular reconstruction using an osteocutaneous fibula free flap with endosseous implants. Factors affecting the functional outcome in patients with oral cancer. *Clin Oral Implants Res.* 2005;16(1):69-79. doi:10.1111/j.1600-0501.2004.01076.x
 27. Parbo N, Murra NT, Andersen K, Buhl J, Kiil B, Nørholt SE. Outcome of partial mandibular reconstruction with fibula grafts and implant-supported prostheses. *Int J Oral Maxillofac Surg.* 2013;42(11):1403-1408. doi:10.1016/j.ijom.2013.05.007
 28. He Y, Zhang ZY, Zhu HG, Wu YQ, Fu HH. Double-barrel fibula vascularized free flap with dental rehabilitation for mandibular reconstruction. *J Oral Maxillofac Surg.* 2011;69(10):2663-2669. doi:10.1016/j.joms.2011.02.051
 29. Shen Y, Guo X hua, Sun J, et al. Double-barrel vascularised fibula graft in mandibular reconstruction: a 10-year experience with an algorithm. *J Plast Reconstr Aesthet Surg.* 2013;66(3):364-371. doi:10.1016/j.bjps.2012.10.005
 30. Shen YF, Rodriguez ED, Wei FC, Tsai CY, Chang YM. Aesthetic and functional mandibular reconstruction with immediate dental implants in a free fibular flap and a low-profile reconstruction plate: five-year follow-up. *Ann Plast Surg.* 2015;74(4):442-446. doi:10.1097/SAP.0b013e3182a0dedf
 31. Ooi A, Feng J, Tan HK, Ong YS. Primary treatment of mandibular ameloblastoma with segmental resection and free fibula reconstruction: achieving satisfactory outcomes with low implant-prosthetic rehabilitation uptake. *J Plast Reconstr Aesthet Surg.* 2014;67(4):498-505. doi:10.1016/j.bjps.2014.01.005
 32. Chaine A, Pitak-Arnop P, Dhanuthai K, Ruhin-Poncet B, Bertrand JCh, Bertolus C. A treatment algorithm for managing giant mandibular ameloblastoma: 5-year experiences in a Paris university hospital. *European Journal of Surgical Oncology (EJSO).* 2009;35(9):999-1005. doi:10.1016/j.ejso.2009.04.006

33. Bulat S, Butsan S, Salikhov K, Abramian S, Arsenidze A. Free fibula flap for reconstruction of the severely atrophic mandible: a retrospective study. *International Journal of Oral and Maxillofacial Surgery*. 2021;50(4):546-554. doi:10.1016/j.ijom.2020.08.005
34. Peng X, Mao C, Yu G yan, Guo C bin, Huang M xian, Zhang Y. Maxillary reconstruction with the free fibula flap. *Plast Reconstr Surg*. 2005;115(6):1562-1569. doi:10.1097/01.prs.0000160691.63029.74
35. Fan S, Wang YY, Wu DH, et al. Intraoral lining with the fibular osteomyofascial flap without a skin paddle during maxillary and mandibular reconstruction. *Head Neck*. 2016;38 Suppl 1:E832-836. doi:10.1002/hed.24109
36. Fang W, Liu YP, Ma Q, Liu BL, Zhao Y. Long-Term Results of Mandibular Reconstruction of Continuity Defects with Fibula Free Flap and Implant-Borne Dental Rehabilitation. *Int J Oral Maxillofac Implants*. Published online December 5, 2014. doi:10.11607/jomi.3606
37. Avraham T, Franco P, Brecht LE, et al. Functional outcomes of virtually planned free fibula flap reconstruction of the mandible. *Plast Reconstr Surg*. 2014;134(4):628e-634e. doi:10.1097/PRS.0000000000000513
38. Bodard AG, Bémer J, Gourmet R, et al. Dental implants and free fibula flap: 23 patients. *Rev Stomatol Chir Maxillofac*. 2011;112(2):e1-4. doi:10.1016/j.stomax.2011.01.008
39. Goker F, Baj A, Bolzoni AR, Maiorana C, Gianni AB, Del Fabbro M. Dental implant-based oral rehabilitation in patients reconstructed with free fibula flaps: Clinical study with a follow-up 3 to 6 years. *Clin Implant Dent Relat Res*. 2020;22(4):514-522. doi:10.1111/cid.12928
40. Pellegrino G, Tarsitano A, Ferri A, Corinaldesi G, Bianchi A, Marchetti C. Long-term results of osseointegrated implant-based dental rehabilitation in oncology patients reconstructed with a fibula free flap. *Clin Implant Dent Relat Res*. 2018;20(5):852-859. doi:10.1111/cid.12658
41. Sozzi D, Novelli G, Silva R, Connelly ST, Tartaglia GM. Implant rehabilitation in fibula-free flap reconstruction: A retrospective study of cases at 1-18 years following surgery. *J Craniomaxillofac Surg*. 2017;45(10):1655-1661. doi:10.1016/j.jcms.2017.06.021
42. Chiapasco M, Biglioli F, Autelitano L, Romeo E, Brusati R. Clinical outcome of dental implants placed in fibula-free flaps used for the reconstruction of maxillo-mandibular defects following ablation for tumors or osteoradionecrosis. *Clin Oral Implants Res*. 2006;17(2):220-228. doi:10.1111/j.1600-0501.2005.01212.x
43. Jacobsen C, Kruse A, Lübbers HT, et al. Is mandibular reconstruction using vascularized fibula flaps and dental implants a reasonable treatment? *Clin Implant Dent Relat Res*. 2014;16(3):419-428. doi:10.1111/cid.12004

44. Lim WTW, Teh LY, Yong LT, Tan HK, Peck RHL. Retrospective Analysis of Vascularised Free Fibula Grafts in Oromandibular Reconstruction and Dental Rehabilitation following Resection of Ameloblastoma. *Proceedings of Singapore Healthcare*. 2014;23(1):42-52. doi:10.1177/201010581402300108
45. Smolka K, Kraehenbuehl M, Eggensperger N, et al. Fibula free flap reconstruction of the mandible in cancer patients: evaluation of a combined surgical and prosthodontic treatment concept. *Oral Oncol*. 2008;44(6):571-581. doi:10.1016/j.oraloncology.2007.07.005
46. Zavattero E, Ramieri G, Agrò G, Fasolis M, Garzino-Demo P, Borbon C. Implant Dental Rehabilitation of Fibula-Free Flap Reconstructed Jaws. *J Craniofac Surg*. 2021;32(2):e134-e136. doi:10.1097/SCS.00000000000006874
47. Williams FC, Hammer DA, Wentland TR, Kim RY. Immediate Teeth in Fibulas: Expanded Clinical Applications and Surgical Technique. *Journal of Oral and Maxillofacial Surgery*. 2021;79(9):1944-1953. doi:10.1016/j.joms.2021.04.005
48. Navarro Cuellar C, Caicoya SJO, Acero Sanz JJ, Navarro Cuellar I, Muela CM, Navarro Vila C. Mandibular reconstruction with iliac crest free flap, nasolabial flap, and osseointegrated implants. *J Oral Maxillofac Surg*. 2014;72(6):1226.e1-15. doi:10.1016/j.joms.2014.02.031
49. Shaw RJ, Sutton AF, Cawood JI, et al. Oral rehabilitation after treatment for head and neck malignancy. *Head Neck*. 2005;27(6):459-470. doi:10.1002/hed.20176
50. Petrovic I, Ahmed ZU, Huryn JM, et al. Oral rehabilitation for patients with marginal and segmental mandibulectomy: A retrospective review of 111 mandibular resection prostheses. *J Prosthet Dent*. 2019;122(1):82-87. doi:10.1016/j.prosdent.2018.09.020
51. Rogers SN, Lowe D, Fisher SE, Brown JS, Vaughan ED. Health-related quality of life and clinical function after primary surgery for oral cancer. *Br J Oral Maxillofac Surg*. 2002;40(1):11-18. doi:10.1054/bjom.2001.0706
52. Teoh KH, Patel S, Hwang F, Huryn JM, Verbel D, Zlotolow IM. Prosthetic intervention in the era of microvascular reconstruction of the mandible--a retrospective analysis of functional outcome. *Int J Prosthodont*. 2005;18(1):42-54.
53. Schoen PJ, Raghoobar GM, Bouma J, et al. Prosthodontic rehabilitation of oral function in head-neck cancer patients with dental implants placed simultaneously during ablative tumour surgery: an assessment of treatment outcomes and quality of life. *Int J Oral Maxillofac Surg*. 2008;37(1):8-16. doi:10.1016/j.ijom.2007.07.015
54. Roumanas ED, Garrett N, Blackwell KE, et al. Masticatory and swallowing threshold performances with conventional and implant-supported prostheses after mandibular fibula free-flap reconstruction. *J Prosthet Dent*. 2006;96(4):289-297. doi:10.1016/j.prosdent.2006.08.015

55. Quirynen M, De Soete M, van Steenberghe D. Infectious risks for oral implants: a review of the literature. *Clin Oral Implants Res.* 2002;13(1):1-19. doi:10.1034/j.1600-0501.2002.130101.x
56. Genden EM, Buchbinder D, Chaplin JM, Lueg E, Funk GF, Urken ML. Reconstruction of the pediatric maxilla and mandible. *Arch Otolaryngol Head Neck Surg.* 2000;126(3):293-300. doi:10.1001/archotol.126.3.293
57. Bohner L, Hanisch M, Kleinheinz J, Jung S. Dental implants in growing patients: a systematic review. *Br J Oral Maxillofac Surg.* 2019;57(5):397-406. doi:10.1016/j.bjoms.2019.04.011
58. Ma H, Shujaat S, Bila M, et al. Survival analysis of segmental mandibulectomy with immediate vascularized fibula flap reconstruction in stage IV oral squamous cell carcinoma patients. *J Stomatol Oral Maxillofac Surg.* 2022;123(1):44-50. doi:10.1016/j.jormas.2020.12.003
59. Chiapasco M, Gatti C. Immediate loading of dental implants placed in revascularized fibula free flaps: a clinical report on 2 consecutive patients. *Int J Oral Maxillofac Implants.* 2004;19(6):906-912.
60. Jackson RS, Price DL, Arce K, Moore EJ. Evaluation of Clinical Outcomes of Osseointegrated Dental Implantation of Fibula Free Flaps for Mandibular Reconstruction. *JAMA Facial Plast Surg.* 2016;18(3):201-206. doi:10.1001/jamafacial.2015.2271
61. Ciocca L, Marchetti C, Mazzoni S, et al. Accuracy of fibular sectioning and insertion into a rapid-prototyped bone plate, for mandibular reconstruction using CAD-CAM technology. *J Craniomaxillofac Surg.* 2015;43(1):28-33. doi:10.1016/j.jcms.2014.10.005
62. Antony AK, Chen WF, Kolokythas A, Weimer KA, Cohen MN. Use of virtual surgery and stereolithography-guided osteotomy for mandibular reconstruction with the free fibula. *Plastic and Reconstructive Surgery.* 2011;128(5):1080-1084. doi:10.1097/PRS.0b013e31822b6723
63. Bell RB, Weimer KA, Dierks EJ, Buehler M, Lubek JE. Computer Planning and Intraoperative Navigation for Palatomaxillary and Mandibular Reconstruction With Fibular Free Flaps. *Journal of Oral and Maxillofacial Surgery.* 2011;69(3):724-732. doi:10.1016/j.joms.2009.12.040
64. Haddock NT, Monaco C, Weimer KA, Hirsch DL, Levine JP, Saadeh PB. Increasing bony contact and overlap with computer-designed offset cuts in free fibula mandible reconstruction. *Journal of Craniofacial Surgery.* 2012;23(6):1592-1595. doi:10.1097/SCS.0b013e318257576c
65. Qu X, Wang M, Xu L, Liu J, Bai S, Zhang C. Occlusion Guided Double-Barreled Fibular Osteoseptocutaneous Free Flap for Refined Mandibular Reconstruction Aided by Virtual

- Surgical Planning. *J Craniofac Surg.* 2017;28(6):1472-1476.
doi:10.1097/SCS.0000000000003841
66. Ochandiano S, García-Mato D, Gonzalez-Alvarez A, et al. Computer-Assisted Dental Implant Placement Following Free Flap Reconstruction: Virtual Planning, CAD/CAM Templates, Dynamic Navigation and Augmented Reality. *Front Oncol.* 2022;11:754943. doi:10.3389/fonc.2021.754943
 67. Schepers RH, Raghoobar GM, Vissink A, et al. Accuracy of fibula reconstruction using patient-specific CAD/CAM reconstruction plates and dental implants: A new modality for functional reconstruction of mandibular defects. *J Craniomaxillofac Surg.* 2015;43(5):649-657. doi:10.1016/j.jcms.2015.03.015
 68. Wang YY, Fan S, Zhang HQ, Lin ZY, Ye JT, Li JS. Virtual Surgical Planning in Precise Maxillary Reconstruction With Vascularized Fibular Graft After Tumor Ablation. *J Oral Maxillofac Surg.* 2016;74(6):1255-1264. doi:10.1016/j.joms.2016.01.010
 69. Zweifel D, Bredell MG, Lanzer M, Rostetter C, Rücker M, Studer S. Precision of Simultaneous Guided Dental Implantation in Microvascular Fibular Flap Reconstructions With and Without Additional Guiding Splints. *J Oral Maxillofac Surg.* 2019;77(5):971-976. doi:10.1016/j.joms.2018.12.025
 70. Klinge A, Becktor K, Lindh C, Becktor JP. Craniofacial height in relation to cross-sectional maxillary and mandibular morphology. *Prog Orthod.* 2017;18:32. doi:10.1186/s40510-017-0187-8
 71. Taupin A, Soubeyrand E, Dugué A, Labbé D, Compère JF, Bénateau H. ["Double barrel" free fibula flap and vascular risk. A national investigation in France]. *Rev Stomatol Chir Maxillofac.* 2011;112(6):333-336. doi:10.1016/j.stomax.2011.08.011
 72. Baj A, Youssef DA, Monteverdi R, Bianchi B, Combi VA, Gianni AB. Reconstruction of partial maxillary defects with the double-barrel fibula free flap. *Acta Otorhinolaryngol Ital.* 2010;30(6):299-302.
 73. González-García R, Naval-Gías L, Rodríguez-Campo FJ, Muñoz-Guerra MF, Sastre-Pérez J. Vascularized free fibular flap for the reconstruction of mandibular defects: clinical experience in 42 cases. *Oral Surg Oral Med Oral Pathol Oral Radiol Endod.* 2008;106(2):191-202. doi:10.1016/j.tripleo.2007.04.002
 74. Ruhin B, Menard P, Ceccaldi J, Dichamp J, Bertrand JC. [Double-barrel fibular free flap for mandibular reconstruction: beneficial alternative for dental implanted rehabilitation (5 cases)]. *Rev Stomatol Chir Maxillofac.* 2006;107(5):338-344; discussion 345-346. doi:10.1016/s0035-1768(06)77060-7
 75. Eski M, Turegun M, Deveci M, Gokce HS, Sengezer M. Vertical distraction osteogenesis of fibular bone flap in reconstructed mandible. *Ann Plast Surg.* 2006;57(6):631-636. doi:10.1097/01.sap.0000235452.87390.d6

76. Möhlhenrich SC, Kniha K, Elvers D, et al. Intraosseous stability of dental implants in free revascularized fibula and iliac crest bone flaps. *J Craniomaxillofac Surg*. 2016;44(12):1935-1939. doi:10.1016/j.jcms.2016.09.011
77. Fang W, Ma W, Ma W guang, Li D hua, Liu B lin. A new submerged split-thickness skin graft technique to rebuild peri-implant keratinized soft tissue in composite flap reconstructed mandible or maxilla. *Oral Surg Oral Med Oral Pathol Oral Radiol*. 2012;113(3):e4-9. doi:10.1016/j.tripleo.2011.06.026
78. Meloni SM, Tallarico M, De Riu G, et al. Guided implant surgery after free-flap reconstruction: Four-year results from a prospective clinical trial. *J Craniomaxillofac Surg*. 2015;43(8):1348-1355. doi:10.1016/j.jcms.2015.06.046
79. Diab J, Leinkram D, Wykes J, et al. Maxillofacial reconstruction with prefabricated prelaminated osseous free flaps. *ANZ J Surg*. 2021;91(3):430-438. doi:10.1111/ans.16541
80. Santamaria E, Correa S, Bluebond-Langner R, Orozco H, Ortiz-Monasterio F. A shift from the osteocutaneous fibula flap to the prelaminated osteomucosal fibula flap for maxillary reconstruction. *Plast Reconstr Surg*. 2012;130(5):1023-1030. doi:10.1097/PRS.0b013e31826864aa
81. Rohner D, Bucher P, Hammer B. Prefabricated fibular flaps for reconstruction of defects of the maxillofacial skeleton: planning, technique, and long-term experience. *Int J Oral Maxillofac Implants*. 2013;28(5):e221-229. doi:10.11607/jomi.te01
82. Peres MA, Macpherson LMD, Weyant RJ, et al. Oral diseases: a global public health challenge. *Lancet*. 2019;394(10194):249-260. doi:10.1016/S0140-6736(19)31146-8
83. Bhayat A, Chikte U. Human Resources for Oral Health Care in South Africa: A 2018 Update. *Int J Environ Res Public Health*. 2019;16(10):E1668. doi:10.3390/ijerph16101668

Vu, le Président du Jury,


(tampon et signature)



Professeur Pierre CORRE


Vu, le Directeur de Thèse,

(tampon et signature)



Docteur Julie LONGIS

Vu, le Doyen de la Faculté,



Professeur Pascale JOLLIET

NOM: NHAM

PRENOM: Thanh Thuy

**LES DEFIS DE LA REHABILITATION PROTHETIQUE EN RECONSTRUCTION MAXILLO-
MANDIBULAIRE PAR LAMBEAU LIBRE DE FIBULA:
REVUE SYSTEMATIQUE DE LA LITTERATURE**

RESUME

Introduction: La réhabilitation prothétique dentaire est l'étape la plus importante pour finaliser la reconstruction maxillo-mandibulaire par lambeau libre de fibula. Toutefois, obtenir une prothèse fonctionnelle et satisfaisante pour le patient dans les plus courts délais, reste un défi actuel majeur. L'objectif est d'étudier les problématiques actuelles de la réhabilitation prothétique à travers les données chirurgicales et les résultats cliniques dans cette revue systématique de la littérature.

Matériel et méthodes: MEDLINE/PubMed, Embase, Scopus and Science Direct ont été consultées pour concevoir la base de données en octobre 2021 et mise à jour en mars 2022. Le critère de jugement principal " prothèse dentaire" était défini comme le nombre de patient ayant terminé la procédure de réhabilitation prothétique par une prothèse dentaire. Deux examinateurs indépendants ont inclus les études, extrait les données et évalué la qualité des études.

Résultats: 36 études ont été incluses, portant sur un nombre total de 1166 patients concernés par une reconstruction maxillo-mandibulaire par lambeau libre de fibula. La prévalence estimée de la réhabilitation prothétique dentaire était de 53% et concernait la mandibule dans la majorité des cas avec 85.7%. L'utilisation des prothèses stabilisés sur implants était majoritaire avec 58.9% des cas. En comparaison aux prothèses conventionnelles, ceux-ci amélioreraient la qualité de la réhabilitation prothétique ainsi que la satisfaction des patients. L'étiologie cancéreuse à l'origine du défaut osseux était la plus fréquemment retrouvée avec 58.3% des cas. Parmi tous les patients reconstruits des mâchoires par lambeau libre de fibula, 38.2% ont été irradiés en post-opératoire. L'implantation immédiate dans la fibula greffée avant la radiothérapie, montrait des taux de survie implantaire supérieur à 89%. Les problématiques les plus souvent reportées au cours du processus de reconstruction étaient : l'impact de la radiothérapie post-opératoire, la gestion des tissus mous et le couloir prothétique inadapté. La satisfaction et la qualité de vie des patients ont été sous-évalués par la majorité des auteurs.

Discussion: Les prothèses implantaires offrent une meilleure qualité de vie aux patients en comparaison aux prothèses conventionnelles et doivent être envisagées en première intention quelle que soit l'étiologie de défaut osseux. L'implantation immédiate dans la fibula greffée avant radiothérapie doit être évaluée selon le succès prothétique sur de plus grands effectifs de patients. La planification virtuelle avec chirurgie guidée améliore la qualité de la reconstruction mais le coût élevé limite son utilisation. Les techniques de plastie de la palette cutanée fibulaire doivent être étudiées dans des études comparatives sur le long terme pour déterminer leur impact sur la qualité de la réhabilitation.

Mots clés : réhabilitation prothétique ; réhabilitation dentaire ; lambeau libre de fibula ; reconstruction maxillo-faciale, reconstruction mandibulaire, reconstruction maxillaire.