



HAL
open science

Contrôle de l'ouverture buccale après coronoidectomie chez les patients atteints de la maladie de Langenbeck ou de Jacob : une étude rétrospective de 20 cas

Manon Domart

► **To cite this version:**

Manon Domart. Contrôle de l'ouverture buccale après coronoidectomie chez les patients atteints de la maladie de Langenbeck ou de Jacob : une étude rétrospective de 20 cas. Médecine humaine et pathologie. 2022. dumas-03794392

HAL Id: dumas-03794392

<https://dumas.ccsd.cnrs.fr/dumas-03794392>

Submitted on 3 Oct 2022

HAL is a multi-disciplinary open access archive for the deposit and dissemination of scientific research documents, whether they are published or not. The documents may come from teaching and research institutions in France or abroad, or from public or private research centers.

L'archive ouverte pluridisciplinaire **HAL**, est destinée au dépôt et à la diffusion de documents scientifiques de niveau recherche, publiés ou non, émanant des établissements d'enseignement et de recherche français ou étrangers, des laboratoires publics ou privés.

IMPORTANT : OBLIGATIONS DE LA PERSONNE CONSULTANT CE DOCUMENT

Conformément au *Code de la propriété intellectuelle*, nous rappelons que le document est destiné à un **usage strictement personnel**. Les "analyses et les courtes citations justifiées par le caractère critique, polémique, pédagogique, scientifique ou d'information" sont autorisées sous réserve de mentionner les noms de l'auteur et de la source (article L. 122-4 du *Code de la propriété intellectuelle*). Toute autre représentation ou reproduction intégrale ou partielle, faite sans le consentement de l'auteur ou de ses ayants droit, est illicite.

De ce fait, nous vous rappelons notamment que, **sauf accord explicite** de l'auteur de la thèse ou du mémoire, **vous n'êtes pas autorisé** à rediffuser ce document sous quelque forme que ce soit (impression papier, transfert par voie électronique, ou autre). Tout contrevenant s'expose aux peines prévues par la loi.

NANTES UNIVERSITÉ

FACULTÉ DE MÉDECINE

Année : 2022

N°

THÈSE

Pour le

DIPLÔME D'ÉTAT DE DOCTEUR EN MÉDECINE

Chirurgie orale

Par

Manon DOMART

Présentée et soutenue publiquement le 16 septembre 2022

Contrôle de l'ouverture buccale après coronoïdectomie chez les patients atteints de la maladie de Langenbeck ou de Jacob. Une étude rétrospective de 20 cas.

Président : Monsieur le Professeur Pierre CORRE

Directeur de thèse : Monsieur le Professeur Pierre CORRE

Membres du jury : Monsieur le Professeur Philippe LESCLOUS

Madame le Docteur Alexandre CLOITRE

Monsieur le Docteur Hélios BERTIN

Table des matières

Remerciements.....	3
Introduction (français)	6
Abstract.....	9
Introduction.....	10
Materials and methods.....	12
1. <i>Data collection</i>	12
2. <i>Statistics</i>	12
Results	13
1. <i>Mouth opening monitoring</i>	14
2. <i>Therapeutic management of patients</i>	14
3. <i>Clinical cases</i>	16
Discussion	17

Remerciements

Pr Corre,

Merci pour votre encadrement, vos précieux conseils et votre soutien durant l'élaboration de cette thèse. Merci également de coordonner le DES de chirurgie orale comme vous le faites. Votre humilité et votre capacité d'écoute sont des exemples pour tout jeune médecin. Je suis très reconnaissante pour tout ce que vous faites pour cette spécialité et j'espère pouvoir œuvrer à vos côtés pour maintenir cette complémentarité entre la CMF et la CO.

Pr Lesclous,

Merci pour tout, de votre accueil lors de mon changement de spécialité, jusqu'à ces derniers semestres d'internat. Vous savez fédérer l'équipe d'internes que nous sommes et savoir que vous êtes là pour nous écouter, nous conseiller et nous soutenir, lorsque vous jugez cela juste et opportun, est d'un grand soutien.

Dr Cloître,

Merci pour ton soutien et tes conseils pour la rédaction de l'article et de la thèse. Tes connaissances dans ce domaine sont un atout majeur pour le service de Chirurgie orale.

Dr Bertin,

Merci d'avoir accepté de faire partie de mon jury. T'avoir vu opérer cette pathologie en collaboration avec le Pr Corre m'a montré un chirurgien à l'écoute de son équipe et bienveillant. Merci également pour ton aide à la rédaction de l'article.

Au Dr Nicot, au Dr Guiol et au Dr Weill,

Merci d'avoir participé au recrutement des patients pour cette étude. De Lille à Quimper, en passant par Caen, savoir que des confrères sont intéressés et disponibles pour échanger à propos de patient et de sujet de recherche est très agréable. Au plaisir d'échanger à nouveau !

À tout le service de Chirurgie orale nantais et aux services de Chirurgie maxillo-faciale de l'Ouest,
Au Pr Lesclous, au Pr Chaux,

À toute l'équipe de La Roche-sur-Yon, au Dr Philippe Lebaud, Anaëlle et Jihane,

À toute l'équipe nazairienne, à Léonie, Fabien, Mathieu et Justine,

À toute l'équipe du CSD, à Maxime,

À Claire, merci mille fois de m'avoir ouvert les portes de ton cabinet. Ta manière de travailler et ton humilité m'inspireront dans ma pratique future, c'est une certitude.

À vous tous, vos conseils ont été et sont précieux pour moi. Je suis fière d'avoir croisé vos chemins respectifs et d'avoir pu apprendre à vos côtés. Votre humilité est un exemple à suivre.

À tous les infirmiers, infirmières, assistantes dentaires, prothésistes et secrétaires avec lesquels j'ai pu travailler durant mon internat. Merci pour votre accueil dans chaque service, pour le travail d'équipe que nous avons pu produire et pour le partage de vos conseils et de votre expérience.

À mes co-internes et amis,

À Agathe, David et Marion,

Ces quatre ans d'internat sont passés à une vitesse folle et vous n'y êtes pas pour rien. Travailler et apprendre chaque jour entourée d'amis n'a pas de prix. Je vous souhaite les plus belles des carrières, et j'espère partager encore beaucoup de moments avec vous, dans nos vies professionnelles et surtout personnelles.

À mes amis,

À Lucile, Marianne, Marie, Marion, et à tous ceux qui se reconnaîtront dans ces quelques lignes. Depuis plus de huit ans maintenant, les moments passés avec vous sont mémorables. Pour la coloco, toutes les soirées place Plumereau, WEDS, les vacances au ski, les peña endiablées... et pour tout ce qui nous attend encore : merci !

À mes sœurs, mes beaux-frères, Arthur et Victoire,

À Marine et Morgane, avec autant de différences flagrantes que de points communs majeurs qui nous rassemblent, je ne vous souhaite que du bonheur à outrance et de la réussite, dans vos carrières respectives et surtout dans vos vies personnelles. Je suis très fière de vos parcours respectifs et ma porte vous sera toujours ouverte. Les moments passés ensemble feront toujours partie de mes priorités.

À Renan,

Passer plus d'un tiers de ma vie avec toi est ma plus belle aventure. Tu as su me conseiller dans des choix importants, avec une bienveillance déconcertante. Notre duo est une évidence pour moi, et je peux affirmer qu'il perdurera encore très longtemps.

À mes parents,

J'essaierai de vous remercier chaque jour de ma vie pour tout ce que vous avez fait pour moi et tout ce que vous continuez à faire aujourd'hui. Je suis fière de vous avoir comme parents, de l'éducation que vous m'avez donnée et du sens de la famille et du dévouement que vous m'avez transmis. Je vous dédie sans aucune hésitation, à tous les deux, l'accomplissement de ces dix années d'étude. Votre soutien inconditionnel et notre complicité sont certaines des choses les plus importantes pour moi. Jamais cela ne changera.

À mes grands-parents, qui me manquent indiciblement.

Contrôle de l'ouverture buccale après coronoidectomie chez les patients atteints de la maladie de Langenbeck ou de Jacob. Une étude rétrospective de 20 cas

INTRODUCTION

En 1853, B. Langenbeck a été le premier à décrire un élargissement du processus coronoïde mandibulaire chez un patient (1). En 1899, l'anatomiste français O. Jacob a décrit la présence d'une articulation non fonctionnelle entre le processus coronoïde de la mandibule et l'arcade zygomatique, entraînant une limitation de l'ouverture de la bouche (2). Les causes d'élargissement du processus coronoïde rencontrées sont l'ostéochondrome, l'ostéome, l'exostose osseuse ou l'hyperplasie (3,4). Même s'il existe des différences entre les maladies de Langenbeck et de Jacob en termes d'étiologies, les signes cliniques retrouvés, l'impact sur la vie du patient et leur prise en charge chirurgicale sont similaires.

L'incidence de ces maladies est encore inconnue. Cependant, les maladies de Jacob et de Langenbeck semblent toucher plus souvent les hommes (63%) à un âge moyen de 30 ans, allant de 5 à 73 ans (5). Les pathologies sont souvent présentées comme des cas bilatéraux (6). L'étiologie de l'hyperplasie coronoïde est encore mal connue. Plusieurs hypothèses ont été avancées, telles que des causes développementales et génétiques (7), une suractivité des muscles temporaux (8), un traumatisme osseux (9), des influences endocriniennes (6,10,11) ou des troubles de l'articulation temporomandibulaire (ATM). La plupart du temps, la maladie est considérée comme idiopathique.

Les signes cliniques courants de ce conflit du processus coronoïde sont représentés par une limitation d'ouverture buccale progressive et indolore, une asymétrie faciale causée par un gonflement en regard de l'arcade zygomatique et des troubles de l'articulation temporomandibulaire (12,13). Tous ces symptômes peuvent avoir de graves répercussions sur l'hygiène buccale et la qualité de vie des patients (14). Le traitement chirurgical le plus souvent appliqué est la coronoidectomie par une approche intra- ou extra-orale. (15) La technique intra-orale vise à sectionner le processus coronoïde mandibulaire hypertrophié par une incision vestibulaire, suivie d'un fort décollement de l'insertion du muscle temporal. L'approche extra-orale par lambeau coronal reste indiquée en cas d'hypertrophie sévère des processus coronoïdes dépassant l'arcade zygomatique jusqu'à la fosse temporale. (16) Cette technique présente un risque de cicatrices

externes et un risque de lésion de la branche frontale du nerf facial. Malgré l'efficacité immédiate de la coronoidectomie en ce qui concerne l'ouverture buccale dans la plupart des cas, la récurrence de cette limitation peut être observée chez 2% des patients. (5) Plusieurs causes peuvent être responsables de cette récurrence, comme le développement d'une nouvelle formation osseuse sur le processus coronoïde ou une fibrose musculaire du muscle temporal.

À notre connaissance, il n'existe aucune publication rapportant la récurrence de la limitation d'ouverture buccale chez des patients traités chirurgicalement pour les maladies de Jacob et de Langenbeck. Goh et al (6) ont étudié 115 cas d'hyperplasie coronoïde opérés par coronoidectomie (toutes causes confondues). On peut calculer un taux de 12% de récurrence de limitation d'ouverture buccale chez ces patients. Malheureusement, les causes de récurrence et les moyens de prévention ne sont pas abordés dans cette revue.

L'objectif principal de notre étude était d'examiner l'ouverture buccale à long terme après une coronoidectomie chez des patients atteints de la maladie de Langenbeck ou de Jacob et d'étudier le risque de récurrence clinique et les facteurs pouvant influencer une récurrence de la limitation de l'ouverture buccale.

Monitoring of oral opening after coronoidectomy in patients with Langenbeck's or Jacob's diseases. A 20 cases retrospective study

Keywords:

Mandible

Musculoskeletal diseases

Mandibular diseases

Cranio-mandibular disorders

Coronoid process

Hyperplasia

Langenbeck's disease

Jacob's disease

Abbreviations:

MO: Mouth opening

MOL: Mouth opening limitation

TMJ: Temporo Mandibular Joint

ABSTRACT

Langenbeck's and Jacob's diseases are rare causes of progressive mouth opening limitation due to the impact of hypertrophy of the coronoid process(es) on the zygomatic bone. This retrospective study included twenty patients with mouth opening limitation who underwent coronoidectomy. Contrary to the literature where recurrence rates ranging from 2 to 12% can be found and where clinical worsening can also be found in some patients, the postoperative follow-up of these patients showed that no clinical recurrence had occurred. The common point of these twenty patients was to continue physical therapy and self-rehabilitation. Although the standard treatment for these conditions is coronoidectomy, it seems important to consider the risk-benefit ratio of the patient and to operate only if the limitation of the mouth opening leads to a real clinical distress for the patient's quality of life.

INTRODUCTION

In 1853 B. Langenbeck was the first to report an enlargement of the mandibular coronoid process in a patient (1). In 1899, the French anatomist O. Jacob described the occurrence of a non-functional joint between the coronoid process of the mandible and the zygomatic arch leading to a mouth opening limitation (MOL) (2). Causes of enlargement of the coronoid process are represented by osteochondroma, osteoma, bone exostosis or hyperplasia (3,4). Even if there are differences between Langenbeck's and Jacob's diseases in terms of etiologies, clinical signs, and impact on the patient life, their surgical management is similar.

The incidence of these diseases is still unknown. However, Jacob's and Langenbeck's diseases appear to involve more often males (63%) at a mean age of 30 years, range from 5 to 73 years (5). The pathologies are commonly presented as bilateral cases (6). The etiology of coronoid hyperplasia is still poorly understood. Several hypothesis have been advanced, such as developmental and genetic causes (7), overactivity of the temporalis muscles (8), bone traumatism (9), endocrine influences (6,10,11) or temporomandibular joint (TMJ) disorders. Most of the time, the disease is considered as idiopathic.

The common clinical signs of coronoid process impingement are represented by a progressive and painless MOL, a facial asymmetry caused by a swelling with regard to the zygomatic arch and TJM disorders (12,13). All of these symptoms may have serious repercussions regarding oral hygiene and quality of life of the patients (14). The surgical treatment mostly applied is coronoidectomy through an intra- or an extraoral approach. (15) The intraoral technique aims at cutting the excessive mandibular coronoid process by a vestibular incision followed by the strong detachment of the insertion of the temporal muscle. Th extraoral approach by coronal flap remains indicated in cases of severe hypertrophy of the coronoid processes extending beyond the zygomatic arch up to the temporal fossa. (16) This technique raises the risks of external scars and potential injury of the frontal branch of the facial nerve. Despite immediate efficacy of coronoidectomy with respect to oral opening in most cases, recurrence of MOL can rarely be observed in 2% of patients. (5) Several causes may be responsible for this recurrence, such as the development of a new bone formation on the coronoid process or muscle fibrosis of the temporalis muscle.

To our knowledge, there is no publication reporting the recurrence of MOL in surgically managed patients with Jacob's and Langenbeck's diseases. Goh et al (6) studied 115 cases with coronoid hyperplasia operated on by coronoidectomy (all causes combined). A 12% rate of MOL recurrence in

these patients can be calculated. Unfortunately, the causes of recurrence and means of prevention are not addressed in this review, nor is the best protocol of care.

The main objective of our study was to examine long-term oral opening after coronoidectomy in patients with Langenbeck's or Jacob's disease and to investigate the risk of recurrence and factors that may influence a recurrence of oral opening limitation.

MATERIALS AND METHODS

Data collection

Patient affected by Langenbeck's or Jacob's disease and having received a unilateral or bilateral coronoidectomy were included in this multicenter, descriptive, retrospective study. We surveyed various French centers that have treated these diseases. To be included the values of patients' mouth opening had to be reported in their medical charts in the preoperative time and during the follow-ups after a minimum of 3 months after the surgical procedure. All the medical charts were reviewed and the data regarding the age, gender, side involved, date of the surgical procedure, type of approach for the coronoidectomy, and values of mouth opening during follow-up. The preoperative value was referred as M1, and the postoperative value as M2. Data related to the injection of botulinum toxin in the masticatory muscles, the active rehabilitation by a physical therapist, as well as self-rehabilitation were also reported.

Due to the retrospective nature of this study, it was granted in written an exemption of requiring approval from the ethics committee of the Nantes University Hospital, in accordance with the French legislation Article L. 1121-1 paragraph 1 and R1121-2 of the Public Health Code. All of the subjects or their guardianships provided their signed consent for use of data.

Statistics

For descriptive analysis, quantitative data were given as means and standard deviations (SD). Qualitative data were given as values and percentages. Histogram and Shapiro-Wilk test have shown that values distribution doesn't rely on a normal law. Then analyses were based on non-parametric test, Wilcoxon or Mann-Whitney tests, according to the dependence between the samples. A *p* value of 0.05 was defined as the threshold of statistical significance. We compared preoperative to postoperative MOL. All data were processed with Excel software (Microsoft Corporation. 2019. Microsoft Excel. Retrieved from <https://office.microsoft.com/excel>).

RESULTS

Twenty patients were included in this study between 2005 and 2022: nine patients were treated in the Nantes University Hospital, 11 came from the Lille University Hospital and 1 patient was treated in the Caen University Hospital.

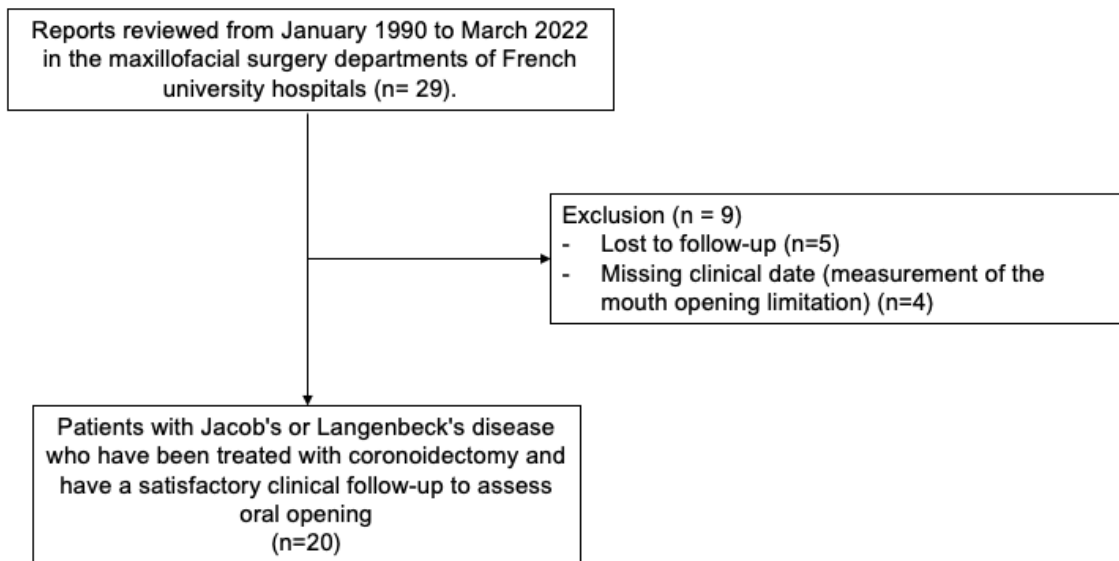


Figure 1: Flow chart of patient selection

Among the included patients in this case series, 6 were female and 12 were male (ratio: 2/1). The mean age at surgical management was 16.3 years, ranging from 6 to 28 years. Of these patients, 17 were diagnosed with Langenbeck's disease and 3 with Jacob's disease.

Mouth opening monitoring (Table 2, Figure 4)

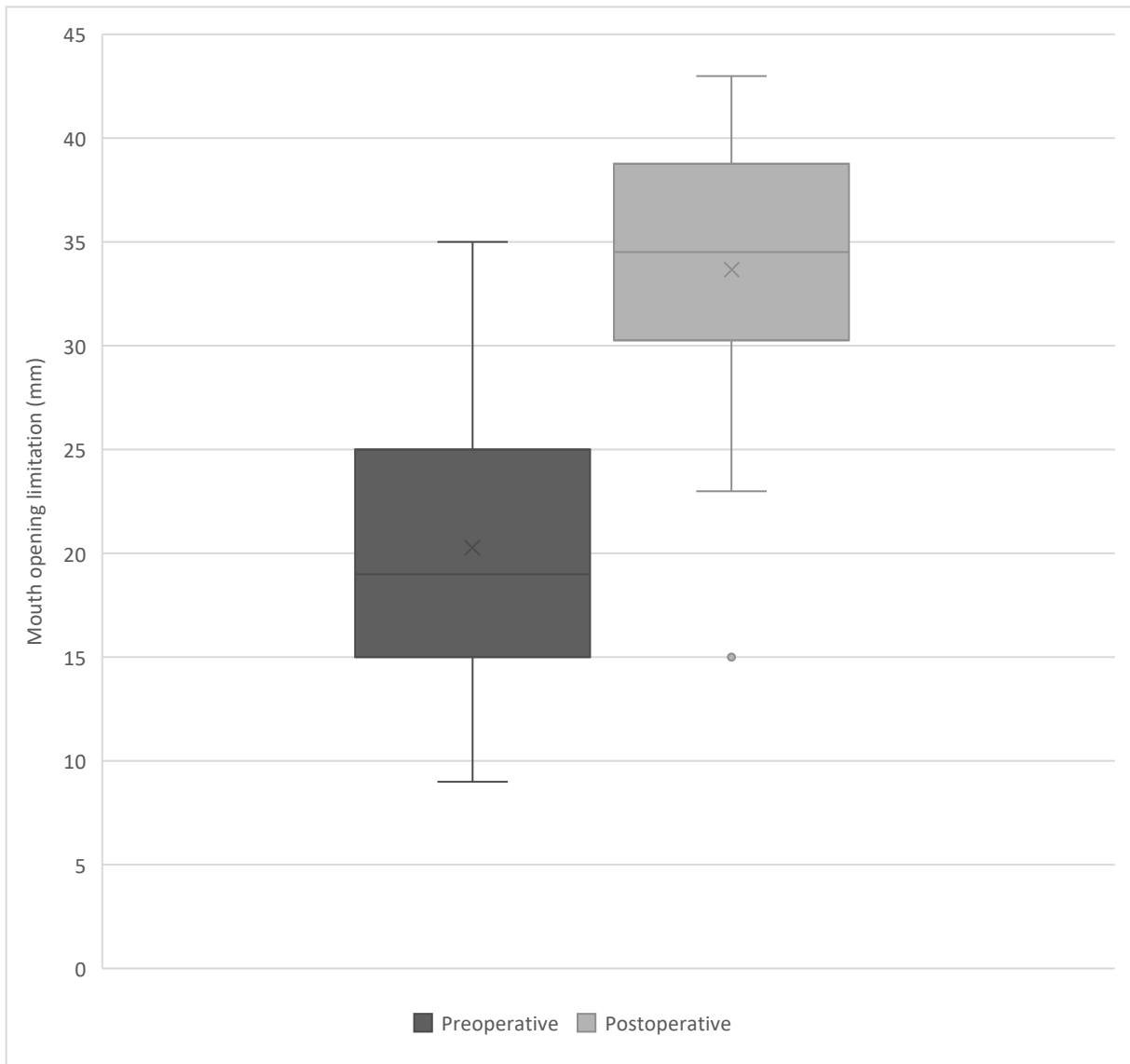
The MO was improved from 20.28 ± 6.66 mm in preoperative time to 33.65 ± 6.81 mm in postoperative period ($p < 0.0001$). However, clinical improvement was poor for two patients (#3 and #7) in who still reported difficulties with feeding and proper dental care.

The duration of postoperative follow-up was therefore disparate among patients; it ranged from 3 months to 14 years. The mean follow-up duration between the M1 and M2 measurements was 21.5 ± 40.5 months.

Therapeutic management of patients (Table 1, Figure 3)

A bilateral coronoidectomy was performed in 17 cases, while 3 patients required a unilateral procedure. Only one patient was given a mixed coronal and intra-oral approach due to the size of the coronoid process extending far above the zygomatic arch into the temporal fossa outside the orbit. All other patients required an intra-oral procedure.

We reported three cases of botulinum toxin injections in the masticatory muscles during the surgical procedure, with a mean of 40 IU in each temporal muscle. Two other patients received botulinum toxin injections in the main masticatory muscles postoperatively at one year after coronoidectomy. All patients received rehabilitation by a physical therapist, followed by self-rehabilitation training. This consisted of diduction, propulsion and mouth opening exercises. The self-rehabilitation consisted of the use of objects of increasing size to gradually increase the mouth opening. However, the frequency of sessions was not known for all patients.



Preoperative and postoperative mouth opening measurements (in millimeters)

Clinical cases

In patient #2, the diagnosis of Langenbeck's disease was evoked by the fact that his mouth opening was limited to 20 mm, which was disabling at the time and was detected by his dental surgeon. He underwent a bilateral coronoidectomy at the age of 12. The immediate postoperative mouth opening measurement was 40 mm. The patient performed self-rehabilitation with corks, but received no other adjuvant treatment. After fourteen years of follow-up, the mouth opening measurement was 38 mm. The patient has no complaints about his initial pathology to date.

Patient #7 has had multiple recurrences despite four coronoidectomies between 2001 and 2021. This patient has chronic mechanical limitation of mouth opening due to conflict of the coronoid processes with the zygomatic bone. After the first three procedures, an improvement in mouth opening was transiently noted. The patient's quality of life was impaired: eating was made difficult and dental care was complicated or even absent (loss of two molars due to carious lesions).

The last surgical procedure in 2021 consisted of a bilateral coronoidectomy through a coronal and intraoral approach under general anesthesia. Preoperative CBCT (Figure 2) showed a right coronoid process of more than 28 mm, and a left coronoid process of more than 40 mm.

The immediate postoperative forced mouth opening was 25 mm. In addition, the patient received botulinum toxin injections into each temporal muscle body (40 IU per muscle). At the follow-up (three months) mouth opening was measured at 15 mm.

DISCUSSION

Due to the MOL, Jacob's and Langenbeck's diseases may have a clinical impact on the quality of life of patients. These pathologies strongly alter eating, chewing, phonation and oral hygiene.

These are rare diseases, poorly described in the literature with no precise prevalence value (18). Furthermore, most of cases are under-diagnosed because they are often initially treated as TMJ disorders (19). A prevalence of 0.5% has been reported for asymptomatic hyperplasia of the coronoid process (3,19). It can therefore be assumed that the prevalence of symptomatic Langenbeck's and Jacob's disease is much lower. The treatment is based on a surgical unilateral or bilateral coronoidectomy to resect the hypertrophic coronoid process and release the temporal insertions to improve mouth opening. However, this treatment has not been evaluated in terms of improvement of the mouth opening and the risk of recurrence. Other treatments have been described to limit the risk of recurrence and improve joint amplitudes; they are based on physical therapy, injection of botulinum toxin in the masticatory muscles. A recurrence rate of 2% has been reported in the literature (19). However, the concept of recurrence seems to cover only the new bone growth of the coronoid process(es), but does not address the clinical symptomatology represented by the oral opening measurements, as studied here. Yet it is the clinical symptoms that are the focus of patients' concern.

This study is the first to focus on the evaluation of oral opening after coronoidectomy in patients with Langenbeck's or Jacob's disease. Twenty patients were studied in three different French centers, which reflects the extreme rarity of the pathology. We demonstrated no recurrence of mouth opening limitation after coronoidectomy. Within our 21.5 months evaluation period, we found no stagnation or clinical worsening of mouth opening among the 20 patients. It is important to note that all patients in our study were followed up for rehabilitation by a physical therapist or self-rehabilitation with exercises taught by the surgeon (use of the plug). Thus, the use of rehabilitation may explain the maintenance of a correct post-coronoidectomy mouth opening (16). In their literature review of 73 operated patients, Goh *et al.* found the absence of improvement in mouth opening in 2 patients and worsening in 7 patients (increased mouth opening limitation postoperatively). Thus, the authors reported 12% of cases presenting with a clinical recurrence of symptoms, without necessarily documenting bone regrowth of the coronoid processes. We did not observe any recurrence of mouth limitation after the surgical procedure. This review includes almost all cases with Langenbeck's and Jacob's disease operated by coronoidectomy found in the literature. Furthermore, the authors found an improvement in mouth opening from 16.52 ± 6.87 mm

preoperatively to 34.88 ± 13.91 mm postoperatively, which is very similar to our results. However, our observation period was longer than the literature review (21.5 ± 40.5 months vs 19.9 ± 22.9 months respectively).

Our study suffers from inevitable drawbacks. First, the retrospective nature of this study sometimes made it difficult to collect the clinical information and symptoms reported by the patients (pain, difficulty in eating and speaking). Postoperative imaging was not systematically performed, which made it impossible to calculate the kinetics of bone regrowth of the coronoid processes. Rehabilitation protocols were sometimes poorly reported. Second, because of the rarity of the disease and the fact that it is often confused with a TMJ disorder, the number of patients collected was small. However, our study reported the largest cohort of patients from Langenbeck and Jacob. Third, postoperative follow-up was sometimes short and did not diagnose recurrence of mouth opening limitation, which may occur later.

Given the risk of clinical recurrence, it is therefore essential to inform patients that they should only undergo surgery if the mouth opening limitation is severe and impacts their quality of life. Thus, the question arises as to what factors may influence the recurrence of mouth opening limitation in these conditions, as well as the correlation or dissociation between the recurrence of mouth opening limitation and bone regrowth of the coronoid processes. Numerous hypotheses can be formulated regarding the factors favoring anatomical recurrence and clinical recurrence. Indeed, during coronoidectomy, the formation of a hematoma opposite the resected process could induce an increased capacity for bone regeneration (11). Similarly, some studies have reported an involvement of growth hormones during puberty, related to an exaggeration of the normal growth pattern observed at this period (10). Finally, the initial surgical failure could be attributed to the continuous growth of the face, secondary to the young age of the patients (14). On the other hand, there is still no consensus on the use of botulinum toxin injections to limit the stresses exerted by the remaining temporal muscle fibers on the coronoid process. Some clinicians perform these injections at the end of the surgical procedure, some propose the injection of botulinum toxin during the follow-up. Similarly, the use of biphosphonates postoperatively has been reported in order to limit the risk of recurrence of growth of the coronoid process but has not been studied (20). de la Torre *et al.* suggested to maintain a continuous mouth opening postoperatively with a removable upper acrylic splint to limit fibrosis and trismus (17).

To go further, it would be necessary to understand more about the pathophysiology of Jacob and Langenbeck diseases.

An interest in the embryology of the coronoid process could help answer some of these questions. Indeed, during the embryological formation of the mandible, growth takes place in the three directions of space through the different skeletal units. In particular, the future mandibular apophyses are referred to as secondary cartilages (condylar and coronoid cartilages in particular). These secondary cartilages are under the influence of local factors. In this case, the coronoid cartilages are under the influence of the temporal muscles.

In the same way, the realization of a systematic assessment in affected patients could be relevant: performing a systematic imaging in the immediate postoperative period, looking for radiological signs (formation of a neo-articulation with the zygomatic arch, appearance of the condyle), biological workup, oral clinical examination that may reveal signs of bruxism by the presence of dental wear facets, palpation and search for hypertrophy of the temporal and masseter muscles, diduction values, and information regarding condylar growth disorders in very young patients. The answers to these questions seem complex and could be provided by massive data collection. Our data are interesting and pave the way for larger studies.

References

1. Langenbeck B. Angeborene Kleinert der Unterkiefer. Langenbecks Arch. 1861;1:451.
2. Jacob O. Une cause rare de constriction permanente des machoires. Bull Mém Société Anat Paris. 1899;(1):917-9.
3. Roychoudhury A, Gupta YK, Parkash H, Karak AK. Jacob disease: Report of a case and review of the literature. J Oral Maxillofac Surg. juin 2002;60(6):699-703.
4. Ajila V, Hegde S, Gopakumar R, Babu GS. Imaging and Histopathological Features of Jacob's Disease: A Case Study. Head Neck Pathol. mars 2012;6(1):51-3.
5. Sreeramaneni SK, Chakravarthi PS, Krishna Prasad L, Raja Satish P, Beeram RK. Jacob's disease: report of a rare case and literature review. Int J Oral Maxillofac Surg. juill 2011;40(7):753-7.
6. Goh YC, Tan CC, Lim D. Coronoid hyperplasia: A review. J Stomatol Oral Maxillofac Surg. sept 2020;121(4):397-403.
7. Puche M, Guijarro-Martínez R, Pérez-Herrezuelo G, Miragall L, Iglesias ME, Martínez-Costa C. The hypothetical role of congenital hypotonia in the development of early coronoid hyperplasia. J Cranio-Maxillofac Surg. sept 2012;40(6):e155-8.
8. Isberg A, Isacson G, Nah KS. Mandibular coronoid process locking: A prospective study of frequency and association with internal derangement of the temporomandibular joint. Oral Surg Oral Med Oral Pathol. mars 1987;63(3):275-9.
9. Iqbal S, Hamid ALA, Purmal K. Unilateral coronoid hyperplasia following trauma: a case report. Dent Traumatol. déc 2009;25(6):626-30.
10. Rowe NL. Bilateral developmental hyperplasia of the mandibular coronoid process. Br J Oral Surg. janv 1963;1:90-104.
11. Smyth AG, Wake MJC. Recurrent bilateral coronoid hyperplasia: an unusual case. Br J Oral Maxillofac Surg. avr 1994;32(2):100-4.
12. McLoughlin PM, Hopper C, Bowley NB. Hyperplasia of the mandibular coronoid process. J Oral Maxillofac Surg. mars 1995;53(3):250-5.

13. Kai S, Hijiya T, Yamane K, Higuchi Y. Open-mouth locking caused by unilateral elongated coronoid process: Report of case. *J Oral Maxillofac Surg.* nov 1997;55(11):1305-8.
14. Schneble EJ, Moore RD, Pettersson DR, Pollock JM, Barajas Jr RF. Coronoid Process Hyperplasia: A Rare Disorder Masquerading as Temporomandibular Joint Disease. *Clin Neuroradiol.* déc 2019;29(4):787-9.
15. Gagé J, Gallucci A, Stroumsa R, Foletti JM, Guyot L, Chossegros C. Coronoïdectomie intra-orale : note technique. *Rev Stomatol Chir Maxillo-Faciale Chir Orale.* déc 2015;116(6):368-71.
16. Capote A, Rodríguez FJ, Blasco A, Muñoz MF. Enfermedad de Jacob asociada con el síndrome de disfunción de la articulación temporomandibular: Presentación de un caso. *Med Oral Patol Oral Cir Bucal.* :5.
17. de la Torre ÒE i, Klok EV, Roig AM i, Mommaerts MY, Ayats JP i. Jacob's disease: report of two cases and review of the literature. *J Cranio-Maxillofac Surg.* déc 2001;29(6):372-6.
18. Thota G, Cillo JE, Krajekian J, Dattilo DJ. Bilateral Pseudojoints of the Coronoid Process (Jacob Disease): Report of a Case and Review of the Literature. *J Oral Maxillofac Surg.* nov 2009;67(11):2521-4.
19. Allan IMcDB, Reid WH. Unilateral exostosis of the coronoid process of the mandible. *Br J Oral Surg.* juill 1967;5(1):20-4.
20. Stow S, Nicmann K, Miller J. Disodium ctidronate in the prevention of postoperative recurrence of heterotopic ossikation in the spinal cord injured patient. *J Bone Joint Surg* 1976; 58: 683-687. *J Bone Joint Surg.* 1976;

Figures

Figure 1 – Flow chart

Figure 2 – Pre-operative and post-operative coronal sections in a patient with Langenbeck disease. A. The left corona is measured at 40.2 mm. B. The right corona is measured at 26.3 mm. C. After coronoidectomy and after 3 months, the left corona is measured at 13.6 mm. The right corona is measured at 18.4 mm. which is visible in the masticatory space of the infratemporal fossa on a coronal cut through the zygomatic arch. Postoperative CBCT at three months shows resected coronoid processes of less than 20 mm on the left, as on the right. The masticatory space is clear on the coronal section.

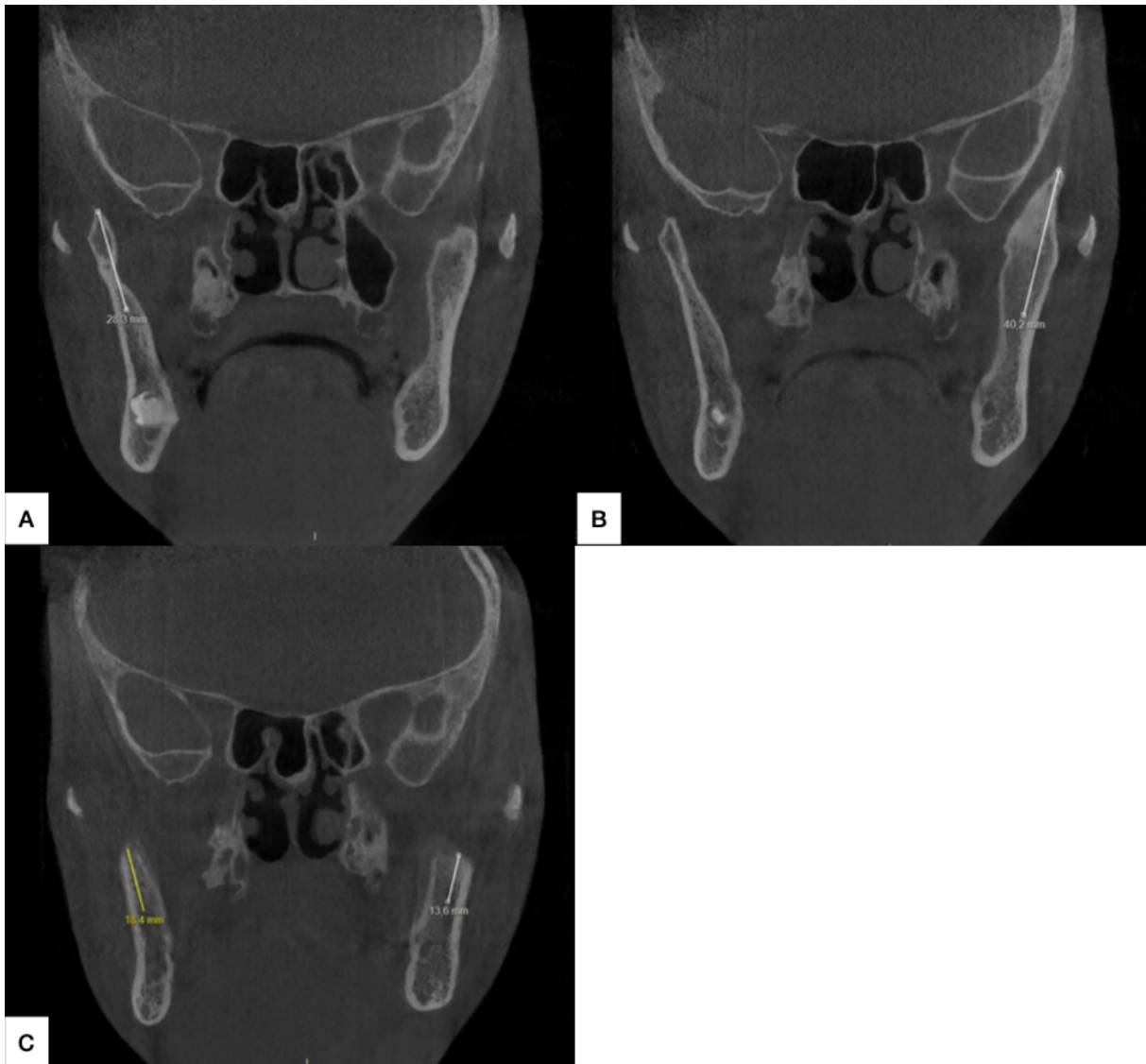


Figure 3 – Table 1

PATIENT	GENDER	AGE AT SURGERY	DIAGNOSIS	SIDE	SURGICAL ACCESS	PREOPERATIVE MO M1 (mm)	IMMEDIATE POSTOPERATIVE MO (mm)	POSTOPERATIVE MO M2 (mm)	FOLLOW-UP PERIOD M1-M2 (months)	USE OF BOTULINIC TOXIN	PHYSIOTHERAPY
1	F	19	Langenbeck	Uni (left)	Intraoral	12	NA	38	96	no	self-rehabilitation
2	M	12	Langenbeck	Bi	Intraoral	20	40	38	168	no	self-rehabilitation
3	M	6	Langenbeck	Bi	Intraoral	18	28	23	4	no	NA
4	M	18	Jacob	Bi	Intraoral	29	43	33	37	yes	self-rehabilitation
5	F	14	Jacob	Bi	Intraoral	22	NA	34	20	no	NA
6	M	14	Langenbeck	Bi	Intraoral	27,5	NA	43	6	no	physiotherapy (one every fifteen days)
7	M	23	Langenbeck	Bi	Intraoral and coronal	9	25	15	3	yes	physiotherapy and self-rehabilitation
8	F	NA	Langenbeck	Bi	Intraoral	18	NA	31	5	no	NA
9	NA	NA	Langenbeck	Bi	Intraoral	25	45	39	3	no	physiotherapy and self-rehabilitation
10	M	28	Langenbeck	Bi	Intraoral	15	40	34	6	no	physiotherapy and self-rehabilitation
11	M	15	Langenbeck	Bi	Intraoral	15	40	35	6	no	physiotherapy and self-rehabilitation
12	M	5	Langenbeck	Uni (left)	Intraoral	23	NA	30	3	no	NA
13	M	15	Langenbeck	Bi	Intraoral	22	40	40	6	no	NA
14	F	9	Langenbeck	Bi	Intraoral	15	36	35	9	no	physiotherapy and self-rehabilitation

15	M	15	Langenbeck	Bi	Intraoral	25	NA	30	6	no	NA
16	F	15	Langenbeck	Bi	Intraoral	29	NA	40	3	no	self-rehabilitation
17	F	25	Langenbeck	Bi	Intraoral	16	50	33	9	no	self-rehabilitation
18	M	18	Langenbeck	Bi	Intraoral	35	42	42	24	yes	physiotherapy and self-rehabilitation
19	M	28	Jacob	Bi	Intraoral	15	25	35	12	no	self-rehabilitation
20	NA	15	Langenbeck	Bi	Intraoral	15	40	25	3	no	self-rehabilitation


MO: mouth opening; NA : not available; Uni: unilateral; Bi: bilateral

Figure 4 – Table 2

PATIENT	PREOPERATIVE MO M1 (mm)	POSTOPERATIVE MO M2 (mm)	FOLLOW-UP PERIOD M1-M2 (months)
1	12	38	96
2	20	38	168
3	18	23	4
4	29	33	37
5	22	34	20
6	27,5	43	6
7	9	15	3
8	18	31	5
9	25	39	3
10	15	34	6
11	15	35	6
12	23	30	3
13	22	40	6
14	15	35	9
15	25	30	6
16	29	40	3
17	16	33	9
18	35	42	24
19	15	35	12
20	15	25	3

Vu, le Président du Jury,


(Tampon et signature)



Pr Pierre CORRE

Vu, le Directeur de Thèse,

(Tampon et signature)



Pr Pierre CORRE

Vu, le Doyen de la Faculté,



Professeur Pascale JOLLIET

NOM : DOMART

PRENOM : Manon

Titre de Thèse : Contrôle de l'ouverture buccale après coronoïdectomie chez les patients atteints de la maladie de Langenbeck ou de Jacob. Une étude rétrospective de 20 cas.

RESUME (10 lignes)

Les maladies de Langenbeck et de Jacob sont des causes rares de limitation progressive de l'ouverture de la bouche, causée par l'hypertrophie du ou des coronés sur l'os zygomatique. Cette étude rétrospective a porté sur vingt patients présentant une limitation de l'ouverture de bouche et ayant subi une coronoïdectomie. Contrairement à la littérature où l'on retrouve des taux de récurrence allant de 2 à 12%, le suivi postopératoire de ces patients a montré qu'aucune récurrence clinique n'était survenue. Le point commun de ces vingt patients était de poursuivre une physiothérapie efficace. Bien que le traitement standard de ces affections soit la coronoïdectomie, il semble important de considérer le rapport bénéfice/risque du patient et de n'opérer que si la limitation de l'ouverture buccale entraîne une réelle souffrance clinique pour la qualité de vie du patient.

MOTS-CLES

Mandible
Musculoskeletal diseases
Mandibular diseases
Craniomandibular disorders
Coronoid process
Hyperplasia