



HAL
open science

Reconstruction of the orbital framework in Brown class III maxillectomies: a systematic review

Sophie Dugast

► **To cite this version:**

Sophie Dugast. Reconstruction of the orbital framework in Brown class III maxillectomies: a systematic review. Médecine humaine et pathologie. 2022. dumas-03940410

HAL Id: dumas-03940410

<https://dumas.ccsd.cnrs.fr/dumas-03940410>

Submitted on 16 Jan 2023

HAL is a multi-disciplinary open access archive for the deposit and dissemination of scientific research documents, whether they are published or not. The documents may come from teaching and research institutions in France or abroad, or from public or private research centers.

L'archive ouverte pluridisciplinaire **HAL**, est destinée au dépôt et à la diffusion de documents scientifiques de niveau recherche, publiés ou non, émanant des établissements d'enseignement et de recherche français ou étrangers, des laboratoires publics ou privés.

IMPORTANT : OBLIGATIONS DE LA PERSONNE CONSULTANT CE DOCUMENT

Conformément au *Code de la propriété intellectuelle*, nous rappelons que le document est destiné à un **usage strictement personnel**. Les "analyses et les courtes citations justifiées par le caractère critique, polémique, pédagogique, scientifique ou d'information" sont autorisées sous réserve de mentionner les noms de l'auteur et de la source (article L. 122-4 du *Code de la propriété intellectuelle*). Toute autre représentation ou reproduction intégrale ou partielle, faite sans le consentement de l'auteur ou de ses ayants droit, est illicite.

De ce fait, nous vous rappelons notamment que, **sauf accord explicite** de l'auteur de la thèse ou du mémoire, **vous n'êtes pas autorisé** à rediffuser ce document sous quelque forme que ce soit (impression papier, transfert par voie électronique, ou autre). Tout contrevenant s'expose aux peines prévues par la loi.

NANTES UNIVERSITÉ

FACULTÉ DE MÉDECINE

Année : 2022

N°

THÈSE

pour le

DIPLÔME D'ÉTAT DE DOCTEUR EN MÉDECINE

(Chirurgie Maxillo Faciale)

par

Sophie DUGAST

Présentée et soutenue publiquement le 27 octobre 2022

**RECONSTRUCTION OF THE ORBITAL FRAMEWORK IN BROWN CLASS III
MAXILLECTOMIES, A SYSTEMATIC REVIEW**

Président : Monsieur le Professeur Pierre CORRE

Directeur de thèse : Monsieur le Docteur Helios BERTIN

Membres du Jury : Madame le Docteur Julie LONGIS
Monsieur le Docteur Christophe FERRON
Monsieur le Docteur Bertrand VABRES

REMERCIEMENTS

Monsieur le Professeur Corre

Je te remercie de Présider ce jury, tu te distingues à mon sens par ton humanité et ta gentillesse. C'est avec beaucoup de hâte que j'attends de passer avec toi, je suis sûre que ce semestre sera extrêmement enrichissant et formateur.

Monsieur le Docteur Helios Bertin

Hélios je te remercie sincèrement pour ton aide précieuse sans laquelle ce travail n'aurait pas vu le jour. J'admire ta grande rigueur chirurgicale et ton implication dans notre formation, j'ai beaucoup appris à tes côtés. J'ai toujours pu compter sur ton aide, une nouvelle fois, merci pour tout.

Madame le Docteur Julie Longis

Depuis le début de mon internat j'ai beaucoup d'admiration pour toi, sur le plan professionnel et humain, tu m'inspires beaucoup et j'espère, un jour, pouvoir suivre tes pas.

Monsieur le Docteur Christophe Ferron

Je vous remercie pour le semestre formidable que j'ai passé avec vous, pour m'avoir fait confiance et m'avoir laissé beaucoup d'autonomie. Ça a été pour moi exceptionnel d'apprendre à opérer à vos côtés, et de suivre pendant ces six mois votre patientelle très touchante.

Monsieur le Docteur Bertrand Vabres :

Je vous remercie d'avoir accepté de faire partie de ce jury, et de nous apporter votre expertise sur ce sujet. La FST de chirurgie d'orbito-palpébro-lacrymale a permis de créer un lien précieux entre nos spécialités qui nous permet de réévaluer nos pratiques et d'améliorer la prise en charge de nos patients. Je tiens à vous remercier pour la grande bienveillance dont vous avez fait preuve dans les différentes rencontres organisées dans le cadre de cette formation.

Maman

C'est dans les moments heureux que tu nous manques le plus, je suis si fière de toi, il ne se passe pas un jour sans que mes pensées ne te reviennent.
J'espère que d'où tu es ça sent le boit de soeuvre et le coquelicot.
Je t'aime de tout mon coeur.

Papa

Tu n'as pas d'égal en termes de dévotion, de générosité et de tolérance. Merci de nous soutenir dans chacun de nos choix, d'être aussi présent et aimant envers nous trois.
Il n'y a pas de mot suffisant pour t'exprimer notre amour.

Julie

Ma Juju, ton attention aux autres, aux petites choses du quotidien, ta culture et ta générosité m'ont toujours impressionnée.
Je suis fière de tout ce que tu es devenue, t'admire et te soutiendrai toujours.
Continue de rêver.

Margot

Margoton, petite dernière qu'on aime et qu'on admire. Je te souhaite d'être toujours heureuse et rayonnante comme tu l'es aujourd'hui.
A nos fous rire partagés tous les quatre.
Je t'aime.

Benoît

Tu n'es semblable à personne d'autre, tu me fascines et me fais rire chaque jour.
Etre à tes côtés est la plus grande joie de ma vie. Je t'aime plus que tout.

Aux grands parents

Papy Gilles

A nos longues discussions traduisant toute ta tolérance, ton humour et ton intelligence.
Je suis heureuse des liens forts que nous entretenons, merci de tout ce que tu fais pour nous. Je t'aime.

Nicole

Merci d'avoir été là, tu resteras à mes yeux le symbole de la femme forte et indépendante.

Papy et Mamie

A toutes les histoires extraordinaires de vos vies passées, pleines de voyages, de lectures, et d'aventure. Nous avons eu la chance d'en avoir les récits qui ont nourri notre imagination quand nous étions petites. Nous vous aimons très fort.

Manue, François, Anne, Cyril, Charlotte, Juliette, Mathilde, Daphnée, Manon

C'est une joie de vous avoir pour famille, vous êtes tous très différents ce qui rend nos retrouvailles le temps avançant de plus en plus enrichissantes. A nos prochaines rencontres..

A notre famille d'adoption Marie et Sophie

Vous nous avez apporté beaucoup de lumière et de rires dans nos vies, c'est toujours un immense plaisir de partager des moments à vos côtés.

A mes plus anciens amis

Roxanne Clara Antoine et Charles

A toutes les vacances passées ensemble depuis qu'on sait marcher. Et aux fous rires partagés, petit big up à l'usurpation d'identité Clara. (Et à vos parents bien sûr qui sont presque nos parents aussi)

Marie, Camille, Camille et Clémence

Mes amies de toujours avec qui j'ai grandi (et beaucoup, beaucoup ri), même si aujourd'hui la distance nous sépare c'est toujours une joie de vous revoir.

La Troll Team

Raphael, Morgan, Aymeric, Valentin, Valentin, Vincent, Jean, Thibaut, Briec, Zoé, mes copains de lycée, aux semaines de vacances et aux soirées du nouvel an à Douarnenez, où nous dormions tous ensemble dans le grenier, je suis heureuse de vous savoir tous épanouis.

Les Kikafete

Les filles, ma team, j'ai commencé à écrire des petits mots doux pour chacune d'entre vous, finalement on va faire simple comme on s'était dit, je vous aime très fort.

A mes très chers amis de Nantes

Helene, Magalie, Charlotte, Sophia, Doriane, Gaétan, Dani, Hugo, Camille, Clémence, Léa, Nicolas et Clémence, Eloïse et Thibault, Antoine, Ines et tous les autres, chaque moments passés avec vous sont des moments de qualité, qui me soulèvent de joie, je suis la plus heureuse de vous avoir rencontrés et de partager ces instants avec vous.

A mes chefs de CMF du CHU de Nantes

Monsieur le Docteur Benoit Piot

Porteur de la cancérologie dans ce service depuis de nombreuses années, tu es toujours disponible pour nous apporter ton expérience et répondre à nos questions. Ça a été un plaisir d'avoir pu aller un peu au bloc avec toi ce semestre. Merci pour ta gentillesse.

Monsieur le Docteur Jean-Philippe Perrin

Nous avons beaucoup de chance de pouvoir bénéficier de vos réflexions et conseils aux staffs d'orthognatique, vous nous poussez à toujours garder l'esprit critique et ouvert. Merci de contribuer à maintenir éveillées nos consciences écologiques.

Marine

Ça a été un plaisir de passer un semestre avec toi, merci pour ta douceur et ta gentillesse. A mes yeux tu sais tout faire, tu es pour moi un exemple.

Mae

Mae, j'ai beaucoup d'admiration pour toi, ton travail et ta détermination. Même si je n'ai pas réussi à parfaitement appréhender Paul B. Preciado, tu m'as sensibilisée au féminisme et autres jolies causes. J'espère que nous continuerons nos échanges à l'avenir et je te souhaite plein de réussite dans ta vie personnelle et professionnelle.

Charlotte

Tu sais toute l'amitié et l'admiration que j'ai pour toi. J'espère que tu pourras poursuivre tous tes jolis projets, tu mérites le meilleur.

Quentin, Justine et Pierre merci pour votre disponibilité et votre gentillesse à l'hôpital et en dehors.

Fanny Laure et Carine, mes premières cheffes de CMF

A Fanny Laure pour ton dynamisme, ta bonne humeur constante et pour m'avoir laissé très tôt beaucoup d'autonomie. A Carine pour ton soutien, ta rigueur et pour m'avoir fait découvrir les bars à vins de Nantes c'est toujours un plaisir de te revoir.

A mes chers co-internes de CMF de Nantes et d'ailleurs Amaury, Victoria, Quitterie, Marine, Julia, Chloe, Mathilde, Charlotte, Alexandre, Sophie, Mathilde, Than Thuy, Samy, tous aux personnalités riches et singulières, vous êtes une jolie équipe de co-internes.

A l'équipe d'ORL du CHU de Nantes

Monsieur le Professeur Olivier Malard

Je tiens à te remercier pour ta confiance et ton accueil dans ce service. J'ai passé trois mois extrêmement formateurs, variés et denses où j'ai énormément appris. Ça a été un honneur et un plaisir de travailler avec toi pour qui j'ai une grande estime.

Pauline, Claire et Marine

J'ai été très heureuse de travailler avec vous, au-delà de votre gentillesse (et votre humour) vous avez été d'un grand soutien et m'avez beaucoup appris. Vous êtes toutes les trois très talentueuses et rigoureuses. Je suis ravie de continuer à vous voir de temps en temps en dehors de l'hôpital.

Aux autres chefs d'ORL

Monsieur Bordure, Guillaume, Julie, Laetitia, et Florent, merci pour votre accueil et votre gentillesse.

A mes co-internes d'ORL

Manon, Volkan, Sarah, Delphine, Adrien, Jules, Arthur, à ce semestre assez incroyable où nous nous sommes particulièrement bien entendus et où nous avons eu l'occasion de faire de nombreux apéros-bureau en cette période de confinement.

Yasmine, devenue mon amie et avec qui on ne se quitte plus tellement, Gabriel, Philomène, Maxime, Ambroise, Audrey et Benoit, merci pour ce deuxième semestre passé à vos côtés.

A toute l'équipe d'infirmières, d'aide soignantes, de secrétaires dans le service de tête et cou du CHU de Nantes, en hospitalisation, en consultation et au bloc opératoire, merci pour votre implication au quotidien, vous faites un travail d'une immense qualité.

A l'équipe de Chirurgie cervico faciale de l'Institut Gustave Roussy

Monsieur le Docteur Stéphane Temam

Vous voir opérer a été un bouleversement dans ma formation. Votre élégance chirurgicale et la précision de chacun de vos gestes témoignent de l'ampleur de votre excellence. Je ne vous remercierai jamais assez pour ce que vous m'avez transmis. C'est un honneur de vous avoir rencontré et d'avoir pu travailler à vos côtés.

Madame le Docteur Nadia Benmoussa

Nadia, merci pour nos échanges, pour nous avoir fait partager tes raisonnements, ta curiosité, ça a pour moi été très inspirant de te rencontrer professionnellement et personnellement. J'ai, comme tu le sais, énormément d'admiration pour toi. Au plaisir de te revoir.

Monsieur le Docteur Antoine Moya Plana

Merci pour ta patience, pour avoir pris le temps de nous expliquer en détail ta manière d'aborder les différentes chirurgies, de nous avoir fait part de la planification de tes gestes sur les imageries préopératoires, ça a été pour moi très formateur.

Docteur Ingrid Breuskin

Merci pour ta gentillesse, ta bonne humeur et ta grande confiance au bloc opératoire, je continue de m'entraîner à opérer à la lame froide comme tu m'as appris dès que j'en ai l'occasion.

Au docteur Gorphe, au docteur Honart, au docteur Hartl, au docteur De kermadec et au docteur Guerlain que je remercie pour leur accueil, leur gentillesse et leur disponibilité, j'ai beaucoup d'estime pour chacun d'entre vous.

Monsieur le Docteur Frédéric Kolb

J'ai une grande admiration pour votre travail, et ai beaucoup de chance que vous me partagiez votre expérience sur les reconstructions mandibulaires de l'enfant, c'est un honneur de pouvoir participer à ce travail, je vous en remercie.

A mes chefs Alix, Sandrine et Adrien, vous avez été exceptionnels, drôles et toujours présents dans les moments d'urgence (je retiendrai la vraie question : Est-ce que je dois courir ?, et le buzzer magique qui nous réconfortait 100 fois par jour), merci encore.

Enfin, à mes co-internes, Cristina, Roxane, Elodie, Emilie et Gaétan, je vous remercie du fond du cœur d'avoir rendu ce semestre si agréable malgré les conditions très intenses dans lesquelles nous travaillions, je vous souhaite le meilleur. Vous serez toujours les bienvenus à Nantes.

REMERCIEMENTS	2
ABSTRACT	9
INTRODUCTION	10
MATERIALS AND METHODS	12
RESULTS	14
DISCUSSION	29
CONCLUSION	34
APPENDIX I	35
BIBLIOGRAPHY	36

ABSTRACT

Background: This systematic review aimed to evaluate the surgical techniques used for orbital floor reconstruction after Brown class III maxillectomies in malignant tumors, regarding ocular functional and esthetic parameters.

Material and methods: An electronic search was conducted using PubMed, Cochrane Library and Google Scholar from January 1990 to January 2022. Forty-four articles were included after study selection, 20 were selected after eligibility assessment. Risk of bias assessment was performed according to the MQAT for case reports and case series. The studies were classified in four groups regarding the surgical technique: group A related to free bone flaps, group B included alloplastic implants, group C included bone grafts, and group D reported the soft-tissue reconstructions.

Results: The included studies were retrospective and descriptive, and enrolled a total of 232 patients. Ectropion and diplopia were assessed clinically and concerned 42.6% and 6.6% of the patients respectively. The soft tissue reconstruction was more likely to cause ectropion (17/27), followed by the reconstruction techniques of group B (34/79), group C (26/70) and group A (1/7). Six cases of decrease visual acuity were recorded all studies combined. Regarding the aesthetic parameters, a postoperative enophthalmos was identified in 18 patients (9.6%), mostly in group D (5/35) followed by groups B (8/68), A (3/33) and C (2/52); while orbit dystopia was described in 6 patients, mostly in group C (5/79). A material exposure occurred in 19 patients including 17 in group B. The quality of articles was high 10 studies, moderate in 7 studies and low in 3 studies.

Conclusion: Qualitative evaluation of existing techniques used for orbital floor reconstruction after maxillectomy suggests that free bone flaps and alloplastic implants represent good reconstructive options with respect to postoperative ocular parameters.

KEYWORDS

Maxillary cancer; orbit surgery; reconstruction; systematic review

INTRODUCTION

Maxillary tumors are rare diseases that can arise from the osseous palate, the alveolar gum, or from the sinus floor. These tumors currently represent 3 to 5% of head and neck cancers with the main histology being squamous cell carcinoma (1,2). Most of these tumors are locally advanced at diagnosis due to late and non-specific symptoms. The recommended treatment is based on a complete surgical removal of the lesion involving all or part of the maxillary bone, and sometimes reaching the orbital bone structures, with an adjuvant radiotherapy (3). For several years, the improvement of reconstruction techniques has enabled more extensive resections allowing a better local control of these tumors. Reconstruction of total maxillectomies remains one of the most delicate procedures in the head and neck region, due to the three-dimensional shape of the maxillary bone (4).

A primary reconstruction, *i.e.* during the carcinologic excision procedure, should be proposed as often as possible (5). As with any oncological reconstruction, the main objectives are to ensure the survival of the patient, to restore the oro-facial functions (breathing, vision, chewing, speech) and as much as possible, to provide a socially acceptable aesthetic result. Several algorithms for the management of different types of maxillectomies have been proposed (6,7). Nevertheless, because of the rarity of the maxillary tumors, there is currently no consensus regarding the reconstruction of Brown class III maxillary defects. These excisions include the maxillary infrastructure associated with the lower part of the orbital frame, which may include the infraorbital rim, the floor of the orbit and the medial or lateral wall of the orbit in their lower portion (4,8). The purpose of this reconstruction is to provide support to the orbital contents in order to maintain its function and satisfactory facial symmetry. These reconstructions are even more challenging as they will be the site of additional radiotherapy which increases the risk of specific functional and aesthetic sequelae (*i.e.* diplopia, ectropion, enophthalmos, lagophthalmos) (9). Various surgical techniques have been described to ensure the support of the orbital contents after removal of the orbital floor. Free bone flaps procedures using a fibula flap, an iliac crest flap or even a costal free flap are currently proposed because of their reliability and their lower bone resorption compared to bone grafts (10–14). Free bone flaps allow both the restoration of the maxillary arch for dental rehabilitation, and orbit reconstruction by providing a solid

and stable bone support for the orbital content (12,15,16). The use of autologous bone grafts including rib, calvaria or iliac crest grafts covered by free or pedicled soft tissue flaps, have also been described (7,12,17–21). These techniques are often considered at risk of exposure, infection, and bone resorption especially after radiotherapy. The use of alloplastic implants such as titanium mesh have also been reported; despite promising aesthetic and functional results, the risk of material exposure and infection is significant considering the common postoperative irradiation (22–28). Finally, some authors are favorable to reconstruct of the orbital floor with soft tissues and in particular with fascia lata strips because of their ease and rapidity of harvesting and their lower risk of complications (29–31).

Through a systematic review of the literature, the objective of this study was to compare the different surgical techniques used for the reconstruction of the orbital floor after Brown class III maxillectomies for malignant tumors in terms of functional and aesthetic parameters.

MATERIALS AND METHODS

This systematic review was conducted in accordance with the items of the PRISMA-NMA (Preferred Reporting Items for Systematic Reviews and Meta-Analyses –Network Meta Analyses) checklist (32). The study was registered within the International prospective register of systematic reviews, Prospero (CRD42021269910).

A systematic research was carried out on three different literature bases: PubMed, Cochrane Library and Google Scholar. For this the following terms were used: ((maxillectomy[Title/Abstract]) OR (maxillar resection[Title/Abstract]) OR (maxilla resection[Title/Abstract]) OR (upper jaw resection[Title/Abstract]) OR (midfacial resection[Title/Abstract]) OR (midface resection[Title/Abstract])) AND (orbit*[Title/Abstract]). A focus on the articles edited from January of 1990 to January 2022 was made. A first reading allowed to select the relevant titles, a second reading the abstracts and a final reading the articles that could be included.

The eligibility criteria were assessed by two reviewers separately (S.D. and H.B.) at each stage of the study. In case of disagreement, a third reader (J.F.H.) was in charge of the final decision. The inclusion criteria were: primary reconstruction of Brown class III maxillary defects, malignant tumors of the maxilla, a minimum of 5 patients studied, assessment of functional, aesthetic and survival results. The exclusion criteria were: secondary reconstruction, Brown class III maxillectomy without orbit reconstruction, benign tumors or post-traumatic defects, lack of clinical evaluation. For one article with missing data regarding aesthetic and functional parameters, we contacted the authors without getting a response. Consequently, these data could not be integrated in the final analysis. The main evaluation criteria were the visual functional parameters after orbital reconstruction including diplopia, the presence of a postoperative ectropion and a decreased visual acuity (DVA). The secondary endpoints included aesthetic parameters (enophthalmos, malposition of the globe, facial asymmetry), carcinologic settings (recurrence and mortality rates), potential postoperative complications in accordance with the reconstruction technique, as well as revision surgeries. The other data collected were: information on the study design, demographic data (age, gender), follow-up data, radiation history as well as need for adjuvant radiotherapy after the reconstruction.

In order to make the results of the different studies more readable, we classified the reconstruction techniques into 4 groups:

- **Group A** included the reconstruction of the orbital framework by using a free bone flap.
- **The group B** combined the alloplastic implants including titanium mesh, three-dimensional (3D) implants and absorbable sheets.
- **Group C** was represented by the techniques of non-vascularized bone grafts.

Finally, **group D** included reconstruction techniques that used only soft tissue, most often a fascia lata strip associated with a free or pedicled non-bone flap.

The level of evidence was evaluated using the Oxford Centre for Evidence-Based Medicine (OCEBM) (33). The risk of bias was evaluated using the Methodological Quality Assessment Tool (MQAT) for case reports and case series (34). Every published article was assessed based on five aspects (patient selection, ascertainment, outcome, follow-up, and reporting). Two reviewing authors independently performed this critical appraisal of the included articles and scored the overall methodological quality (low, moderate or high), based on the questions deemed most critical in the specific clinical scenario. The quality assessment outcomes of these studies are listed in Appendix I.

RESULTS

A PRISMA flowchart (Fig. 1) of the systematic review describes the steps leading from the search strategy to the final included articles. Initial identification retrieved 616 articles (Pubmed: 438; Cochrane Library: 70; Google Scholar: 106), two studies were included by screening the reference lists of the remaining articles, and two duplicate studies were removed. Consequently, a total of 614 articles were screened independently by two authors (S.D. and H.B.). From this screening process, 44 articles progressed onto full text review and 20 studies were selected according to the inclusion and exclusion criteria. The remaining 24 articles were not retained for the following reasons: 4 articles were not in English or French-language, 5 articles included less than 5 patients, 3 articles included benign etiologies without separation of functional and aesthetic results of reconstruction between malignant and benign tumors, 12 studies were not included due to lack of evaluation of orbital parameters.

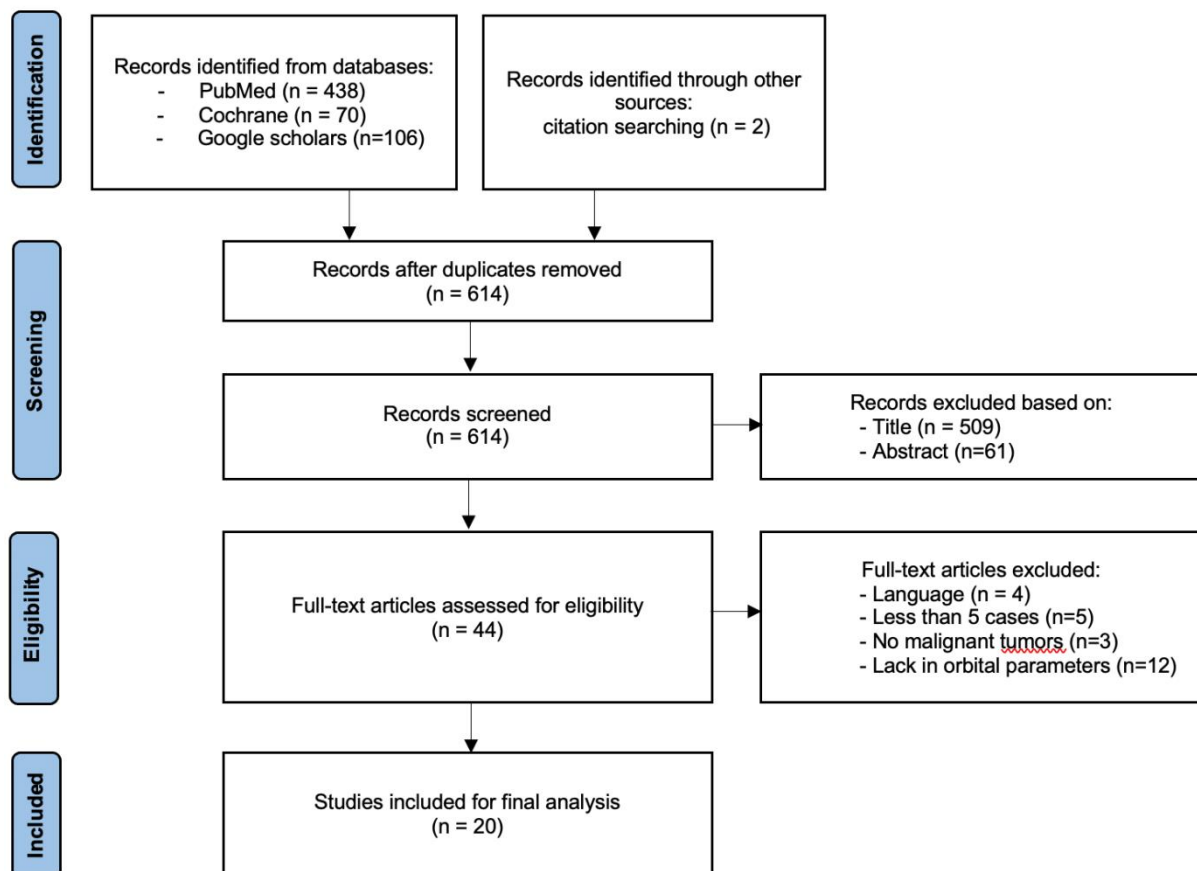


Figure 1. Flow chart representing the selection process of the articles.

Design of the studies and Patient characteristics

All 20 studies were retrospective and descriptive ones. The recruitment period of the different studies was on average 5.5 years [1-24]. Only one of the studies was comparative (31). Three studies described the use of two different reconstruction techniques, without comparison between the techniques (12,21,29). Bianchi *et al.* described the use of both bone grafts harvested from the iliac crest in five patients, and titanium mesh in one patient (12). Jung *et al.* reported the use of a tensor fascia-lata sling and of alloplastic materials (29). Finally, Kim *et al.* reported the use of titanium mesh in four cases, and vascularized calvaria bone grafts in two patients (21). The total enrollment for all studies combined represented a total of 232 patients, 33 in the group A, 85 in group B, 79 in group C, and 35 in group D. The mean age of the patients studied was: 51.8 ± 17.8 years for the group A, 54.7 ± 16.58 years for the group B, 58.6 ± 15.03 years for the group C and 53.3 ± 14.9 years for the group D.

The main histological diagnosis for maxillary tumors was squamous cell carcinoma (n=119), followed by cystic adenoid carcinoma (n=39), sarcoma (n=31), adenocarcinoma (n=10), mucous melanoma (n=4), myoepithelial carcinoma (n=3). Others histopathological diagnosis were: mucoepidermoid carcinoma, salivary duct carcinoma, nerve tumors, anaplastic carcinoma, and spindle cell carcinoma. All the demographic (mean age, gender, follow-up) and reconstruction techniques are reported in table 1.

Surgical procedures

In the group A, three different bone flaps were used for the orbit repair: the fibula free flap (FFF), the Free Serratus-Rib Flap, and the free tensor fascia lata-iliac crest osteomusculocutaneous flap. Iier *et al.* chose the iliac crest for its shape suitable for orbital reconstruction, with the crest forming the rim of the orbit and the concave surface of the iliac bone forming the floor (13). The tensor fascia lata was, for its part, used to fill the palatal defect and provided support for the bone flap itself attached to the adjacent bone with wires. Kraft *et al.* described a technique with harvesting of a free serratus-rib flap: the rib was shaped to recreate the orbital floor and could be the site of osteotomies to improve its conformation as long as the length of the pedicle allowed it while preserving the periosteum (35). The bone was then fixed using a reconstruction plate. The muscle component of the flap was then used to fill the defect in the maxillary

infrastructure. Sampathirao *et al.* described the use of different bone free flaps (FFF in 14 patients, TFL-IC in 9 patients, the radial artery forearm free flap with bone in 1 patient, and the free latissimus dorsi with rib in another case) for the reconstruction of both the orbital floor and the maxillary defect (31). All the associated procedures are presented in table 1.

Article	No. of patient	Recruitment period	Age, year (\pm SD)	Gender (M/F)	Follow-up, month (\pm SD)	Orbit reconstruction	Associated procedure
Group A		n=33					
Iyer <i>et al.</i> 2012	7	2007-2008	57.2 (\pm 9.3)	5/2	6	TFL - IC FF: n=7	-
Kraft <i>et al.</i> 2020	6	-	45.6 (\pm 23.9)	3/3	26.7 (\pm 13.6)	Serratus-Rib FF: n=6	-
Sampathirao <i>et al.</i> 2013	20*	2004-2009	-	-	-	FFF: n=14 TFL-IC: n=9 Bony RF: n=2 LD-Rib FF: n=1	-
Group B		n=85					
Zhang <i>et al.</i> 2015	6	2012-2014	56.1 (\pm 25.2)	4/2	24.1 (\pm 8.4)	3D Titanium Implant: n=6	ALT: n=4 FFF: n=1 RAFF: n=1
Jung <i>et al.</i> 2016	14	2003-2013	59.4 (\pm 12.6)	10/4	63.1 (\pm 27.5)	Titanium mesh: n=2 Absorbable sheet: n=12	0
Le Clerc <i>et al.</i> 2019	7	2013-2015	58.7 (\pm 11.5)	1/6	24 (\pm 18.4)	3D Titanium implant: n=7	-
Motiee-Langroudi <i>et al.</i> 2015	10	2009-2010	49 (\pm 16.6)	8/2	35,9 (\pm 5.6)	Titanium mesh: n=10	FL: n=10
Bianchi <i>et al.</i> 2010	1	1996-2008	78	1/0	90	Titanium mesh: n=1	ICFF: n=1
Trosman <i>et al.</i> 2017	12	2006-2015	55 (\pm 18.5)	3/9	48 (\pm 30.8)	Titanium mesh: n=12	LFFF: n=12
Shipchandler <i>et al.</i> 2012	7	2005-2010	50.85 (\pm 23.3)	2/5	30 (\pm 25.6)	Titanium mesh: n=7	LFFF: n=7
Zhu <i>et al.</i> 2020	12	2011-2018	55	6/6	-	Orbital plates: n=11 Titanium mesh: n=1	LFFF: n=11 ALT: n=1

Dediol et al. 2013	7	2009-2012	57 (± 13.6)	6/1	21 (± 14.4)	3D Titanium implant: n=7	ALT: n=6 LD: n=1
Kim et al. 2010	4	1993-2008	40 (± 7.11)	1/3	-	Titanium mesh	TPF: n=4
Hashikawa et al. 2006	5	1994-1999	64,8 (± 4.1)	3/2	72 (± 5.4)	Titanium mesh	RF: n=5
Group C	n=79						
Chen et al. 2006	9	1997-2005	54.3 (± 14.6)	-	10 (± 10.3)	Iliac: n=4 Calvaria: n=4 Mandible: n=1	RAFF: n=9
Cordeiro et al. 1998	14	1992-1997	51 (± 16.2)	8/6	21 (± 15.0)	Iliac: n=2 Calvaria: n=6 Rib: n=6	RAFF: n=12 TPF: n=2
Cenzi et al. 2006	5	1990-2005	50,6 (± 14.8)	3/2	60,2 (± 43.0)	Calvaria: n=5	TPF: n=5
Bianchi et al. 2006	22	1996-2003	62,33 (± 13.0)	13/9	32 (± 31.0)	Iliac: n = 22	RAFF: n=19 RAOM: n=3
Bianchi et al. 2010	5	1996-2006	68,28 (± 13.0)	3/2	90	Iliac: n=5	ICFF: n=5
Cordeiro et al. 2012	22	1992-2006	-	-	-	Iliac: n= 9 Calvaria: n=7 Rib: n=3 Mandible: n=1 Unknown: 2	RAFF: n=22
Kim et al. 2010	2	1993-2008	67 (± 28.3)	2/0	-	Calvaria: n=2	TPF: n=2
Group D	n=35						
Jung et al. 2016	5	2003-2013	49.4 (± 17.5)	2/3	30 (± 24.5)	FL	0
Joo et al. 2013	22	2004-2011	54.2 (± 14.6)	16/6	6	FL	ALT-FL flap: n=22
Sampathirao et al. 2013	8	2004-2009	-	-	-	Fascia of the RAFF: n=6 Prolene: n=2	RAFF: n=6 RF: n=2

Table 1. Demographic data of patients and surgical procedure used in the included studies. n, number of patients; M, male ; F, female; TFL-IC FF, tensor fascia lata –iliac crest free flap; Serratus-rib FF, serratus rib free flap; FFF, fibula free flap; Bony RF, bony radial artery forearm free flap; LD-Rib FF, Latissimus Dorsi with rib free flap; ALT, antero-lateral tight free flap; RAFF, rectus abdominis free flap; FL, fascia lata sling; ICFF, iliac crest free flap; LFFF, layered fibula free flap; LD, latissimus dorsi; RF, radial artery forearm free flap; TPF, temporoparietal fascia flap; RAOM, rectus abdominis osteomyocutaneous; ALT-FL, antero-lateral tight fascia-lata. *Despite 26 patients included by the authors, the functional and aesthetic results were reported in 20 patients that have been included in our analysis.

The reconstruction techniques with alloplastic implants (group B) were largely composed of titanium-based materials. These implants consisted in custom-made individualized titanium mesh manufactured from the preoperative CT-scan images, three-dimensional (3D) titanium implants, and titanium mesh shaped intraoperatively. We also included in this group patients reconstructed with absorbable sheets (ultra-high molecular weight polyethylene, L-Lactide polyglycolide and trim ethylene carbonate, betatricalcium phosphate, porous polyethylene, polyactide&polycolide, poly-l-lactide polymer). Custom made 3D implants were created with computer-assisted design and manufacturing. Implants were shaped by mirroring the contralateral orbit on pre-operative CT-scans. These implants were used in three studies to repair the orbital floor, the lower orbital rim, the malar prominence, and the anterior maxillary wall up to alveolus (22,23,28). In these studies, the alloplastic material for orbit reconstruction could be combined to soft tissue or bone free flaps for the reconstruction of the maxillary defect: anterior lateral thigh flap (n=10), rectus abdominis muscle flap (n=1), FFF (n=1), and latissimus dorsi (n=1) (22,28). Le Clerc *et al.* coupled the orbital reconstruction with a cover flap consisting in a pedicled fascia temporalis when the maxillary infrastructure was not involved, a latissimus dorsi free flap when the removal of the infrastructure did not extend above the canine and a subscapular chimeric free flap when the removal extended beyond the canine (23). Three studies used the layered-fibula technique consisting in 3 to 5 osteotomies to reconstruct the entire maxillary structure from the infraorbital rim to the alveolar ridge with a single flap (15,16,27). In these studies, the orbital floor was repaired with a titanium plate in most of cases (n=19) and with orbital plates in other cases (n=11), without further information on the type of material used. Zhu *et al.* described the use of an anterolateral thigh (ALT) flap associated to a titanium mesh for orbit reconstruction (27). In the other cases, the titanium mesh was covered either by a pedicled temporalis fascia flap (21), or by a fascia lata sling to avoid soft tissue entrapment in the titanium mesh (36). Others studies combined the titanium implant with an iliac-crest free flap or a soft tissue free flap such as forearm free flap (12,26). In contrast, Jung *et al.* described the use of absorbable sheets in twelve patients and titanium mesh in two others without providing any flap support to the orbit reconstruction (29). The authors covered the exposed maxillary mucosal defect with an harvested split thickness skin graft.

In group C (reconstruction with bone graft), bone donor sites included ribs, calvaria, iliac crest, and mandibular bones (7,12,17–21). The graft was often fragmented in two or three pieces, attached together with miniplates, to reshape the orbital floor and orbital walls, and then fixed to the adjacent bone with microplates. The tongue-in-groove technique was described by Chen *et al.* and consisted in fixing the bone graft by fitting it through a bone osteotomy made in the zygomatic bone (18). According to the authors, the advantage of this technique was to promote the integration of the graft by increasing its contact with the adjacent vascularized bone. The bone graft was associated to a soft tissue contribution, either by a free flap, in particular the free rectus abdominis flap (7,18,20), or by a pedicled fascia temporalis flap when the patients were not eligible for a free flap (19) or systematically (17). Bianchi *et al.* reported combined graft reconstruction with a rectus abdominis flap in 19 cases and in three cases with an osteomyocutaneous rectus abdominis flap (20). These soft tissues provided a support and a vascularization bed for the bone graft. The free rectus abdominis flap was harvested in two pallets, one to fill the palatal defect, the other to separate the nasal cavity from the orbit and limit infectious contamination of the graft (7,18). When a fascia temporalis was used, the reconstruction of the maxillary infrastructure was performed by obturator prosthesis (21).

In group D, patients received a fascia lata sling fixed with non-absorbable sutures and titanium screws to the nasal bone, lateral canthal tendon, and the remnant of the posterior orbital floor, in order to maintain adequate tension to support the orbital contents. Jung *et al.* described the use of a FL alone whereas Joo *et al.* harvested the ALT perforator flap to combine with FL string (29,30). These flaps were harvested with a skin paddle dedicated to recreate the palate. In the study from Sampathirao *et al.* rectus-abdominis free flaps were used in 6 patients; the muscle fascia was used as a sling to provide support for the orbital content. In this same study, two cases were reconstructed with a radialforearm flap associated with a prolene plate (31).

Functional outcomes (main criteria)

Fifteen patients (6.6 %) experienced a diplopia after resection and orbit reconstruction, 1/32 in group A, 4/85 in group B, 8/75 in group C and 2/35 in group D. Diplopia was defined as double vision in binocular vision and disabling for the patient. The symptom was mostly evaluated by clinical examination, no objective or automatic measurement

was reported. Some of this diplopia were related to the loss of extraocular muscle function and were not related to malposition of the globe (19,27). In the case of the diplopia was present postoperatively, if the sign resolved spontaneously after a few weeks or months, it was not qualified as a sequellar diplopia. All the data about diplopia are presented in table 2.

A postoperative ectropion was diagnosed in 78 patients (42.6 %). Ectropion was particularly observed in patients reconstructed with only soft tissue (group D, 17/27), followed by the reconstruction with alloplastic implants (group B, 34/79), bone graft (group C, 26/70) and finally bone free flaps (group A, 1/7). The incidence of ectropion varied widely between studies and according to the reconstruction techniques or the surgical approach used. In particular, at least half of the patients were affected by the complication after the use of a layered fibula technique associated with a titanium mesh, absorbable alloplastic implants, and bone grafts. The most frequently used surgical approach was the Weber-Ferguson approach which associates a paralatero nasal incision and a subpalpebral split line. Several secondary procedures were needed to correct the palpebral retraction: 16 in group B and 7 in group C. Ectropion was corrected with lateral or medial canthopexy, or by interposing a spreader graft. All the data about ectropion are presented in table 3.

Six cases of DVA were recorded after the surgical procedure, all studies combined. One in group B (29) was attributed to a local recurrence of adenoid cystic carcinoma with invasion of the extraocular muscles and extension to the intracranial area. The other in group B was due to a postoperative retinopathy (presumed ischemic) (15). Finally, 4 cases of decreased visual acuity were recorded in another study of which three cases were reconstructed with a free bone flap, and one case in the soft tissue reconstruction group, without specifying etiology and evolution (31)

Article	No. Of patient	Assessment method	Time of assessment	No. of diplopia
Group A				
	n=33			
Iyer <i>et al.</i> 2012	7	-	> 6 months	0
Kraft <i>et al.</i> 2020	6	-	-	0
Sampathirao <i>et al.</i> 2013	20	Clinical examination	> 6 months	1
Group B				
	n=85			
Zhang <i>et al.</i> 2015	6	Clinical examination	-	1
Jung <i>et al.</i> 2016	14	-	> 3 months	0
Le Clerc <i>et al.</i> 2019	7	Clinical examination	> 6 months	0
Motiee-Langroudi <i>et al.</i> 2015	10	-	-	0
Bianchi <i>et al.</i> 2010	1	-	-	0
Trosman <i>et al.</i> 2017	12	-	-	0
Shipchandler <i>et al.</i> 2012	7	-	-	0
Zhu <i>et al.</i> 2020	12	-	-	2
Dediol <i>et al.</i> 2013	7	Clinical examination	-	0
Kim <i>et al.</i> 2010	4	-	-	0
Hashikawa <i>et al.</i> 2006	5	Clinical examination	> 5 years	1
Group C				
	n=75			
Chen <i>et al.</i> 2006	9	Clinical examination	-	0
Cordeiro <i>et al.</i> 1998	14	Clinical examination	> 6 months	1
Cenzi <i>et al.</i> 2006	5	Clinical examination	> 6 months	0
Bianchi <i>et al.</i> 2006	22	-	-	3
Bianchi <i>et al.</i> 2010	5	-	-	0
Cordeiro <i>et al.</i> 2012	18	Clinical examination	-	4
Kim <i>et al.</i> 2010	2	-	-	0
Group D				
	n=35			
Jung <i>et al.</i> 2016	5	-	> 3 months	0
Joo <i>et al.</i> 2013	22	-	> 6 months	1
Sampathirao <i>et al.</i> 2013	8	Clinical examination	> 6 months	1

Table 2. Assessment of diplopia in literature review. n, number of patients.

Article	No. of patient	Incision approach	Time of assessment	Ectropion	Surgical revision
Group A					
	n=7				
Iyer et al. 2012	7	-	> 6 months	1	-
Group B					
	n=79				
Jung et al. 2016	14	-	> 3 months	9	-
Le Clerc et al. 2019	7	WF: n=7	> 6 months	3	1
Motiee-Langroudi et al. 2015	10	WF: n=10	-	3	2
Bianchi et al. 2010	1	-	-	1	-
Trosman et al. 2017	12	WF: n=7 ELR: n=5	-	6	6
Shipchandler et al. 2012	7	WF: n=2 NR: n=4	-	3	3
Zhu et al. 2020	12	-	-	8	4
Dediol et al. 2013	7	WF: n=7	-	0	-
Kim et al. 2010	4	-	-	0	0
Hashikawa et al. 2006	5	WF: n= 5	> 5 years	1	1
Group C					
	n=70				
Chen et al. 2006	9	WF: n=9	-	1	0
Cordeiro et al. 1998	14	-	> 6 months	10	6
Bianchi et al. 2006	22	-	> 6 months	5	-
Bianchi et al. 2010	5	-	-	1	1
Cordeiro et al. 2012	18	-	-	9	0
Kim et al. 2010	2	-	-	0	0
Group D					
	n=27				
Jung et al. 2016	5	-	> 3months	2	-
Joo et al. 2013	22	WF: n=22	> 3 months	15	-

Table 3. Assessment of ectropion, in literature review. n, number of patients; WF, Weber-Ferguson incision; ELR, extended lateral rhinotomy; NR, not reported.

Aesthetic outcomes (secondary criteria)

Measurement of aesthetic outcomes was most often performed on postoperative photographs and by clinical examination during follow-up visits (7,18,22,26,27,31,35). Four studies reported the use of at least two reviewers, often two head and neck surgeons, to assess the aesthetic parameters (7,16,18,19). In one study the patient was asked to comment on the aesthetic result of the reconstruction (22). In two studies the orbital volume and the position of the bony reliefs were compared between the reconstructed hemi-face and the normal side using 3D software on postoperative CT-scans performed at 6 months after the procedure (27,28).

Only one patient with clinical dystopia was identified in group A, none in group B. Dystopia was described in 5/79 cases of group C, in one of these cases it was a 1mm dystopia that did not require surgical correction.

In group A there we reported 3/33 patients presenting with enophthalmos, one of whom had a maxillectomy combined with a craniofacial approach with probably a wider resection (13,31). We did not have any information about the treatment of the enophthalmos. In group B, enophthalmos was observed in 8/68 patients (15,16,21,27). In group C 2/52 patients presented an enophthalmos (18). In the soft tissue reconstruction group, five cases of enophthalmos were described out of 35 patients analyzed (30,31). Enophthalmos was not disturbing for the patients, neither functionally nor aesthetically, and did not require a second procedure.

Finally, the evaluation of facial symmetry, most often performed by the surgeon, showed globally satisfactory results in each study. This element remained difficult to interpret because of its subjectivity with poorly reproducible criteria between studies. Except for Zhu *et al.* who evaluated postoperative facial symmetry by analyzing postoperative CT images and comparing the reconstructed hemiface to the contralateral hemiface based on different criteria (orbital rim and globe height and projection, lower lid height, volume of the orbit, midfacial width, and soft tissue contours) (27). The authors found a mean differences between the reconstructed side compared to the contralateral side of 3.5 mm for the orbital rim height, 3.4 mm for the orbital rim projection, 2.5 mm for the globe height, 2.8 mm for the globe projection, 3.2 mm for the lower lid height, 2.4 cm³ for the orbit volume, and 1.5mm for the midface width. For the patients followed-up more than 6 months, this difference tended to increase slightly. The authors analyzed the correlation between the orbit parameters and showed a significant correlation

between the projection of the infraorbital rim and the orbit volume, and a strong correlation between orbital rim height, globe height, and lower lid height.

All the aesthetic results are presented in table 4.

Oncologic, Post Operative and Aesthetic Outcomes (Secondary Criteria) :

The mean follow up of patients was 15.5 ± 14.6 months in group A, 42.6 ± 28.1 months in group B, 33.8 ± 29.6 months in group C, and 10.4 ± 24.5 months in group D.

History of radiotherapy was comparable in the different groups: 26 patients had adjuvant radiotherapy and no preoperative radiotherapy in group A out of 27 patients for whom this data was analyzed. In group B 55/85 patients had adjuvant radiotherapy and 16 had preoperative radiotherapy. In group C 43/57 patients had adjuvant radiotherapy and 9 in preoperative time. In group D 30/35 patients had adjuvant radiotherapy. Sampathirao *et al.* reported a history of prior surgical treatment or radiation therapy in twelve patients without giving more details about the protocol (31). Moreover, the authors stated that all cases of reconstruction were primary reconstructions.

Regarding the survival rates, there were 3 cases of death in group A (on 33 patients), including 1 cases of cancer recurrence leading to death. In group B 4 patients died of the disease and there were 7 cases of recurrence (data reported in 37 patients). For group C 19 patients died, two of which were from heart attack in the days following the surgical procedure, 3 patients of diseases not related to oral cancer without further details given, and the others died of their oncological disease (out of 50 patients evaluated). Data on mortality and recurrence were not given in the studies of group D.

The postoperative complications were collected when available. An early postoperative infection (<3 months) occurred at the donor site of the TFL-IC flap in one patient of the group A and was successfully managed conservatively (13). Five infections were reported on the operated site in group B (on 77 patients analyzed), one early and four late. The consequences of these infections on the reconstruction were not detailed, except for one patient reconstructed with an absorbable sheet. For this patient, the infection occurred 4 months after the surgical procedure, the material was exposed at 6 months and had to be removed. The floor of the orbit in this patient was subsequently reconstructed with a reverse temporalis muscle flap and a rib bone graft. Two cases of infection were reported in the group C, one of which was resolved with antibiotic

therapy alone, the second patient developed a late infection that required four new procedures to debride the infected area (18,19). In group D, one patient had a donor site infection, but no infection occurred at the reconstruction site (30). A material exposure occurred in 19 patients including 17 from group B and 2 from group C (16,17,29,36). Maziar Motiee-Langroudi *et al.* reported 4 cases of exposure with no need for material removal, the exposed area was covered by loco-regional flap (36). Trosman *et al.* reported two exposures (one at 6 months after surgery, the second at 11 months after a direct facial trauma), both cases required removal of the exposed osteosynthesis material and the use of loco-regional cover flap (16). In their series, Dediol *et al.* reported one case of exposure, the patient had a primary reconstruction with titanium mesh covered by a free latissimus dorsi flap (22). Jung *et al.* described 8 cases of material exposure, 3 within 3 months after surgery and 5 beyond 3 months after the procedure (29). Regarding patients assigned to group C there were only two cases of exposure, the exposed fixation device was removed in both cases, and only one of the two patients had to have further surgery for graft debridement (17). In all studies, regardless of the type of reconstruction, all cases of material exposure occurred in patients with a history of irradiation, except for one patient whose material was exposed after a trauma.

Article	No. of patient	No. of infection	No. of exposure	Time of exposure	Revision surgery	Assessment method of dystopia and enophthalmos	Time of assessment	Dystopia	Enophthalmos	Facial symmetry evaluation
Group A	n=33									
Iyer et al. 2012	7	1	0	-	-	Clinical examination	> 6 months	0	1	-
Kraft et al. 2020	6	0	0			Photograph examination	-	0	0	-
Sampathirao et al. 2013	20	-	-	-	-	Clinical and photograph examination	> 6 months	1	2	Good: 15 Fair: 5
Group B	n=85									
Zhang et al. 2015	6	-	0	-	-	Post operative CT scan analysis. Clinical examination	-	0	0	Good: 6
Jung et al. 2016	14	5	8	< 3 months: 3 > 3 months: 5	-	-	> 3 months	-	0	-
Le Clerc et al. 2019	7	0	-	-	-	-	> 6 months	-	-	Good: 1 Fair: 4 Poor: 2
Motiee-Langroudi et al. 2015	10	0	4	-	Locoregional flap No removal	-	-	0	-	-
Bianchi et al. 2010	1	0	0	-	-	-	-	0	0	-
Trosman et al. 2017	12	0	2	6 months 11 months	Fixation device removed & locoregional flap: 2	3 reviewers	-	0	1	Good: 10 Fair: 2
Shipchandler et al. 2012	7	0	1	-	-	-	-	0	1	Good: 7

Zhu et al. 2020	12	-	-	-	-	Clinical assessment and CT scans	-	-	5	n=6
Dediol et al. 2013	7	0	1	12 months	Flap repositioning	Clinical examination	-	0	0	0
Kim et al. 2010	4	0	1	-	Free tissue transfer	-	-	0	1	-
Hashikawa et al. 2006	5	0	0	-	-	Clinical examination	> 5 years	0	0	-
Group C	n=79									
Chen et al. 2006	9	1	-	-	-	2 reviewers, clinical and photographs examination	-	1	2	Good: 7 Fair: 1 NA: 1
Cordeiro et al. 1998	14	1	0	-	Fixation device removal: 2 Hyperbaric oxygen Graft debriedment: 1	2 reviewers, clinical and photographs examination	> 6 months	1	0	Good: 9 Fair: 4 Poor: 1
Cenzi et al. 2006	5	0	2	-	Fixation device removal: 2 Hyperbaric oxygen Graft debriedment: 1	-	> 6 months	0	0	Good: 5
Bianchi et al. 2006	22	0	0	-	-	-	> 9 months	2	-	Good: 14 Fair: 3 Poor: 5
Bianchi et al. 2010	5	0	0	-	-	-	-	0	-	-
Cordeiro et al. 2012	18	0	-	-	-	Clinical examination and photographs		1	0	Excellent: 12/17 Good: 4/17 Fair: 1/17

Kim et al. 2010	2	0	0	-	-	-	-	0	0	-
Group D	n=35									
Jung et al. 2016	5	0	-	-	-	-	> 3 months	-	0	-
Joo et al. 2013	22	1	-	-	-	Aesthetic scale (Funk et al.)	> 6 months	-	2	Good: 17 Fair: 5
Sampathirao et al. 2013	8	-	-	-	-	Clinical examination	> 6 months	1	3	Good: 4 Fair: 4

Table 4. Results of the secondary outcomes

DISCUSSION

Maxillary tumors are considered as rare cancers and are most of the time diagnosed at locally advanced stages. The reference treatment is based on maxillectomy surgery usually associated with adjuvant radiotherapy (3). Different types of maxillectomies can be performed depending on the size and the location of the tumor. In our analysis, we opted to refer to the Brown classification of maxillary defect because it is widely used, and also because it refers to both vertical and horizontal components of the maxillectomy allowing for a three-dimensional visualization of the area to be reconstructed (4,8). The Brown class I defect is limited to the alveolar bone without creating an oronasal communication, while the class II involves the hemipalate and the lower part of the maxillary sinus leading to the formation of a communication between the sinus and the oral cavity. Both class I and class II defects are commonly reconstructed with an obturator plate or with a free soft tissue flap. In the defects with medial extension, an additional vascularized bone tissue is nevertheless recommended to allow reconstruction of the alveolar arch, support of the soft tissues of the premaxillary region and to allow prosthetic or implant rehabilitation afterwards. Class III maxillectomy refers to the total removal of the maxillary bone and the lower part of the orbit; that is the one we focus on in this work because it requires an appropriate reconstruction of the orbit floor. It is proposed in tumors involving the periorbit without affecting the orbital content. In contrast, in Brown class IV, maxillectomy is extended to the whole orbit and therefore associated to an orbital exenteration.

Regarding the periorbital tumor invasion associated to sinusonasal tumors, the current attitude in regard to oncologic margins is organ preservation. Indeed, similar oncological results have been established between patients with eye sparing surgery and patients with orbital exenteration surgery on 5-year survival and local recurrence (37,38). Although excision surgery and maxillary reconstruction are well codified with several algorithms, there is in the current literature no recommendation regarding the orbit reconstruction (7,12,17–21). Through this systematic review we wished to compare the techniques used for the orbital floor reconstruction after total maxillectomy with respect to ocular functional and aesthetic parameters. We screened few studies related to this topic, which explains the small number of included patients; a

great heterogeneity was noted in the clinical parameters studied, and the clinical evaluation of the results remained mostly subjective. For each of the studies, it was not possible to dissociate the functional and aesthetic results, so it was impossible to perform a meta-analysis on these parameters. Also, it was observed a great heterogeneity in patients follow-up between the studies (ranged from 4 to 125 months). Radiotherapy is often proposed after class III maxillectomies and we know that it may lead to late complications such as exposure of material, infection, or resorption of the grafts. The quality of a reconstruction technique can therefore only be assessed on the basis of long-term patient follow-up, *i.e.* several years, which may moreover be inconsistent with the survival rates of patients with maxillary sinus cancer. We chose to express our results through the elaboration of four groups, considering the variety of the reconstruction techniques regarding the use of vascularized versus non-vascularized tissue, rigid versus soft-tissue reconstruction, and autologous versus alloplastic materials. It has already been shown that the absence of orbital frame reconstruction in maxillectomies was more likely to result in enophthalmos and dystopia, so we excluded from this study the patients without any orbital reconstruction (39). When the technique combined a free bone flap with a titanium mesh for orbital reconstruction (example of the layered fibula technique), it was classified in group B (reconstructions with alloplastic implants) considering that the titanium mesh provided most of the support for the intraorbital content. However, it is obvious that the contribution of a vascularized bone flap contributes greatly to the stability of the orbital framework and reduces the risk of secondary complications (15,16). In a study of 14 patients reconstructed using only a titanium mesh, Jung *et al.* reported a high rate (57.1%) of material exposure, mainly delayed after 6 months (29). Furthermore, as evidenced by Zhu *et al.*, it seems to exist a strong correlation between the height of the infraorbital rim and the height of the globe, suggesting the importance to reconstruct also the infraorbital rim (27). Surprisingly we observed few descriptions of the use of vascularized free bone-flap for the reconstruction of the orbital rim, although these flaps appears to be the method of choice for head and neck reconstruction (4). One of the explanations lies in the operative time required for large maxillectomy and reconstruction, and the need for a double team to perform the excision surgery and the flap harvesting (40). Joo *et al.* stated that even if bony reconstruction seems functionally and esthetically ideal, it generates significant systemic stress that can have serious

repercussions on the long-term quality of life of patients (30). The same authors argued that the priority was to ensure the filling of the defect and to repair as best as possible to allow the rapid start of complementary treatments. In a retrospective analysis of 21,548 patients with head and neck cancer, Wang *et al.* showed that the mean operative time in the free flap failures was significantly higher than in the free flap successes (41). In maxillary resection, a free bone or soft-tissue flap is usually preferred for the reconstruction of the lower framework allowing for the restoration of some vital functions (*i.e.* speech and feeding) rather than the orbit reconstruction which could be provided with others materials.

Our systematic review revealed that postoperative ectropion was the most frequently observed complication in 42.6 % of patients regardless of the method of reconstruction. In a retrospective study of 24 patients treated with a maxillectomy and with objective assessment of ophthalmologic changes, Sweeney *et al.* reported a 50% rate of ectropion (9). Although ectropion can have an aesthetic impact, it has mostly functional consequences with regard to the risk of exposure keratitis, decrease in visual acuity, epiphora, and chronic conjunctivitis. One of the explanations for the incidence of ectropion is the frequent use of the Weber-Ferguson incision with subciliary extension in maxillary tumor extirpation (9). Some authors argue for the use of the transconjunctival approach as an alternative to the subciliary incision in total maxillectomies (42). In our study, ectropion represented the main cause of repeated surgeries. Furthermore, the irradiation of the orbital-facial region is likely associated to tissue retraction, muscle atrophy and skin dystrophy, which make reconstruction of ectropion more challenging than in non-irradiated patients. Reconstruction of ectropion often require the combination of canthotomy, canthopexy and a spreader graft such as total skin graft harvested from the contralateral upper eyelid (43). An additional lipofilling is relevant in this context as it brings adipose stem cells to improve trophicity and softness of the lower eyelid, but there is still a lack of hindsight concerning their use in cervicofacial reconstruction (44). Our study reported a lower rate of diplopia, mostly associated to non-vascularized bone graft (8/75). A possible reason lies in the spontaneous resorption of bone, enhanced by radiotherapy. In the context of total maxillectomies for the treatment of sinusal cancer, diplopia can have several etiologies. It may be related to the lack of rigid support resulting in ptosis of the orbital content with secondary diplopia. It may also be related to damage of the inferior rectus

muscle during oncological resection or by tumor extension. Involvement of the ocular musculature is usually an indication for orbital exenteration, and this situation was not included in our study (37). None of the studies included in the analysis detailed the causes of diplopia. Furthermore, we observed a lack in the measurement of this diplopia with absence of objective method of assessment. The common method of the “finger test” fails to reveal 65% of oculomotor disorders in a post-traumatic context (45). We therefore recommend a full orthoptic preoperative and postoperative examination for each patient in the context of oncologic orbital reconstructions. Decreased visual acuity was a rare event often related to external causes apart from the reconstructive surgery.

Regarding our secondary outcomes, dystopia and enophthalmos was more frequently observed in reconstructions using flexible material such as fascia lata, although the small number of patients makes interpretation difficult. These data are in line with numerous authors who recommend rigid reconstruction to ensure support of the orbital contents (31,39). Sampitharao *et al.* compared rigid bone reconstruction and soft tissue repair of the orbital floor with free tissue transfer and found a significant association of eyeball malposition with the soft tissue reconstruction, but no difference was observed in terms of functional outcome, eye movement, and visual acuity (31). Enophthalmos can have multiple causes as it can be related to a change in the volume of the orbital frame but also to a loss of intra orbital fat and muscle volume secondary to radiotherapy. Some authors recommend a slight overcorrection of the orbital floor reconstruction in a non-anatomical position to anticipate the volume loss related to radiotherapy (16,20). The measurement of enophthalmos should be done clinically with an exophthalmometer or radiologically by calculating the oculo-orbital index in the neuro-ocular plane (46,47). In our systematic review only two studies referred to postoperative CT scans for this measurement (13,27).

As for alloplastic implants, multiple materials have been described for orbital reconstructions in non-oncological context. Bourry *et al.* have showed good functional and aesthetic results associated to a combination of porous polyethylene and titanium for the reconstruction of large defects of the orbital floor (48). Such materials also appear as good solution for orbit reconstruction in the carcinologic resection of orbital floor, as evidenced by our literature review. Many authors have identified radiotherapy as a risk factor for failure in head and neck reconstructions; it causes tissue sclerosis,

shrinkage and delays in healing (25,49). Our review showed that almost all cases of material exposure (19 of 232 patients) occurred in patients with a history of radiotherapy. However, in a retrospective study of 66 patients who underwent a maxillectomy, Sun *et al.* failed to demonstrate a statistical correlation between adjuvant radiotherapy and material exposure (25). Our study also suggested a relative rarity of postoperative infection (9 patients). The challenge of the maxillary reconstruction is to ensure a complete closure between the nasal cavity, the mouth, and the orbit to avoid any upward contamination of the orbital content by sinus germs. For this purpose, Moya-Plana *et al.* proposed to harvest a bone free flap (latissimus dorsi-scapular flap) with a double skin paddle positioned perpendicular to each other, to close both the nasal cavity and the maxillary defect (10). There are many publications related to the patients' quality of life after maxillectomy and maxillary reconstruction has been evaluated in numerous studies, particularly regarding the restoration of oral functions (speech, chewing and swallowing) (50). In this systematic review, only Le Clerc *et al.* have administered a questionnaire, the EORTC QLQ-C30, showing a good quality of life in all the reconstructed patients except one with an average >60/100 (23).

The findings of our systematic review in relation to our overriding aim concluded the existing literature to be of poor quality overall. Nevertheless, the question of orbital reconstruction in Brown Class III total maxillectomies had never been investigated before in such many patients. The strengths of the methodology employed included a thorough and comprehensive search of the existing literature coupled with universally accepted assessment tools for evaluating full texts. However, our review suffers from some limitations, the first lies in the inclusion of case series, the quality of which may be debatable. This type of study increases the risk of bias, and its level of evidence is usually considered very low (51). For this reason, case series are generally excluded from systematic reviews. However, in the field of surgery, they have made a significant contribution to the medical literature and provide valuable information on the benefits and risks of certain procedures when randomized controlled trials are not possible (52), which is the case here. Indeed, this work may offer more evidence for decision-making. Secondly all the studies except were single arm without comparison of two techniques for the reconstruction of the orbital floor. Thirdly, substantial heterogeneity existed in the methods used regarding the assessment of the functional and aesthetic parameters, almost with subjective clinical methods of measurements.

CONCLUSION

Notwithstanding the quality and limitations of the literature, qualitative evaluation of existent techniques used for the orbital floor reconstruction after maxillectomy suggest that bone free flaps and alloplastic implants associated to free flaps represent good options regarding the postoperative ophthalmologic functional and aesthetic parameters. Currently there is a lack of confidence on the available literature on the clinical benefits of using an alloplastic material alone, autologous bone graft or soft tissue reconstruction regarding the risk of postoperative complication including material exposure and enophthalmos. Furthermore, the results of this systematic review have unearthed the need for high quality prospective RCTs to assess the best technique for orbital floor reconstruction in Brown Class III maxillectomies.

APPENDIX I

Reference (first author, year)	OCEBM	MQAT					Overall
		Selection	Ascertainment	Outcome	Follow-up	Reporting	
Bianchi, 2006	4	Moderate	Low	Low	High	High	Moderate
Bianchi, 2010	4	Moderate	Low	Low	High	High	Moderate
Cenzi, 2006	4	Moderate	Low	Low	High	High	Moderate
Chen, 2008	4	Moderate	Moderate	Low	Moderate	High	Low
Cordeiro, 1998	4	Moderate	Moderate	Low	High	High	High
Cordeiro, 2012	4	High	Moderate	Low	Moderate	High	High
Dediol, 2013	4	Moderate	Low	Low	Moderate	High	Low
Hashikawa, 2006	4	Moderate	Low	Low	High	High	Moderate
Iyer, 2012	4	Low	High	Low	High	High	High
Joo, 2013	4	Moderate	Moderate	Low	Low	High	Low
Jung, 2016	4	Moderate	Low	Low	High	High	Moderate
Kim, 2010	4	High	Low	Low	High	High	High
Kraft, 2020	4	High	Moderate	Low	High	High	High
Le Clerc, 2020	4	High	Low	Low	High	High	High
Motiee Langroudi, 2015	4	Moderate	Low	Low	High	High	Moderate
Sampathiero, 2013	4	Moderate	Moderate	Low	High	High	High
Shipchandler, 2012	4	Moderate	Low	Low	High	High	Moderate
Trosman, 2017	4	High	Moderate	Low	High	High	High
Zhang, 2015	4	Moderate	High	Low	High	High	High
Zhu, 2020	4	Moderate	High	Low	High	High	High

Table 1: Quality assessment of included studies

BIBLIOGRAPHY

1. Dhanani R, Faisal M, Shahid H, Malik KI, Jamshed A, Hussain R. Outcomes of Management of Sinonasal Malignancies at a Dedicated Cancer Institution: A Retrospective Study. *Ann Maxillofac Surg.* juin 2021;11(1):115-20.
2. Maghami E, Kraus DH. Cancer of the nasal cavity and paranasal sinuses. *Expert Rev Anticancer Ther.* juin 2004;4(3):411-24.
3. Ashraf M, Biswas J, Dam A, Bhowmick A, Jha null, Sing V, et al. Results of Treatment of Squamous Cell Carcinoma of Maxillary Sinus: A 26-Year Experience. *World J Oncol.* févr 2010;1(1):28-34.
4. Brown JS, Shaw RJ. Reconstruction of the maxilla and midface: introducing a new classification. *Lancet Oncol.* oct 2010;11(10):1001-8.
5. Santamaria E, de la Concha E. Lessons Learned from Delayed Versus Immediate Microsurgical Reconstruction of Complex Maxillectomy and Midfacial Defects: Experience in a Tertiary Center in Mexico. *Clin Plast Surg.* oct 2016;43(4):719-27.
6. Hanasono MM, Silva AK, Yu P, Skoracki RJ. A comprehensive algorithm for oncologic maxillary reconstruction. *Plast Reconstr Surg.* janv 2013;131(1):47-60.
7. Cordeiro PG, Chen CM. A 15-year review of midface reconstruction after total and subtotal maxillectomy: part I. Algorithm and outcomes. *Plast Reconstr Surg.* janv 2012;129(1):124-36.
8. Brown JS, Rogers SN, McNally DN, Boyle M. A modified classification for the maxillectomy defect. *Head Neck.* janv 2000;22(1):17-26.
9. Sweeney AR, Walker B, Bhrany AD, Chang SH, Jian-Amadi A. Ophthalmic Changes Following Maxillectomy With or Without Postoperative Radiation Therapy. *J Craniofac Surg.* juill 2019;30(5):1448-51.
10. Moya-Plana A, Veyrat M, Honart JF, de Fremicourt K, Alkhashnam H, Sarfati B, et al. Reconstruction of maxillectomy and midfacial defects using latissimus dorsi-scapular free flaps in a comprehensive cancer center. *Oral Oncol.* déc 2019;99:104468.
11. Brown JS. Deep circumflex iliac artery free flap with internal oblique muscle as a new method of immediate reconstruction of maxillectomy defect. *Head Neck.* oct 1996;18(5):412-21.
12. Bianchi B, Ferri A, Ferrari S, Copelli C, Boni P, Sesenna E. Iliac crest free flap for maxillary reconstruction. *J Oral Maxillofac Surg Off J Am Assoc Oral Maxillofac Surg.* nov 2010;68(11):2706-13.
13. Iyer S, Chatni S, Kuriakose MA. Free tensor fascia lata-iliac crest osteomusculocutaneous flap for reconstruction of combined maxillectomy and orbital floor defect. *Ann Plast Surg.* janv 2012;68(1):52-7.
14. Wilkman T, Husso A, Lassus P. Clinical Comparison of Scapular, Fibular, and Iliac Crest Osseal Free Flaps in Maxillofacial Reconstructions. *Scand J Surg SJS Off Organ Finn Surg Soc Scand Surg Soc.* mars 2019;108(1):76-82.
15. Shipchandler TZ, Waters HH, Knott PD, Fritz MA. Orbitomaxillary reconstruction using the layered fibula osteocutaneous flap. *Arch Facial Plast Surg.* avr 2012;14(2):110-5.
16. Trosman SJ, Haffey TM, Couto RA, Fritz MA. Large orbital defect reconstruction in the setting of globe-sparing maxillectomy: The titanium hammock and layered fibula technique. *Microsurgery.* mai 2018;38(4):354-61.
17. Cenzi R, Carinci F. Calvarial bone grafts and temporalis muscle flap for midfacial reconstruction after maxillary tumor resection: a long-term retrospective evaluation of 17 patients. *J Craniofac Surg.* nov 2006;17(6):1092-104.

18. Chen CM, Cordeiro PG. The tongue-in-groove technique for orbital floor reconstruction after maxillectomy. *Plast Reconstr Surg.* janv 2008;121(1):225-32.
19. Cordeiro PG, Santamaria E, Kraus DH, Strong EW, Shah JP. Reconstruction of total maxillectomy defects with preservation of the orbital contents. *Plast Reconstr Surg.* nov 1998;102(6):1874-84; discussion 1885-1887.
20. Bianchi B, Bertolini F, Ferrari S, Sesenna E. Maxillary reconstruction using rectus abdominis free flap and bone grafts. *Br J Oral Maxillofac Surg.* déc 2006;44(6):526-30.
21. Kim JYS, Buck DW, Johnson SA, Butler CE. The temporoparietal fascial flap is an alternative to free flaps for orbitomaxillary reconstruction. *Plast Reconstr Surg.* sept 2010;126(3):880-8.
22. Dediol E, Uglešić V, Zubčić V, Knežević P. Brown class III maxillectomy defects reconstruction with prefabricated titanium mesh and soft tissue free flap. *Ann Plast Surg.* juill 2013;71(1):63-7.
23. Le Clerc N, Baudouin R, Carlevan M, Khoueir N, Verillaud B, Herman P. 3D titanium implant for orbital reconstruction after maxillectomy. *J Plast Reconstr Aesthetic Surg JPRAS.* avr 2020;73(4):732-9.
24. Liu BY, Cao G, Dong Z, Chen W, Xu JK, Guo T. The application of 3D-printed titanium mesh in maxillary tumor patients undergoing total maxillectomy. *J Mater Sci Mater Med.* 14 nov 2019;30(11):125.
25. Sun Q, Soh HY, Zhang WB, Yu Y, Wang Y, Mao C, et al. Long-term Effect of Individualized Titanium Mesh in Orbital Floor Reconstruction After Maxillectomy. *The Laryngoscope.* oct 2021;131(10):2231-7.
26. Hashikawa K, Tahara S, Ishida H, Yokoo S, Sanno T, Terashi H, et al. Simple reconstruction with titanium mesh and radial forearm flap after globe-sparing total maxillectomy: a 5-year follow-up study. *Plast Reconstr Surg.* mars 2006;117(3):963-7.
27. Zhu B, Han M, Heaton C, Park AM, Seth R, Knott PD. Assessing Free Flap Reconstruction Accuracy of the Midface and Orbit Using Computer-Aided Modeling Software. *Facial Plast Surg Aesthetic Med.* avr 2020;22(2):93-9.
28. Zhang WB, Mao C, Liu XJ, Guo CB, Yu GY, Peng X. Outcomes of Orbital Floor Reconstruction After Extensive Maxillectomy Using the Computer-Assisted Fabricated Individual Titanium Mesh Technique. *J Oral Maxillofac Surg Off J Am Assoc Oral Maxillofac Surg.* oct 2015;73(10):2065.e1-15.
29. Jung BK, Yun IS, Lee WJ, Lew DH, Choi EC, Lee DW. Orbital floor reconstruction using a tensor fascia lata sling after total maxillectomy. *J Cranio-Maxillo-fac Surg Off Publ Eur Assoc Cranio-Maxillo-fac Surg.* mai 2016;44(5):648-53.
30. Joo YH, Cho KJ, Park JO, Kim MS. Usefulness of the anterolateral thigh flap with vascularized fascia lata for reconstruction of orbital floor and nasal surface after total maxillectomy. *The Laryngoscope.* sept 2013;123(9):2125-30.
31. Sampathirao LMCSR, Thankappan K, Duraisamy S, Hedne N, Sharma M, Mathew J, et al. Orbital floor reconstruction with free flaps after maxillectomy. *Cranio-maxillofacial Trauma Reconstr.* juin 2013;6(2):99-106.
32. Hutton B, Salanti G, Caldwell DM, Chaimani A, Schmid CH, Cameron C, et al. The PRISMA extension statement for reporting of systematic reviews incorporating network meta-analyses of health care interventions: checklist and explanations. *Ann Intern Med.* 2 juin 2015;162(11):777-84.
33. OCEBM Levels of Evidence Working Group — Centre for Evidence-Based Medicine (CEBM), University of Oxford [Internet]. 2011. Disponible sur: <https://www.cebm.ox.ac.uk/resources/levels-of-evidence/ocebml-levels-of-evidence>

34. Mh M, S S, S H, F B. Methodological quality and synthesis of case series and case reports. *BMJ Evid-Based Med* [Internet]. avr 2018 [cité 17 oct 2022];23(2). Disponible sur: <https://pubmed.ncbi.nlm.nih.gov/29420178/>
35. Kraft CT, Hanasono MM, Skoracki RJ. The Free Serratus-Rib Flap for Orbital Floor Reconstruction After Oncologic Resection. *Ann Plast Surg*. avr 2020;84(4):409-12.
36. Motiee-Langroudi M, Harirchi I, Amali A, Jafari M. Reconstruction of Midface and Orbital Wall Defects After Maxillectomy and Orbital Content Preservation With Titanium Mesh and Fascia Lata: 3-Year Follow-Up. *J Oral Maxillofac Surg Off J Am Assoc Oral Maxillofac Surg*. déc 2015;73(12):2447.e1-5.
37. Suárez C, Ferlito A, Lund VJ, Silver CE, Fagan JJ, Rodrigo JP, et al. Management of the orbit in malignant sinonasal tumors. *Head Neck*. févr 2008;30(2):242-50.
38. Imola MJ, Schramm VL. Orbital preservation in surgical management of sinonasal malignancy. *The Laryngoscope*. août 2002;112(8 Pt 1):1357-65.
39. Stern SJ, Goepfert H, Clayman G, Byers R, Wolf P. Orbital preservation in maxillectomy. *Otolaryngol--Head Neck Surg Off J Am Acad Otolaryngol-Head Neck Surg*. juill 1993;109(1):111-5.
40. Lindeborg MM, Puram SV, Sethi R, Abt N, Emerick KS, Lin D, et al. Predictive factors for prolonged operative time in head and neck patients undergoing free flap reconstruction. *Am J Otolaryngol*. avr 2020;41(2):102392.
41. Wang KY, Lin YS, Chen LW, Yang KC, Huang WC, Liu WC. Risk of Free Flap Failure in Head and Neck Reconstruction: Analysis of 21,548 Cases From A Nationwide Database. *Ann Plast Surg*. janv 2020;84(1S Suppl 1):S3-6.
42. Goyal A, Tyagi I, Jain S, Syal R, Singh AP, Kapila R. Transconjunctival incision for total maxillectomy--an alternative for subciliary incision. *Br J Oral Maxillofac Surg*. sept 2011;49(6):442-6.
43. Tarallo M, Rizzo MI, Monarca C, Fanelli B, Parisi P, Scuderi N. Optimal care for eyelid contraction after radiotherapy: case report and literature review. *J Oral Maxillofac Surg Off J Am Assoc Oral Maxillofac Surg*. oct 2012;70(10):2459-65.
44. Hammond SE, Samuels S, Thaller S. Filling in the Details: A Review of Lipofilling of Radiated Tissues in the Head and Neck. *J Craniofac Surg*. juin 2019;30(3):667-71.
45. Timkovic J, Stransky J, Handlos P, Janosek J, Tomaskova H, Stembirek J. Detecting Binocular Diplopia in Orbital Floor Blowout Fractures: Superiority of the Orthoptic Approach. *Med Kaunas Lith*. 19 sept 2021;57(9):989.
46. Bertin H, Huon JF, Guillot P, Longis J, Corre P, Bordereau S, et al. Fibrous dysplasia of the orbital region: Series of 12 cases and review of the literature. *J Fr Ophtalmol*. juin 2020;43(6):467-76.
47. Cabanis EA, Iba-Zizen MT, Coin JL, Guillaumat L, Pineau H. [Visual pathways, a « new » plane of orientation of the head (neuro-ocular plane)]. *Bull Soc Ophtalmol Fr*. mai 1981;81(4-5):433-9.
48. Bourry M, Hardouin JB, Fauvel F, Corre P, Lebranchu P, Bertin H. Clinical evaluation of the efficacy of materials used for primary reconstruction of orbital floor defects: Meta-analysis. *Head Neck*. févr 2021;43(2):679-90.
49. Mücke T, Rau A, Weitz J, Ljubic A, Rohleder N, Wolff KD, et al. Influence of irradiation and oncologic surgery on head and neck microsurgical reconstructions. *Oral Oncol*. avr 2012;48(4):367-71.
50. Murphy J, Isaiah A, Wolf JS, Lubek JE. Quality of life factors and survival after total or extended maxillectomy for sinonasal malignancies. *J Oral Maxillofac Surg Off J Am Assoc Oral Maxillofac Surg*. avr 2015;73(4):759-63.

51. Murad MH. Clinical Practice Guidelines: A Primer on Development and Dissemination. *Mayo Clin Proc.* mars 2017;92(3):423-33.
52. Vandembroucke JP. In defense of case reports and case series. *Ann Intern Med.* 20 févr 2001;134(4):330-4.

Vu, le Président du Jury,

(tampon et signature)



Professeur Pierre CORRE

Vu, le Directeur de Thèse,

(tampon et signature)



Docteur Helios BERTIN

Vu, le Doyen de la Faculté,



Professeur Pascale JOLLIET

RÉSUMÉ

Contexte : Cette revue systématique visait à évaluer les techniques chirurgicales utilisées en reconstruction du plancher orbitaire dans les maxillectomies Brown III dans les cancers maxillaires, en étudiant les paramètres fonctionnels et esthétiques oculaires.

Matériel et méthodes : Une recherche électronique a été menée sur PubMed, Cochrane Library et Google Scholar de janvier 1990 à janvier 2022. Quarante-quatre articles ont été inclus après sélection des études, 20 ont été retenus après évaluation de l'éligibilité. L'évaluation du risque de biais a été réalisée selon le MQAT pour les cas cliniques et les séries de cas. Les études ont été classées en quatre groupes selon la technique chirurgicale : le groupe A concernait les lambeaux libres osseux, le groupe B comprenait les implants alloplastiques, le groupe C les greffes osseuses et le groupe D les reconstructions par tissus mous.

Résultats : Les études incluses étaient rétrospectives et descriptives, et ont porté sur un total de 232 patients. L'ectropion et la diplopie ont été évalués cliniquement et concernaient respectivement 42,6% et 6,6% des patients. La reconstruction des tissus mous était plus susceptible de provoquer un ectropion (17/27), suivie par les techniques de reconstruction du groupe B (34/79), du groupe C (26/70) et du groupe A (1/7). Six cas de baisse de l'acuité visuelle ont été enregistrés toutes études confondues. En ce qui concerne les paramètres esthétiques, une énophtalmie postopératoire a été identifiée chez 18 patients (9,6%), principalement dans le groupe D (5/35) suivi des groupes B (8/68), A (3/33) et C (2/52) ; tandis que la dystopie orbitaire était décrite chez 6 patients, principalement dans le groupe C (5/79). Une exposition de matériel est survenue chez 19 patients dont 17 dans le groupe B. La qualité des articles était élevée dans 10 études, modérée dans 7 études et faible dans 3 études.

Conclusion : L'évaluation qualitative des techniques existantes utilisées pour la reconstruction du plancher orbitaire après maxillectomie suggère que les lambeaux libres osseux et les implants alloplastiques représentent de bonnes options thérapeutiques.

MOTS CLÉS

Cancer maxillaire ; chirurgie de l'orbite ; reconstruction ; revue systématique