



HAL
open science

Usefulness of Coronary Artery Interpretation on TAVI-CT to Avert Invasive Coronary Angiography

Adrien Lecomte

► **To cite this version:**

Adrien Lecomte. Usefulness of Coronary Artery Interpretation on TAVI-CT to Avert Invasive Coronary Angiography. Human health and pathology. 2024. dumas-04751870

HAL Id: dumas-04751870

<https://dumas.ccsd.cnrs.fr/dumas-04751870v1>

Submitted on 24 Oct 2024

HAL is a multi-disciplinary open access archive for the deposit and dissemination of scientific research documents, whether they are published or not. The documents may come from teaching and research institutions in France or abroad, or from public or private research centers.

L'archive ouverte pluridisciplinaire **HAL**, est destinée au dépôt et à la diffusion de documents scientifiques de niveau recherche, publiés ou non, émanant des établissements d'enseignement et de recherche français ou étrangers, des laboratoires publics ou privés.

IMPORTANT : OBLIGATIONS DE LA PERSONNE CONSULTANT CE DOCUMENT

Conformément au *Code de la propriété intellectuelle*, nous rappelons que le document est destiné à un **usage strictement personnel**. Les "analyses et les courtes citations justifiées par le caractère critique, polémique, pédagogique, scientifique ou d'information" sont autorisées sous réserve de mentionner les noms de l'auteur et de la source (article L. 122-4 du *Code de la propriété intellectuelle*). Toute autre représentation ou reproduction intégrale ou partielle, faite sans le consentement de l'auteur ou de ses ayants droit, est illicite.

De ce fait, nous vous rappelons notamment que, **sauf accord explicite** de l'auteur de la thèse ou du mémoire, **vous n'êtes pas autorisé** à rediffuser ce document sous quelque forme que ce soit (impression papier, transfert par voie électronique, ou autre). Tout contrevenant s'expose aux peines prévues par la loi.

NANTES UNIVERSITÉ

FACULTÉ DE MÉDECINE

Année : 2024

THÈSE

pour le

DIPLÔME D'ÉTAT DE DOCTEUR EN MÉDECINE

RADIOLOGIE ET IMAGERIE MEDICALE

par

Adrien LECOMTE

Né le 17 Octobre 1996 à Rennes

Présentée et soutenue publiquement le 27 juin 2024

***Usefulness of Coronary Artery Interpretation on TAVI-CT to Avert
Invasive Coronary Angiography***

Président du jury : Professeur Jean-Michel SERFATY

Directeur de thèse : Professeur Jean-Michel SERFATY

Membres du jury : Docteur Renan LIBERGE, Docteur Thibaut MANIGOLD,
Docteur Lara MARTEAU

REMERCIEMENTS

A Monsieur le Professeur Jean-Michel SERFATY, président du jury et directeur de thèse, pour votre soutien lors de ce travail et votre écoute tout le long de l'internat.

Au Docteur Renan LIBERGE, membre du jury, d'avoir accepté mon invitation, afin de vous remercier de votre bienveillance et de votre pédagogie lors de ces années d'internat.

Aux Docteurs Thibaut MANIGOLD et Lara MARTEAU, membres du jury, de me faire l'honneur de juger mon travail grâce votre expertise dans ce domaine.

A ma famille (Maman, Papa, Chloé et Clara), mes grand parents, mes oncles et tantes, mes cousin.es pour votre immense soutien durant toutes ces années passées.

Au groupe "CCN" (Appoline, Célia, Clara, Clémence, Marine, Margot, Solenn) pour tous ces beaux moments passés avec vous et à venir ; au groupe "Peau Neuve" pour tous ces week-ends retrouvailles ; à Camille et Marguerite, pour toutes ces soirées à Rennes ; à Gabrielle, pour cette belle colocation parisienne.

A mes amis nantais, Coline, Lucille et Marion pour tous ces moments partagés ; à Charlotte et Thomas pour tous ces dîners dominicaux ; à Hadrien, pour toutes ces soirées entre Nantes et Paris ; à mes colocs de la Roche-Sur-Yon (Charlotte, Emeline et Louise) et aux autres yonnais (notamment Manon, Mareva, Philo, Tom) pour tous ces souvenirs partagés.

A mes co-internes nantais, pour tout ce temps partagé avec vous à apprendre, travailler et rigoler bien sûr (en particulier, Aude, Johanna, Louis, Mathieu, Maureen, Nathanaël, Théo et Vincent) ; à tous les chefs de radiologie du CHU de Nantes, du CHD vendée et de l'ICO, pour votre gentillesse et votre transmission du savoir ; à toutes les équipes paramédicales rencontrées (manipulateurs radio, aide-soignant.e.s et secrétaires).

A mes co-internes parisiens, le temps d'un semestre (notamment, Alexandra, Antonio, Denis et Pénélope) ; aux chefs de Cochin (en particulier, Professeur Marie-Pierre REVEL) pour votre accueil et votre disponibilité.

A tous les autres, pour ces belles rencontres durant ces années de médecine.

TABLES DES MATIÈRES

REMERCIEMENTS	2
TABLES DES MATIÈRES	3
ABBREVIATIONS LIST	4
TABLE AND FIGURES	5
MAIN POINT	6
I. INTRODUCTION	7
II. METHODS	8
A. Study population	8
B. Image data acquisition and post-processing	8
C. Image Quality assessment	9
D. Interpretation of CA on TAVI-CT	11
E. Interpretation of CA on coronary angiography	11
III. STATISTICAL ANALYSIS	12
IV. RESULTS	13
A. Study population	13
B. Image quality	15
C. Interpretation of CA	16
V. DISCUSSION	17
VI. CONCLUSION	20
BIBLIOGRAPHY	21
ABSTRACT	27

ABBREVIATIONS LIST

CA, Coronary artery

CAD, Coronary artery disease

CAS, Coronary artery stenosis

CI, Confidence interval

DBT, Died before treatment

NPV, Negative predictive value

PPV, Positive predictive value

SD, Standard deviation

TAVI, Transcatheter aortic valve implantation

TAVI-CT, Pre transcatheter aortic valve implantation CT

TABLE AND FIGURES

Table 1 - Baseline characteristics of 206 patients included in the study.

CrCl indicates creatinine clearance.

Qualitative variables are expressed as raw numbers; numbers in parentheses are proportions followed by percentages.

Quantitative variables are expressed as means § standard deviations; numbers in brackets are ranges.

Figure 1 - Flow chart of the study population.

CAG indicates coronary angiography; CAS indicates coronary artery stenosis; DBT: Died before treatment

Figure 2 - Figures show examples of pre transcatheter aortic valve implantation CT image quality assessment for coronary artery interpretation.

A: Insufficient quality (grade 1) for coronary artery analysis (heavy circumflex artery calcification with blooming artifact).

B: Moderate quality (grade 2) hindering interpretation (anterior descending artery calcification with blooming artifacts).

C: Good quality (grade 3) with easy interpretation (severe ostial stenosis of the right coronary artery).

MAIN POINT

In the study, almost half of XA can be avoided safely by interpreting CA in the usual analysis of TAVI-CT, for the benefit of the patient and at a lower cost for society.

Recent CT technological developments are helpful to improve image quality and therefore the identification of TAVI patients not requiring CA revascularization.

I. INTRODUCTION :

Transcatheter aortic valve implantation (TAVI) is the standard treatment in patients with severe aortic stenosis, at high and intermediate surgical risk [1–4]. Patients treated with TAVI are commonly in the elderly and have a high prevalence of comorbidities including atrial fibrillation and extensive coronary artery calcifications [1–4].

Currently, before TAVI procedure, all patients undergo pre-TAVI computed tomography examination (TAVI-CT) and an invasive coronary angiography [1–4]. Indeed, coronary angiography is performed to identify patients with significant coronary artery (CA) stenosis (CAS) which require revascularization before or during TAVI. CT is performed to characterize the aortic root anatomy and the vascular access root, to identify vascular contraindication to TAVI including ongoing diseases such as neoplasia [5–7].

In a recent meta-analysis, Gatti et al. evaluated the diagnostic accuracy of TAVI-CT for the evaluation of CAS and found that routine TAVI-CT assessment of CAS as part of the pre-TAVI workup could avoid the performance of coronary angiography in more than 40% of patients, with potentially a greater specificity for one heartbeat CT [8]. Since these published data, several important technological innovations including new tubes, deep learning image reconstruction algorithms to lower image noise and automated coronary artery motion correction algorithms have been developed and applied to clinical practice [9–11]. To our knowledge, these innovations have not been evaluated for the diagnosis of CAS on TAVI-CT. The purpose of this study was therefore to evaluate the percentage of coronary angiography that could be securely avoided by the interpretation of CA on TAVI-CT, using a new generation single heartbeat CT combined with the latest reconstruction algorithms.

II. METHODS :

A) Study population :

This retrospective study was conducted in compliance with the Declaration of Helsinki of the World Medical Association revised in 2013 for experiments involving humans. All patients were part of the France-TAVI registry and agreed to have their data used for research purposes. All consecutive patients who underwent TAVI-CT and coronary angiography before TAVI in our institution (whether TAVI was performed or not) from December 2021 to July 2022 were screened for inclusion the study. Patients who had coronary stents or coronary bypass graft on TAVI-CT examinations, or those who did not undergo TAVI, were excluded.

B) Image data acquisition and post-processing :

Cardiac CT acquisition was performed with a new generation 256- row detector CT (Revolution Apex, GE Healthcare), which includes a 1300 W tube (Quantix tube, GE Healthcare). Images were acquired either at 100 kVp or 80 kVp based on automatic kVp selection based on scout images. A total of 60 mL of iodinated contrast material (Iobitridol, Xenetix 350, Guerbet, or Iomeprol, Iomeron 350, Bracco Imaging) at a rate of 3.5 mL/sec. A prospective cardiac gated acquisition on the thorax (positioned between 30 and 40% and at 75% of the RR interval) with two 16 cm volumes immediately followed by a non-electrocardiogram-gated helical scanning on the abdomen and pelvis was obtained. Image acquisition was obtained during the arterial phase following intravenous administration of contrast material. No premedication with beta-blockers or nitrates was given to the patients before CT acquisition. Cardiac images were reconstructed with a field of view of 25 cm using deep-learning reconstruction algorithm (TrueFidelity TM, GE Healthcare) and motion correction algorithm that froze coronary arteries (SnapShot Freeze2, GE Healthcare) at 30% for aortic valve interpretation, 40% and 75% of the RR interval for CA analysis. CT images were analyzed using the display console of the picture archiving and

communication system of our institution (Carestream, version 12.1.6.1005). When needed, curvilinear reconstructions of CA were obtained using the Advantage Workstation 4.7 (GE Healthcare).

C) Image Quality assessment :

CAs on TAVI-CT were analyzed retrospectively by a junior radiologist (A.L., with six months of experience in cardiac imaging) who was blinded to the coronary angiography report. Image quality was assessed using a semi-quantitative score as follows: 1 indicating insufficient quality for CA analysis (residual motion artifacts, calcifications of CA with blooming artifacts, insufficient arterial enhancement); 2 indicating moderate quality hindering interpretation; and 3 indicating good image quality, easy interpretation (Fig. 2). A score ≥ 2 was considered as acceptable for interpretation.

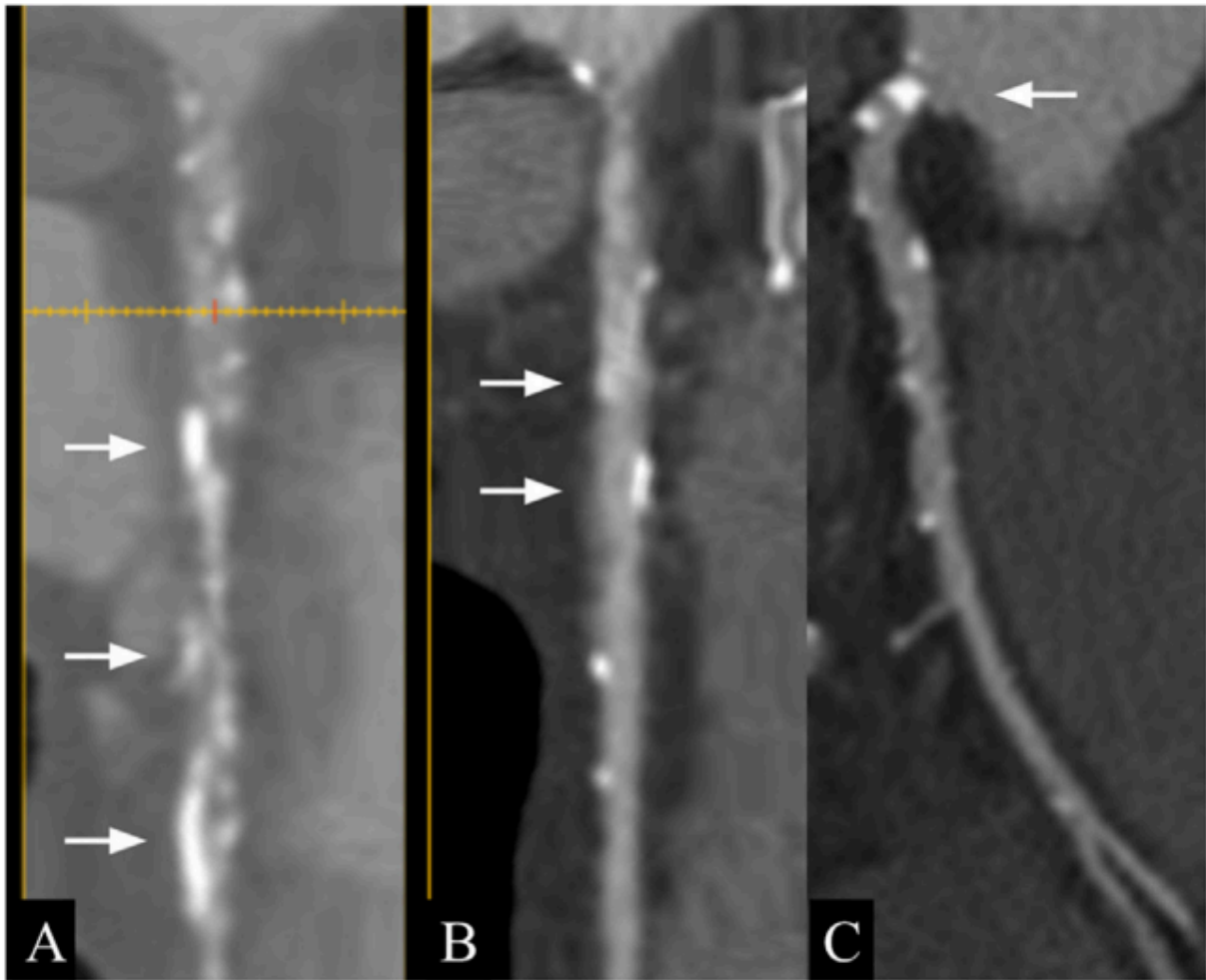


Figure 2 - Figures show examples of pre transcatheter aortic valve implantation CT image quality assessment for coronary artery interpretation.

A: Insufficient quality (grade 1) for coronary artery analysis (heavy circumflex artery calcification with blooming artifact).

B: Moderate quality (grade 2) hindering interpretation (anterior descending artery calcification with blooming artifacts).

C: Good quality (grade 3) with easy interpretation (severe ostial stenosis of the right coronary artery).

D) Interpretation of CA on TAVI-CT :

For TAVI-CT for which image quality was rated acceptable for interpretation, significant CAS was defined as a stenosis of $\geq 50\%$ on the left main CA and $\geq 70\%$ on other CA segments with a diameter larger than 2.5 mm [12]. The analysis of the CA was made on a patient basis. One significant CAS was defined as enough to require coronary angiography. Analysis was performed on either the 40% or 75% motion correction algorithm reconstructions. Reading time for CA interpretation on CT was recorded on 20 consecutive patients.

Based on the outcomes and/or image quality of TAVI-CT examination and in the absence of the knowledge of the results of coronary angiography, patients were classified into two groups. Patients who did not need an additional coronary angiography (no significant CAS or no CAD) were assigned to group A. Patient who needed an additional coronary angiography to decide for revascularization (significant CAS on TAVI-CT or insufficient quality for CA analysis) were assigned to group B. In addition, in case of doubt (even minimal) patients were assigned to group B in order to obtain a high negative predictive value (NPV) to diagnose significant CAS on TAVI-CT.

E) Interpretation of CA on coronary angiography :

Coronary angiography was conducted and interpreted directly at the end of the procedure by experienced cardiologists (T.M., V. L. with 10 and 15 years of experience in coronary angiography, respectively). They reported patients with significant CAS ($\geq 50\%$ on the left main CA and $\geq 70\%$ on other CA segments with a diameter > 2.5 mm) in need of potential revascularization according to recent guidelines [13]. Identification of significant CAS on coronary angiography was considered the standard of reference for further analysis.

II. STATISTICAL ANALYSIS :

Statistical analyses were performed using R version 4.3.0. Categorical variables were expressed as raw numbers, proportions and percentages. Continuous variables were expressed as means § standard deviations (SD) and ranges [14]. The performance of TAVI-CT to identify patients with at least one significant CAS in a proximal CA (i.e., CAS >2.5 mm diameter) was estimated using sensitivity, specificity, positive predictive value (PPV), NPV and accuracy using the decision of the interventional cardiologist to select patients who may benefit from CA recanalization before TAVI as the gold standard. Sensitivity, specificity, PPV, NPV, and accuracy of CA analysis on TAVI-CT to avoid coronary angiography were reported with their exact binomial 95% confidence intervals (CI).

To assess the intra-reader variability, the junior radiologist (A. L.) randomly reread 20 TAVI-CT examinations two months after his initial read. To assess inter-reader variability, the subset of 20 consecutive TAVI-CT examinations was rated by another junior radiologist (SA with six months of experience in cardiac imaging) and an experienced cardiac radiologist (J.-M. S. with 25 years of experience in cardiac imaging,). TAVI-CT readers were blinded to coronary angiography outcomes and of other readers' results. Inter- and intra-observer agreements for image quality was assessed regarding grade 1 (CT analysis not possible) vs. grades 2 or 3 (CT analysis possible).

Intra- and inter-observer agreement regarding group A (coronary angiography needed) and group B (coronary angiography not needed) was also performed. Intra- and inter-observer agreements were estimated using Cohen Kappa test with kappa value of 0.01–0.20, indicating slight agreement; 0.21–0.40 fair agreement; 0.41–0.60 moderate agreement; 0.61–0.80 substantial agreement; 0.81–1.00 almost perfect.

III. RESULTS :

A) Study population

Over the period, before each TAVI procedure, 329 patients underwent TAVI-CT and coronary angiography within one month of each other. By applying the exclusion criteria mentioned above, 206 patients were included in the study. A total of 123 patients were excluded, including 70 patients with either a coronary stent or a coronary bypass graft, 26 patients who were redirected to conventional surgery, 24 patients who did not undergo either TAVI or surgery based on the conclusion of the heart team, and three patients who died before the TAVI procedure. Fig. 1 shows the study flowchart. Patient baseline characteristics are summarized in Table 1.

According to the results of coronary angiography, the prevalence of CAS requiring revascularization was 13% (27 out of 206 patients). Of these 27 patients, based on the decision of the heart team, only 13 (6.3%) were treated with coronary stenting while 14 other patients were not treated with coronary stenting. This decision took into account all the clinical and paraclinical elements requested to decide for CA revascularization in addition to the data provided by TAVI-CT (other than CA analysis) and coronary angiography. Looking at the post-procedure follow-up of these 14 patients, three months later, only one patient had a cardiac event due to advanced dilated cardiomyopathy that led to death. In the other patients, no cardiac events were reported.

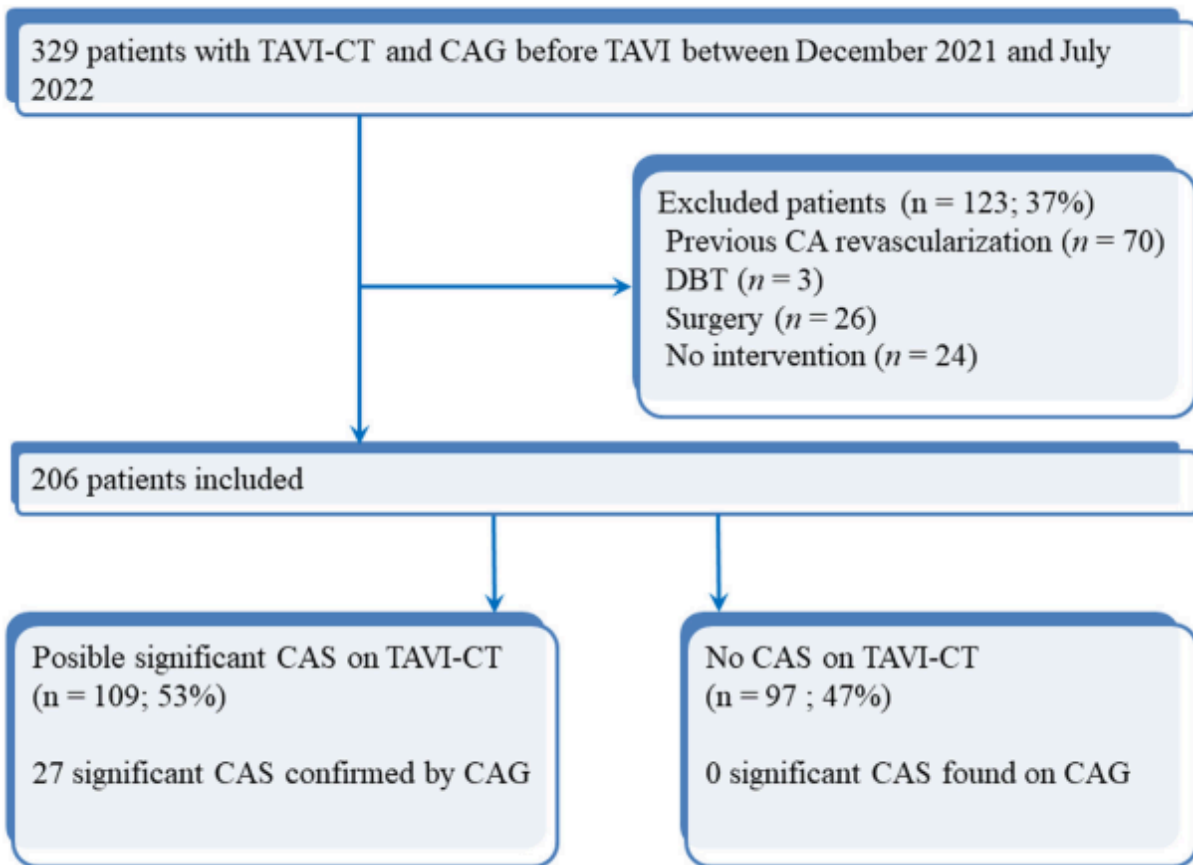


Figure 1 - Flowchart of the study population
 CAG indicates coronary angiography; CAS indicates coronary artery stenosis; DBT: Died before treatment

Variables	Values
Age (years)	80.6 ± 6.1 [74.5–86.7]
Gender	
<i>Male</i>	92 (92/206; 45%)
<i>Female</i>	114 (114/206; 55%)
Body mass index (kg/m ²)	26.7 ± 4.6 [22.1–31.3]
Previous pacemaker	24 (11%)
Atrial fibrillation	41 (20%)
Cr Cl (Cockcroft) (mL/min/1.73m ²)	59.0 ± 21.5 [37.5–80.5]
Aortic valve area (cm ²)	0.75 ± 0.29 [0.46–1.04]
Mean aortic gradient (mmHg)	54.0 ± 17.4 [36.6–71.4]
Left ventricular function (%)	57.0 ± 13.4 [43.6 70.4]

Table 1 - Baseline characteristics of 206 patients included in the study

CrCl indicates creatinine clearance.

Qualitative variables are expressed as raw numbers; numbers in parentheses are proportions followed by percentages.

Quantitative variables are expressed as means § standard deviations; numbers in brackets are ranges.

B) Image quality

Image quality for CA interpretation was rated grade 1 for 51/206 patients (25%), grade 2 for 76/206 patients (37%), and grade 3 for 79/ 206 patients (38%).

Intra-observer agreement for image quality was almost perfect (kappa, 0.81; 95% CI: 0.76–0.87) and inter-observer agreement (junior1-junior2 and junior1-senior) showed substantial agreement (kappa, 0.68; 95% CI: 0.60–0.76 and kappa, 0.74; 95% CI: 0.63–0.82), respectively.

C) Interpretation of CA

For grade 1 patients, coronary angiography was systematically recommended for 51/51 patients (100%). For grade 2 and 3 patients, TAVI-CT ruled out coronary angiography for 97/155 patients (63%) and recommended additional coronary angiography for 58/155 patients (37%). In this group of patients, no indication for CA revascularization was considered during coronary angiography (Fig. 2). Based on TAVI-CT, coronary angiography would have been recommended for 109/206 patients (53%), including 51/51 (100%) grade 1 quality patients by protocol, 33/76 (43%) grade 2 and 25/79 (32%) grade 3.

Sensitivity of TAVI-CT for identifying patients with at least one significant CAS in a proximal CA was 100% (95% CI: 87.2–100) and NPV was 100% (95% CI: 96.3–100%). The specificity of TAVI-CT was 54% (95% CI: 46.6–61.6), PPV was 25% (95% CI: 17.0–34.0%) and accuracy was 60% (95% CI: 53.1–66.9%). Searching for at least one significant CAS on TAVI-CT needed a mean interpretation time of 2 min (1.2 SD; range: 1–5 min).

Inter-observer agreement for classification of patients in group A (coronary angiography not needed) or group B (coronary angiography needed) showed substantial agreement (Kappa, 0.79; 95% CI: 0.69–0.84) for junior1-junior2 and substantial agreement (Kappa, 0.72; 95% CI: 0.63–0.81) for junior1-senior. Intra-observer agreement was almost perfect (Kappa, 0.83; 95% CI: 0.75–0.86).

IV. DISCUSSION :

The main result of this study is that analysis of CA on TAVI-CT might potentially avoid 47% of coronary angiographies by using a new generation CT and latest reconstruction algorithms (i.e., deep learning image reconstruction and automated motion correction algorithm). This can be done thanks to the high NPV (100%) of TAVICT to exclude patients requiring CA revascularization. The identification of significant CAS requiring revascularization before TAVI is important as aortic valve calcification and atherosclerosis convey similar risk factors. This overlap increases the risk of severe CAD, which has to be treated before TAVI according to current guidelines [1,6].

A recent meta-analysis assessed the ability of TAVI-CT to identify significant CAS before every TAVI procedure [8]. Despite heterogeneity in inclusion criteria and CT equipment, the authors found that owing to a high NPV (90% to 100%) for the diagnosis of significant CAS, TAVI-CT allowed avoiding up to 49% coronary angiographies [8]. The results of our study are in line with those of this meta-analysis, with 100% NPV and obviating the need for further invasive coronary angiography in 47% of patients. Indeed, reaching 100% NPV should be the main goal in the elderly population at risk of severe ischemic myocardial complications. Our results as well as those from Strong et al. reached this goal with no false negative results [15].

Regarding false-positive findings, based on TAVI-CT we would have incorrectly oriented 79/203 (39%) patients towards CA, including the 51 patients with inconclusive CA interpretations on TAVI-CT (group 1 patients would have been sent directly to coronary angiography), within the range of prior results (7 to 38%) [8,15]. Searching for a high NPV led to a high number of false positives and a low PPV (25% in our study), and use of the latest technology was not sufficient to significantly lower false-positive findings.

Indeed, the inclusion of elderly patients with aortic stenosis, who are known to be more difficult to scan compared to younger patients with chest pain, due to extensive coronary calcifications, limited breath-hold capabilities, and arrhythmias provided a number

of inconclusive CA interpretations on TAVI-CT [1,16]. In this study, inconclusive interpretations were due to motion artifacts (respiratory and cardiac) and blooming artifacts (coronary calcification), which in most patients were difficult to separate. Despite significant improvements related deep-learning reconstruction and motion correction algorithms, development of higher temporal resolution and spatial resolution in the future should be useful [17,18].

Marked improvements in CT image quality over recent years have been obtained owing to the use of larger detectors, shorter rotation time, deep learning image reconstruction and more effective automated motion correction algorithm [19]. Larger detectors offer a perfect homogeneity of contrast media in the heart and CAs, which facilitates interpretation. Deep learning image reconstruction lowers the level of noise on CT images, especially when reconstructed with a small field of view (25 cm in our protocol with a 512 × 512 matrix), which has a better spatial resolution but more noise [9,20-21]. This is important to lower blooming artifacts. Finally, motion correction algorithm that freezes CAs lowers motion artifacts yielding improved image quality [10-11,22]. Indeed, improving image quality is essential to enhance the performance of TAVI-CT to identify CAS, as demonstrated in our study by the better specificity to diagnose significant CAS in group 3 (good image quality) as compared to group 2 (moderate image quality).

An additional explanation to the low PPV in this study is our choice to recommend coronary angiography at the slightest doubt of significant CAS in order to obtain a high NPV and to lower the CT interpretation time of CA. Instead of the time consuming search for all CAS on CT as done in previous studies (segment by segment analysis), we believe that the role of CT is primarily to determine whether patients need an additional coronary angiography, and therefore to search for at least one proximal significant CAS [8]. This approach can be easily integrated into clinical practice as demonstrated by our 2 min mean CT interpretation time to detect CAS. Moreover, the agreement between junior radiologists and junior and senior radiologists to identify patients with no significant CAS was good in our study, demonstrating that a non-exhaustive and limited interpretation of CA during the interpretation of a TAVI-CT (needing of an additional coronary angiography or not) is sufficient and effective, even for less experienced radiologists.

From a public health perspective, limiting the use of diagnostic coronary angiography before each TAVI should reduce costs and above all potential complications of coronary angiography [23–24]. It should also improve patient's experience within the TAVI care pathway. These points highlight the need for the use of high performance CT machines in the future for the interpretation of CA.

This study has some limitations too. First, we did not include patients with coronary stenting or coronary bypass graft because these patients already benefit from a close follow up for their CAD, with often recent coronary angiography having been performed. In addition, coronary stents are more difficult to interpret due to blooming artifacts which might lower PPV. However, using the same interpretation technique (coronary angiography at the slightest doubt), we should be able to reach a high NPV as well and avoid additional coronary angiography, as suggested by previous studies [1,8]. Second, we did not include patients who did not undergo TAVI because of death, surgical intervention, indication of TAVI not retained, in order to homogenize our population.

Although we believe that the diagnostic performance of TAVI-CT would have been similar in this population, these non-inclusion criteria might be a source of bias. Third, the study was retrospective and was performed in a single expert cardiology center with radiologists trained in TAVI-CT reading. Fourth, the low prevalence of patients for whom percutaneous intervention was recommended might artificially have increased the NPV.

V. CONCLUSION :

The analysis of CA on TAVI-CT with a simple analysis protocol using most recent acquisition and reconstruction techniques may safely avoid 47% of coronary angiography, for the benefit of the patient and potential health cost savings. Future developments of CT might improve even further these results.

BIBLIOGRAPHY

1. Vahanian A, Beyersdorf F, Praz F, Milojevic M, Baldus S, Bauersachs J, Capodanno D, Conradi L, De Bonis M, De Paulis R, Delgado V, Freemantle N, Gilard M, Haugaa KH, Jeppsson A, Jüni P, Pierard L, Prendergast BD, Sádaba JR, Tribouilloy C, Wojakowski W; ESC/EACTS Scientific Document Group. 2021 ESC/EACTS Guidelines for the management of valvular heart disease. *Eur Heart J*. 2022 Feb 12;43(7):561-632. doi: 10.1093/eurheartj/ehab395. Erratum in: *Eur Heart J*. 2022 Feb 18;: PMID: 34453165.

2. Nishimura RA, Otto CM, Bonow RO, Carabello BA, Erwin JP 3rd, Fleisher LA, Jneid H, Mack MJ, McLeod CJ, O'Gara PT, Rigolin VH, Sundt TM 3rd, Thompson A. 2017 AHA/ACC Focused Update of the 2014 AHA/ACC Guideline for the Management of Patients With Valvular Heart Disease: A Report of the American College of Cardiology/American Heart Association Task Force on Clinical Practice Guidelines. *J Am Coll Cardiol*. 2017 Jul 11;70(2):252-289. doi: 10.1016/j.jacc.2017.03.011. Epub 2017 Mar 15. PMID: 28315732.

3. Mack MJ, Leon MB, Thourani VH, Makkar R, Kodali SK, Russo M, Kapadia SR, Malaisrie SC, Cohen DJ, Pibarot P, Leipsic J, Hahn RT, Blanke P, Williams MR, McCabe JM, Brown DL, Babaliaros V, Goldman S, Szeto WY, Genereux P, Pershad A, Pocock SJ, Alu MC, Webb JG, Smith CR; PARTNER 3 Investigators. Transcatheter Aortic-Valve Replacement with a Balloon-Expandable Valve in Low-Risk Patients. *N Engl J Med*. 2019 May 2;380(18):1695-1705. doi: 10.1056/NEJMoa1814052. Epub 2019 Mar 16. PMID: 30883058.

4. Popma JJ, Deeb GM, Yakubov SJ, Mumtaz M, Gada H, O'Hair D, Bajwa T, Heiser JC, Merhi W, Kleiman NS, Askew J, Sorajja P, Rovin J, Chetcuti SJ, Adams DH, Teirstein PS, Zorn GL 3rd, Forrest JK, Tchétché D, Resar J, Walton A, Piazza N, Ramlawi B, Robinson N, Petrossian G, Gleason TG, Oh JK, Boulware MJ, Qiao H, Mugglin AS, Reardon MJ; Evolut Low Risk Trial Investigators. Transcatheter Aortic-Valve Replacement with a Self-Expanding Valve in Low-Risk Patients. *N Engl J Med*. 2019 May 2;380(18):1706-1715. doi: 10.1056/NEJMoa1816885. Epub 2019 Mar 16. PMID: 30883053.

5. Blanke P, Weir-McCall JR, Achenbach S, Delgado V, Hausleiter J, Jilaihawi H, Marwan M, Nørgaard BL, Piazza N, Schoenhagen P, Leipsic JA. Computed Tomography Imaging in the Context of Transcatheter Aortic Valve Implantation (TAVI)/Transcatheter Aortic Valve Replacement (TAVR): An Expert Consensus Document of the Society of Cardiovascular Computed Tomography. *JACC Cardiovasc Imaging*. 2019 Jan;12(1):1-24. doi: 10.1016/j.jcmg.2018.12.003. PMID: 30621986.
6. Francone M, Budde RPJ, Bremerich J, Dacher JN, Loewe C, Wolf F, Natale L, Pontone G, Redheuil A, Vliegenthart R, Nikolaou K, Gutberlet M, Salgado R. CT and MR imaging prior to transcatheter aortic valve implantation: standardisation of scanning protocols, measurements and reporting-a consensus document by the European Society of Cardiovascular Radiology (ESCR). *Eur Radiol*. 2020 May;30(5):2627-2650. doi: 10.1007/s00330-019-06357-8. Epub 2019 Sep 5. Erratum in: *Eur Radiol*. 2020 Mar 2;: PMID: 31489471; PMCID: PMC7160220.
7. Nishimura RA, Otto CM, Bonow RO, Carabello BA, Erwin JP 3rd, Guyton RA, O'Gara PT, Ruiz CE, Skubas NJ, Sorajja P, Sundt TM 3rd, Thomas JD; American College of Cardiology/American Heart Association Task Force on Practice Guidelines. 2014 AHA/ACC guideline for the management of patients with valvular heart disease: executive summary: a report of the American College of Cardiology/American Heart Association Task Force on Practice Guidelines. *J Am Coll Cardiol*. 2014 Jun 10;63(22):2438-88. doi: 10.1016/j.jacc.2014.02.537. Epub 2014 Mar 3. Erratum in: *J Am Coll Cardiol*. 2014 Jun 10;63(22):2489. PMID: 24603192.
8. Gatti M, Gallone G, Poggi V, Bruno F, Serafini A, Depaoli A, De Filippo O, Conrotto F, Darvizeh F, Faletti R, De Ferrari GM, Fonio P, D'Ascenzo F. Diagnostic accuracy of coronary computed tomography angiography for the evaluation of obstructive coronary artery disease in patients referred for transcatheter aortic valve implantation: a systematic review and meta-analysis. *Eur Radiol*. 2022 Aug;32(8):5189-5200. doi: 10.1007/s00330-022-08603-y. Epub 2022 Feb 22. PMID: 35192010; PMCID: PMC9279258.

9. Benz DC, Benetos G, Rampidis G, von Felten E, Bakula A, Sustar A, Kudura K, Messerli M, Fuchs TA, Gebhard C, Pazhenkottil AP, Kaufmann PA, Buechel RR. Validation of deep-learning image reconstruction for coronary computed tomography angiography: Impact on noise, image quality and diagnostic accuracy. *J Cardiovasc Comput Tomogr*. 2020 Sep-Oct;14(5):444-451. doi: 10.1016/j.jcct.2020.01.002. Epub 2020 Jan 13. PMID: 31974008.
10. Liang J, Sun Y, Ye Z, Sun Y, Xu L, Zhou Z, Thomsen B, Li J, Sun Z, Fan Z. Second-generation motion correction algorithm improves diagnostic accuracy of single-beat coronary CT angiography in patients with increased heart rate. *Eur Radiol*. 2019 Aug;29(8):4215-4227. doi: 10.1007/s00330-018-5929-6. Epub 2019 Jan 7. PMID: 30617487.
11. Goldberg A, Adams WH, Thomsen B, Ashraf U, Vasilopoulos V. Validation of Second-Generation Motion-Correction Software for Computed Tomography Coronary Angiography With Novel Quantitative Approach. *J Comput Assist Tomogr*. 2021 May-Jun 01;45(3):403-407. doi: 10.1097/RCT.0000000000001145. PMID: 33797442.
12. Cury RC, Leipsic J, Abbara S, Achenbach S, Berman D, Bittencourt M, Budoff M, Chinnaiyan K, Choi AD, Ghoshhajra B, Jacobs J, Koweek L, Lesser J, Maroules C, Rubin GD, Rybicki FJ, Shaw LJ, Williams MC, Williamson E, White CS, Villines TC, Blankstein R. CAD-RADS™ 2.0 - 2022 Coronary Artery Disease-Reporting and Data System: An Expert Consensus Document of the Society of Cardiovascular Computed Tomography (SCCT), the American College of Cardiology (ACC), the American College of Radiology (ACR), and the North America Society of Cardiovascular Imaging (NASCI). *JACC Cardiovasc Imaging*. 2022 Nov;15(11):1974-2001. doi: 10.1016/j.jcmg.2022.07.002. Epub 2022 Sep 14. PMID: 36115815.
13. Neumann FJ, Sousa-Uva M, Ahlsson A, Alfonso F, Banning AP, Benedetto U, Byrne RA, Collet JP, Falk V, Head SJ, Juni P, Kastrati A, Koller A, Kristensen SD, Niebauer J, Richter DJ, Seferovic PM, Sibbing D, Stefanini GG, Windecker S, Yadav R, Zembala MO; ESC Scientific Document Group. 2018 ESC/EACTS Guidelines on myocardial revascularization. *Eur Heart J*. 2019 Jan 7;40(2):87-165. doi: 10.1093/eurheartj/ehy394. Erratum in: *Eur Heart J*. 2019 Oct 1;40(37):3096. PMID: 30165437.

14. Barat M, Jannot AS, Dohan A, Soyer P. How to report and compare quantitative variables in a radiology article. *Diagn Interv Imaging*. 2022 Dec;103(12):571-573. doi: 10.1016/j.diii.2022.09.007. Epub 2022 Oct 22. PMID: 36280585.
15. Strong C, Ferreira A, Teles RC, Mendes G, Abecasis J, Cardoso G, Guerreiro S, Freitas P, Santos AC, Saraiva C, Brito J, Raposo L, Gonçalves PA, Gabriel HM, Almeida MS, Mendes M. Diagnostic accuracy of computed tomography angiography for the exclusion of coronary artery disease in candidates for transcatheter aortic valve implantation. *Sci Rep*. 2019 Dec 27;9(1):19942. doi: 10.1038/s41598-019-56519-3. PMID: 31882777; PMCID: PMC6934755.
16. DISCHARGE Trial Group. Comparative effectiveness of initial computed tomography and invasive coronary angiography in women and men with stable chest pain and suspected coronary artery disease: multicentre randomised trial. *BMJ*. 2022 Oct 19;379:e071133. doi: 10.1136/bmj-2022-071133. PMID: 36261169.
17. Solomon J, Lyu P, Marin D, Samei E. Noise and spatial resolution properties of a commercially available deep learning-based CT reconstruction algorithm. *Med Phys*. 2020 Sep;47(9):3961-3971. doi: 10.1002/mp.14319. Epub 2020 Jul 6. PMID: 32506661.
18. Matsumoto Y, Fujioka C, Yokomachi K, Kitera N, Nishimaru E, Kiguchi M, Higaki T, Kawashita I, Tatsugami F, Nakamura Y, Awai K. Evaluation of the second-generation whole-heart motion correction algorithm (SSF2) used to demonstrate the aortic annulus on cardiac CT. *Sci Rep*. 2023 Mar 3;13(1):3636. doi: 10.1038/s41598-023-30786-7. PMID: 36869155; PMCID: PMC9984533.
19. Joshi M, Melo DP, Ouyang D, Slomka PJ, Williams MC, Dey D. Current and Future Applications of Artificial Intelligence in Cardiac CT. *Curr Cardiol Rep*. 2023 Mar;25(3):109-117. doi: 10.1007/s11886-022-01837-8. Epub 2023 Jan 28. PMID: 36708505.

20. Greffier J, Frandon J, Durand Q, Kammoun T, Loisy M, Beregi JP, Dabli D. Contribution of an artificial intelligence deep-learning reconstruction algorithm for dose optimization in lumbar spine CT examination: A phantom study. *Diagn Interv Imaging* 2023;104:76-83.
21. Greffier J, Frandon J, Si-Mohamed S, Dabli D, Hamard A, Belaouni A, Akessoul P, Besse F, Guiu B, Beregi JP. Comparison of two deep learning image reconstruction algorithms in chest CT images: A task-based image quality assessment on phantom data. *Diagn Interv Imaging* 2022;103:21-30.
22. Chen Z, Contijoch F, Schluchter A, Grady L, Schaap M, Stayman W, Pack J, McVeigh E. Precise measurement of coronary stenosis diameter with CCTA using CT number calibration. *Med Phys*. 2019 Dec;46(12):5514-5527. doi: 10.1002/mp.13862. Epub 2019 Oct 31. PMID: 31603567; PMCID: PMC7700731.
23. Yu MY, Gao RL, Chen JL, Yang YJ, Qin XW, Qiao SB, Yao M, Yao KB, Liu HB, Wu YJ, Yuan JQ, Chen J, Wu Y, You SJ, Xu B, Chen ZJ. [Complications in selective coronary angiography: analysis of 9196 cases]. *Zhonghua Yi Xue Za Zhi*. 2003 Jan 25;83(2):91-5. Chinese. PMID: 12812672.
24. Li YM, Mei FY, Yao YJ, Tsao JY, Peng Y, Chen M. Causes and predictors of readmission after transcatheter aortic valve implantation : A meta-analysis and systematic review. *Herz*. 2021 Apr;46(Suppl 1):1-8. English. doi: 10.1007/s00059-019-04870-6. Epub 2019 Dec 5. PMID: 31807789.

Vu, le Président du Jury,



Professeur Jean-Michel SERFATY

Vu, le Directeur de Thèse,



Professeur Jean-Michel SERFATY

Vu, le Doyen de la Faculté,



Professeur Antoine HAMEL

Coronary artery assessment on pre transcatheter aortic valve implantation computed tomography may avoid the need for additional coronary angiography

ABSTRACT

Purpose - The purpose of this study was to evaluate the percentage of coronary angiography that can be securely avoided by the interpretation of coronary arteries on pre transcatheter aortic valve implantation CT (TAVI-CT), using CT images obtained with deep-learning reconstruction and motion correction algorithms.

Material and method - All consecutive patients who underwent TAVI-CT and coronary angiography, from December 2021 to July 2022 were screened for inclusion in the study. Patients who had previous coronary artery revascularization or who did not undergo TAVI were excluded. All TAVI-CT examinations were obtained using deep-learning reconstruction and motion correction algorithms. On TAVI-CT examinations, quality and stenosis of coronary artery were analyzed retrospectively. When insufficient image quality and/ or when diagnosis or doubt of one significant coronary artery stenosis, patients were considered as having possible coronary artery stenosis. The results of coronary angiography were used as the standard of reference for significant CAS.

Results - A total of 206 patients (92 men; mean age, 80.6 years) were included; of these 27/206 (13%) had significant coronary artery stenosis on coronary angiography and were referred for potential revascularization. Sensitivity, specificity, negative predictive value, positive predictive value, and accuracy of TAVI-CT to identify patients requiring coronary artery revascularization was 100% (95% confidence interval [CI]: 87.2–100%), 100% (95% CI: 96.3–100%), 54% (95% CI: 46.6–61.6), 25% (95% CI: 17.0–34.0%) and 60% (95% CI: 53.1–66.9%) respectively. Intra- and inter observer variability was substantial agreement for quality and decision to recommend coronary angiography. Mean reading time was 2 +/- 1.2 (standard deviation) min (range: 1–5 min). Overall, TAVI-CT could potentially rule out indication for revascularization for 97 patients (47%).

Conclusion - Analysis of coronary artery on TAVI-CT using deep-learning reconstruction and motion correction algorithms can potentially safely avoid coronary angiography in 47% of patients.

Keywords : Computed tomography ; Computed tomography angiography ; Coronary artery disease ; Transcatheter aortic valve implantation (TAVI) ; Transcatheter aortic valve replacement (TAVR)

L'évaluation des artères coronaires sur le scanner TAVI pourrait éviter le recours à la coronarographie diagnostique

RÉSUMÉ

Objectif - L'objectif de l'étude est d'évaluer le pourcentage de coronarographie diagnostique pouvant être évité, en analysant les artères coronaires sur le scanner TAVI, avec des images post-traitées par une reconstruction itérative en deep-learning et par un algorithme de correction de mouvement.

Matériels et méthodes - Tous les patients qui avaient eu un scanner TAVI et une coronarographie diagnostique, entre décembre 2021 et juillet 2022, étaient screenés consécutivement pour être inclus dans l'étude. Les patients qui avaient déjà subi une revascularisation coronarienne (percutané ou pontage) ou qui n'avaient pas eu un TAVI posé, étaient exclus. Toutes les images du scanners TAVI étaient obtenues par reconstruction itérative en deep-learning et par un algorithme de correction de mouvement. Sur ces images, la qualité de celle-ci et les artères coronaires étaient analysées rétrospectivement. Quand la qualité de l'image était insuffisante et/ou quand il y avait une sténose coronarienne significative ou au moindre doute, le patient était considéré comme ayant possiblement une sténose coronarienne significative. La coronarographie diagnostique était utilisée comme référence pour déterminer une sténose coronarienne significative.

Résultats - Un total de 206 patients (92 hommes ; moyenne d'âge : 80.6 ans) avait été inclus. Sur ces 206 patients, 27 (13%) avaient une sténose coronarienne significative sur la coronarographie diagnostique et étaient adressés pour un possible geste de revascularisation. La sensibilité, la spécificité, la valeur prédictive négative, la valeur prédictive positive et l'accuracy du scanner TAVI pour identifier les patients nécessitant un geste de revascularisation coronarienne étaient de 100% (95% intervalle de confiance [IC]: 87.2–100%), 100% (95% IC: 96.3–100%), 54% (95% IC: 46.6–61.6), 25% (95% IC: 17.0–34.0%) and 60% (95% IC: 53.1–66.9%), respectivement. Les analyses intra et inter-observateur montraient une bonne concordance pour la qualité de l'image et l'interprétation des artères coronaires. Le temps moyen d'interprétation des coronaires étaient de 2 minutes +/- 1.2 minutes (intervalle : 1-5 minutes). Enfin, le scanner TAVI pouvait potentiellement exclure l'indication de revascularisation pour 97 patients (47 %).

Conclusion - L'analyse des artères coronaires sur le scanner TAVI en utilisant une reconstruction itérative par deep-learning et un algorithme de correction de mouvement pourrait éviter le recours à la coronarographie diagnostique chez 47% des patients.

Mots-clés : Tomodensitométrie ; Maladie coronarienne ; Transcatheter aortic valve implantation (TAVI)