



**HAL**  
open science

## Incidence et facteurs de risque des pseudodrusen réticulés : l'étude ALIENOR

Cyril Dutheil

► **To cite this version:**

Cyril Dutheil. Incidence et facteurs de risque des pseudodrusen réticulés : l'étude ALIENOR. Médecine humaine et pathologie. 2018. dumas-02077128

**HAL Id: dumas-02077128**

**<https://dumas.ccsd.cnrs.fr/dumas-02077128>**

Submitted on 22 Mar 2019

**HAL** is a multi-disciplinary open access archive for the deposit and dissemination of scientific research documents, whether they are published or not. The documents may come from teaching and research institutions in France or abroad, or from public or private research centers.

L'archive ouverte pluridisciplinaire **HAL**, est destinée au dépôt et à la diffusion de documents scientifiques de niveau recherche, publiés ou non, émanant des établissements d'enseignement et de recherche français ou étrangers, des laboratoires publics ou privés.

**Thèse pour l'obtention du  
DIPLOME D'ÉTAT DE DOCTEUR EN MEDECINE**

**Discipline : OPHTALMOLOGIE**

Présentée et soutenue publiquement

Le 12 octobre 2018

**Par Cyril DUTHEIL**

Né le 13 septembre 1985 à Sarlat-la-Canéda (24)

**INCIDENCE ET FACTEURS DE RISQUE DES PSEUDODRUSEN**

**RÉTICULÉS : L'ÉTUDE ALIENOR**

**Directeur de thèse :** Madame le Professeur Marie-Noëlle DELYFER

**Rapporteur de thèse :** Monsieur le Docteur Yacine AILEM

**Membres du jury :**

Monsieur le Professeur Jean-François KOROBELNIK

Madame le Professeur Marie-Noëlle DELYFER

Madame le Docteur Cécile DELCOURT

Monsieur le Professeur Jean-François DARTIGUES

Monsieur le Professeur David TOUBOUL

Madame le Docteur Marie-Bénédicte ROUGIER

Président  
Directeur de thèse

Juge

Juge

Juge

Juge

# **TABLES DES MATIÈRES**

---

<b>I.</b>	<b>LISTE DES ABRÉVIATIONS.....</b>	<b>9</b>
<b>II.</b>	<b>TABLE DES ILLUSTRATIONS : tableaux et figures.....</b>	<b>10</b>
<b>III.</b>	<b>INTRODUCTION.....</b>	<b>11</b>
<b>IV.</b>	<b>ARTICLE.....</b>	<b>14</b>
	KEY POINTS.....	15
	ABSTRACT.....	16
	MANUSCRIPT.....	17
	<i>Introduction</i> .....	17
	<i>Subjects and Methods</i> .....	18
	<i>Results</i> .....	22
	<i>Discussion</i> .....	23
	<i>Conclusion</i> .....	26
	REFERENCES.....	27
	FIGURES.....	33
	TABLES.....	35
<b>V.</b>	<b>SYNTHÈSE ET PERSPECTIVES.....</b>	<b>39</b>
<b>VI.</b>	<b>ANNEXES.....</b>	<b>41</b>
	A. Annexe 1 : Les pseudodrusen réticulés.....	41
	B. Annexe 2 : Classifications et DMLA.....	44
	C. Annexe 3 : Nouvelles imageries.....	46
	D. Annexe 4 : Facteurs associés décrits dans la littérature.....	48
<b>VII.</b>	<b>BIBLIOGRAPHIE.....</b>	<b>53</b>

## I. LISTE DES ABRÉVIATIONS

---

<b>ALIENOR</b> : Antioxydants, Lipides Essentiels, Nutrition et maladies OculaiRes	<b>PED</b> : Pigment Epithelial Detachment
<b>ABCA1</b> : Adenosine triphosphate-Binding Cassette subfamily A member 1	<b>RAP</b> : Retinal Angiomatous Proliferation
<b>ADN</b> : Acide DesoxyriboNucléique	<b>RFP</b> : Retinal Fundus Photography
<b>AMD</b> : Age-related Macular Degeneration	<b>RPD</b> : Reticular Pseudodrusen
<b>ApoE4</b> : Apolipoprotein E4	<b>RPE</b> : Retinal Pigment Epithelium
<b>AREDS</b> : Age-Related Eye Disease Study	<b>SD</b> : Standard Deviation
<b>ARMS2</b> : Age-Related Maculopathy Susceptibility 2	<b>SD-OCT</b> : Spectral-Domain Optical Coherence Tomography
<b>BDES</b> : Beaver Dam Eye Study	<b>SFCT</b> : Subfoveal Choroidal Thickness
<b>BL</b> : Basal Laminar	<b>SKILL</b> : Smith-Kettlewell Institute Low Luminance
<b>BMES</b> : Blue Mountains Eye Study	<b>SNP</b> : Single-Nucleotide Polymorphism
<b>BMI</b> : Body Mass Index	<b>SS-OCT</b> : Swept-Source Optical Coherence Tomography
<b>C3</b> : Complement factor 3	<b>TG</b> : Triglycerides
<b>CC</b> : Choriocapillaris	<b>TIMP3</b> : Tissue Inhibitor Of Metalloproteinases 3
<b>CETP</b> : Cholesteryl Ester Transfer Protein	<b>VEGF</b> : Vascular Endothelial Growth Factor
<b>CFH</b> : Complement Factor H	
<b>CFI</b> : Complement Factor I	
<b>CI</b> : Confidence Interval	
<b>CNV</b> : Choroidal NeoVascularization	
<b>CRP</b> : C-Reactive Protein	
<b>cSLO</b> : confocal Scanning Laser Ophthalmoscopy	
<b>DMLA</b> : Dégénérescence Maculaire Liée à l'Age	
<b>EDI</b> : Enhanced Depth Imaging	
<b>ETDRS</b> : Early Treatment of Diabetic Retinopathy Study	
<b>FA</b> : Fluorescein Angiography	
<b>FAF</b> : Fundus AutoFluorescence	
<b>GA</b> : Geographic Atrophy	
<b>GEE</b> : Generalized Estimating Equations	
<b>GWAS</b> : Genome-Wide Association Study	
<b>HDL</b> : High-Density Lipoprotein	
<b>HR</b> : Hazard Ratio	
<b>HTRA1</b> : High-Temperature Requirement A Serine Peptidase 1	
<b>ICGA</b> : IndoCyanin Green Angiography	
<b>IOL</b> : IntraOcular Lens	
<b>NA</b> : Non-available	
<b>IR</b> : Incidence Rate	
<b>IRM</b> : Imagerie par Résonance Magnétique	
<b>IS/OS</b> : Inner Segment/Outer Segment	
<b>LDL</b> : Low-Density Lipoprotein	
<b>LIPC</b> : LiPase C precursor	
<b>LPL</b> : LipoProtein Lipase	
<b>NIR</b> : Near-Infrared Reflectance	
<b>OCT</b> : Optical Coherence Tomography	

## II. TABLE DES ILLUSTRATIONS : tableaux et figures

---

### 1. MANUSCRIPT

- a. **Figure 1:** Reticular pseudodrusen in multimodal imaging.....33
- b. **Figure 2:** Two patients with incident reticular pseudodrusen .....34
- c. **Table 1:** Baseline characteristics of included and non-included eyes.....35
- d. **Table 2:** Annual and five-year cumulative incidence of reticular pseudodrusen per eye according to sex and age range in the ALIENOR Study, 2011-2017.....36
- e. **Table 3:** Associations of incident Reticular Pseudodrusen per eye with potential risk factors in the ALIENOR Study, 2011-2017 (univariate model).....37
- f. **Table 4:** Associations of incident Reticular Pseudodrusen per eye with potential risk factors in the ALIENOR Study, 2011-2017 (multivariate model).....38

### 2. ANNEXE 1

- a. **Figure 1 :** Schéma comparatif pseudodrusen réticulés versus drusen.....41
- b. **Figure 2 :** Les différents sous-types de pseudodrusen réticulés.....42
- c. **Figure 3 :** Les différents stades de pseudodrusen réticulés.....43

### 3. ANNEXE 2

- a. **Figure 4 :** Classification de la DMLA selon Ferris et al., 2013.....44
- b. **Figure 5 :** Classification des néovaisseaux d'après Freund et al., 2010.....45

### 4. ANNEXE 3

- a. **Figure 6 :** Les pseudodrusen et l'imagerie ultra-grand champ.....46
- b. **Figure 7 :** Les pseudodrusen en OCT en face grand champ.....47

### 5. ANNEXE 4

- a. **Table 1 :** Synthèse des principaux facteurs associés aux pseudodrusen réticulés.....48

### III. INTRODUCTION

---

La dégénérescence maculaire liée à l'âge (DMLA) correspond à un vieillissement oculaire associé à des modifications pathologiques chroniques et progressives au niveau du complexe épithélium pigmentaire – membrane de Bruch - choriocapillaire. Il s'agit d'une des principales causes de malvoyance dans le monde, et de la première cause dans les pays développés chez les sujets de plus de 50 ans.<sup>1</sup>

Les pseudodrusen réticulés ont été décrits pour la première fois en 1990<sup>2</sup> sous l'aspect d'un lacis blanc jaunâtre au fond d'œil, d'allure profonde, localisé préférentiellement au niveau des vaisseaux temporaux supérieurs. Ces dépôts, mieux visualisés sur les clichés en lumière monochromatique bleue, sont situés entre les photorécepteurs et l'épithélium pigmentaire, à la différence des drusen, sous-épithéliaux (**Annexe 1**), intégrés dans la classification de la DMLA. (**Annexe 2**). Les pseudodrusen réticulés ont été établis comme étant un facteur de risque de DMLA dès 1995.<sup>3</sup> Depuis, de nombreuses études ont montré qu'ils représentaient un facteur de risque indépendant de DMLA, 4 à 8 fois supérieur aux drusen seuls. Ils sont associés à l'évolution vers l'atrophie géographique<sup>4</sup> ou vers la DMLA néovasculaire et notamment les néovaisseaux de type 3.<sup>5</sup> Par ailleurs, l'impact médico-socio-économique de la DMLA, difficilement quantifiable, n'en demeure pas moins élevé ne serait-ce qu'avec les injections intravitréennes d'anti-VEFG. Ainsi avec une prévalence des pseudodrusen réticulés récemment évaluée à 13.4% dans une étude française<sup>6</sup> de la population bordelaise de plus de 77 ans, ces éléments mettent en exergue l'importance de leur dépistage en termes de santé publique.

Lorsqu'ils sont isolés, les symptômes associés sont peu marqués (diminution de la sensibilité scotopique et aux contrastes, baisse d'acuité visuelle en faible luminance et atteinte micro périmétrique) et ils ne conduisent généralement pas le patient à consulter.<sup>7</sup> Par ailleurs, leur mise en évidence n'est pas toujours aisée et nécessite le plus souvent l'utilisation d'une imagerie multimodale : rétinophotographies, clichés du fond d'œil en autofluorescence et en proche infra-rouge et la tomographie à cohérence optique.<sup>6</sup> Nous comprenons ainsi la difficulté à les appréhender dans notre pratique clinique quotidienne d'une part, mais également lors des travaux de recherche.

Il existe deux grandes études de population analysant l'incidence des pseudodrusen réticulés (Beaver Dam Eye Study<sup>8</sup> et Blue Mountains Eye Study<sup>9</sup>) mais elles n'utilisent pas l'imagerie multimodale et ne sont pas réalisées en Europe (Etats-Unis et Australie). Alors que les facteurs

environnementaux jouent un rôle dans le processus de DMLA<sup>10</sup>, il apparait important de ne pas extrapoler les données issues d'autres continents.

Ainsi, la cohorte ALIENOR (Antioxydants, Lipides Essentiels, Nutrition et maladies Oculaires) née en 2006, à l'Institut de Santé Publique d'Epidémiologie et de Développement de Bordeaux, apporte des données épidémiologiques européennes. Il s'agit d'une cohorte prospective en population générale chez des sujets bordelais âgés d'au moins 73 ans, dont l'objectif est d'étudier les associations entre les maladies oculaires liées à l'âge (DMLA, glaucome, cataracte, sécheresse oculaire) et les facteurs nutritionnels, génétiques, environnementaux et vasculaires. Elle est issue de la cohorte des Trois Cités (3C), lancée en 1999 à Bordeaux, Dijon et Montpellier dont l'objectif initial était l'étude des facteurs vasculaires de la démence.

Les 9294 sujets de plus de 65 ans, dont 2104 bordelais, ont été recrutés en 1999-2001 à partir des listes électorales, et bénéficient depuis, d'un suivi biannuel.

Les données recueillies dans 3C comprennent :

- À l'inclusion : les caractéristiques socio-démographiques, les habitudes alimentaires, un bilan sanguin (lipides, glycémie, créatininémie) et une banque d'ADN
- À chaque suivi : le bilan cognitif et psychologique, l'IRM cérébrale, les incapacités et modifications comportementales, les paramètres vasculaires (antécédents de maladies cardiovasculaires, mesure de la tension artérielle, électrocardiogramme, échographie des carotides), les antécédents médicaux, les traitements et les mesures anthropométriques
- Pour la cohorte bordelaise lors du premier suivi : le dosage de nutriments d'intérêt (antioxydants, acides gras oméga-3, caroténoïdes)

Parmi les 1450 sujets ayant participé au troisième examen de suivi de la cohorte bordelaise de 3C, 963 ont accepté initialement de participer à la cohorte ALIENOR. Les données recueillies comprennent :

- Les antécédents ophtalmologiques, la mesure de la réfraction et de l'acuité visuelle, deux photographies couleur de la rétine à 45° (macula et nerf optique), une mesure de la pression intraoculaire et de l'épaisseur cornéenne centrale, un test du break-up time, un auto-questionnaire sur les facteurs de risque oculaires (exposition au soleil, utilisation de la télévision et de l'ordinateur) et les symptômes de sécheresse oculaire (Ocular Surface Disease Index)
- Depuis 2009, la tomographie à cohérence optique, les clichés 30° du fond d'œil en autofluorescence et proche infrarouge

Nous avons conçu ce travail afin d'évaluer l'incidence des pseudodrusen réticulés et leurs facteurs de risque dans la population de sujets âgés bordelais. Il s'agit de la première étude réalisée en Europe à ce sujet et la première dans le monde utilisant l'imagerie multimodale pour le diagnostic.



## IV. ARTICLE

---

### **Incidence and risk factors for reticular pseudodrusen: the ALIENOR study**

Cyril Dutheil, M.D., <sup>1,2</sup> Mélanie Le Goff, M.Sc., <sup>1</sup> Sarra Gatoussi, M.D. PhD., <sup>1,2</sup>  
Jean-François Korobelnik, M.D., <sup>1,2</sup> Marie-Bénédicte Rougier, M.D. PhD., <sup>2</sup> Cédric  
Schweitzer, M.D. PhD.,<sup>1,2</sup> Cécile Delcourt, PhD., <sup>1</sup> Marie-Noëlle Delyfer, M.D. PhD.<sup>1,2</sup>

1. Univ. Bordeaux, Inserm, Bordeaux Population Health Research Center, LEHA team, UMR 1219, F-33000 Bordeaux, France
2. Service d'Ophthalmologie, CHU de Bordeaux, F-33000 Bordeaux, France

**Abbreviated title:** *Incidence of reticular pseudodrusen*

**Corresponding author:** Prof. Marie-Noelle Delyfer

Service d'ophtalmologie du CHU de Bordeaux – Hôpital Pellegrin – Place Amélie Raba Léon  
– 33000 Bordeaux – France / Phone : +33 557821217 – Fax : +33 556794758

**Manuscript word count :** 3778

**Grants:** Laboratoires Théa (Clermont-Ferrand, France), Université de Bordeaux (Bordeaux, France), Fondation Voir et Entendre (Paris, France), Agence Nationale de la Recherche (2010-PRSP-011), CNSA (Caisse Nationale pour la Solidarité et l'Autonomie) (Paris, France).

Laboratoires Théa participated in the design of the study, but none of the sponsors participated in the collection, management, statistical analysis and interpretation of the data, or in the preparation, review or approval of the present manuscript.

**Proprietary interest:** None

## **KEY POINTS**

**Question:** What are the incidence and risk factors of reticular pseudodrusen (RPD) in a French elderly population using multimodal imaging?

**Findings:** The annual incidence of RPD was 2.047% and the estimated 5-year incidence was 9.73% in 472 eyes of subjects aged 77 years or more. Incident RPD were significantly associated with female gender, age, choroidal thinning and genetic background, while liposoluble statin medication was found to be protective.

**Meaning:** This study presents a higher incidence of RPD than in previous ones, confirms risk factors already describe and suggests a key role of lipid metabolism in RPD pathophysiology.

## **KEY WORDS**

Age related macular degeneration, ARMS2, choroidal thickness, incidence, LIPC, reticular pseudodrusen, statins, subretinal drusenoid deposits

## ABSTRACT

**Importance:** While reticular pseudodrusen (RPD) diagnose needs multimodal imaging, previous incidence studies are based only on fundus photography.

**Objective:** To describe in a population-based study of French elderly subjects the incidence of RPD as detected using multimodal imaging, and to analyze their potential associated risk factors.

**Design :** Cohort study : the Antioxydants, Lipides Essentiels, Nutrition et Maladies Oculaires (ALIENOR) Study. Data were collected between February 22, 2011 and February 15, 2017 and analyzed from Mars 15, 2017 to April 24, 2018. Mean (SD) follow-up duration was 3.7 (1.0) years.

**Setting:** Population-based cohort.

**Participants:** Population-based sample of 759 residents of Bordeaux, France, who participated in the ALIENOR Study. 257 were unable to come to hospital and did not perform all exams. Of the remaining 1004 eyes (502 participants), 532 eyes were excluded: 118 had already prevalent RPD, 51 disclosed late age-related macular degeneration, 46 had uninterpretable data and 317 did not participate to any follow-up examination. Finally, 472 eyes were included.

**Main outcomes and measures:** RPD were defined as definite if they were classified as present with at least two imaging methods from among color fundus photography, fundus autofluorescence, near-infrared reflectance and optical coherence tomography.

**Results:** Of the 472 eyes participants, 263 (55.7%) were women, and the mean (SD) age was 81.9 (3.2) years. 42 eyes were incident for RPD with an overall annual incidence of 2.047% (95% CI, 1.373-3.051) and an estimated 5-year incidence of 9.73%. Annual incidence was higher in females, i.e. 1.948% (95% CI, 1.287-2.947) versus 1.512% (95% CI, 0.786-2.911) in males, and increased with age. In multivariate analysis, three risk factors for incident RPD were identified: subfoveal choroidal thinning (HR, 1.06; 95% CI 1.01-1.11; P=0.0085), presence of risk allele of ARMS2 rs10490924 (HR, 3.36; 95% CI 1.64-6.88; P=0.0009) and LIPC rs10468017 (HR, 2.65; 95% CI 1.39-5.03; P=0.0029). Taking liposoluble statin medication (HR, 0.18; 95% CI 0.03-0.96; P=0.0448) was shown to be a protective factor.

**Conclusions and Relevance:** In this cohort, RPD incidence rate was higher to those observed in other population-based study. We confirm high risk for incident RPD in patients with subfoveal choroidal thinning and carriers of ARMS2 at-risk genotypes and suggests it in patients' carriers of LIPC at-risk genotypes. Also, taking liposoluble statin medication could be a protective factor.

## Introduction

Age-related macular degeneration (AMD) is the third cause of visual impairment worldwide <sup>1</sup> and the number of people affected by AMD is expected to increase by approximately 40% between 2020 and 2040. <sup>2</sup> Early AMD is clinically characterized by the presence of yellowish drusen <sup>3</sup> which are accumulations of extracellular material between the retinal pigment epithelium (RPE)-basal lamina (BL) and the inner collagenous layer of Bruch membrane. A specific category of drusen called reticular pseudodrusen (RPD), <sup>4</sup> or alternatively “subretinal drusenoid deposits”, <sup>5,6</sup> corresponds to drusen-like, granular hyperreflective material located not beneath but above the RPE. <sup>7</sup> Early identification of RPD is important, as they have been shown to be a key risk factor for late AMD as compared to other drusen <sup>8-13</sup>, with a late AMD cumulative incidence risk of 33.9 to 54.50% at 5 years. <sup>14,15</sup>

Reported prevalence of RPD in population-based studies has been variable due to the different imaging tools used for RPD detection and the characteristic of the studied participants. According to the main studies based solely on retinal color fundus image interpretations, RPD prevalence was found to be 0.7% in subjects aged 43 to 86 years in the Beaver Dam Eye Study (BDES) <sup>10</sup>, 0.41% in subjects of approximately the same age in the Melbourne Collaborative Cohort Study <sup>16</sup> and 1.95% in the Blue Mountains Eye Study (BMES). <sup>14</sup> In the Rotterdam Eye Study <sup>17</sup>, RPD detection was based not only on retinal color images but also on near-infrared reflectance (NIR) imaging and the observed prevalence of RPD increased up to 4.9% in participants over 65 years of age. In the Alienor Study <sup>18</sup> using multimodal imaging for RPD detection -combining color fundus photography, spectral-domain optical coherence tomography (SD-OCT), fundus autofluorescence (FAF) and NIR images- we showed that RPD prevalence was even higher - at 13.4% - in subjects over 77 years. Sensitivity of color fundus photographs for RPD detection has been shown to vary between 29% and 88% while that of NIR or SD-OCT ranges between 71% and 100%. <sup>11,15,18-20</sup> Several studies have hence recommended the use of multimodal imaging (and at least two imaging modalities) for accurate RPD identification. <sup>11,19,20,18,21</sup>

Incidence rate of RPD was only assessed, to date, in two population-based studies, BDES and BMES, with the limitation of a diagnosis based only on color fundus photographs <sup>22,10,14</sup> and these previous analyses may therefore have underestimated their incidence due to the absence of multimodal imaging as specified above.

In the literature, several risk factors were described in association with RPD, some of them being still debated. Main reported risk factors are the following: increasing age, female gender, decrease in subfoveal choroidal thickness (SFCT), high body mass index (BMI), low educational level, smoking history, presence of cardiovascular risk factors, presence of risk alleles encoding for complement factor H (CFH) or age-related maculopathy susceptibility 2 (ARMS2).<sup>5,13,23</sup>

The aim of our study is thus to analyze RPD incidence in a population-based study of French elderly subjects using multimodal imaging for their detection, and to further identify their potential associated risk factors.

## **Subjects and Methods**

### **Study participants**

Subjects of the Alienor Study were recruited from an ongoing population-based study (Three-City (3C) Study) on the vascular risk factors for dementia.<sup>24</sup> The Alienor Study consists in periodic eye examinations proposed to all participants of the 3C cohort in Bordeaux since 2006. Among the 1450 subjects of the 3C study re-examined in 2006-2008, 963 (66.4%) participated in the Alienor Study. Detailed characteristics of participants and non-participants have been described elsewhere.<sup>25</sup>

For our study, we used the fifth follow-up of the 3C study as baseline (2011-2012), since SD-OCT, FAF and NIR imaging were systematically performed from then on. Among the 1235 participants of the 3C cohort in Bordeaux who were still alive, 759 (61%) participated in this eye examination. Every follow-up examination thereafter was included in this study: 2011-2012 (baseline), 2013-2015 (first follow-up visit, Alienor wave 1) and 2015-2017 (second follow-up visit, Alienor wave 2). Data collection was performed from February 22<sup>nd</sup>, 2011 to February 15<sup>th</sup>, 2017.

This research followed the tenets of the Declaration of Helsinki. Participants gave written informed consent for participation in the study. The design of the Alienor Study was approved by the Ethical Committee of Bordeaux (Comité de Protection des Personnes Sud-Ouest et Outre-Mer III) in May 2006.

### **Eye Examination**

All eye examinations were performed in the Department of Ophthalmology of the University Hospital of Bordeaux in 2011-2012 (baseline), 2013-2015 (wave 1) and 2015-2017 (wave 2).

They included a recording of past ophthalmic history, measurement of refraction by an auto-refractometer (Speedy-K, Luneau, Prunay-le-Gillon, France), best-corrected visual acuity (using Early Treatment of Diabetic Retinopathy Study [ETDRS] scale), intraocular pressure measurement with a non-contact tonometer (KT 800, Kowa, Tokyo, Japan), slit lamp examination with lens status evaluation, axial length measurement with non-contact partial coherence laser interferometry (IOL Master; Carl Zeiss Meditec AG, Jena, Germany) and fundus color images with a non mydriatic fundus camera (TRC NW6S; Topcon, Tokyo, Japan). Finally, SD-OCT, FAF and NIR imaging were realized using Spectralis® device (Software Version 5.4.7.0; Heidelberg Engineering, Heidelberg, Germany). All the acquisitions were performed by the same experienced technician.

### **Retinal color imaging**

45° retinal color fundus photographs were performed without pupil dilation using a high-resolution digital non mydriatic fundus camera (TRC NW6S; Topcon, Tokyo, Japan). Photographs were interpreted in duplicate by two specially trained technicians. Color and contrast were adjusted if needed to obtain better images when interpreting. Inconsistencies between the two interpretations were adjudicated by a retina specialist for classification of AMD and other retinal diseases. All cases of late AMD and other retinal diseases were reviewed and confirmed by specialists.

### **SD-OCT, FAF and NIR imaging**

SD-OCT examinations were performed using Spectralis® device. All OCT assessments were performed by the same experienced technician without pupil dilation. For macular cube acquisition, conditions used for acquisition were the following: resolution mode, high speed; scan angle, 20°; size X, 1024 pixels (5.7 mm); size Z, 496 pixels (1.9 mm); scaling X, 5.54 µm/pixel; scaling Z, 3.87 µm/pixel; number of B-scans, 19; pattern size, 20 × 15° and distance between B-scans, 236 µm. A horizontal B-scan crossing the fovea using the Enhanced Depth Imaging (EDI) mode was also acquired. FAF and NIR images were obtained using the confocal scanning laser ophthalmoscope (cSLO). FAF images were obtained using an excitation blue light of 488 nm and a barrier filter beginning at 500 nm. NIR images were obtained at 810 nm. For both, examination field size was 30 x 30° centered on the macula.

SD-OCT, FAF and NIR images were interpreted by three independent retina specialists in a masked fashion; that is they neither were involved in the interpretation of any other retinal examination nor had access to color images of the participants. Each image series was deemed absent, present, questionable, or ungradable for the presence of RPD. In the present study,

questionable abnormalities were considered as absent. We included subjects for whom at least two of the four imaging techniques were gradable. SFCT was measured manually by one ophthalmologist, on one horizontal OCT B-scan crossing the fovea and acquired using the EDI mode as previously described.<sup>26</sup>

### **Multimodal definition of RPD**

On color fundus photography, RPD were identified as yellowish interlacing networks ranging from 125 to 250  $\mu\text{m}$  in width.<sup>4,8</sup> On SD-OCT, they were identified as well-defined round or triangular hyperreflective deposits localized between the RPE and the boundary between the inner and outer segments of the photoreceptors (IS/OS boundary) and as small mounds that broke through the IS/OS boundary in more advanced stages.<sup>7</sup> All stages of RPD were considered. On FAF and NIR, RPD were identified as an area of isoautofluorescence/reflectance surrounded by halos of reduced autofluorescence/reflectance, responsible for the “target aspect”.<sup>11,27,28</sup> As previously described<sup>18</sup>, RPD were defined as definite if they were classified as present with at least two imaging methods among color fundus photography, FAF, NIR, and SD-OCT. **Figure 1** illustrates the typical aspect of RPD through multimodal imaging.

### **Classification of AMD**

Classification of late atrophic or neovascular AMD were based on all available information (ophthalmological history and treatments, retinal photographs, SD-OCT scans) as previously described.<sup>29,26,30</sup> All cases of AMD were confirmed by a retina specialist.

### **Assessment of risk factors**

Clinical risk factors (smoking, blood hypertension, diabetes, education level) were collected during the baseline home visit of the 3C Study by trained psychologists or nurses. For participants who were current or past smokers, the number of pack-year was calculated as follows: number of smoking years x (mean number of cigarettes per day/20). Diabetes was defined as fasting blood glucose  $\geq 7$  mmol/L or non-fasting blood glucose  $\geq 11$  mmol/L or use of antidiabetic medication or self-reported diabetes. Blood hypertension was defined as a self-reported medical follow-up for hypertension or systolic blood pressure  $\geq 140$ mmHg or diastolic blood pressure  $\geq 90$  mmHg or antihypertensive treatment. The list of treatments including any lipid lowering therapy was collected at each follow-up. BMI ( $\text{kg}/\text{m}^2$ ) was calculated as weight/height<sup>2</sup> using weight and height measured during the home visit. Plasma lipids were measured at the Biochemistry Laboratory of the University Hospital of Dijon (France) from

baseline fasting blood samples using routine enzymatic techniques. Genome wide-scan analysis was performed at the Lille Génopôle (France) from DNA samples collected at baseline of the 3C study, as previously described.<sup>31</sup> The following known single-nucleotide polymorphisms (SNPs) associated with advanced AMD were extracted from the GWAS data: CFH Y402H rs1061170, Complement Factor C3 (C3) rs2230199, Complement Factor B rs641153, ARMS2 A69S rs10490924, Apolipoprotein E4 (ApoE4), Lipase C precursor (LIPC) rs493258/rs10468017, Cholesteryl Ester Transfer Protein (CETP) rs3764261, Adenosine triphosphate-Binding Cassette subfamily A member 1 (ABCA1) rs1883025, LipoProtein Lipase (LPL) rs12678919.

### **Statistical Analyses**

Characteristics of eyes included in our study were compared with that excluded using logistic Generalized Estimating Equations (GEE) models, which allow taking into account the data from both eyes and their intra-individual correlations.<sup>32</sup> For continuous variables, results were presented using means  $\pm$  standard deviations. For categorical variables, results were presented using n and percentage.

Incidence rate, progression rate and 95% confidence intervals (CIs) of RPD per eye were obtained using Poisson regression models for correlated data. The cumulative 5-year incidence (CI-5) was derived from the incidence rate (IR) using the following exponential formula<sup>30</sup>:  $CI-5(t) = 1 - \exp(-IR \times t)$ . Associations between RPD occurrence and socio-demographic, medical and genetic data were estimated using Cox proportional hazards models with delayed entry and age as the time scale. For genetic variables, SNPs were coded by the number of major frequent alleles (0, 1 and 2). Hazard ratios (HRs) and 95% CIs for occurrence of RPD were estimated using the individual eye as the unit of analysis.<sup>33</sup> First, the association with each risk factor was assessed independently using gender-adjusted models. Secondly, stepwise models were applied using variables with  $p \leq .15$  and a  $p \geq .05$  was considered for exiting the model. Axial length was forced into the multivariate model because of well-known strong correlation with SFCT.<sup>26,34</sup> Data management were performed between Mars 15<sup>th</sup>, 2017 and April 24<sup>th</sup>, 2018.

Values of  $p < .05$  were considered significant. Statistics were performed using SAS software, version 9.4 (SAS Institute Inc, Cary, NC).



## **Results**

### **Study sample**

Among the 759 participants at baseline, 257 were unable to come to the hospital for their eye examination and had only visual acuity and color images available. Of the remaining 1004 eyes (corresponding to 502 subjects) with color fundus images, SD-OCT, FAF and NIR imaging data, 532 eyes were not eligible for RPD incidence analyses, since 118 eyes had already prevalent RPD, 51 eyes disclosed late AMD, 46 had uninterpretable data for RPD assessment in at least one follow-up visit and 317 did not participate to any follow-up examination. Finally, 472 eyes were included for RPD incidence analyses. The mean duration of follow-up was 3.7 years (SD, 1.0; range, 1.2-5.6).

Comparison of demographic characteristics between included and non-included eyes of Alienor participants is summarized in **Table 1**. Included and non-included eyes differed for age (81.9 years and 84.4 respectively,  $p < 0.0001$ ), mean total cholesterol level (5.38 mmol/l and 5.63 mmol/l respectively,  $p = 0.0204$ ), mean low-density lipoprotein (LDL) cholesterol level (3.33 mmol/l and 3.52 mmol/l respectively,  $p = 0.0384$ ) and SNP rs641153 (B Factor) ( $p = 0.05$ ). No statistically significant differences were found between the two groups regarding sex, education level, smoking status, lens extraction, SFCT, axial length, diabetes, blood hypertension, any treatment intake (i.e. lowering blood pressure medication, statin or fibrate therapy), BMI and SNPs in CFH, ARMS2, C3 Factor, ApoE4, LIPC, LPL, CETP, ABCA1.

### **Annual incidence of RPD and five-year cumulative incidence**

As shown in **Table 2**, incident RPD were identified in 42 of the analyzed 472 eyes between the baseline (2011-2012) and the last follow-up visit (2015-2017), with an overall annual incidence of 2.047% (95% CI, 1.373-3.051) and an estimated 5-year incidence of 9.73%. Annual incidence was found to be higher in females, i.e. 1.948% (95% CI, 1.287-2.947) versus 1.512% (95% CI, 0.786-2.911) in males, and increased with age. **Figure 2** illustrates the case of two participants with incident RPD during follow-up.

### **Characteristics of eyes with incident RPD**

Socio-demographic, medical and genetic characteristics of eyes with and without incident RPD were analyzed.

In the univariate model, as shown in **Table 3**, no statistical differences were observed concerning the following socio-demographic and medical factors: sex, education level, smoking status, axial length, lens extraction, diabetes, blood hypertension (or lowering blood

pressure medication) and BMI. A significant association was found with subfoveal choroidal thinning (HR, 1.05; 95% CI 1.01-1.10; P=0.0479). In the subgroup of eyes with axial length measurement available (n= 40 out of 42 incident RPD cases), adjustment of SFCT data on axial length increased the statistical significance of the association (HR, 1.08; 95% CI 1.03-1.12; P=0.00018). Whereas no associations were found with standard markers of lipid metabolism (mean total cholesterol, high-density lipoprotein (HDL) cholesterol, low-density lipoprotein (LDL) cholesterol, triglycerides), a protective association was observed specifically with liposoluble statin medication (HR, 0.13; 95% CI 0.02-0.97; P=0.0467). Among the genetic factors analyzed, risk of incident RPD was increased with at-risk alleles for CFH rs1061170 (HR, 1.96; 95% CI, 1.02-3.77; P=0.0441), ARMS2 rs10490924 (HR, 3.22; 95% CI 1.53-6.77; P=0.0020) and, interestingly, also with LIPC rs10468017 (HR, 2.11; 95% CI 1.02-4.37; P=0.0442). No significant associations were observed with SNPs rs2230199 (C3 factor), rs641153 (B factor), rs493258 (LIPC), rs12678919 (LPL), rs3764261 (CETP), rs1883025 (ABCA1) and ApoE4.

**Table 4** displays the results of the multivariate analysis. Due to the major confusion in SFCT interpretation data with axial length, the multivariate model was forced for axial length as specified in the method section. Three risk factors for incident RPD were identified in our population: subfoveal choroidal thinning (HR, 1.06; 95% CI 1.01-1.11; P=0.0085), ARMS2 risk allele T (HR, 3.36; 95% CI 1.64-6.88; P=0.0009) and LIPC (rs10468017) risk allele T (HR, 2.65; 95% CI 1.39-5.03; P=0.0029). Conversely, intake of liposoluble statin medication (HR, 0.18; 95% CI 0.03-0.96; P=0.0448) was found to be a protective factor.

## **Discussion**

Our study analyzes for the first time RPD incidence in a population of elderly subjects using multimodal imaging. In our cohort, RPD annual incidence rate was 2.047%, and the estimated cumulative 5-year incidence rate was 9.73%. Previous published incidental data were only based on retinal color image interpretations. In BDES, in eyes over 75 years at baseline, the reported 15-year incidence of RPD was 6.6%.<sup>10</sup> In BMES, the 5-year incidence, the 15-year cumulative incidence whatever the age and the 15-year cumulative incidence in eyes over 75 years were 2.0%, 4.0% and 4.9% respectively.<sup>14,22</sup> The higher rate we observed in our cohort can mainly be explained by two factors. First, the systematic use of multimodal imaging for RPD assessment which has undoubtedly increased the sensitivity of RPD detection in our participants<sup>11,18-20</sup>. Secondly, the short intervals between eye examinations (1 to 2 years) used

in our cohort have minimized survival bias as compared to BDES and BMES. In these two cohorts, indeed, follow-up examinations were performed with 5-year intervals and this may have led to increased survival bias and subsequent decreased incidence rates, as some participants may have developed RPD and died within the 5-year interval and therefore not have been counted as incident cases.

Identified risk factors associated with incident RPD in our cohort were high age, female gender, subfoveal choroidal thinning and genetic background (CFH, ARMS2 and LIPC at-risk genotypes). Interestingly, lipophilic statin intake was found to be protective. Several constitutive, genetic and acquired -either environmental or behavioral- risk factors were described in the literature in association with RPD<sup>13,23</sup>. Most studies agree that RPD prevalence<sup>8,16-18,21,35,36</sup> and incidence<sup>10,14</sup> increase with age and female gender, as observed in the present study. Besides age and gender, choroidal thinning was regularly found to be associated with RPD<sup>8,20,35,37-39,39-56</sup>. However, causality between choroidal thinning and RPD remains elusive: RPD were alternatively proposed to be a consequence<sup>8,38,40,57</sup> or a cause of choroidal thinning<sup>58</sup>. Our prospective analyses rule out this last hypothesis, since incident RPD were found to be significantly associated with choroidal thinning both in the univariate and multivariate models, therefore demonstrating that choroidal modifications precede RPD occurrence. However, underlying pathophysiological mechanisms remains to be elucidated and we cannot exclude a third unidentified factor.<sup>46</sup>

Predisposing genetic background has been documented in age-related retinal lesions.<sup>3</sup> Variants in ARMS2<sup>59,60</sup> and CFH<sup>61,62</sup> genes have been strongly involved in AMD. Same risk alleles have also been found to be associated with RPD.<sup>5,13,23</sup> Whereas ARMS2 is almost constantly associated with a higher risk of RPD<sup>14,16,17,35,36,63-66</sup>, controversial data on CFH were reported, CFH being alternatively significantly associated with RPD<sup>14,16,17,65,66</sup>, or not<sup>36,63,67</sup>, and when associated with RPD either described as a risk factor<sup>14,16,17,66</sup> or a protective factor<sup>65</sup>. Our results are in line with the literature, demonstrating an increased risk of RPD in eyes with ARMS2 risk allele, both in the univariate and the multivariate models. As for the CFH, it was found to be associated with a higher incidence of RPD in the univariate model, but no more in the multivariate analysis. This could be explained by a lack of power due to the sample size, and/or a less important role of CFH on RPD occurrence as compared to the other factors included in the multivariate model and as suggested by the heterogeneous results in the literature. Besides ARMS2 and CFH, we further identified an association with a variant in the hepatic lipase gene LIPC (rs10468017) that persisted after multivariate analysis. LIPC encodes hepatic triglyceride lipase which is expressed in the liver, the retina and the subretinal space, and would be involved in HDL metabolism.<sup>68-70</sup> LIPC variants (rs10468017 and rs493258)

were already reported to be associated with a decreased risk of early and late AMD<sup>31,71</sup>, but never with RPD alone<sup>65</sup>. In our analyses, only LIPC variant rs10468017 was found to be associated with incident RPD, but interestingly as a risk factor. Reasons explaining various influence of LIPC on RPD or on other types of drusen or late AMD remain to be elucidated. We can hypothesize that the specific location of RPD above the RPE, contrary to the main other early AMD lesions, may at least explain for part our observation. Lipoprotein environment of the RPE indeed is different at the basolateral and apical sides, with different cholesterol carriers and efflux.<sup>68,72-74</sup> Yet, influence of LIPC on AMD lesions was proposed to be independent of HDL levels<sup>69,75,76</sup>. In our population, indeed, all other biomarkers of lipid metabolism (total cholesterol, HDL, LDL, triglycerides) were not found to be associated with incident RPD,<sup>10,12,14,17,36,41,45,67</sup> in line with most of the previous reports, except for HDL and triglycerides in one incidental study in which they were identified as a risk factor for RPD.<sup>14</sup>

We further identified new arguments in favor of a pivotal role of lipid metabolism on RPD occurrence. An interesting protective association of lipophilic statin intake with incident RPD was hence observed. Such association has never been reported to this day. Association of statin medication with AMD was analyzed in several studies with conflicting results, statins being alternatively reported to be associated with AMD<sup>77-84,85,86</sup> or not<sup>78,80,82,87-90</sup>. Moreover, when statins were found associated with AMD, they were described either as a protective factor<sup>77-84</sup> or as a risk factor<sup>85,86</sup>. Such discrepancies in the literature may rely on the nature of the analyzed statins. Hydrophilic and lipophilic statins indeed exhibit different chemical properties with subsequent different metabolic effects. Lipophilic statins passively and non-selectively diffuse into both hepatocyte cells and non-hepatocyte cells, while hydrophilic statins are liver-specific and require an active transport into hepatocytes to exert their effects<sup>91,92</sup>. Thus, a combined analysis of the effect of the two statin subgroups without any distinction may cover up any specific subgroup properties. The protective role of lipophilic statin towards RPD occurrence can be explained by three potential mechanisms reported in the literature. First, in vitro lipophilic statins were shown to be more efficient than hydrophilic statins to increase the phagocytic function of RPE cells<sup>93</sup> and to influence cholesterol metabolism in RPE cells<sup>64</sup>. Secondly, lipophilic statins exhibit anti-inflammatory properties.<sup>83</sup> Thirdly, lipophilic statins protect RPE cells from oxidative stress.<sup>94,95</sup>

The main strengths of our study include its population-based older cohort sample with a three time-point follow-up, the systematic use of multimodal imaging at each follow-up visit, and short intervals between eye examinations (1 to 2 years) that limited survival bias. Furthermore, RPD were not over-diagnosed since doubtful RPD were not considered for our analyses.

Our study has still some limitations. First, the follow-up rate was intermediate at 61%. Secondly, the small number of incident RPD (n=42) may have induced insufficient statistical power for detecting some associations. Thirdly, included and non-included eyes differed about age, total cholesterol, LDL cholesterol and B Factor. Finally, a last limitation could come from the representativeness of the sample. As previously discussed,<sup>25</sup> the Alienor subsample tends to over-represent younger subjects and high socioeconomic status, compared to the parent cohort (the 3C study). The individuals included in this study may accordingly be healthier and present different lifestyles, in particular concerning their diet and physical activity, by comparison with the general population. However, for most parameters of interest in our study, in particular smoking, BMI, diabetes, hypertension and plasma lipids, subjects included in the Alienor study were not different from those who did not participate.<sup>25</sup>

## **Conclusion**

In conclusion, in this population-based study of French elderly subjects, the annual incidence rate of RPD was 2.047% and the five-year cumulative incidence of 9.73. These results were higher than those previously reported in the literature and can be explained by the multimodal detection of RPD here used for the first time. Incident RPD were strongly associated with high age, female gender, SNPs in CFH, ARMS2, a LIPC variant and a thinner choroid. Interestingly, lipophilic statin therapy intake was found to be protective.

## REFERENCES

1. Bourne RRA, Stevens GA, White RA, et al. Causes of vision loss worldwide, 1990–2010: a systematic analysis. *Lancet Glob Health*. 2013;1(6):e339-e349. doi:10.1016/S2214-109X(13)70113-X
2. Wong WL, Su X, Li X, et al. Global prevalence of age-related macular degeneration and disease burden projection for 2020 and 2040: a systematic review and meta-analysis. *Lancet Glob Health*. 2014;2(2):e106-e116. doi:10.1016/S2214-109X(13)70145-1
3. Lim LS, Mitchell P, Seddon JM, Holz FG, Wong TY. Age-related macular degeneration. *The Lancet*. 2012;379(9827):1728-1738. doi:10.1016/S0140-6736(12)60282-7
4. Mimoun G, Soubrane G, Coscas G. [Macular drusen]. *J Fr Ophthalmol*. 1990;13(10):511-530.
5. Spaide RF, Ooto S, Curcio CA. Subretinal Drusenoid Deposits AKA Pseudodrusen. *Surv Ophthalmol*. May 2018. doi:10.1016/j.survophthal.2018.05.005
6. Rudolf M, Malek G, Messinger JD, Clark ME, Wang L, Curcio CA. Sub-retinal drusenoid deposits in human retina: Organization and composition. *Exp Eye Res*. 2008;87(5):402-408. doi:10.1016/j.exer.2008.07.010
7. Zweifel SA, Spaide RF, Curcio CA, Malek G, Imamura Y. Reticular Pseudodrusen Are Subretinal Drusenoid Deposits. *Ophthalmology*. 2010;117(2):303-312.e1. doi:10.1016/j.ophtha.2009.07.014
8. Arnold JJ, Sarks SH, Killingsworth MC, Sarks JP. Reticular pseudodrusen. A risk factor in age-related maculopathy. *Retina Phila Pa*. 1995;15(3):183-191.
9. Cohen SY, Dubois L, Tadayoni R, Delahaye-Mazza C, Debibie C, Quentel G. Prevalence of reticular pseudodrusen in age-related macular degeneration with newly diagnosed choroidal neovascularisation. *Br J Ophthalmol*. 2007;91(3):354-359. doi:10.1136/bjo.2006.101022
10. Klein R, Meuer SM, Knudtson MD, Iyengar SK, Klein BEK. The Epidemiology of Retinal Reticular Drusen. *Am J Ophthalmol*. 2008;145(2):317-326. doi:10.1016/j.ajo.2007.09.008
11. Smith RT, Sohrab MA, Busuioc M, Barile G. Reticular Macular Disease. *Am J Ophthalmol*. 2009;148(5):733-743.e2. doi:10.1016/j.ajo.2009.06.028
12. Pumariega NM, Smith RT, Sohrab MA, LeTien V, Souied EH. A PROSPECTIVE STUDY OF RETICULAR MACULAR DISEASE. *Ophthalmology*. 2011;118(8):1619-1625. doi:10.1016/j.ophtha.2011.01.029
13. Sivaprasad S, Bird A, Nitiapapand R, Nicholson L, Hykin P, Chatziralli I. Perspectives on reticular pseudodrusen in age-related macular degeneration. *Surv Ophthalmol*. 2016;61(5):521-537. doi:10.1016/j.survophthal.2016.02.005
14. Joachim N, Mitchell P, Rochtchina E, Tan AG, Wang JJ. Incidence and Progression of Reticular Drusen in Age-related Macular Degeneration. *Ophthalmology*. 2014;121(4):917-925. doi:10.1016/j.ophtha.2013.10.043
15. Gil JQ, Marques JP, Hogg R, et al. Clinical features and long-term progression of reticular pseudodrusen in age-related macular degeneration: findings from a multicenter cohort. *Eye*. 2017;31(3):364-371. doi:10.1038/eye.2016.207
16. Finger RP, Chong E, McGuinness MB, et al. Reticular Pseudodrusen and Their Association with Age-Related Macular Degeneration: The Melbourne Collaborative Cohort Study. *Ophthalmology*. 2016;123(3):599-608. doi:10.1016/j.ophtha.2015.10.029
17. Buitendijk GHS, Hooghart AJ, Brussee C, et al. Epidemiology of Reticular Pseudodrusen in Age-Related Macular Degeneration: The Rotterdam Study Epidemiology of Reticular Pseudodrusen. *Invest Ophthalmol Vis Sci*. 2016;57(13):5593-5601. doi:10.1167/iovs.15-18816

18. Chan H, Cougnard-Grégoire A, Delyfer M-N, et al. Multimodal Imaging of Reticular Pseudodrusen in a Population-Based Setting: The Alienor Study. *Invest Ophthalmol Vis Sci.* 2016;57(7):3058-3065. doi:10.1167/iovs.16-19487
19. Ueda-Arakawa N, Ooto S, Tsujikawa A, Yamashiro K, Oishi A, Yoshimura N. SENSITIVITY AND SPECIFICITY OF DETECTING RETICULAR PSEUDODRUSEN IN MULTIMODAL IMAGING IN JAPANESE PATIENTS: *Retina.* 2013;33(3):490-497. doi:10.1097/IAE.0b013e318276e0ae
20. De Bats F, Mathis T, Mauget-Faÿsse M, Joubert F, Denis P, Kodjikian L. PREVALENCE OF RETICULAR PSEUDODRUSEN IN AGE-RELATED MACULAR DEGENERATION USING MULTIMODAL IMAGING: *Retina.* 2016;36(1):46-52. doi:10.1097/IAE.0000000000000648
21. Schmitz-Valckenberg S, Alten F, Steinberg JS, et al. Reticular Drusen Associated with Geographic Atrophy in Age-Related Macular Degeneration. *Invest Ophthalmol Vis Sci.* 2011;52(9):5009-5015. doi:10.1167/iovs.11-7235
22. Mitchell P, Wang JJ, Foran S, Smith W. Five-year incidence of age-related maculopathy lesions. *Ophthalmology.* 2002;109(6):1092-1097. doi:10.1016/S0161-6420(02)01055-2
23. Rabiolo A, Sacconi R, Cicinelli MV, Querques L, Bandello F, Querques G. Spotlight on reticular pseudodrusen. *Clin Ophthalmol Auckl NZ.* 2017;11:1707-1718. doi:10.2147/OPHTH.S130165
24. Antoniak M, Pugliatti M, Hubbard R, et al. Vascular Factors and Risk of Dementia: Design of the Three-City Study and Baseline Characteristics of the Study Population. *Neuroepidemiology.* 2003;22(6):316-325. doi:10.1159/000072920
25. Delcourt C, Korobelnik J-F, Barberger-Gateau P, et al. Nutrition and Age-Related Eye Diseases: The ALIENOR (Antioxydants, LIpides Essentiels, Nutrition et Maladies OculaiRes) Study. *J Nutr Health Aging.* 2010;14(10):854-861.
26. Gattoussi S, Cougnard-Grégoire A, Korobelnik J-F, et al. CHOROIDAL THICKNESS, VASCULAR FACTORS, AND AGE-RELATED MACULAR DEGENERATION: The ALIENOR Study. *Retina Phila Pa.* June 2018. doi:10.1097/IAE.0000000000002237
27. Schmitz-Valckenberg S, Steinberg JS, Fleckenstein M, Visvalingam S, Brinkmann CK, Holz FG. Combined Confocal Scanning Laser Ophthalmoscopy and Spectral-Domain Optical Coherence Tomography Imaging of Reticular Drusen Associated with Age-Related Macular Degeneration. *Ophthalmology.* 2010;117(6):1169-1176. doi:10.1016/j.ophtha.2009.10.044
28. Querques G, Querques L, Martinelli D, et al. Pathologic insights from integrated imaging of reticular pseudodrusen in age-related macular degeneration. *Retina Phila Pa.* 2011;31(3):518-526. doi:10.1097/IAE.0b013e3181f04974
29. Seddon JM, Sharma S, Adelman RA. Evaluation of the Clinical Age-Related Maculopathy Staging System. *Ophthalmology.* 2006;113(2):260-266. doi:10.1016/j.ophtha.2005.11.001
30. Saunier V, Merle BMJ, Delyfer M-N, et al. Incidence of and Risk Factors Associated With Age-Related Macular Degeneration: Four-Year Follow-up From the ALIENOR Study. *JAMA Ophthalmol.* 2018;136(5):473. doi:10.1001/jamaophthalmol.2018.0504
31. Merle BMJ, Maubaret C, Korobelnik J-F, et al. Association of HDL-Related Loci with Age-Related Macular Degeneration and Plasma Lutein and Zeaxanthin: the Alienor Study. *PLoS ONE.* 2013;8(11). doi:10.1371/journal.pone.0079848
32. Zeger SL, Liang KY, Albert PS. Models for longitudinal data: a generalized estimating equation approach. *Biometrics.* 1988;44(4):1049-1060.
33. Glynn RJ, Rosner B. Regression Methods when the Eye is the Unit of Analysis. *Ophthalmic Epidemiol.* 2012;19(3):159-165. doi:10.3109/09286586.2012.674614
34. Agawa T, Miura M, Ikuno Y, et al. Choroidal thickness measurement in healthy Japanese subjects by three-dimensional high-penetration optical coherence tomography. *Graefes Arch Clin Exp Ophthalmol.* 2011;249(10):1485. doi:10.1007/s00417-011-1708-7

35. Yoneyama S, Sakurada Y, Mabuchi F, et al. Genetic and clinical factors associated with reticular pseudodrusen in exudative age-related macular degeneration. *Graefes Arch Clin Exp Ophthalmol*. 2014;252(9):1435-1441. doi:10.1007/s00417-014-2601-y
36. Boddu S, Lee MD, Marsiglia M, Marmor M, Freund KB, Smith RT. Risk Factors Associated with Reticular Pseudodrusen versus Large Soft Drusen. *Am J Ophthalmol*. 2014;157(5):985-993.e2. doi:10.1016/j.ajo.2014.01.023
37. Cicinelli MV, Rabiolo A, Marchese A, et al. Choroid morphometric analysis in non-neovascular age-related macular degeneration by means of optical coherence tomography angiography. *Br J Ophthalmol*. January 2017:bjophthalmol-2016-309481. doi:10.1136/bjophthalmol-2016-309481
38. Garg A, Oll M, Yzer S, et al. Reticular Pseudodrusen in Early Age-Related Macular Degeneration Are Associated With Choroidal Thinning. *Invest Ophthalmol Vis Sci*. 2013;54(10):7075-7081. doi:10.1167/iovs.13-12474
39. Querques G, Querques L, Forte R, Massamba N, Coscas F, Souied EH. Choroidal Changes Associated with Reticular Pseudodrusen. *Invest Ophthalmol Vis Sci*. 2012;53(3):1258-1263. doi:10.1167/iovs.11-8907
40. Sohrab MA, Smith RT, Salehi-Had H, Sadda SR, Fawzi AA. Image Registration and Multimodal Imaging of Reticular Pseudodrusen. *Invest Ophthalmol Vis Sci*. 2011;52(8):5743-5748. doi:10.1167/iovs.10-6942
41. Hogg RE, Silva R, Staurengi G, et al. Clinical Characteristics of Reticular Pseudodrusen in the Fellow Eye of Patients with Unilateral Neovascular Age-Related Macular Degeneration. *Ophthalmology*. 2014;121(9):1748-1755. doi:10.1016/j.ophtha.2014.03.015
42. Ueda-Arakawa N, Ooto S, Ellabban AA, et al. Macular Choroidal Thickness and Volume of Eyes With Reticular Pseudodrusen Using Swept-Source Optical Coherence Tomography. *Am J Ophthalmol*. 2014;157(5):994-1004.e3. doi:10.1016/j.ajo.2014.01.018
43. Capuano V, Souied EH, Miere A, Jung C, Costanzo E, Querques G. Choroidal maps in non-exudative age-related macular degeneration. *Br J Ophthalmol*. 2016;100(5):677-682. doi:10.1136/bjophthalmol-2015-307169
44. Corvi F, Souied EH, Capuano V, et al. Choroidal structure in eyes with drusen and reticular pseudodrusen determined by binarisation of optical coherence tomographic images. *Br J Ophthalmol*. 2017;101(3):348-352. doi:10.1136/bjophthalmol-2016-308548
45. Leisy HB, Ahmad M, Marmor M, Smith RT. Association between Decreased Renal Function and Reticular Macular Disease in Age-Related Macular Degeneration. *Ophthalmol Retina*. 2017;1(1):42-48. doi:10.1016/j.oret.2016.08.011
46. Mrejen S, Spaide RF. The relationship between pseudodrusen and choroidal thickness. *Retina*. 2014;34(8):1560-1566.
47. Switzer DW, Mendonça LS, Saito M, Zweifel SA, Spaide RF. Segregation of ophthalmoscopic characteristics according to choroidal thickness in patients with early age-related macular degeneration. *Retina Phila Pa*. 2012;32(7):1265-1271. doi:10.1097/IAE.0b013e31824453ac
48. Yun C, Ahn J, Kim M, Hwang S-Y, Kim S-W, Oh J. Ocular Perfusion Pressure and Choroidal Thickness in Early Age-Related Macular Degeneration Patients With Reticular Pseudodrusen OPP and CT in AMD Patients With Reticular Pseudodrusen. *Invest Ophthalmol Vis Sci*. 2016;57(15):6604-6609. doi:10.1167/iovs.16-19989
49. Thorell MR, Goldhardt R, Nunes RP, et al. Association Between Subfoveal Choroidal Thickness, Reticular Pseudodrusen, and Geographic Atrophy in Age-Related Macular Degeneration. *Ophthalmic Surg Lasers Imaging Retina*. 2015;46(5):513-521. doi:10.3928/23258160-20150521-02
50. Zheng F, Gregori G, Schaal KB, et al. Choroidal Thickness and Choroidal Vessel Density in Nonexudative Age-Related Macular Degeneration Using Swept-Source Optical



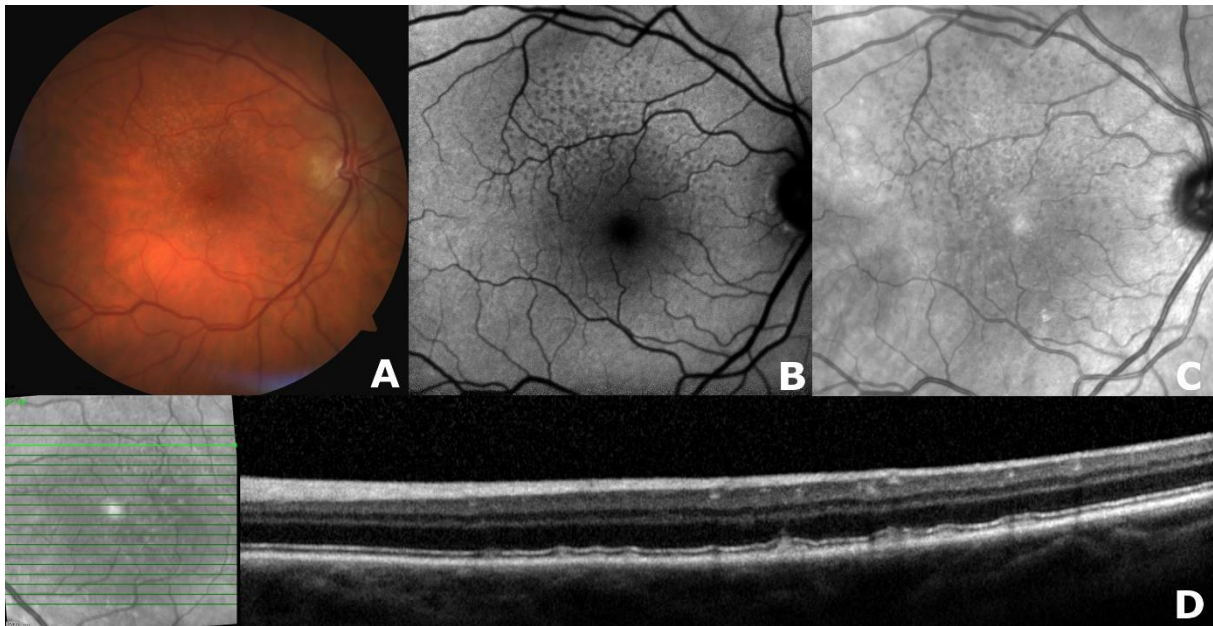
- Coherence Tomography Imaging. *Invest Ophthalmol Vis Sci.* 2016;57(14):6256-6264. doi:10.1167/iovs.16-20161
51. Spaide RF. Choriocapillaris Flow Features Follow a Power Law Distribution: Implications for Characterization and Mechanisms of Disease Progression. *Am J Ophthalmol.* 2016;170:58-67. doi:10.1016/j.ajo.2016.07.023
  52. Haas P, Esmaelpour M, Ansari-Shahrezaei S, Drexler W, Binder S. Choroidal Thickness in Patients With Reticular Pseudodrusen Using 3D 1060-nm OCT Maps. *Invest Ophthalmol Vis Sci.* 2014;55(4):2674-2681. doi:10.1167/iovs.13-13338
  53. Alten F, Heiduschka P, Clemens CR, Eter N. Exploring choriocapillaris under reticular pseudodrusen using OCT-Angiography. *Graefes Arch Clin Exp Ophthalmol.* 2016;254(11):2165-2173. doi:10.1007/s00417-016-3375-1
  54. A. Martillo M, Marsiglia M, D. Lee M, Pumariaga N, Bearely S, Smith RT. Is Reticular Macular Disease a Choriocapillaris Perfusion Problem? *Med Hypothesis Discov Innov Ophthalmol.* 2012;1(2):37-41.
  55. Nesper PL, Soetikno BT, Fawzi AA. Choriocapillaris Nonperfusion is Associated With Poor Visual Acuity in Eyes With Reticular Pseudodrusen. *Am J Ophthalmol.* 2017;174:42-55. doi:10.1016/j.ajo.2016.10.005
  56. Chatziralli I, Theodossiadis G, Panagiotidis D, Pousoulidi P, Theodossiadis P. Choriocapillaris' alterations in the presence of reticular pseudodrusen compared to drusen: study based on OCTA findings. *Int Ophthalmol.* August 2017:1-7. doi:10.1007/s10792-017-0671-7
  57. Alten F, Clemens CR, Heiduschka P, Eter N. Localized Reticular Pseudodrusen and Their Topographic Relation to Choroidal Watershed Zones and Changes in Choroidal Volumes. *Invest Ophthalmol Vis Sci.* 2013;54(5):3250-3257. doi:10.1167/iovs.13-11923
  58. Spaide RF. OUTER RETINAL ATROPHY AFTER REGRESSION OF SUBRETINAL DRUSENOID DEPOSITS AS A NEWLY RECOGNIZED FORM OF LATE AGE-RELATED MACULAR DEGENERATION: *Retina.* 2013;33(9):1800-1808. doi:10.1097/IAE.0b013e31829c3765
  59. Fritsche LG, Loenhardt T, Janssen A, et al. Age-related macular degeneration is associated with an unstable *ARMS2 (LOC387715)* mRNA. *Nat Genet.* 2008;40(7):892-896. doi:10.1038/ng.170
  60. Kortvely E, Hauck SM, Duetsch G, et al. *ARMS2* Is a Constituent of the Extracellular Matrix Providing a Link between Familial and Sporadic Age-Related Macular Degenerations. *Invest Ophthalmol Vis Sci.* 2010;51(1):79-88. doi:10.1167/iovs.09-3850
  61. Seddon JM, Reynolds R, Rosner B. Peripheral Retinal Drusen and Reticular Pigment: Association with CFHY402H and CFHrs1410996 Genotypes in Family and Twin Studies. *Invest Ophthalmol Vis Sci.* 2009;50(2):586-591. doi:10.1167/iovs.08-2514
  62. Klein RJ. Complement Factor H Polymorphism in Age-Related Macular Degeneration. *Science.* 2005;308(5720):385-389. doi:10.1126/science.1109557
  63. Ueda-Arakawa N, Ooto S, Nakata I, et al. Prevalence and Genomic Association of Reticular Pseudodrusen in Age-Related Macular Degeneration. *Am J Ophthalmol.* 2013;155(2):260-269.e2. doi:10.1016/j.ajo.2012.08.011
  64. Wu T, Fujihara M, Tian J, et al. Apolipoprotein B100 Secretion by Cultured ARPE-19 Cells is Modulated by Alteration of Cholesterol Levels. *J Neurochem.* 2010;114(6):1734-1744. doi:10.1111/j.1471-4159.2010.06884.x
  65. Lin LY, Zhou Q, Hagstrom S, et al. Association of Single-Nucleotide Polymorphisms in Age-Related Macular Degeneration With Pseudodrusen: Secondary Analysis of Data From the Comparison of AMD Treatments Trials. *JAMA Ophthalmol.* May 2018. doi:10.1001/jamaophthalmol.2018.1231
  66. Puche N, Blanco-Garavito R, Richard F, et al. Genetic and environmental factors associated with reticular pseudodrusen in age-related macular degeneration. *Retina Phila Pa.* 2013;33(5):998-1004. doi:10.1097/IAE.0b013e31827b6483

67. Wu Z, Ayton LN, Luu CD, Baird PN, Guymer RH. Reticular Pseudodrusen in Intermediate Age-Related Macular Degeneration: Prevalence, Detection, Clinical, Environmental, and Genetic Associations Reticular Pseudodrusen in Intermediate AMD. *Invest Ophthalmol Vis Sci*. 2016;57(3):1310-1316. doi:10.1167/iovs.15-18682
68. Fritsche LG, Fariss RN, Stambolian D, Abecasis GR, Curcio CA, Swaroop A. Age-Related Macular Degeneration: Genetics and Biology Coming Together. *Annu Rev Genomics Hum Genet*. 2014;15:151-171. doi:10.1146/annurev-genom-090413-025610
69. Neale BM, Fagerness J, Reynolds R, et al. Genome-wide association study of advanced age-related macular degeneration identifies a role of the hepatic lipase gene (LIPC). *Proc Natl Acad Sci*. 2010;107(16):7395-7400. doi:10.1073/pnas.0912019107
70. Zheng W, Reem RE, Omarova S, et al. Spatial Distribution of the Pathways of Cholesterol Homeostasis in Human Retina. Chaum E, ed. *PLoS ONE*. 2012;7(5):e37926. doi:10.1371/journal.pone.0037926
71. Lou L-X, Hu K-M, Jin K, Zhang S-Z, Ye J. The Relationship Between Hepatic Lipase Gene Variant and Advanced Age-Related Macular Degeneration: A Meta-analysis. *JAMA Ophthalmol*. 2014;132(10):1226-1231. doi:10.1001/jamaophthalmol.2014.1752
72. Pikuleva IA, Curcio CA. Cholesterol in the retina: the best is yet to come. *Prog Retin Eye Res*. 2014;0:64-89. doi:10.1016/j.preteyeres.2014.03.002
73. Lyssenko NN, Haider N, Picataggi A, et al. Directional ABCA1-mediated cholesterol efflux and apoB-lipoprotein secretion in the retinal pigment epithelium. *J Lipid Res*. August 2018. doi:10.1194/jlr.M087361
74. Curcio CA, Messinger JD, Sloan KR, McGwin G, Medeiros NE, Spaide RF. Subretinal Drusenoid Deposits In Non-Neovascular Age-Related Macular Degeneration: Morphology, Prevalence, Topography, And Biogenesis Model. *Retina Phila Pa*. 2013;33(2). doi:10.1097/IAE.0b013e31827e25e0
75. Lee J, Zeng J, Hughes G, et al. Association of LIPC and advanced age-related macular degeneration. *Eye*. 2013;27(2):265-271. doi:10.1038/eye.2012.276
76. Seddon JM, Reynolds R, Rosner B. Associations of smoking, body mass index, dietary lutein, and the LIPC gene variant rs10468017 with advanced age-related macular degeneration. *Mol Vis*. 2010;16:2412-2424.
77. Guymer RH, Chiu AW, Lim L, Baird PN. HMG CoA Reductase Inhibitors (Statins): Do They Have a Role in Age-related Macular Degeneration? *Surv Ophthalmol*. 2005;50(2):194-206. doi:10.1016/j.survophthal.2004.12.002
78. Tan JSL, Mitchell P, Rochtchina E, Wang JJ. Statins and the Long-term Risk of Incident Age-related Macular Degeneration: The Blue Mountains Eye Study. *Am J Ophthalmol*. 2007;143(4):685-687. doi:10.1016/j.ajo.2006.11.021
79. Hall NF, Gale CR, Syddall H, Phillips DIW, Martyn CN. Risk of macular degeneration in users of statins: cross sectional study. *BMJ*. 2001;323(7309):375-376.
80. Tsao SW, Fong DS. Do Statins Have a Role in the Prevention of Age-Related Macular Degeneration? *Drugs Aging*. 2013;30(4):205-213. doi:10.1007/s40266-013-0061-4
81. Guymer RH, Baird PN, Varsamidis M, et al. Proof of Concept, Randomized, Placebo-Controlled Study of the Effect of Simvastatin on the Course of Age-Related Macular Degeneration. *PLoS ONE*. 2013;8(12). doi:10.1371/journal.pone.0083759
82. Barbosa DTQ, Mendes TS, Cíntron-Colon HR, et al. Age-related macular degeneration and protective effect of HMG Co-A reductase inhibitors (statins): results from the National Health and Nutrition Examination Survey 2005–2008. *Eye*. 2014;28(4):472-480. doi:10.1038/eye.2014.8
83. Ma L, Wang Y, Du J, Wang M, Zhang R, Fu Y. The association between statin use and risk of age-related macular degeneration. *Sci Rep*. 2015;5. doi:10.1038/srep18280
84. Vavvas DG, Daniels AB, Kapsala ZG, et al. Regression of Some High-risk Features of Age-related Macular Degeneration (AMD) in Patients Receiving Intensive Statin Treatment. *EBioMedicine*. 2016;5:198-203. doi:10.1016/j.ebiom.2016.01.033

85. Etminan M, Brophy JM, Maberley D. Use of statins and angiotensin converting enzyme inhibitors (ACE-Is) and the risk of age-related macular degeneration: nested case-control study. *Curr Drug Saf.* 2008;3(1):24-26.
86. Peiretti E, Mandas A, Abete C, et al. Age-related macular degeneration and cognitive impairment show similarities in changes of neutral lipids in peripheral blood mononuclear cells. *Exp Eye Res.* 2014;124(Supplement C):11-16. doi:10.1016/j.exer.2014.04.017
87. Klein R, Klein BEK, Tomany SC, Danforth LG, Cruickshanks KJ. Relation of Statin Use to the 5-Year Incidence and Progression of Age-Related Maculopathy. *Arch Ophthalmol.* 2003;121(8):1151-1155. doi:10.1001/archoph.121.8.1151
88. Chuo JY, Wiens M, Etminan M, Maberley DAL. Use of Lipid-Lowering Agents for the Prevention of Age-Related Macular Degeneration: A Meta-Analysis of Observational Studies. *Ophthalmic Epidemiol.* 2007;14(6):367-374. doi:10.1080/09286580701421684
89. Maguire MG, Ying G, McCannel CA, Liu C, Dai Y. Statin Use and the Incidence of Advanced Age-Related Macular Degeneration in the Complications of Age-Related Macular Degeneration Prevention Trial. *Ophthalmology.* 2009;116(12):2381-2385. doi:10.1016/j.ophtha.2009.06.055
90. Shalev V, Srur M, Goldshtein I, Kokia E, Chodick G. Statin Use and the Risk of Age Related Macular Degeneration in a Large Health Organization in Israel. *Ophthalmic Epidemiol.* 2011;18(2):83-90. doi:10.3109/09286586.2011.560746
91. Hamelin B. Hydrophilicity/ lipophilicity: relevance for the pharmacology and clinical effects of HMG-CoA reductase inhibitors. *Trends Pharmacol Sci.* 1998;19(1):26-37. doi:10.1016/S0165-6147(97)01147-4
92. Bonsu KO, Kadirvelu A, Reidpath DD. Lipophilic versus hydrophilic statin therapy for heart failure: a protocol for an adjusted indirect comparison meta-analysis. *Syst Rev.* 2013;2:22. doi:10.1186/2046-4053-2-22
93. Tian B, Al-Moujahed A, Bouzika P, et al. Atorvastatin Promotes Phagocytosis and Attenuates Pro-Inflammatory Response in Human Retinal Pigment Epithelial Cells. *Sci Rep.* 2017;7. doi:10.1038/s41598-017-02407-7
94. Qian J, Keyes KT, Long B, Chen G, Ye Y. Impact of HMG-CoA reductase inhibition on oxidant-induced injury in human retinal pigment epithelium cells. *J Cell Biochem.* 2011;112(9):2480-2489. doi:10.1002/jcb.23173
95. Kim KJ, Kim KS, Kim NR, Chin HS. Effects of Simvastatin on the Expression of Heme Oxygenase-1 in Human RPE Cells. *Invest Ophthalmol Vis Sci.* 2012;53(10):6456-6464. doi:10.1167/iovs.12-9658

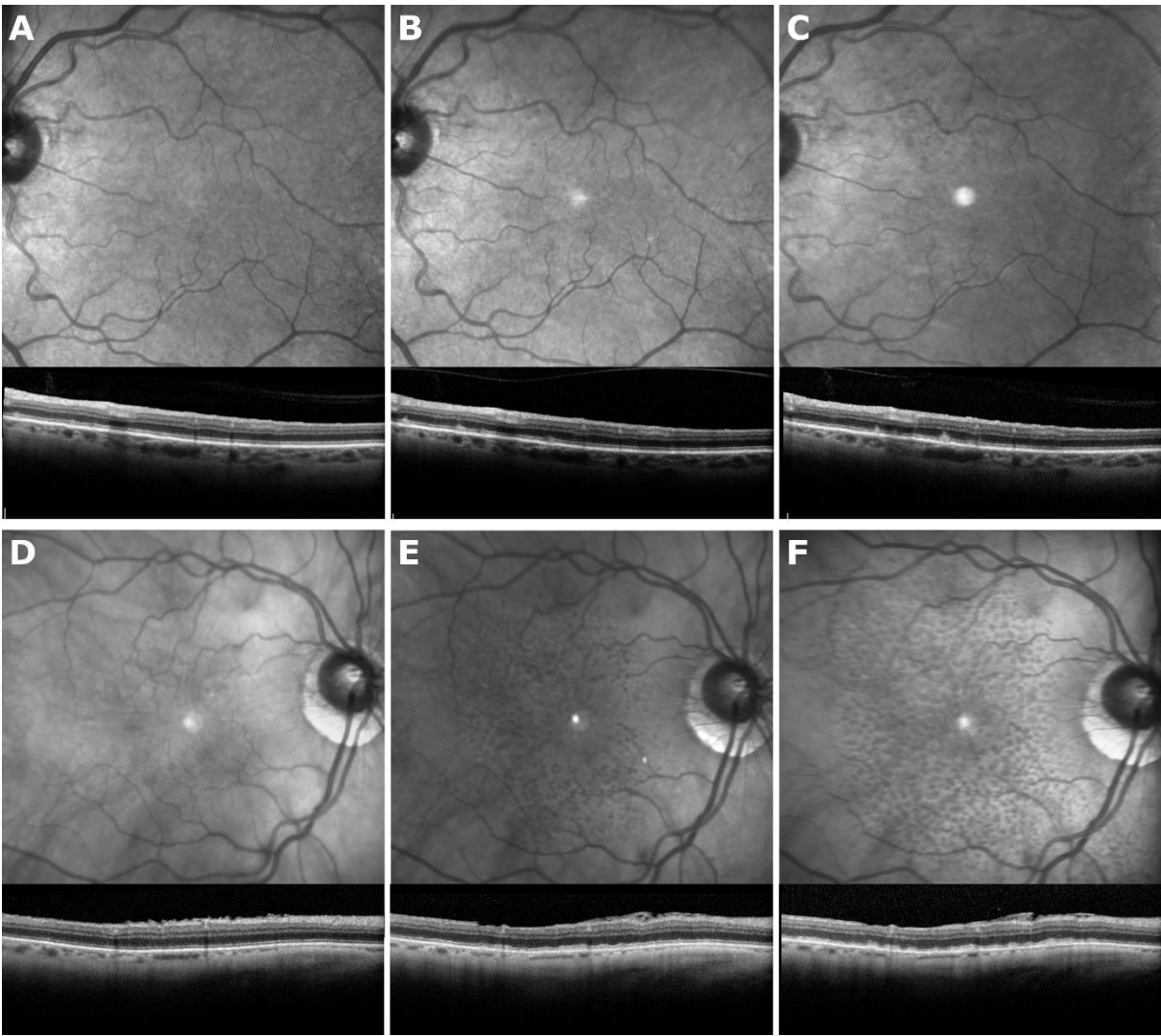
## FIGURES

**Figure 1: Reticular pseudodrusen in multimodal imaging**



**Figure 1.** Reticular Pseudodrusen (RPD) along the upper arcade of the macula, in multimodal imaging. **(A)** Color fundus photography with yellowish interlacing network. **(B)** Fundus autofluorescence (FAF) with a group of ill-defined hypofluorescent lesions. **(C)** Near-infrared reflectance (NIR) with a group of isorefectant lesions surrounded by halos of hyporefectance, responsible for the “target aspect”. **(D)** Spectral-domain optical coherence tomography (SD-OCT): horizontal line scan showing different stages of RPD with hyperreflective deposits between the retinal pigment epithelium and the ellipsoid zone (stage 1) or triangular deposits breaking through the ellipsoid zone (stage 3).

**Figure 2: Two patients with incident reticular pseudodrusen**



**Figure 2.** Images of two patients with incident Reticular Pseudodrusen (RPD). For each follow-up we decided to show the two most sensitive exams: Near-infrared reflectance (NIR) and Optical Coherence Tomography (OCT) acquired with following conditions. Two years passed between each follow-up and the appearance of typical images of RPD is visible for the first patient along the superior vascular arcades on the left eye (**A, B and C**) and for the second with a diffuse distribution on the right eye (**D, E and F**).

**TABLES**

**Table 1. Baseline characteristics of included and non-included eyes**

Characteristic	Eyes		P value
	Included (n= 472) N (%) or Mean $\pm$ SD	Non-included (n=532) N (%) or Mean $\pm$ SD	
Age, years	81.9 $\pm$ 3.2	84.4 $\pm$ 3.9	<b>&lt;0.0001</b>
Female sex	263 (55.7)	331 (62.2)	0.14
Education			0.52
None or primary	28 (5.9)	40 (7.6)	
Secondary	215 (45.6)	257 (48.5)	
High school or university	229 (48.5)	233 (44.0)	
Cataract extraction	230 (50.8)	298 (59.8)	0.98
Subfoveal Choroidal Thickness, $\mu$ m	220.1 $\pm$ 82.40	192.5 $\pm$ 76.68	0.12
Axial length, mm	23.5 $\pm$ 1.4	23.6 $\pm$ 1.5	0.76
Smoking status			0.12
Non-smoker	315 (67.6)	331 (62.9)	
<20 pack-year	64 (13.7)	108 (20.5)	
$\geq$ 20 pack-year	87 (18.7)	87 (16.5)	
Body Mass Index, kg/m <sup>2</sup>	26.2 $\pm$ 4.0	25.6 $\pm$ 4.2	0.11
Diabetes	41 (8.8)	67 (13.2)	0.11
Hypertension $\geq$ 140/90 mmHg	254 (57.9)	290 (60.3)	0.59
Antihypertensive therapy intake	296 (63.8)	338 (66.5)	0.52
Plasma lipid concentration, mmol/L			
Total cholesterol	5.38 $\pm$ 1.10	5.63 $\pm$ 1.16	<b>0.0204</b>
HDL cholesterol	1.46 $\pm$ 0.36	1.50 $\pm$ 0.39	0.31
LDL cholesterol	3.33 $\pm$ 0.95	3.52 $\pm$ 0.98	<b>0.0384</b>
Triglyceride	1.27 $\pm$ 0.50	1.32 $\pm$ 0.58	0.36
Statin therapy intake	141 (30.4)	145 (28.7)	0.67
Liposoluble	84 (18.1)	86 (17.0)	0.74
Water-soluble	57 (12.3)	59 (11.7)	0.83
Fibrate therapy intake	42 (9.0)	40 (7.9)	0.64
CFH rs1061170			0.44*
CC	51 (11.6)	53 (11.1)	
TC	179 (40.8)	223 (46.6)	
TT	209 (47.6)	203 (42.4)	
ARMS2 rs10490924			0.08*
GG	279 (69.6)	273 (64.2)	
GT	114 (28.4)	128 (30.1)	
TT	8 (2.0)	24 (5.6)	
C3 Factor rs2230199			0.06*
CC or GC	90 (23.1)	132 (31.9)	
GG	300 (76.9)	282 (68.1)	
B Factor rs641153			<b>0.05*</b>
AA or GA	122 (30.4)	100 (23.5)	
GG	279 (69.6)	325 (76.5)	
ApoE4	86 (19.3)	80 (16.4)	0.40

Characteristic	Eyes		P value
	Included (n= 472) N (%) or Mean $\pm$ SD	Non-included (n=532) N (%) or Mean $\pm$ SD	
<b>LIPC rs493258</b>			0.33*
CC	99 (24.7)	123 (28.9)	
CT	212 (52.9)	216 (50.8)	
TT	90 (22.4)	86 (20.2)	
<b>LIPC rs10468017</b>			0.20*
CC	192 (47.9)	228 (54.2)	
TC	179 (44.6)	167 (39.7)	
TT	30 (7.5)	26 (6.2)	
<b>LPL rs12678919</b>			0.57*
AA	290 (74.7)	326 (78.7)	
GG or AG	98 (25.3)	88 (21.3)	
<b>CETP rs3764261</b>			0.24*
AA	36 (9.1)	38 (9.1)	
AC	151 (38.3)	191 (45.9)	
CC	207 (52.5)	187 (44.9)	
<b>ABCA1 rs1883025</b>			0.19*
CC	212 (52.9)	226 (53.2)	
CT	160 (39.9)	148 (34.8)	
TT	29 (7.2)	51 (12.0)	

Bold values indicate significant difference  
 ABCA1= Adenosine triphosphate-Binding Cassette transporter 1; ApoE4= Apolipoprotein E4;  
 ARMS2= Age-Related Maculopathy Susceptibly 2; B Factor= Complement Factor B; C3 Factor=  
 Complement Factor C3; CETP= Cholesteryl Ester Transfer Protein; CFH= Complement Factor H;  
 HDL= high-density lipoprotein; LDL= low-density lipoprotein; LIPC= Lipase C precursor; LPL=  
 LipoProtein Lipase;  
 \* P value obtained by using generalized linear model

**Table 2. Annual and five-year cumulative incidence of reticular pseudodrusen per eye according to sex and age range in the ALIENOR Study, 2011-2017**

Characteristic	Number at risk	Annual Incidence % (95% CI)	5-Year Incidence
<b>Male sex</b>	209	1.512 (0.786-2.911)	7.28
<b>Female sex</b>	263	1.948 (1.287-2.947)	9.28
<b>77-79 years</b>	163	3.605 (2.225-5.840)	16.49
<b>80-84 years</b>	235	11.79 (4.364-31.87)	44.54
<b>85 + years</b>	74	14.69 (4.691-45.99)	52.03
<b>Total</b>	472	2.047 (1.373-3.051)	9.73

CI= Confidence Interval

**Table 3. Associations of incident Reticular Pseudodrusen per eye with potential risk factors in the ALIENOR Study, 2011-2017 (univariate model adjusted for gender)**

Characteristic	N	Eyes		HR (CI 95%)	P value	
		Incident /Non-incident	Incident RPD N(%) or Mean $\pm$ SD			Non-Incident RPD N(%) or Mean $\pm$ SD
Age, years	42/430		83.7 $\pm$ 3.3	81.7 $\pm$ 3.1		
Female sex	42/430		28 (65.1)	235 (54.8)	0.66 (0.28-1.53)	0.33
Education	42/430					0.49
None or primary			2 (4.6)	26 (6.1)		
Secondary			15 (34.9)	200 (46.6)	0.83 (0.11-6.44)	
High school or university			26 (60.5)	203 (47.3)	1.37 (0.18-10.17)	
Cataract extraction	41/412		28 (66.7)	202 (49.1)	1.75 (0.80-3.82)	0.16
Subfoveal Choroidal Thickness, $\mu$ m	40/408		186.48 $\pm$ 78.38	223.36 $\pm$ 82.13	1.05 (1.01-1.10) <sup>a</sup>	<b>0.0479</b>
Axial length, mm	42/430		23.17 $\pm$ 1.11	23.57 $\pm$ 1.40	0.80 (0.56-1.16)	0.24
Smoking status	40/426					0.14
Non-smoker			25 (61.0)	290 (68.2)		
<20 pack-year			3 (7.3)	61 (14.4)	0.72 (0.19-2.66)	
$\geq$ 20 pack-year			13 (31.7)	74 (17.4)	2.52 (0.87-7.24)	
Body Mass Index, kg/m <sup>2</sup>	43/405		26.2 $\pm$ 4.3	26.2 $\pm$ 4.0	1.02 (0.92-1.15)	0.67
Diabetes	42/422		3 (7.0)	38 (9.0)	0.52 (0.13-2.06)	0.35
Hypertension $\geq$ 140/90 mmHg	38/402		20 (52.6)	234 (58.4)	0.80 (0.35-1.83)	0.60
Antihypertensive therapy intake	42/422		28 (65.1)	268 (63.7)	1.22 (0.50-2.98)	0.66
Plasma lipid concentration mmol/L						
Total cholesterol	36/372		5.21 $\pm$ 1.21	5.40 $\pm$ 1.08	0.74 (0.43-1.29)	0.29
HDL cholesterol	36/372		1.9 $\pm$ 0.40	1.45 $\pm$ 0.35	2.54 (0.67-9.54)	0.17
LDL cholesterol	36/372		3.10 $\pm$ 1.01	3.36 $\pm$ 0.94	0.64 (0.37-1.11)	0.11
Triglyceride	36/372		1.15 $\pm$ 0.42	1.28 $\pm$ 0.51	0.59 (0.21-1.65)	0.32
Statin therapy intake	42/422		10 (23.3)	131 (31.1)	0.78 (0.30-2.00)	0.61
Liposoluble	42/422		1 (2.3)	83 (19.7)	0.13 (0.02-0.97)	<b>0.0467</b>
Water-soluble	42/422		9 (20.9)	48 (11.4)	2.00 (0.68-5.88)	0.21
Fibrate therapy intake	42/422		2 (4.6)	40 (9.5)	0.43 (0.08-2.40)	0.34
CFH rs1061170	40/399				1.96 (1.02-3.77)	<b>0.0441*</b>
CC (2)			11 (27.5)	41 (10.3)		
TC (1)			18 (45.0)	161 (40.4)		
TT (0)			11 (27.5)	197 (49.4)		
ARMS2 rs10490924	37/364				3.22 (1.53-6.77)	<b>0.0020*</b>
GG (0)			19 (51.4)	260 (71.4)		
GT (1)			13 (35.1)	101 (27.8)		
TT (2)			5 (13.5)	3 (0.8)		
C3 Factor rs2230199	37/353				1.20 (0.53-2.74)	0.66*
GG (0)			26 (70.3)	274 (77.6)		
GC (1)			11 (29.7)	75 (21.3)		
CC (2)			0	4 (1.1)		



Characteristic	N	Eyes		HR (CI 95%)	P value
		Incident /Non-incident	RPD N(%) or Mean $\pm$ SD		
<b>B Factor rs641153</b>	37/364			0.54 (0.19-1.49)	0.23*
GG (0)		30 (81.1)	249 (68.4)		
AG (1)		5 (13.5)	107 (29.4)		
AA (2)		2 (5.4)	8 (2.2)		
<b>ApoE4</b>	40/406	6 (14.6)	80 (19.8)	0.61 (0.19-1.96)	0.40
<b>LIPC rs493258</b>	37/364			1.47 (0.77-2.78)	0.24*
CC (0)		8 (21.6)	91 (25.0)		
CT (1)		16 (43.2)	197 (54.1)		
TT (2)		13 (35.1)	76 (20.9)		
<b>LIPC rs10468017</b>	37/364			2.11 (1.02-4.37)	<b>0.0442*</b>
CC (0)		14 (37.8)	178 (48.9)		
TC (1)		17 (46.0)	163 (44.8)		
TT (2)		6 (16.2)	23 (6.3)		
<b>LPL rs12678919</b>	33/355			0.35 (0.09-1.38)	0.14*
AA (0)		29 (87.9)	260 (73.2)		
AG (1)		4 (12.1)	93 (26.2)		
GG (2)		0	2 (0.6)		
<b>CETP rs3764261</b>	37/359			0.64 (0.27-1.54)	0.32*
AA (2)		3 (8.6)	33 (9.2)		
AC (1)		8 (22.8)	143 (39.8)		
CC (0)		24 (68.6)	183 (51.0)		
<b>ABCA1 rs1883025</b>	37/364			0.68 (0.28-1.64)	0.39*
CC (0)		24 (64.9)	188 (51.6)		
CT (1)		10 (27.0)	150 (41.2)		
TT (2)		3 (8.1)	26 (7.1)		

Bold values indicate significant HRs

ABCA1= Adenosine triphosphate-Binding Cassette transporter 1; ApoE4= Apolipoprotein E4; ARMS2= Age-Related Maculopathy Susceptibly 2; B Factor= Complement Factor B; C3 Factor= Complement Factor C3; CETP= Cholesteryl Ester Transfer Protein; CFH= Complement Factor H; CI= Confidence Interval; HDL= high-density lipoprotein; HR = Hazard Ratio; LDL= low-density lipoprotein; LIPC= Lipase C precursor; LPL= LipoProtein Lipase;

<sup>a</sup>HR per 10 microns decrease

\*HR obtained from the number of risk alleles (0,1,2)

**Table 4. Associations of incident Reticular Pseudodrusen per eye with potential risk factors in the ALIENOR Study, 2011-2017 (multivariate model)**

Characteristic	HR (95% CI)	P value
<b>ARMS2 rs10490924</b>	3.36 (1.64-6.88)	0.0009
<b>LIPC rs10468017</b>	2.65 (1.39-5.03)	0.0029
<b>Subfoveal Choroidal Thickness, <math>\mu</math>m</b>	1.06 (1.01-1.11) <sup>a</sup>	0.0085
<b>Liposoluble Statin therapy intake</b>	0.18 (0.03-0.96)	0.0448

ARMS2= Age-Related Maculopathy Susceptibly 2; CI= Confidence Interval; HR = Hazard Ratio; LIPC= Lipase C precursor

<sup>a</sup>HR per 10 microns decrease

Axial length and gender forced into the model

## V. SYNTHÈSE ET PERSPECTIVES

---

Notre étude met en évidence un taux d'incidence annuel de 2.047% pour les pseudodrusen réticulés chez les sujets bordelais de plus de 77 ans. Les facteurs de risque associés, mis en évidence lors de l'analyse multivariée étaient : la présence de l'allèle à risque du gène ARMS2 rs10490924, la présence de l'allèle à risque du gène LIPC rs10468017 et une épaisseur choroïdienne plus fine. La prise d'une statine liposoluble était un facteur protecteur.

Cette étude retrouve un taux d'incidence supérieur à ceux de la littérature (6.6% à 15 ans dans la Beaver Dam Eye Study<sup>8</sup> et 2.0% à 15 ans dans la Blue Mountains Eye Study<sup>9</sup>). Ceci s'explique en partie par l'utilisation d'une imagerie multimodale, avec une sensibilité diagnostique supérieure à celle des rétinophotographies seules. En revanche, notre suivi moyen de 3.7 ans est relativement court comparé aux précédentes études et il serait intéressant de poursuivre ce travail avec un suivi plus long. Toutefois, notre population étant vieillissante avec un nombre de perdus de vue augmentant à chaque suivi, la création d'une nouvelle cohorte plus jeune permettrait d'avoir un échantillon plus représentatif de la population générale.

En ce qui concerne le diagnostic, les imageries à notre disposition sont en constante progression et nous pourrions envisager une sensibilité et une spécificité diagnostique proche de 100% en 2018, ce qui n'était pas le cas à l'inclusion de nos données en 2011. Par exemple, les rétinographes ultra-grand champ permettent de visualiser 200° de la rétine avec des images en couleur ou en autofluorescence (**Annexe 3a**). Domalpally et al.<sup>11</sup> ont montré que la prévalence des pseudodrusen réticulés sur ces clichés 200° était de 11% versus 5% avec une image conventionnelle 45°. De même pour l'OCT, la possibilité d'enregistrer des volumes de 12 x 12 mm, a permis de montrer que 10% des pseudodrusen réticulés n'étaient pas diagnostiqués versus 14% pour un OCT classique 6 x 6 mm<sup>12</sup> (**Annexe 3b**). En effet, même s'ils sont souvent présents au niveau de l'arcade temporale supérieure, la répartition des pseudodrusen réticulés est variable, allant de la péri fovéa à la moyenne périphérie rétinienne, en passant par la zone péripapillaire.<sup>13</sup>

Par ailleurs, Van Grinsven et al.<sup>14</sup> ont montré qu'une automatisation du diagnostic était possible avec des performances similaires à une analyse manuelle.

Ainsi, de nombreux progrès diagnostics ont été réalisés au cours des dernières années concernant les pseudodrusen réticulés et la DMLA. Une des priorités devient donc l'identification des facteurs de risque, notamment génétiques. En effet, la recherche sur la thérapie génique dans la DMLA n'a pas permis d'établir de nouveau traitement à ce jour, mais l'augmentation du nombre d'études laisse un espoir pour les années à venir.<sup>15</sup> Une étude de plus grande envergure, multicentrique, permettrait d'augmenter la puissance statistique, souvent trop faible pour mettre en évidence les gènes associés aux pseudodrusen réticulés. De même, une meilleure identification des facteurs de risque modifiables, sur le modèle de l'étude AREDS<sup>16</sup>, permettrait d'envisager des mesures de prévention des pseudodrusen réticulés. En ce qui concerne l'association à une choroïde plus fine, d'une part notre étude la confirme et d'autre part, elle évoque la notion de temporalité avec une atteinte choroïdienne qui précéderait l'apparition des pseudodrusen. Même si cette relation a déjà été évoquée, il s'agit de la première étude épidémiologique la confirmant.<sup>7</sup> Toutefois, nous ne pouvons pas exclure la présence d'un tiers facteur non identifié.<sup>17</sup>

Par ailleurs, une analyse histologique et immunohistochimique plus fine, différenciant les sous types de pseudodrusen<sup>18</sup> (**Annexe 1c**), les différents stades<sup>19</sup> (**Annexe 1d**) ainsi que leur distinction dans une étude épidémiologique de grande envergure permettrait de mieux comprendre la physiopathologie et notamment l'influence des statines liposolubles.

A l'avenir, l'identification et la lutte contre les facteurs de risque modifiables des pseudodrusen réticulés pourraient permettre une diminution du risque d'évolution vers une forme sévère de DMLA. De plus, leur prise en compte dans une nouvelle classification de la DMLA permettrait de conforter l'intérêt de leur dépistage précoce en pratique clinique.

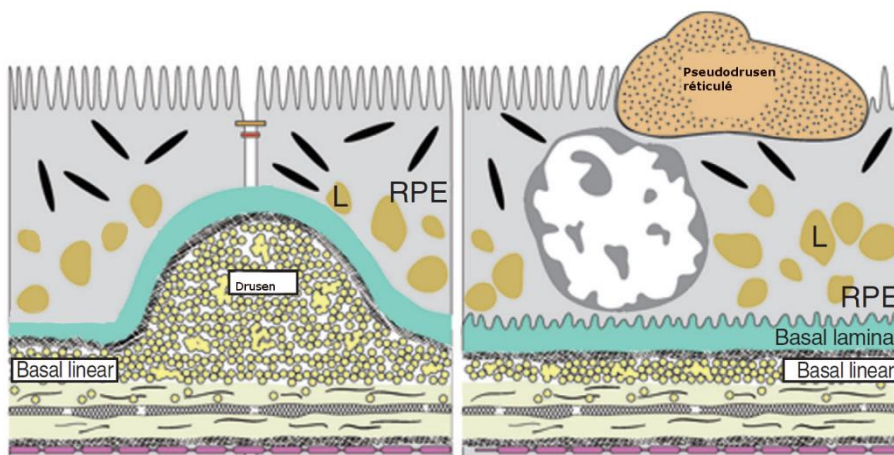
En conclusion, notre étude fondée sur l'imagerie multimodale apporte une vision européenne de l'incidence des pseudodrusen réticulés. Parmi les facteurs de risque décrits habituellement, nous avons mis en évidence dans l'analyse multivariée : la présence de l'allèle à risque de ARMS2 rs10409024 et une épaisseur choroïdienne plus fine. En revanche, deux associations n'ont jamais été décrites dans des études épidémiologiques : LIPC rs1046801 en tant que facteur de risque et la prise d'une statine liposoluble en tant que facteur protecteur. De nouvelles études, idéalement avec un effectif plus large, sont nécessaires afin de valider ces résultats.

## VI. ANNEXES

### A. Annexe 1 : Les pseudodrusen réticulés

#### a. *Pseudodrusen réticulés versus drusen*

Les pseudodrusen réticulés sont situés en avant de l'épithélium pigmentaire (RPE) à l'inverse des drusen, des « *basal linear deposit* » et de leurs précurseurs (« *basal laminar deposit* »), situés en arrière de l'épithélium pigmentaire.



**Figure 1 : Schéma comparatif pseudodrusen réticulés versus drusen.**

L : lipofuscine

RPE : rétinal pigment epithelium

Modifié d'après Andrew P. Schachat, *Rayan's RETINA Sixth Edition*, Elsevier, 2018, pp. 532

#### b. *Terminologie (d'après Spaide et al., 2018)*

Bien que le terme de « pseudodrusen visible en lumière bleue » fût le premier utilisé, d'autres dénominations ont été utilisées : pseudodrusen réticulés, drusen réticulés, maladie réticulée maculaire et dépôts drusénoïdes sous rétiniens. Les termes les plus cités sont « pseudodrusen réticulés » et « dépôts drusénoïdes sous rétiniens », en raison de la localisation pré épithéliale et sous rétinienne d'une part et des quelques caractéristiques communes avec les drusen d'autre part. Toutefois, le caractère réticulé ne correspond pas à la forme la plus fréquente, mais à celle décrite initialement au fond d'œil et d'un point de vue sémantique, il faudrait donc privilégier « dépôts drusénoïdes sous rétiniens ».

Dans ce travail, et dans l'attente d'un consensus, nous avons choisi de conserver le terme de « pseudodrusen réticulé », actuellement le plus cité.

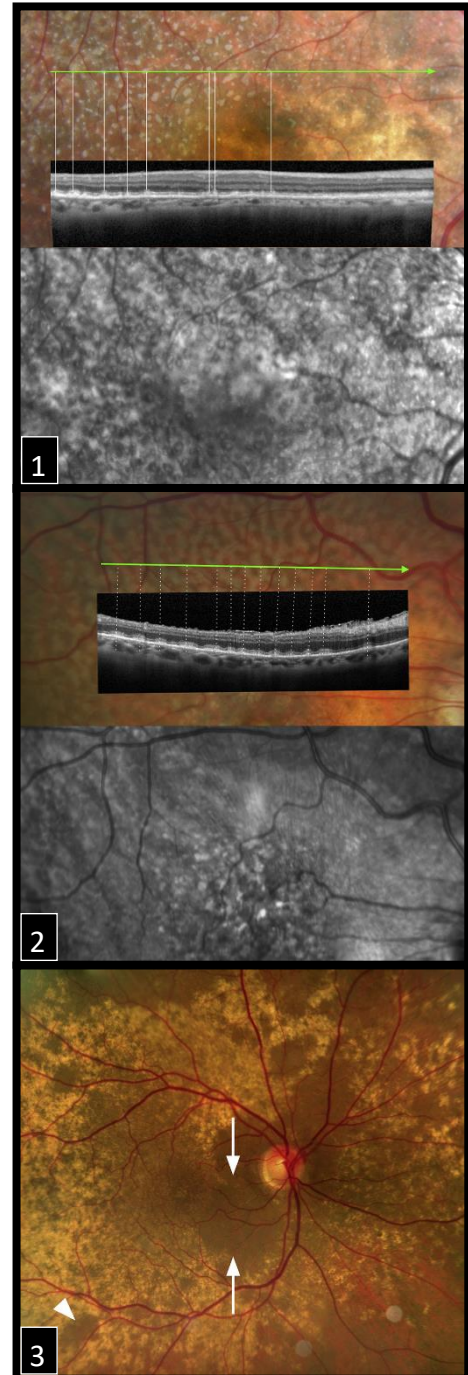
### c. Classification

Il existe plusieurs sous-types, classés selon leur apparence en imagerie multimodale par Suzuki et al., 2014.<sup>18</sup>

1) Les pseudodrusen punctiformes (« Dot »)  
*Ce sont les plus fréquents, ils sont généralement détectés avec les clichés en proche infrarouge et les rétino-photographies couleurs.*

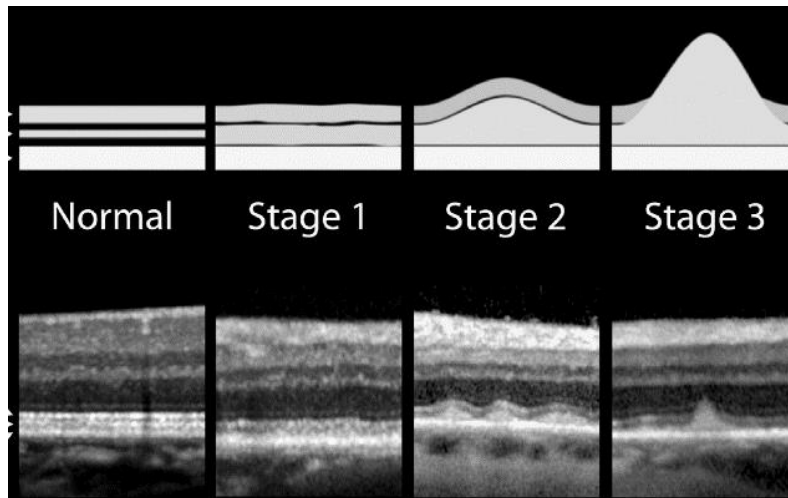
2) Les pseudodrusen en ruban (« Ribbon »)  
*Ils ressemblent à la description originale avec leur aspect réticulé. Ils sont généralement associés à la forme « Dot ». Ils sont mieux visualisés sur les rétino-photographies couleurs.*

3) Les pseudodrusen de la moyenne périphérie (« Mid-peripheral »)  
*Ils apparaissent petits, espacés sous forme de globules confluents localisés préférentiellement à l'extérieur des arcades vasculaires.*



**Figure 2 : Les différents sous-types de pseudodrusen**  
*Illustration adaptée de Suzuki et al., 2014<sup>18</sup>*

*d. Les différents stades décrits par Zweifel et al., 2010*



**Figure 3 : Les différents stades de pseudodrusen réticulés**

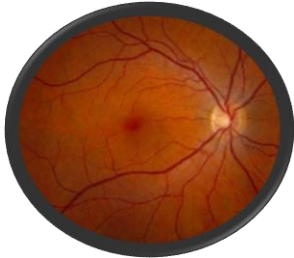
*Illustration extraite de Zweifel et al., 2010<sup>19</sup>*

La figure 3 présente les différents stades de pseudodrusen réticulés décrits par Zweifel et al.<sup>19</sup> Cette classification est fondée sur l'OCT et la localisation de la limite supérieure du matériel hyper réfléchif par rapport à la ligne IS/OS (limite entre les segments internes et externes des photorécepteurs)

- **Stade 1** : dépôt diffus de matériel hyper réfléchif granulaire entre l'épithélium pigmentaire et la ligne IS/OS
- **Stade 2** : accumulation de matériel suffisant pour altérer la ligne IS/OS
- **Stade 3** : apparence conique du matériel, qui interrompt la ligne IS/OS

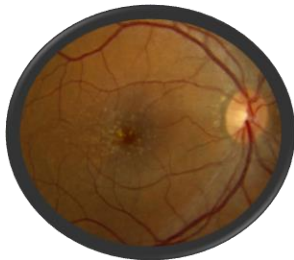## B. Annexe 2 : Classifications et DMLA

La dégénérescence maculaire liée à l'âge a été décrite à travers plusieurs classifications ayant évoluées avec l'apport de nouvelles connaissances. La figure 4 présente celle de Ferris et al.<sup>20</sup>



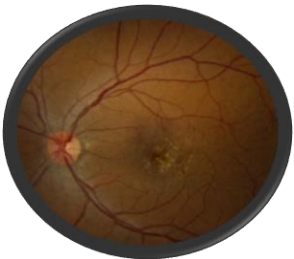### Absence de modifications liées à l'âge

- Pas de drusen **et**
- Pas d'anomalie pigmentaire liée à la DMLA\*



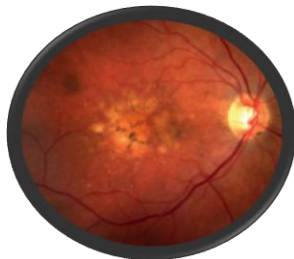### Modifications normales liées à l'âge

- Seulement des drusen  $\leq 63\mu\text{m}$  **et**
- Pas d'anomalie pigmentaire liée à la DMLA\*



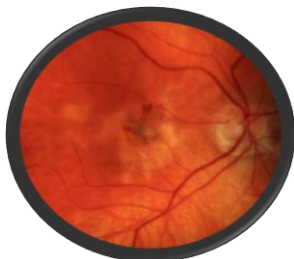### DMLA précoce

- Drusen entre 63 et 125  $\mu\text{m}$  **et**
- Pas d'anomalie pigmentaire liée à la DMLA\*



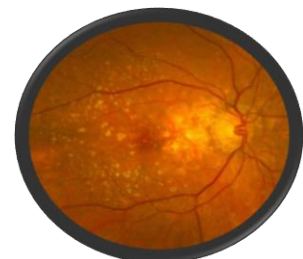### DMLA intermédiaire

- Drusen  $> 125\mu\text{m}$  **et/ou**
- N'importe quelle anomalie pigmentaire liée à la DMLA\*



### DMLA avancée

- DMLA néovasculaire **et/ou**
  - Atrophie géographique
- # prévalence élevée avec les pseudodrusen

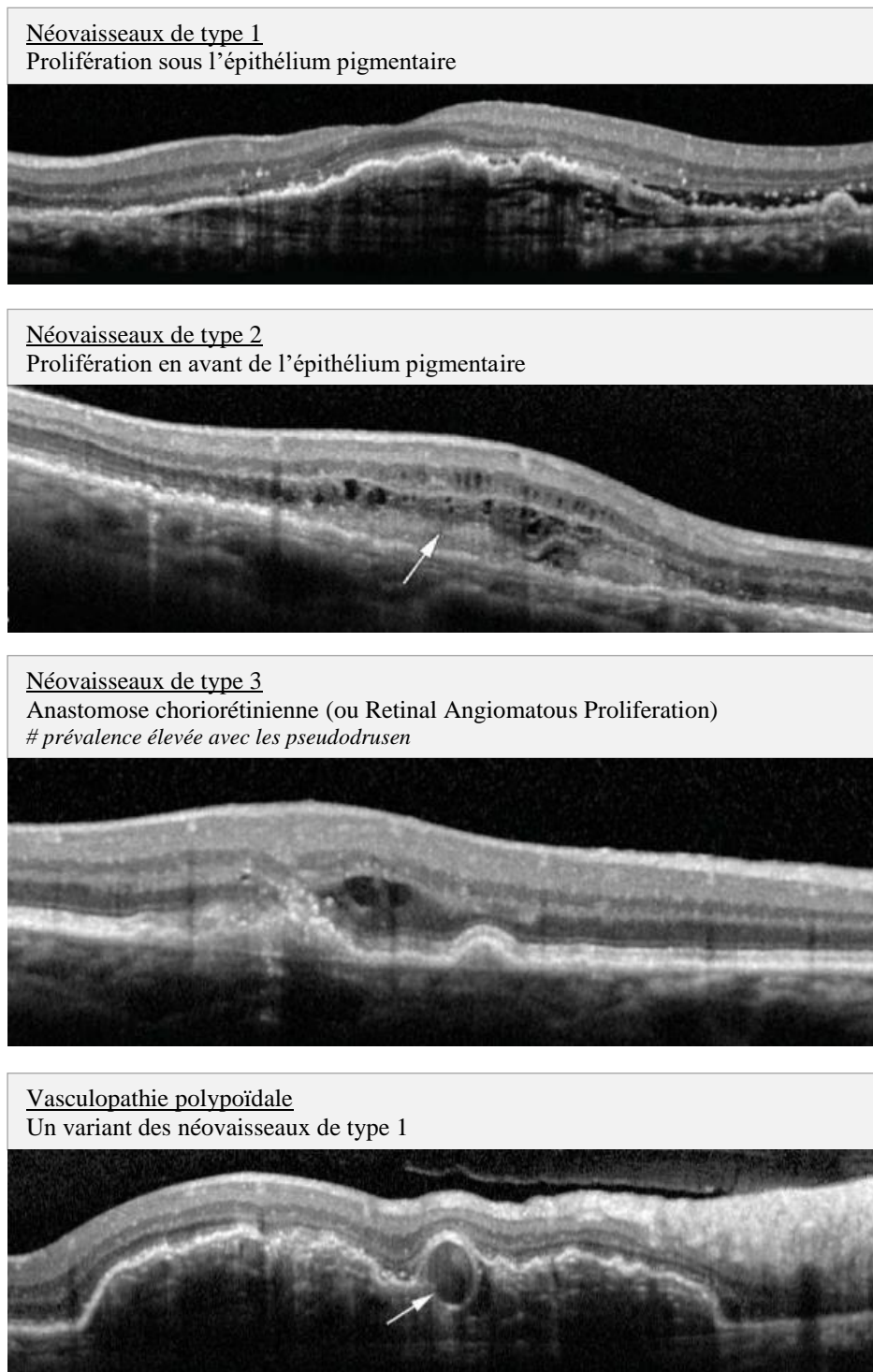


*\*Anomalies pigmentaire liée à la DMLA = hyper ou hypo pigmentation associée à des drusen, en l'absence d'autre pathologie maculaire connue*

**Figure 4. Classification de la DMLA selon Ferris et al., 2013<sup>20</sup>**



La figure 5 présente la classification des néovaisseaux dans la DMLA exsudative, par Freund et al.<sup>21</sup>



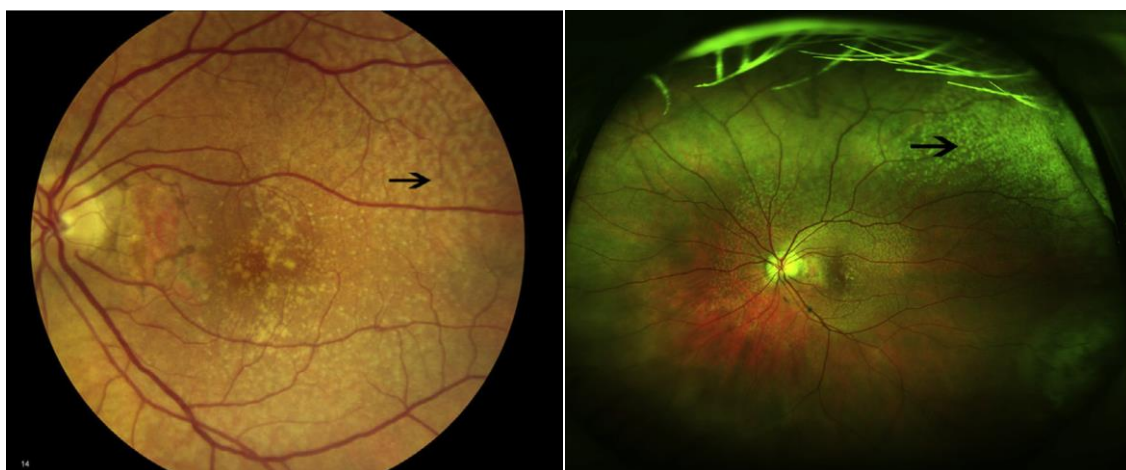
**Figure 5 : Classification des néovaisseaux d'après Freund et al., 2010<sup>21</sup>**



### C. Annexe 3 : Nouvelles imageries

#### a. *L'imagerie ultra-grand champ*

L'image de gauche est une rétinothographie couleur standard de 30° et l'image de droite est une image du fond d'œil ultra-grand champ de 200°. Les flèches correspondent à des pseudodrusen réticulés.



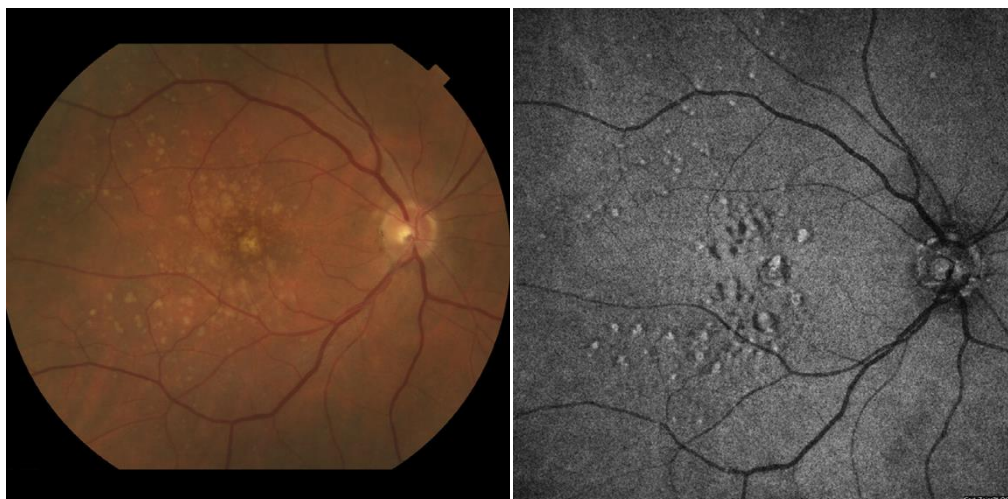**Figure 6 : Les pseudodrusen et l'imagerie ultra-grand champ : œil gauche d'un patient atteint de DMLA et présentant des pseudodrusen réticulés**

*Illustrations extraites de Domalpally et al., 2017<sup>11</sup>*

### ***b. L'OCT grand champ***

L'image de gauche est une rétinophotographie couleur standard de 45° sur laquelle les dépôts jaunâtres sont compatibles avec des drusen classiques et pseudodrusen réticulés.

L'OCT en face (12 x 12 mm) à droite, avec une segmentation de 20 microns située en avant de l'épithélium pigmentaire rétinien, met en évidence des zones d'hyper réflectivité focales, typiques des pseudodrusen réticulés.



**Figure 7 : Les pseudodrusen en OCT en face grand champ : œil droit d'un patient de 76 ans atteint de DMLA et présentant des pseudodrusen réticulés**

*Illustrations extraites de Schaal et al., 2017<sup>12</sup>*

## D. Annexe 4 : Facteurs associés décrits dans la littérature

Source	Study type	Country	Number of participants	Sex (%male)	Mean age (years)	Diagnosis method	Main inclusion criteria	Incidence (%)	Prevalence (%)	Significant associated factor	Non-significant factor
Arnold et al., 1995 <sup>3</sup>	Case series	Australia	100	NA	NA	RFP	NA	NA	NA	Age, female gender, choroidal ischemia, neovascular AMD	NA
Alten et al., 2012 <sup>22</sup>	Case series	Germany	102	30,4	75	NIR, SD-OCT	PED	NA	53,9	Age, female gender	Type of PED
Alten et al., 2016 <sup>23</sup>	Case-control	Germany	20	35	78,9	NIR, SD-OCT	RPD	NA	100	CC vessel density	NA
Boddu et al., 2014 <sup>24</sup>	Cross-sectional	US	30	16,7	87	NIR, AF, SD-OCT	AMD + RPD	NA	NA	Age, female gender, AMD	Smoking, hypertension, hyperlipidemia, diabetes, ARMS, CFH
Buitendijk et al., 2016 <sup>25</sup>	Cohort	Netherlands	2774	45,4	75	NIR, RFP	Rotterdam study	NA	4,9	Age, female gender, CFH, ARMS2, C2/B, C3, VEGFA	hyperlipidemia, education, hypertension, diabetes, CFI, LPL, LIPC, ABCA1, CETP, TIMP3...
Capuano et al., 2016 <sup>26</sup>	Case-control	France	90	35,5	79,7	FAF, SS-OCT	Early AMD	NA	32,4	Choroidal thickness	NA
Chan et al., 2016 <sup>6</sup>	Cohort	France	494	41	83	RFP, FAF, SD-OCT, NIR	NA	NA	13,4	Age, female gender, AMD	NA
Chang et al., 2016 <sup>27</sup>	Case series	South Korea	81	25,9	74,7	RFP, FAF, SD-OCT, NIR, FA, ICGA	RAP	NA	55,6	RAP	NA
Cho et al., 2015 <sup>28</sup>	Case series	South Korea	43	47,4	74,8	RFP, FAF, SD-OCT, NIR, FA, ICGA	RAP	NA	60,5	RAP, GA	NA
Cicinelli et al., 2017 <sup>29</sup>	Cross-sectional	Italy	45	47,1	74,2	RFP, FAF, SD-OCT, NIR, FA, ICGA	Non-neovascular AMD	NR	NR	Choroidal thickness (all layers)	NA
Cohen et al., 2007 <sup>5</sup>	Case series	France	100	23	79,2	RFP, FA, ICGA	RPD	NA	100,0	RAP, AMD	Age, female gender
Corvi et al., 2017 <sup>30</sup>	Case-control	Italy	18	31,8	76,6	SD-OCT	Drusen, RPD	NA	NA	Total choroidal (luminal and stroma) reduced	NA
Curcio et al., 2013 <sup>31</sup>	Histology	US	22	40	83,1	Histology	AMD	NA	NA	AMD	NA
Cymerman et al., 2016 <sup>32</sup>	Cohort	US	76	52,6	66,7	NIR, SD-OCT	Coronary artery disease	NA	NA	Coronary artery disease	NA
De Bats et al., 2013 <sup>33</sup>	Case series	France	8	0	40	RFP, SD-OCT, FA, ICGA	Early Onset Drusen	NA	NA	Early Onset Drusen	NA
De Bats et al., 2016 <sup>34</sup>	Case series	France	125	30,2	81,1	RFP, FAF, SD-OCT, NIR	AMD	NA	68,8	Choroidal thickness, macular fibrosis, soft drusen	Age, female gender, visual acuity
Elfandi et al., 2016 <sup>35</sup>	Case series	Japan	101	46,5	82,1	RFP, FAF, SD-OCT, NIR, FA, ICGA	AMD + RPD	NA	100	NA	CFH, ARMS2 (no influence on RPD classification)
Finger et al., 2014 <sup>36</sup>	Case series	Australia	200	31	77	RFP, FAF, SD-OCT, NIR, FA, ICGA	Unilateral neovascular AMD	NA	58	GA	NA

Source	Study type	Country	Number of participants	Sex (%male)	Mean age (years)	Diagnosis method	Main inclusion criteria	Incidence (%)	Prevalence (%)	Significant associated factor	Non-significant factor
Finger et al.,2016 <sup>37</sup>	Cohort	Australia	21130	40	77	RFP	Melbourne Collaborative Cohort Study	NA	0,41	Age, female gender, current smoking, AMD: pigment abnormalities, large drusen, GA, CNV, ARMS2, HTRAI, CFH	Education, hypertension, coronary artery disease
Garg et al.,2013 <sup>38</sup>	Cross-sectional	US	84	20	76,9	RFP, NIR, AF, SD-OCT	Early AMD + RPD	NA	NA	Choroidal thickness	NA
Garg et al.,2017 <sup>39</sup>	Cross-sectional	US	78	21	76,7	RFP, NIR, AF, SD-OCT	Early AMD + RPD	NA	NA	Beta-peripapillary atrophy	NA
Gil et al.,2017 <sup>40</sup>	Case series	Portugal	88	45,4	75,6	RFP, FAF, SD-OCT, NIR, FA, ICGA	Unilateral neovascular AMD	NA	58	Late AMD (progression)	NA
Haas et al.,2014 <sup>41</sup>	Case series	Austria	25	32	77,5	RFP, NIR, AF, SD-OCT, SS-OCT	RPD	NA	NA	Choroidal thickness (Sattler's and Haller's layers)	NA
Hogg et al.,2014 <sup>42</sup>	Cohort	UK	105	50	75,6	RFP, NIR, AF, SD-OCT	Unilateral neovascular AMD	NA	41	Drusen, pigment abnormalities, early AMD, retinal and choroidal thickness	Age, BMI, female gender, hypertension, coronary artery disease, hyperlipidemia, current smoker, visual acuity, SKILL score
Huisingh et al.,2016 <sup>43</sup>	Cohort	US	455	34,7	68,6	NIR, AF, SD-OCT	ALSTAR cohort	NA	25,5	Age, AMD	Female gender, race, BMI, education, current smoker, alcohol consumption, CRP, visual acuity
Joachim et al.,2014 <sup>9</sup>	Cohort	Australia	3654	43,4	63,4	RFP	BMES	4 (15-year)	1,95	Age, female gender, CFH, ARMS2, HDL, TG, current smoker	Hypertension, total cholesterol, alcohol consumption, vitamin supplementation
Kim et al.,2015 <sup>44</sup>	Cross-sectional	South Korea	321	66,4	69,9	RFP, FAF, SD-OCT, NIR, FA, ICGA	Neovascular AMD	NA	14,6	RAP (stronger association with ribbon RPD)	NA
Klein et al.,2008 <sup>45</sup>	Cohort	US	4926	41,8	56,8	RFP	BDES	3,0 (15-year)	0,70%	Age, female gender, smoking status, education, income, B vitamin use, diabetes history (decreased risk), steroid eye drops, glaucoma, drusen type, CFH, Vitamin E use, GA, Exudative AMD, sedentary lifestyle, anti-depressants use	Alcohol consumption, UV-exposure, hypertension, BMI, hyperlipidemia, coronary artery disease, cataract surgery
Kovach et al.,2016 <sup>46</sup>	Cohort	US	1178	NA	NA	RFP, NIR, AF, SD-OCT	AMD	NA	17%	Late AMD	NA
Lee et al.,2012 <sup>47</sup>	Case series	South Korea	233	11,6	71,4	RFP, NIR, AF, SD-OCT	RPD	NA	100	Diffuse RPD and late AMD	NA

Source	Study type	Country	Number of participants	Sex (%male)	Mean age (years)	Diagnosis method	Main inclusion criteria	Incidence (%)	Prevalence (%)	Significant associated factor	Non-significant factor
Leisy et al.,2017 <sup>48</sup>	Cohort	US	119	NA	75	SD-OCT	AMD	NA	NA	Glomerular filtration rate, age, erythrocyte sedimentation rate, choroidal thickness	BMI, hyperlipidemia, female gender, smoking status, diabetes mellitus, hypertension, coronary artery disease
Lin et al.,2018 <sup>49</sup>	Cohort	US	755	37,6	78	RFP, NIR, AF, FA	Post hoc analysis CATT	NA	28,2	ARMS2, HTRA1, CFH Y402H(protector), C3 (protector)	LIPC, CFB, C2, CFH I62V
Marsiglia et al.,2013 <sup>50</sup>	Cohort	US	126	25	81,9	NIR, AF, SD-OCT	GA	NA	93,6	GA progression	NA
Marsiglia et al.,2015 <sup>51</sup>	Case series	US	83	28,9	87	RFP, FA, SD-OCT	Exudative AMD	NA	NA	Type 3 CNV, Type CNV (protector)	Age, female gender, smoking status, hypertension, statin intake
McCarter et al.,2017 <sup>52</sup>	Cohort	UK	534	56	58	UWF retinal imaging	Sub study of clinical trial: SCOT-HEART (coronary artery disease)	NA	5,6	Large Drusen, intermediate AMD	Age, female gender, BMI, coronary artery disease, Hypertension, diabetes, smoking status
Mitchell et al.,2002 <sup>53</sup>	Cohort	Australia	2335	62,5	64,5	RFP	BMES	2 (5-year)	NA	NA	NA
Mrejen et al.,2014 <sup>17</sup>	Case series	US	96	32,1	83,7	RFP, NIR, AF, SD-OCT	High myopia or RPD	NA	NA	Age, choroidal thickness (broad peak between 50µm and 100µm)	NA
Naysan et al.,2016 <sup>54</sup>	Cohort	US	694	37,5	81	RFP, NIR, FA, AF, SD-OCT, ultrawide field retinal imaging	Type 2 CNV	NA	88	Type 2 CNV	NA
Puche et al.,2013 <sup>55</sup>	Cohort	France	519	29,5	77,4	RFP, NIR, AF, SD-OCT	AMD	NA	NA	CFH, ARMS2, C3	Age, smoking status, hypertension, hyperlipidemia, diabetes, AMD history, apoE4
Pumariega et al.,2011 <sup>56</sup>	Cohort	France	271	36,9	74,1	RFP, NIR, AF, FA, ICGA	AMD (NAT 2 Study)	NA	NA	Late AMD progression (CNV, GA)	NA
Querques et al.,2012 <sup>57</sup>	Case-control	France	22	40,9	82,5	RFP, FA, ICGA, SD-OCT	AMD + RPD	NA	NA	Refractive error, choroidal thickness	Visual acuity
Sarks et al.,2011 <sup>58</sup>	Case series	Australia	166	19,3	73,3	RFP, AF, NIR, FA, SD-OCT	RPD	NA	NA	Late AMD progression	NA
Sawa et al.,2014 <sup>59</sup>	Case series	Japan	20	40	83	RFP, AF, NIR, FA, ICGA, SD-OCT	Unilateral Type 3 CNV	NA	55	Type 3 CNV	NA
Ravera et al.,2016 <sup>60</sup>	Cross-sectional	Italy	30	NA	NA	RFP, NIR, FA, ICGA, SD-OCT	Neovascular AMD	NA	NA	Type 3 CNV	NA

Source	Study type	Country	Number of participants	Sex (%male)	Mean age (years)	Diagnosis method	Main inclusion criteria	Incidence (%)	Prevalence (%)	Significant associated factor	Non-significant factor
Schmitz-Valckengerg et al.,2011 <sup>4</sup>	Cohort	Germany	458	40	78	RFP, NIR, AF	GA (Geographic Atrophy Progression Study)	NA	62	Age, female gender	GA
Smith et al.,2009 <sup>61</sup>	Cross-sectional	US	42	21	80	RFP, NIR, AF, ICGA	RPD	NA	NA	Age, female gender, late AMD progression	NA
Smith et al.,2011 <sup>62</sup>	Cross-sectional	US	67	20,9	83	RFP, NIR, AF, ICGA	RPD	NA	NA	ARMS2	CFH
Sohrab et al.,2011 <sup>63</sup>	Cross-sectional	US	153	20	83	RFP, NIR, AF, SD-OCT	AMD	NA	33,3	Female gender, topography (intervascular choroidal stroma)	NA
Spaide, 2016 <sup>64</sup>	Case series	US	104	43,7	71	OCT-A	Interpretable OCTA	NA	10,6	Flow voids (choriocapillaris)	NA
Steinberg et al.,2015 <sup>65</sup>	Cohort	Germany	98	30	73,4	RFP, NIR, AF, SD-OCT	Early AMD	16,6	43,9	Age, female gender	AREDS stage, late AMD progression, contralateral eye involvement
Ueda-Arakawa et al.,2013 <sup>66</sup>	Case series	Japan	216	75	73,9	RFP, NIR, AF, SD-OCT	Late AMD	NA	11,3	Type 3 CNV, GA, ARMS2	CFH
Ueda-Arakawa et al.,2014 <sup>67</sup>	Cross-sectional	Japan	63	50	79,4	RFP, NIR, AF, SD-OCT, FA, SS-OCT	RPD	NA	NA	Choroidal thickness and volume, choroidal vasculature	NA
Wilde et al.,2016 <sup>68</sup>	Case series	UK	231	43,3	80,4	RFP, NIR, AF, SD-OCT, FA	Neovascular AMD	NA	22,1	Female gender	Age, CNV type, Type 3 CNV
Wu et al.,2016 <sup>69</sup>	Cohort	Australia	300	27,7	70,6	RFP, NIR, AF, SD-OCT	Bilateral large drusen	NA	29	Age, ARMS2, GA	Female gender, smoking history, hypertension, atherosclerosis, hypercholesterolemia, CFH
Xu et al.,2013 <sup>70</sup>	Case series	US	157	22,2	81,8	RFP, NIR, AF, SD-OCT	GA	NA	93	GA progression	NA
Yoneyama et al.,2014 <sup>71</sup>	Case series	Japan	408	72,3	74,9	RFP, NIR, AF, FA, ICGA, SD-OCT	Exudative AMD	NA	6,8	Age, female gender, type 3 CNV, choroidal thickness, ARMS2	CFH
Yun et al.,2016 <sup>72</sup>	Case series	South Korea	89	30,3	70,3	RFP, NIR, AF, FA, ICGA, SD-OCT	Early AMD	NA	47,2	Age, female gender, choroidal thickness	Lens status, refractive error, hypertension, diabetes, AMD stage, drusen
Yun et al.,2016 <sup>73</sup>	Case series	South Korea	103	33	72,4	RFP, NIR, AF, SD-OCT	Early AMD	NA	43,7	Age, female gender, choroidal thickness	Ocular perfusion pressure, lens status, refractive error, hypertension, diabetes, AMD stage, drusen

Source	Study type	Country	Number of participants	Sex (%male)	Mean age (years)	Diagnosis method	Main inclusion criteria	Incidence (%)	Prevalence (%)	Significant associated factor	Non-significant factor
Zarubina et al.,2016 <sup>74</sup>	Cross-sectional	US	651	33,2	70,6	RFP, NIR, AF, SD-OCT	Alabama Study of Early AMD	32	Age, AMD	Female gender, race, education, smoking status, alcohol consumption, cardiovascular disease, hypertension, statin use	NA
Zheng et al.,2016 <sup>75</sup>	Case series	US	25	NA	72,1	SS-OCT	Non-exudative AMD	NA	NA	Choroidal thickness, vessel density	NA
Zweifel et al.,2010 <sup>76</sup>	Case-control	US	153	34,6	80,3	RFP, NIR, AF, SD-OCT	AMD	NA	8,7 - 38,4	Late AMD	NA

**Tableau 1 : Synthèse des principales études rapportant les facteurs associés aux pseudodrusen réticulés.**

ABCA1 : Adenosine triphosphate-Binding Cassette subfamily A member 1, AMD: Age Macular Degeneration, ApoE4: Apolipoprotein E4, AREDS: Age-Related Eye Disease Study, ARMS: Age-Related Maculopathy Susceptibility, BMI: Body Mass Index, CC: Choriocapillaris, CETP: Cholesteryl Ester Transfer Protein, CFH: Complement Factor H, CFI: Complement Factor I, CNV: Choroidal Neovascularization, CRP: C-Reactive Protein, FA: Fluorescein Angiography, FAF: Fundus Autofluorescence, GA: Geographic Atrophy, HDL: High-Density Lipoprotein, HTRA1: High-Temperature Requirement A Serine Peptidase 1, ICGA: Indocyanin Green Angiography, LIPC: Lipase C precursor, LPL: LipoProtein Lipase, NA : Non Available, NIR : Near Infrared Reflectance, PED: Pigment Epithelial Detachment, RAP: Retinal Angiomatous Proliferation, RFP : Retinal Fundus Photography, RPD: Reticular Pseudodrusen, SKILL: Smith-Kettlewell Institute Low Luminance, SD-OCT : Spectral-Domain Optical Coherence Tomography, SS-OCT : Swept-Source Optical Coherence Tomography, TG: Triglycerides, TIMP3: Tissue Inhibitor Of Metalloproteinases 3

## VII. BIBLIOGRAPHIE

---

1. Bourne RRA, Stevens GA, White RA, et al. Causes of vision loss worldwide, 1990–2010: a systematic analysis. *The Lancet Global Health*. 2013;1(6):e339-e349. doi:10.1016/S2214-109X(13)70113-X
2. Mimoun G, Soubrane G, Coscas G. [Macular drusen]. *J Fr Ophthalmol*. 1990;13(10):511-530.
3. Arnold JJ, Sarks SH, Killingsworth MC, Sarks JP. Reticular pseudodrusen. A risk factor in age-related maculopathy. *Retina (Philadelphia, Pa)*. 1995;15(3):183-191.
4. Schmitz-Valckenberg S, Alten F, Steinberg JS, et al. Reticular Drusen Associated with Geographic Atrophy in Age-Related Macular Degeneration. *Invest Ophthalmol Vis Sci*. 2011;52(9):5009-5015. doi:10.1167/iovs.11-7235
5. Cohen SY, Dubois L, Tadayoni R, Delahaye-Mazza C, Debibie C, Quentel G. Prevalence of reticular pseudodrusen in age-related macular degeneration with newly diagnosed choroidal neovascularisation. *Br J Ophthalmol*. 2007;91(3):354-359. doi:10.1136/bjo.2006.101022
6. Chan H, Cougnard-Grégoire A, Delyfer M-N, et al. Multimodal Imaging of Reticular Pseudodrusen in a Population-Based Setting: The Alienor Study. *Invest Ophthalmol Vis Sci*. 2016;57(7):3058-3065. doi:10.1167/iovs.16-19487
7. Sivaprasad S, Bird A, Nitiahpapand R, Nicholson L, Hykin P, Chatziralli I. Perspectives on reticular pseudodrusen in age-related macular degeneration. *Survey of Ophthalmology*. 2016;61(5):521-537. doi:10.1016/j.survophthal.2016.02.005
8. Klein R, Meuer SM, Knudtson MD, Iyengar SK, Klein BEK. The Epidemiology of Retinal Reticular Drusen. *Am J Ophthalmol*. 2008;145(2):317-326. doi:10.1016/j.ajo.2007.09.008
9. Joachim N, Mitchell P, Rochtchina E, Tan AG, Wang JJ. Incidence and Progression of Reticular Drusen in Age-related Macular Degeneration. *Ophthalmology*. 2014;121(4):917-925. doi:10.1016/j.ophtha.2013.10.043
10. Seddon JM, Reynolds R, Yu Y, Daly MJ, Rosner B. Risk Models for Progression to Advanced Age-Related Macular Degeneration Using Demographic, Environmental, Genetic, and Ocular Factors. *Ophthalmology*. 2011;118(11):2203-2211. doi:10.1016/j.ophtha.2011.04.029
11. Domalpally A, Clemons TE, Danis RP, et al. Peripheral Retinal Changes Associated with Age-Related Macular Degeneration in the Age-Related Eye Disease Study 2: Age-Related Eye Disease Study 2 Report Number 12 by the Age-Related Eye Disease Study 2 Optos PEripheral RetinA (OPERA) Study Research Group\*. *Ophthalmology*. 2017;124(4):479-487. doi:10.1016/j.ophtha.2016.12.004
12. Schaal KB, Legarreta AD, Feuer WJ, et al. Comparison between Widefield En Face Swept-Source OCT and Conventional Multimodal Imaging for the Detection of Reticular Pseudodrusen. *Ophthalmology*. 2017;124(2):205-214. doi:10.1016/j.ophtha.2016.10.009



13. Spaide RF, Ooto S, Curcio CA. Subretinal Drusenoid Deposits AKA Pseudodrusen. *Survey of Ophthalmology*. May 2018. doi:10.1016/j.survophthal.2018.05.005
14. van Grinsven MJJP, Buitendijk GHS, Brussee C, et al. Automatic identification of reticular pseudodrusen using multimodal retinal image analysis. *Invest Ophthalmol Vis Sci*. 2015;56(1):633-639. doi:10.1167/iovs.14-15019
15. Moore NA, Bracha P, Hussain RM, Morral N, Ciulla TA. Gene therapy for age-related macular degeneration. *Expert Opinion on Biological Therapy*. 2017;17(10):1235-1244. doi:10.1080/14712598.2017.1356817
16. The Age-Related Eye Disease Study (AREDS): Design Implications AREDS Report No. 1. *Control Clin Trials*. 1999;20(6):573-600.
17. Mrejen S, Spaide RF. The relationship between pseudodrusen and choroidal thickness. *Retina*. 2014;34(8):1560–1566.
18. Suzuki M, Sato T, Spaide RF. Pseudodrusen Subtypes as Delineated by Multimodal Imaging of the Fundus. *American Journal of Ophthalmology*. 2014;157(5):1005-1012. doi:10.1016/j.ajo.2014.01.025
19. Zweifel SA, Spaide RF, Curcio CA, Malek G, Imamura Y. Reticular Pseudodrusen Are Subretinal Drusenoid Deposits. *Ophthalmology*. 2010;117(2):303-312.e1. doi:10.1016/j.ophtha.2009.07.014
20. Ferris FL, Wilkinson CP, Bird A, et al. Clinical Classification of Age-related Macular Degeneration. *Ophthalmology*. 2013;120(4):844-851. doi:10.1016/j.ophtha.2012.10.036
21. Freund KB, Zweifel SA, Engelbert M. Do We Need a New Classification for Choroidal Neovascularization in Age-Related Macular Degeneration?: *Retina*. 2010;30(9):1333-1349. doi:10.1097/IAE.0b013e3181e7976b
22. Alten F, Clemens CR, Milojcic C, Eter N. SUBRETINAL DRUSENOID DEPOSITS ASSOCIATED WITH PIGMENT EPITHELIUM DETACHMENT IN AGE-RELATED MACULAR DEGENERATION: *Retina*. 2012;32(9):1727-1732. doi:10.1097/IAE.0b013e3182475b03
23. Alten F, Heiduschka P, Clemens CR, Eter N. Exploring choriocapillaris under reticular pseudodrusen using OCT-Angiography. *Graefes Arch Clin Exp Ophthalmol*. 2016;254(11):2165-2173. doi:10.1007/s00417-016-3375-1
24. Boddu S, Lee MD, Marsiglia M, Marmor M, Freund KB, Smith RT. Risk Factors Associated with Reticular Pseudodrusen versus Large Soft Drusen. *Am J Ophthalmol*. 2014;157(5):985-993.e2. doi:10.1016/j.ajo.2014.01.023
25. Buitendijk GHS, Hooghart AJ, Brussee C, et al. Epidemiology of Reticular Pseudodrusen in Age-Related Macular Degeneration: The Rotterdam Study Epidemiology of Reticular Pseudodrusen. *Invest Ophthalmol Vis Sci*. 2016;57(13):5593-5601. doi:10.1167/iovs.15-18816
26. Capuano V, Souied EH, Miere A, Jung C, Costanzo E, Querques G. Choroidal maps in non-exudative age-related macular degeneration. *British Journal of Ophthalmology*. 2016;100(5):677-682. doi:10.1136/bjophthalmol-2015-307169

27. Chang YS, Kim JH, Yoo SJ, Lew YJ, Kim J. Fellow-eye neovascularization in unilateral retinal angiomatous proliferation in a Korean population. *Acta Ophthalmologica*. 2016;94(1):e49-e53. doi:10.1111/aos.12748
28. Cho HJ, Yoo SG, Kim HS, et al. Risk Factors for Geographic Atrophy After Intravitreal Ranibizumab Injections for Retinal Angiomatous Proliferation. *American Journal of Ophthalmology*. 2015;159(2):285-292.e1. doi:10.1016/j.ajo.2014.10.035
29. Cicinelli MV, Rabiolo A, Marchese A, et al. Choroid morphometric analysis in non-neovascular age-related macular degeneration by means of optical coherence tomography angiography. *British Journal of Ophthalmology*. January 2017:bjophthalmol-2016-309481. doi:10.1136/bjophthalmol-2016-309481
30. Corvi F, Souied EH, Capuano V, et al. Choroidal structure in eyes with drusen and reticular pseudodrusen determined by binarisation of optical coherence tomographic images. *British Journal of Ophthalmology*. 2017;101(3):348-352. doi:10.1136/bjophthalmol-2016-308548
31. Curcio CA, Messinger JD, Sloan KR, McGwin G, Medeiros NE, Spaide RF. Subretinal Drusenoid Deposits In Non-Neovascular Age-Related Macular Degeneration: Morphology, Prevalence, Topography, And Biogenesis Model. *Retina*. 2013;33(2). doi:10.1097/IAE.0b013e31827e25e0
32. Cymerman RM, Skolnick AH, Cole WJ, Nabati C, Curcio CA, Smith RT. Coronary Artery Disease and Reticular Macular Disease, a Subphenotype of Early Age-Related Macular Degeneration. *Curr Eye Res*. 2016;41(11):1482-1488. doi:10.3109/02713683.2015.1128552
33. De Bats F, Wolff B, Mauget-Fajysse M, Meunier I, Denis P, Kodjikian L. Association of Reticular Pseudodrusen and Early Onset Drusen. *ISRN Ophthalmology*. 2013;2013:1-9. doi:10.1155/2013/273085
34. De Bats F, Mathis T, Mauget-Fajysse M, Joubert F, Denis P, Kodjikian L. PREVALENCE OF RETICULAR PSEUDODRUSEN IN AGE-RELATED MACULAR DEGENERATION USING MULTIMODAL IMAGING: *Retina*. 2016;36(1):46-52. doi:10.1097/IAE.0000000000000648
35. Elfandi S, Ooto S, Ueda-Arakawa N, et al. Clinical and Genetic Characteristics of Japanese Patients with Age-Related Macular Degeneration and Pseudodrusen. *Ophthalmology*. 2016;123(10):2205-2212. doi:10.1016/j.ophtha.2016.06.052
36. Finger RP, Wu Z, Luu CD, et al. Reticular Pseudodrusen: A Risk Factor for Geographic Atrophy in Fellow Eyes of Individuals with Unilateral Choroidal Neovascularization. *Ophthalmology*. 2014;121(6):1252-1256. doi:10.1016/j.ophtha.2013.12.034
37. Finger RP, Chong E, McGuinness MB, et al. Reticular Pseudodrusen and Their Association with Age-Related Macular Degeneration: The Melbourne Collaborative Cohort Study. *Ophthalmology*. 2016;123(3):599-608. doi:10.1016/j.ophtha.2015.10.029
38. Garg A, Oll M, Yzer S, et al. Reticular Pseudodrusen in Early Age-Related Macular Degeneration Are Associated With Choroidal Thinning. *Invest Ophthalmol Vis Sci*. 2013;54(10):7075-7081. doi:10.1167/iovs.13-12474

39. Garg A, Blumberg DM, Al-Aswad LA, et al. Associations Between  $\beta$ -Peripapillary Atrophy and Reticular Pseudodrusen in Early Age-Related Macular Degeneration. *Invest Ophthalmol Vis Sci*. 2017;58(5):2810-2815. doi:10.1167/iovs.16-20343
40. Gil JQ, Marques JP, Hogg R, et al. Clinical features and long-term progression of reticular pseudodrusen in age-related macular degeneration: findings from a multicenter cohort. *Eye*. 2017;31(3):364-371. doi:10.1038/eye.2016.207
41. Haas P, Esmaelpour M, Ansari-Shahrezaei S, Drexler W, Binder S. Choroidal Thickness in Patients With Reticular Pseudodrusen Using 3D 1060-nm OCT Maps. *Invest Ophthalmol Vis Sci*. 2014;55(4):2674-2681. doi:10.1167/iovs.13-13338
42. Hogg RE, Silva R, Staurengi G, et al. Clinical Characteristics of Reticular Pseudodrusen in the Fellow Eye of Patients with Unilateral Neovascular Age-Related Macular Degeneration. *Ophthalmology*. 2014;121(9):1748-1755. doi:10.1016/j.ophtha.2014.03.015
43. Huisingh C, McGwin G, Neely D, et al. The Association Between Subretinal Drusenoid Deposits in Older Adults in Normal Macular Health and Incident Age-Related Macular Degeneration Subretinal Drusenoid Deposits and Incident AMD. *Invest Ophthalmol Vis Sci*. 2016;57(2):739-745. doi:10.1167/iovs.15-18316
44. Kim JH, Chang YS, Kim JW, Lee TG, Kim CG. Prevalence of subtypes of reticular pseudodrusen in newly diagnosed exudative age-related macular degeneration and polypoidal choroidal vasculopathy in Korean patients. *Retina*. 2015;35(12):2604-2612.
45. Klein R, Knudtson MD, Klein BEK, et al. Inflammation, Complement Factor H, and Age-Related Macular Degeneration: The Multi-Ethnic Study of Atherosclerosis. *Ophthalmology*. 2008;115(10):1742-1749. doi:10.1016/j.ophtha.2008.03.021
46. Kovach JL, Schwartz SG, Agarwal A, et al. The Relationship Between Reticular Pseudodrusen and Severity of AMD. *Ophthalmology*. 2016;123(4):921-923. doi:10.1016/j.ophtha.2015.10.036
47. Lee MY, Yoon J, Ham D-I. Clinical features of reticular pseudodrusen according to the fundus distribution. *British Journal of Ophthalmology*. 2012;96(9):1222-1226. doi:10.1136/bjophthalmol-2011-301207
48. Leisy HB, Ahmad M, Marmor M, Smith RT. Association between Decreased Renal Function and Reticular Macular Disease in Age-Related Macular Degeneration. *Ophthalmology Retina*. 2017;1(1):42-48. doi:10.1016/j.oret.2016.08.011
49. Lin LY, Zhou Q, Hagstrom S, et al. Association of Single-Nucleotide Polymorphisms in Age-Related Macular Degeneration With Pseudodrusen: Secondary Analysis of Data From the Comparison of AMD Treatments Trials. *JAMA Ophthalmol*. May 2018. doi:10.1001/jamaophthalmol.2018.1231
50. Marsiglia M, Boddu S, Bearely S, et al. Association Between Geographic Atrophy Progression and Reticular Pseudodrusen in Eyes With Dry Age-Related Macular Degeneration. *Invest Ophthalmol Vis Sci*. 2013;54(12):7362-7369. doi:10.1167/iovs.12-11073

51. Marsiglia M, Boddu S, Chen CY, et al. CORRELATION BETWEEN NEOVASCULAR LESION TYPE AND CLINICAL CHARACTERISTICS OF NONNEOVASCULAR FELLOW EYES IN PATIENTS WITH UNILATERAL, NEOVASCULAR AGE-RELATED MACULAR DEGENERATION: *Retina*. 2015;35(5):966-974. doi:10.1097/IAE.0000000000000460
52. McCarter RV, McKay GJ, Quinn NB, et al. Evaluation of coronary artery disease as a risk factor for reticular pseudodrusen. *British Journal of Ophthalmology*. August 2017;bjophthalmol-2017-310526. doi:10.1136/bjophthalmol-2017-310526
53. Mitchell P, Wang JJ, Foran S, Smith W. Five-year incidence of age-related maculopathy lesions. *Ophthalmology*. 2002;109(6):1092-1097. doi:10.1016/S0161-6420(02)01055-2
54. Naysan J, Jung JJ, Dansingani KK, Balaratnasingam C, Freund KB. TYPE 2 (SUBRETINAL) NEOVASCULARIZATION IN AGE-RELATED MACULAR DEGENERATION ASSOCIATED WITH PURE RETICULAR PSEUDODRUSEN PHENOTYPE: *Retina*. 2016;36(3):449-457. doi:10.1097/IAE.0000000000000758
55. Puche N, Blanco-Garavito R, Richard F, et al. Genetic and environmental factors associated with reticular pseudodrusen in age-related macular degeneration. *Retina (Philadelphia, Pa)*. 2013;33(5):998-1004. doi:10.1097/IAE.0b013e31827b6483
56. Pumariega NM, Smith RT, Sohrab MA, LeTien V, Souied EH. A PROSPECTIVE STUDY OF RETICULAR MACULAR DISEASE. *Ophthalmology*. 2011;118(8):1619-1625. doi:10.1016/j.ophtha.2011.01.029
57. Querques G, Canouï-Poitrine F, Coscas F, et al. Analysis of Progression of Reticular Pseudodrusen by Spectral Domain–Optical Coherence Tomography. *Invest Ophthalmol Vis Sci*. 2012;53(3):1264-1270. doi:10.1167/iovs.11-9063
58. Sarks J, Arnold J, Ho I-V, Sarks S, Killingsworth M. Evolution of reticular pseudodrusen. *British Journal of Ophthalmology*. 2011;95(7):979-985. doi:10.1136/bjo.2010.194977
59. Sawa M, Ueno C, Gomi F, Nishida K. INCIDENCE AND CHARACTERISTICS OF NEOVASCULARIZATION IN FELLOW EYES OF JAPANESE PATIENTS WITH UNILATERAL RETINAL ANGIOMATOUS PROLIFERATION: *Retina*. 2014;34(4):761-767. doi:10.1097/01.iae.0000434566.57189.37
60. Ravera V, Bottoni F, Giani A, Cigada M, Staurengi G. RETINAL ANGIOMATOUS PROLIFERATION DIAGNOSIS: A Multiimaging Approach. *Retina*. 2016;36(12):2274-2281. doi:10.1097/IAE.0000000000001152
61. Smith RT, Sohrab MA, Busuioc M, Barile G. Reticular Macular Disease. *Am J Ophthalmol*. 2009;148(5):733-743.e2. doi:10.1016/j.ajo.2009.06.028
62. Smith RT. Complement Factor H 402H Variant and Reticular Macular Disease. *Archives of Ophthalmology*. 2011;129(8):1061. doi:10.1001/archophthalmol.2011.212
63. Sohrab MA, Smith RT, Salehi-Had H, Sadda SR, Fawzi AA. Image Registration and Multimodal Imaging of Reticular Pseudodrusen. *Invest Ophthalmol Vis Sci*. 2011;52(8):5743-5748. doi:10.1167/iovs.10-6942

64. Spaide RF. Choriocapillaris Flow Features Follow a Power Law Distribution: Implications for Characterization and Mechanisms of Disease Progression. *American Journal of Ophthalmology*. 2016;170:58-67. doi:10.1016/j.ajo.2016.07.023
65. Steinberg JS, Göbel AP, Fleckenstein M, Holz FG, Schmitz-Valckenberg S. Reticular drusen in eyes with high-risk characteristics for progression to late-stage age-related macular degeneration. *British Journal of Ophthalmology*. 2015;99(9):1289-1294. doi:10.1136/bjophthalmol-2014-306535
66. Ueda-Arakawa N, Ooto S, Nakata I, et al. Prevalence and Genomic Association of Reticular Pseudodrusen in Age-Related Macular Degeneration. *American Journal of Ophthalmology*. 2013;155(2):260-269.e2. doi:10.1016/j.ajo.2012.08.011
67. Ueda-Arakawa N, Ooto S, Ellabban AA, et al. Macular Choroidal Thickness and Volume of Eyes With Reticular Pseudodrusen Using Swept-Source Optical Coherence Tomography. *American Journal of Ophthalmology*. 2014;157(5):994-1004.e3. doi:10.1016/j.ajo.2014.01.018
68. Wilde C, Patel M, Lakshmanan A, Morales MA, Dhar-Munshi S, Amoaku WMK. Prevalence of reticular pseudodrusen in eyes with newly presenting neovascular age-related macular degeneration. *Eur J Ophthalmol*. 2016;26(2):128-134. doi:10.5301/ejo.5000661
69. Wu Z, Ayton LN, Luu CD, Baird PN, Guymer RH. Reticular Pseudodrusen in Intermediate Age-Related Macular Degeneration: Prevalence, Detection, Clinical, Environmental, and Genetic Associations Reticular Pseudodrusen in Intermediate AMD. *Invest Ophthalmol Vis Sci*. 2016;57(3):1310-1316. doi:10.1167/iovs.15-18682
70. Xu L, Blonska AM, Pumariega NM, et al. Reticular Macular Disease is Associated with Multilobular Geographic Atrophy in Age-Related Macular Degeneration. *Retina*. 2013;33(9):1850-1862. doi:10.1097/IAE.0b013e31828991b2
71. Yoneyama S, Sakurada Y, Mabuchi F, et al. Genetic and clinical factors associated with reticular pseudodrusen in exudative age-related macular degeneration. *Graefe's Archive for Clinical and Experimental Ophthalmology*. 2014;252(9):1435-1441. doi:10.1007/s00417-014-2601-y
72. Yun C, Oh J, Ahn S-E, Hwang S-Y, Kim S-W, Huh K. Peripapillary choroidal thickness in patients with early age-related macular degeneration and reticular pseudodrusen. *Graefe's Archive for Clinical and Experimental Ophthalmology*. 2016;254(3):427-435. doi:10.1007/s00417-015-3054-7
73. Yun C, Ahn J, Kim M, Hwang S-Y, Kim S-W, Oh J. Ocular Perfusion Pressure and Choroidal Thickness in Early Age-Related Macular Degeneration Patients With Reticular Pseudodrusen OPP and CT in AMD Patients With Reticular Pseudodrusen. *Invest Ophthalmol Vis Sci*. 2016;57(15):6604-6609. doi:10.1167/iovs.16-19989
74. Zarubina AV, Neely DC, Clark ME, et al. Prevalence of subretinal drusenoid deposits in older persons with and without age-related macular degeneration, by multimodal imaging. *Ophthalmology*. 2016;123(5):1090-1100. doi:10.1016/j.ophtha.2015.12.034
75. Zheng F, Gregori G, Schaal KB, et al. Choroidal Thickness and Choroidal Vessel Density in Nonexudative Age-Related Macular Degeneration Using Swept-Source Optical

Coherence Tomography Imaging. *Invest Ophthalmol Vis Sci.* 2016;57(14):6256-6264.  
doi:10.1167/iovs.16-20161

76. Zweifel SA, Imamura Y, Spaide TC, Fujiwara T, Spaide RF. Prevalence and Significance of Subretinal Drusenoid Deposits (Reticular Pseudodrusen) in Age-Related Macular Degeneration. *Ophthalmology.* 2010;117(9):1775-1781.  
doi:10.1016/j.ophtha.2010.01.027

## SERMENT D'HIPPOCRATE

Au moment d'être admis à exercer la médecine, je promets et je jure d'être fidèle aux lois de l'honneur et de la probité.

Mon premier souci sera de rétablir, de préserver ou de promouvoir la santé dans tous ses éléments, physiques et mentaux, individuels et sociaux.

Je respecterai toutes les personnes, leur autonomie et leur volonté, sans aucune discrimination selon leur état ou leurs convictions. J'interviendrai pour les protéger si elles sont affaiblies, vulnérables ou menacées dans leur intégrité ou leur dignité. Même sous la contrainte, je ne ferai pas usage de mes connaissances contre les lois de l'humanité.

J'informerai les patients des décisions envisagées, de leurs raisons et de leurs conséquences.

Je ne tromperai jamais leur confiance et n'exploiterai pas le pouvoir hérité des circonstances pour forcer les consciences.

Je donnerai mes soins à l'indigent et à quiconque me les demandera. Je ne me laisserai pas influencer par la soif du gain ou la recherche de la gloire.

Admis dans l'intimité des personnes, je tairai les secrets qui me seront confiés. Reçu à l'intérieur des maisons, je respecterai les secrets des foyers et ma conduite ne servira pas à corrompre les mœurs.

Je ferai tout pour soulager les souffrances. Je ne prolongerai pas abusivement les agonies. Je ne provoquerai jamais la mort délibérément.

Je préserverai l'indépendance nécessaire à l'accomplissement de ma mission. Je n'entreprendrai rien qui dépasse mes compétences. Je les entretiendrai et les perfectionnerai pour assurer au mieux les services qui me seront demandés.

J'apporterai mon aide à mes confrères ainsi qu'à leurs familles dans l'adversité.

Que les hommes et mes confrères m'accordent leur estime si je suis fidèle à mes promesses ; que je sois déshonoré et méprisé si j'y manque.

# ABSTRACT

## INCIDENCE AND RISK FACTORS FOR RETICULAR PSEUDODRUSEN: THE ALIENOR STUDY

**Purpose:** To describe in a population-based study of French elderly subjects the incidence of reticular pseudodrusen (RPD) as detected using multimodal imaging, and to analyze their potential associated risk factors.

**Methods:** Population-based sample of 759 residents of Bordeaux, France, who participated in the Antioxydants, Lipides Essentiels, Nutrition et Maladies Oculaires (ALIENOR) Study. 257 were unable to come to hospital and did not perform all exams. Of the remaining 1004 eyes (502 participants), 532 eyes were excluded. Data were collected between February 22, 2011 and February 15, 2017 mean (SD) follow-up duration was 3.7 (1.0) years. RPD were defined as definite if they were classified as present with at least two imaging methods from among color fundus photography, fundus autofluorescence, near-infrared reflectance and optical coherence tomography.

**Results:** Of the 472 eyes participants, 263 (55.7%) were women, and the mean (SD) age was 81.9 (3.2) years. 42 eyes were incident for RPD with an overall annual incidence of 2.047% (95% CI, 1.373-3.051) and an estimated 5-year incidence of 9.73%. Annual incidence was higher in females, i.e. 1.948% (95% CI, 1.287-2.947) versus 1.512% (95% CI, 0.786-2.911) in males, and increased with age. In multivariate analysis, three risk factors for incident RPD were identified: subfoveal choroidal thinning (HR, 1.06; 95% CI 1.01-1.11; P=0.0085), presence of risk allele of ARMS2 rs10490924 (HR, 3.36; 95% CI 1.64-6.88; P=0.0009) and LIPC rs10468017 (HR, 2.65; 95% CI 1.39-5.03; P=0.0029). Taking liposoluble statin medication (HR, 0.18; 95% CI 0.03-0.96; P=0.0448) was shown to be a protective factor.

**Conclusions:** In this cohort, RPD incidence rate was higher to those observed in other population-based study. We confirm high risk for incident RPD in patients with subfoveal choroidal thinning and carriers of ARMS2 at-risk genotypes and suggests it in patients' carriers of LIPC at-risk genotypes. Also, taking liposoluble statin medication could be a protective factor.



## RESUME

### INCIDENCE ET FACTEURS DE RISQUE DES PSEUDODRUSEN RÉTICULÉS : L'ÉTUDE ALIENOR

**Objectif :** Décrire dans une cohorte de sujets âgés français, l'incidence des pseudodrusen réticulés (RPD) diagnostiqués par imagerie multimodale, et analyser les facteurs de risque associés.

**Méthodes :** Etude de cohorte issue d'un échantillon de 759 bordelais participant à l'étude ALIENOR (Antioxydants, Lipides Essentiels, Nutrition et Maladies Oculaires). Parmi eux, 257 ne pouvaient se rendre à l'hôpital pour réaliser l'ensemble des examens. Sur les 1004 yeux restants (502 participants), 532 ont été exclus. Les données ont été recueillies entre 2011 et 2017 et la durée moyenne de suivi était de 3.7 +/- 1.0 ans. Les RPD devaient être présents sur au moins deux examens parmi les rétinophotographies, les clichés en autofluorescence ou en proche infrarouge et la tomographie en cohérence optique.

**Résultats :** Sur les 472 yeux inclus, 263 (55.7%) étaient des femmes et l'âge moyen était de 81.9 +/-3.2 ans. 42 yeux présentaient des RPD incidents avec un taux d'incidence annuel de 2.047% (IC95%, 1.373-3.051) et une incidence à 5 ans estimée à 9.73%. L'incidence annuelle était plus élevée chez les femmes que chez les hommes (1.948% versus 1.512%) et augmentait également avec l'âge. En multivarié, trois facteurs de risque ont été identifiés : une épaisseur choroïdienne rétrofovéolaire plus mince (HR, 1.06 ; IC95% 1.01-1.11 ; p=0.0085) et la présence des génotypes à risque pour ARMS2 rs10490924 (HR, 3.36 ; IC95% 1.64-6.88 ; p=0.0009) et LIPC rs10468017 (HR, 2.65 ; IC95% 1.39-5.03 ; p=0.0029). La prise de statine liposoluble était un facteur protecteur (HR, 0.18 ; IC95% 0.03-0.96 ; p=0.0448).

**Conclusion :** Dans notre cohorte, l'incidence des RPD est plus élevée que dans les précédentes et nous confirmons deux facteurs de risque connus : amincissement choroïdien et ARMS2. LIPC en tant que facteur de risque et le caractère protecteur des statines liposolubles sont deux nouvelles associations nécessitant de nouvelles études.

**DISCIPLINE :** Ophtalmologie

**MOTS-CLEFS :** Pseudodrusen réticulés, dégénérescence maculaire liée à l'âge, épaisseur choroïdienne, ARMS2, LIPC, statines liposolubles, dépôts drusénoïdes sous-rétiniens, incidence

**INTITULÉ ET ADRESSE DU LABORATOIRE :** ISPED